

False Computed Tomography Findings in Bilateral Choanal Atresia

Ezzeddin Elsheikh¹ Mohammad Waheed El-Anwar¹

¹Department of Otorhinolaryngology - Head and Neck Surgery, School of Medicine, Zagazig University, Zagazig, Egypt

Int Arch Otorhinolaryngol 2016;20:163–165.

Address for correspondence Mohammad Waheed El-Anwar, MD, Department of Otorhinolaryngology Head and Neck Surgery, School of Medicine, Zagazig University, Zagazig 0020552309843, Egypt (e-mail: mwenteg@yahoo.com).

Abstract

Introduction Choanal atresia (CA) is a challenging surgical problem defined as a failure in the development of communication between the nasal cavity and nasopharynx.

Objective The objective of this study is to describe computed tomography (CT) findings in cases with bilateral choanal atresia.

Methods The study involved performing axial and coronal non-contrast CT scanning with 2–3 mm sections on 14 neonates that had bilateral CA. We used fiberoptic nasal endoscopy to confirm the diagnosis. We evaluated coronal CT to study the skull base area in such neonates.

Results This study included 14 neonates with bilateral CA; with mean age of 7 ± 3.5 days. Mixed atretic plates were found in 12 (85.7%) cases while two (14.3%) had pure bony atresia. Isolated CA was detected in 9 cases (64.3%) and 5 (35.7%) cases had associated anomalies. Coronal CT showed soft tissue density in the nasal cavity that appeared to extend through an apparent defect in the nasal roof (cribriform plate), falsely diagnosed by radiologists as associated encephalocele. At the time of surgical repair, all patients showed thick tenacious mucous secretions in both nasal cavities and revealed no encephalocele. Nasal roof remained intact in all cases.

Conclusion The thick secretion of bilateral CA could give a false encephalocele appearance on the CT. It is highly recommended to perform proper suction of the nasal cavity of suspected CA cases just before CT scanning.

Keywords

- ▶ choanal atresia
- ▶ computed tomography
- ▶ neonate
- ▶ encephalocele

Introduction

Congenital choanal atresia (CA) is a failure in the development of communication between the nasal cavity and nasopharynx causing complete obstruction of the choana.¹ Although its incidence is rare (~1 in 7000 births),² it represents the most common congenital abnormality of the nose.³

Congenital CA showed abnormally thickened third portion of the vomer.³ Paranasal computed tomography (CT) scan and nasal fiberoptic endoscopy are the gold standard of diagnostic tools,⁴ since they set the diagnosis and enable the examiner to identify the type and thickness of atresia.⁴

Congenital CA can be associated with other congenital anomalies in ~50% of cases^{5,6} and studies have reported accumulated tenacious mucous secretion with CA.⁷

At birth, the entire midline of the face may be composed of a radiolucent stripe of cartilage that lies between paired ossifications in the lateral masses of the ethmoids. On CT, this radiolucent fibrocartilage can simulate midline defect.^{8,9} The cribriform plate begins to ossify between 2 and 8 months. The meso ethmoidal center forms the perpendicular plate of the ethmoid and begins to ossify between the ages of 4 and 11 months. At age 6 years, the lateral masses and the perpendicular plate of the ethmoid unite across the nasal cavity by ossification of cribriform plate.⁸

received

April 8, 2015

accepted

October 4, 2015

published online

December 15, 2015

DOI <http://dx.doi.org/>

10.1055/s-0035-1570314.

ISSN 1809-9777.

Copyright © 2016 by Thieme Publicações Ltda, Rio de Janeiro, Brazil

License terms



The skull develops from three major ossification centers: the basioccipital, the basisphenoid, and the pre-sphenoid. The midline septal cartilage is continuous with the cartilaginous skull base and is not ossified at birth.⁸

The aim of this study was to describe and bring attention to false CT findings suggesting unilateral encephalocele in neonates with bilateral CA.

Patients and Methods

This study was conducted in the department of Otorhinolaryngology Head and Neck Surgery department on neonates with bilateral congenital CA in the period from October 2011 to January 2015. The parents of the children gave informed written consent. Revision cases were excluded from the study.

We reviewed the full history of all patients, which underwent a physical examination by attempt to pass six-French catheter through the nasal cavity to the nasopharynx. Before surgical repair, patients underwent axial and coronal non-contrast CT scanning with 2–3 mm sections. Fiberoptic nasal endoscopy was used to confirm the diagnosis. Then, we evaluated coronal CT to study the skull base area in the neonates.

Results

This study included 14 neonates that had bilateral CA; 10 (71.4%) girls and 4 (28.6%) boys. The mean age of the patients was 7 ± 3.5 days, ranging from 3 to 15 days. We detected mixed atretic plates in 12 (85.7%) cases while two patients (14.3%) had pure bony atresia.

Isolated CA was found in 9 cases (64.3%) while 5 (35.7%) cases had associated anomalies; one case had CHARGE syndrome with coloboma, ventricular septal defect, bilateral CA, retardation of growth and development, undescended small testis, and bilateral sensorineural hearing loss. While four cases had cardiac anomalies.

All neonates were diagnosed with bilateral CA by axial CT. Coronal CT showed soft tissue density in the nasal cavity

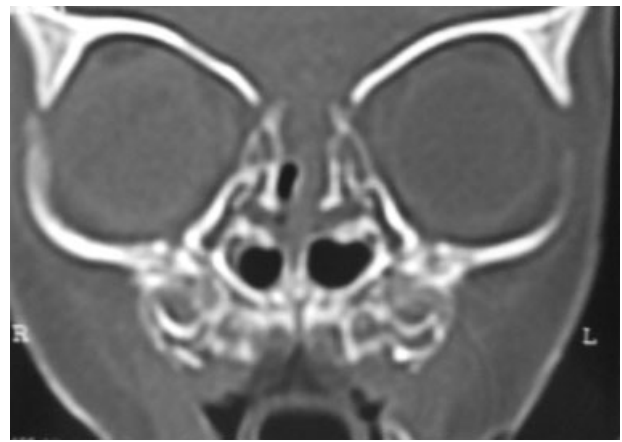


Fig. 1 Coronal CT of a neonate with bilateral choanal atresia with soft tissue density in nasal cavity appeared continuous with brain parenchyma due to lack of ossification along the floor of the anterior cranial fossa, falsely appearing as a bony defect.

appeared to extend through an apparent defect in the nasal roof (cribriform plate). The radiologists falsely diagnosed this soft tissue density as associated encephalocele (→Figs. 1, 2).

At the time of surgical repair, all patients showed thick tenacious mucous secretions in both nasal cavities and endoscopic assessment confirmed the diagnosis of bilateral CA, revealing no encephalocele with intact nasal roof in all cases.

Discussion

Bilateral CA causes complete bilateral nasal obstruction leading to immediate respiratory distress and even potential death due to asphyxia. This is because the newborn is obligated to nose breathe until 4–6 weeks of life when he learns mouth breathing. Therefore, bilateral CA is a life threatening condition making early diagnosis and treatment imperative.¹⁰

Encephaloceles occur as result of herniation of meninges, with or without brain tissue, through a congenital skull base

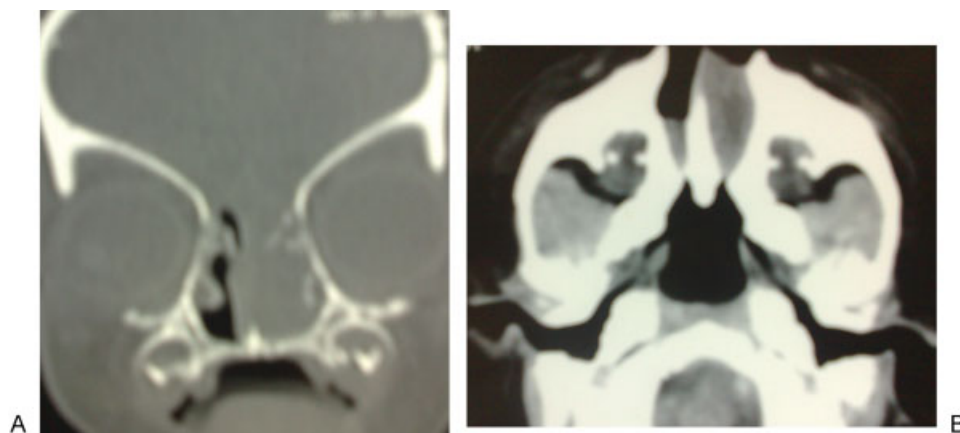


Fig. 2 Another case, A; Coronal CT showed soft tissue density in the nasal cavity appeared continuous with the brain parenchyma due to lack of ossification of the floor of the anterior cranial fossa. B; Axial CT showed bilateral choanal atresia appeared thick due to accumulated secretion in front.

defect. They may occur in occipital, basal, or fronto ethmoidal regions. All encephaloceles involve a midline skull defect, which corresponds to the site of neural tube closure in the midline. In the nasal region, encephaloceles generally present as nasal masses at birth. They may result in nasal obstruction, snoring, or respiratory distress.¹¹

CT scanning is the radiology of choice in the evaluation of CA¹² and it is useful for visualization of the skull base defect.¹¹

In 14% of infants less than one year old, there is no midline ossification of the anterior cranial fossa or septum. Thus, the entire midline of the face may be a radiolucent stripe of cartilage situated between the paired ossifications in the lateral masses of the ethmoids. This radiolucent line can simulate a midline cleft on imaging studies.^{8,13}

Accumulated tenacious mucous secretion in nasal cavity is one of the features found in CA.⁷ In axial CT, this secretion gives false appearance of thickened atretic segment.¹² However, in the current study, CT also gave a false encephalocele appearance in the very young neonates with bilateral CA.

The lack of midline facial ossification is not problematic in imaging in neonates with patent choanal because air in the nasal cavity abuts the cribriform plate.¹⁴ In CA, however, accumulated thick fluid in the nasal cavities with fluid attenuation approximates that of adjacent brain parenchyma, as described here. Thus, midline encephalocele may be impossible to exclude on the basis of CT examination alone.

After an extensive literature review using PubMed database, we found that only three neonates presented with bilateral CA associated with encephalocele. They were published as case reports^{14,15} with no consistent association between fronto ethmoidal encephalocele and CA.^{11,12}

Our case series increases surgeons and radiologists awareness of the developmental anatomy of the nasal cavity during interpretation of CT of CA. Moreover, we highly recommend performing proper and complete suction of the nasal cavity of the suspected cases in the CT center after the neonate is sedated and just before CT scanning.

Conclusion

The thick secretion of bilateral CA could give a false encephalocele appearance on CT. It is highly recommendable to perform proper suction of the nasal cavity of the suspected cases just before CT scanning.

Conflict of Interest and Financial Disclosure

The authors declare no financial support to this study and declare no conflict of interest.

References

- 1 Ibrahim AA, Magdy EA, Hassab MH. Endoscopic choanoplasty without stenting for congenital choanal atresia repair. *Int J Pediatr Otorhinolaryngol* 2010;74(2):144–150
- 2 Gujrathi CS, Daniel SJ, James AL, Forte V. Management of bilateral choanal atresia in the neonate: an institutional review. *Int J Pediatr Otorhinolaryngol* 2004;68(4):399–407
- 3 Case AP, Mitchell LE. Prevalence and patterns of choanal atresia and choanal stenosis among pregnancies in Texas, 1999–2004. *Am J Med Genet A* 2011;155A(4):786–791
- 4 Lubianca Neto JF, Kuhl G, Smith MM, Souza PA, Vieira LR. Association between congenital nasolacrimal duct cyst and bilateral choanal atresia. *Braz J Otorhinolaryngol* 2011;77(2):267
- 5 Keller JL, Kacker A. Choanal atresia, CHARGE association, and congenital nasal stenosis. *Otolaryngol Clin North Am* 2000;33(6):1343–1351, viii
- 6 Schoem SR. Transnasal endoscopic repair of choanal atresia: why stent? *Otolaryngol Head Neck Surg* 2004;131(4):362–366
- 7 Elsheikh E, El-Anwar MW, Abdel-aziz HR, Mohamed AF, Annany A. Choanal atresia: histochemical, immunohistochemical and ultrastructure study of the nasal mucosa. *Int J Pediatr Otorhinolaryngol* 2015;79(2):170–174
- 8 Naidich TP, Osborn RE, Bauer BS, McLone DG, Kernahan DA, Zapparackas ZG. Embryology and congenital lesions of the midface. In: Som PM, Bergerson RT, Curtin HD, et al, eds. *Head and Neck Imaging*. 2nd ed. St Louis, Mo: Mosby-Year Book; 1991:7–26
- 9 Naidich TP, Takahashi S, Tobin RB. Normal patterns of ossification of the skull base: ages 0–16 years. Presented at the annual meeting of the Radiological Society of North America, Chicago, Ill, November 1985
- 10 Sattar A, Sultan T. Choanal atresia, review article. *Bangladesh J Otorhinolaryngol* 2011;17(1):59–61
- 11 Naidich TP, Altman NR, Braffman BH, McLone DG, Zimmerman RA. Cephaloceles and related malformations. *AJNR Am J Neuroradiol* 1992;13(2):655–690
- 12 Chaudhary V, Anand RMK, Narula MK, Singh SK. The role of computed tomography in the evaluation of bilateral choanal atresia: two case reports. *Iran J Radiol* 2009;6(4):221–224
- 13 Scott JH. The cartilage of the nasal septum (a contribution to the study of facial growth). *Br Dent J* 1953;95:37–43
- 14 Black CM, Dungan D, Fram E, et al. Potential pitfalls in the work-up and diagnosis of choanal atresia. *AJNR Am J Neuroradiol* 1998;19(2):326–329
- 15 Dunham ME, Miller RP. Bilateral choanal atresia associated with malformation of the anterior skull base: embryogenesis and clinical implications. *Ann Otol Rhinol Laryngol* 1992;101(11):916–919