



Arthroscopic Medial Meniscal Posterior Root Repair With Transtibial Luggage-Tag and Horizontal Mattress Sutures

David Drynan, M.B.B.S., B.E., F.R.A.C.S.(Orth), Marcel Betsch, M.H.B.A., Wael Aljilani, M.B.B.S., S.B.Ortho, and Daniel B. Whelan, F.R.C.S.

Abstract: Medial meniscal posterior root repair techniques have shown positive yet varied results in the literature. The decision to perform repair has improved clinical outcomes in many situations, although the healing rate is approximately 64% and the repair strength is roughly one-third of the native root strength, with meniscal extrusion being common. We present a technique based on biomechanical evidence to obtain a strong anatomic posterior root repair to restore nearly normal knee mechanics, combining an increased size of footprint under the lateral aspect of the medial meniscal horn for healing and a luggage-tag suture with a posteriorly placed horizontal mattress suture. The horizontal mattress suture is passed to capture the circumferential fibers of the meniscus and the luggage-tag suture is passed to capture the radial fibers of the meniscal body, through a single transtibial tunnel. The aim of this repair is to restore the normal meniscal function.

There is increased focus regarding tears of the medial meniscal posterior root as increased clinical data confirm its importance in knee function. Medial meniscal posterior root tears (MMPRTs) have been reported in 2 case reports in the adolescent population and at rates between 10.1% and 27.8% in the adult knee.¹⁻³ Meniscal root tears involve the area from the tibial insertion to 9 mm from the insertion, and they increase medial-compartment contact pressure and cause altered kinematics and meniscal extrusion, leading to degenerative disease within a year.⁴⁻⁷

Restoring knee kinematics and force distribution via an appropriately positioned meniscus is essential for

achieving good functional results, improving force distribution across the joint, normalizing internal rotation and anterior translation, and limiting degenerative joint disease.^{6,8-10} This is dependent on complete healing of the meniscus, with stated rates between 0% and 95%, with an average healing rate of 64%, to prevent meniscal excursion and abnormal mechanics.^{8,9,11,12} To assist in preventing excursion, some authors have used tendon grafts, medial anchors, and additional tunnels, improving stability.^{5,13-16} Other authors have advocated different suture configurations and types with a pullout technique to improve stability and prevent excursion although mainly in biomechanical studies.¹⁷⁻³¹

Many authors have attempted to decrease extrusion and improve function through alternate suture techniques, using more sutures, additional anchors, or fixation of the posteromedial tibial plateau. We believe that by combining the clinical and biomechanical evidence with the basic science and anatomic constraints of the medial meniscus while attempting to address the meniscal root pathology, we can achieve a safe, reproducible, and biomechanically sound repair of MMPRTs.

Technique

Positioning and View

The patient is placed supine on the operating table, with an above-knee tourniquet, lateral bolster, and foot roll, and is draped in the standard arthroscopy fashion.

From the Division of Orthopaedic Surgery, University Hospital Network, Toronto Western Hospital, Toronto, Ontario, Canada (D.D.); Division of Orthopaedic Surgery, University of Toronto, Women's College Hospital, Toronto, Ontario, Canada (M.B., W.A.); and Division of Orthopaedic Surgery, University of Toronto, St Michael's Hospital, Toronto, Ontario, Canada (D.B.W.).

The authors report no conflicts of interest in the authorship and publication of this article. Full ICMJE author disclosure forms are available for this article online, as [supplementary material](#).

Received July 2, 2020; accepted September 10, 2020.

Address correspondence to David Drynan, M.B.B.S., B.E., F.R.A.C.S.(Orth), Orthopaedic Department, Toronto Western Hospital, 399 Bathurst St, Toronto, Ontario M5T 2S8, Canada. E-mail: david.drynan@gmail.com

© 2020 by the Arthroscopy Association of North America. Published by Elsevier. This is an open access article under the CC BY-NC-ND license (<http://creativecommons.org/licenses/by-nc-nd/4.0/>).

2212-6287/201153

<https://doi.org/10.1016/j.eats.2020.09.004>

Table 1. Equipment for Arthroscopic Posterior Medial Root Repair

Standard arthroscopy setup with 30° scope
Acuflex ACL Tip Aimer guide (Smith & Nephew)
2.4-mm Beath pin (Smith & Nephew)
Curved curette
Hewson suture passer (Smith & Nephew)
ConMed Spectrum suture passer with PDS shuttle sutures
No. 2 Ultrabraid × 2 (Smith & Nephew)
EndoButton (Smith & Nephew)

ACL, anterior cruciate ligament.

In the case displayed, a combined anterior cruciate ligament (ACL) tear and MMPRT are addressed, and the bone–patellar tendon–bone (BPTB) graft harvest incision is used on the medial aspect for anteromedial and accessory anteromedial portal access. If the MMPRT is not combined with an ACL reconstruction, then standard anterolateral, anteromedial, and accessory anteromedial portals are used, and a small incision lateral to the tibial tuberosity is made for fixation of the meniscal repair sutures.

Operative Technique

Diagnostic arthroscopy is performed to assess the lesion in question, confirm associated injuries, and assess access. In the case of a medial meniscal root tear, we perform a titrated extra-articular release of the medial collateral ligament to improve access and visualization to the posterior horn and root, with a spinal needle release from the posteromedial aspect inferior to the tibial flare (Video 1). The equipment needed for our technique is shown Table 1, pearls and pitfalls are presented in Table 2, and diagnostic findings of root tears are presented in Figure 1.

Desired tibial footprint preparation is performed with the knee in extension and valgus force to open the posteromedial aspect of the knee. A curette is introduced, and cartilage is removed from the anatomic root posterior to the ACL, in a posteromedial direction for approximately 5mm to bleeding bone, to improve healing (Figs 2 and 3). The footprint preparation is completed with an arthroscopic shaver as needed (Fig 4). Then, a 2.4-mm guide pin is passed through the ACL tip-aiming guide approximately 5 to 6 mm medial to the anatomic root, achieving approximately 3 mm of cancellous bone surrounding the guidewire (Fig 5). This allows the anatomic reduction of the meniscus while suturing the strongest aspects of the meniscus with downward pressure. Care must be taken during this step not to injure the neurovascular structures in the posterior compartment of the knee.

A 45° ConMed Spectrum suture passer (ConMed, Utica, NY) is introduced into the knee, and sutures are passed just medial to the transition zone through the body of the posterior horn. The first limb of the No. 2

Ultrabraid (Smith & Nephew, Watford, England) should pass at the junction of the outer and middle thirds of the meniscus, and the second limb should pass in the central aspect of the middle third of the meniscal tissue abutting the red-white/white zone to capture the radial fibers for strength. This creates a luggage tag–type suture configuration in the meniscal root, which we believe further strengthens the repair. Then, a horizontal mattress suture (No. 2 Ultrabraid) is passed in the body, medial to the transition zone, posterior to the luggage-tag suture, with the first limb in the peripheral third and the second limb at the junction of the middle and peripheral thirds of the meniscus. This technique is performed to capture the fiber orientation of the posterior horn of the meniscus and apply a large surface area of downward pressure to the footprint, and we believe that a suture passes through the meniscus with less trauma than a tape and has a similar cut-through rate.

All sutures limbs are shuttled via a Hewson suture passer (Smith & Nephew) to the anterolateral tibia to be tied over an EndoButton (Smith & Nephew) (Fig 6). The drill tunnel is located lateral to the tibial tuberosity to avoid tunnel interference in combination procedures and is as short as possible to avoid the bungee effect of long tunnels. The sutures are tied over an EndoButton placed on the tibial cortex, with the knee reduced, if there is concomitant ligamentous injury, and held at 30° of flexion (Figs 7 and 8).

Rehabilitation

The patient is initially placed in a knee extension brace until quadriceps control is regained; then, physiotherapist-guided non–weight-bearing rehabilitation is commenced. Rehabilitation includes a graded increase in non–weight-bearing flexion and extension exercises from 0° to 90° for 6 weeks, allowing limited internal rotation, followed by full range of motion and a

Table 2. Pearls and Pitfalls for Arthroscopic Posterior Medial Root Repair

Pearls
A percutaneous titrated MCL release should be performed.
The surgeon should remove cartilage to bleeding bone, following the line of the posterior rim of the meniscus.
The surgeon should plan where the sutures are to be placed in the body of the meniscus and then place the ACL guide pin in the center of the planned sutures.
Placement of a luggage-tag suture first can often help hold the meniscus reduced to allow placement of a horizontal mattress suture at the posterior aspect.
Pitfalls
Footprint too small
Mismatch between tibial tunnel and ideal sutures in body medial to transition zone
Luggage-tag suture too central in white-white zone, which can fold meniscus

ACL, anterior cruciate ligament; MCL, medial collateral ligament.

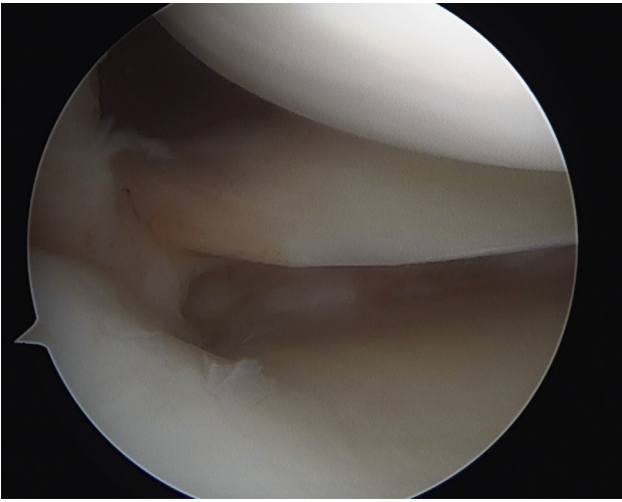


Fig 1. Diagnostic arthroscopic findings, confirming a type 2 posterior medial meniscal root tear (supine position, right side, viewing from the anterolateral portal).

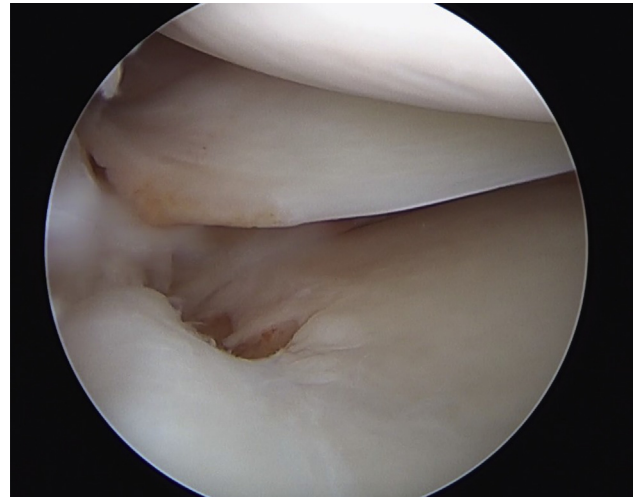


Fig 3. Tibial footprint preparation (supine position, right side, viewing from the anterolateral portal).

graded return to weight bearing from weeks 6 to 8 postoperatively. The patient is allowed to perform deep squats after the fourth postoperative month and to return to sport-related training at 5 months.

Discussion

Repair of MMPRTs is required to restore normal knee mechanics, improve functional outcomes, and delay degenerative disease.^{6-8,13,32-39} Lee et al.⁹ have shown that patients with stable healed meniscal roots have higher Hospital for Special Surgery and International Knee Documentation Committee scores, presumably

owing to restoration of knee mechanics and proprioception.⁴⁰ Our technique uses a luggage-tag stitch through the body of the meniscus combined with a horizontal mattress suture for improved downward pressure and resistance to displacement, aiming to restore the nearly normal mechanics of the medial meniscus.

The anatomic footprint of the medial meniscal posterior root is an area of approximately 30.4 mm² in the posterior intercondylar fossa, a small area anterior to the posterior cruciate ligament.^{41,42} By restoring the anatomic location of the root and decreasing excursion, hoop stress and meniscal function are restored.⁴³⁻⁴⁶

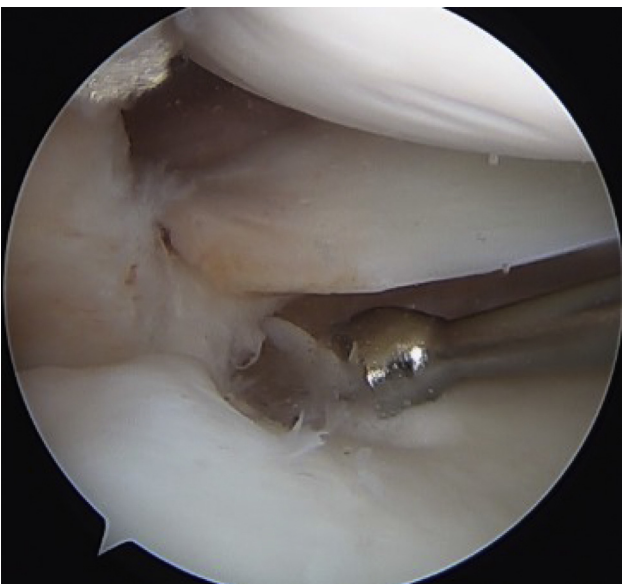

Fig 2. Curettage to the medial root and cartilage under the radial fibers and body (right side, viewing from the lateral portal), with a curved curette through the medial portal.

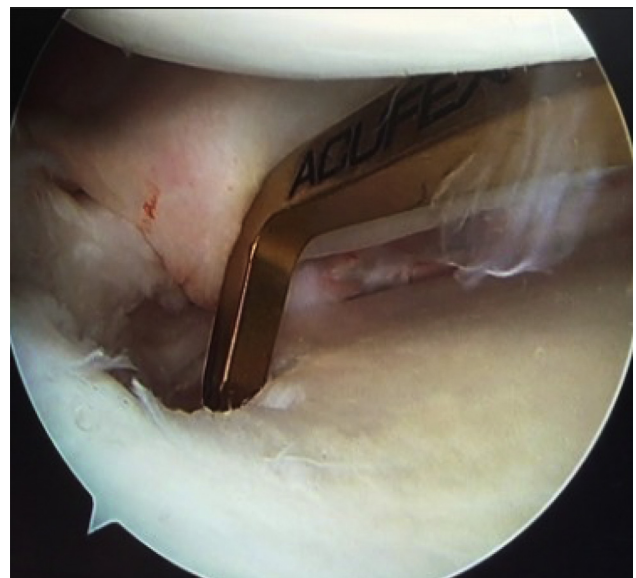


Fig 4. Acuflex anterior cruciate ligament guide used to drill through the center of the posterior medial root repair, slightly medial to the anatomic origin, to improve footprint healing (supine position, right side, viewing from the anterolateral portal).

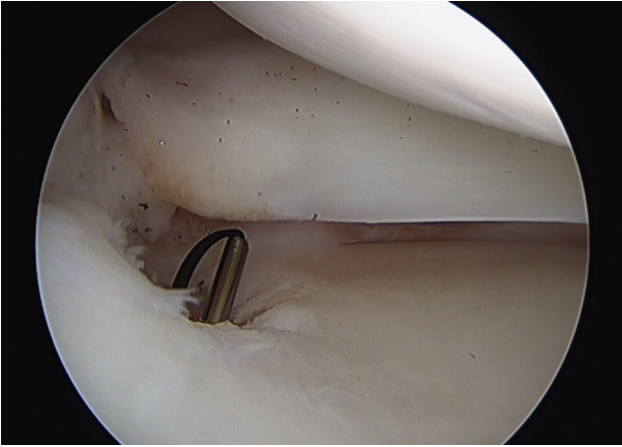


Fig 5. Hewson suture passer placed in the center-medial aspect of the footprint (supine position, right side, viewing from the anterolateral portal).

Exposing bleeding cancellous bone in the line of the posterior horn of the medial meniscus, we aim to achieve stable healing of the root and improve stability of the meniscus by increasing the footprint under the red-red zone and location of the circumferential fibers to achieve ideal restoration of the hoop stress distribution without overconstraining the posterior horn movement.^{41,47} Kwon et al.⁴⁸ found that lateral tibial tunnel placement is more accurate and the tunnel is usually 5.6 mm medial to the root; by

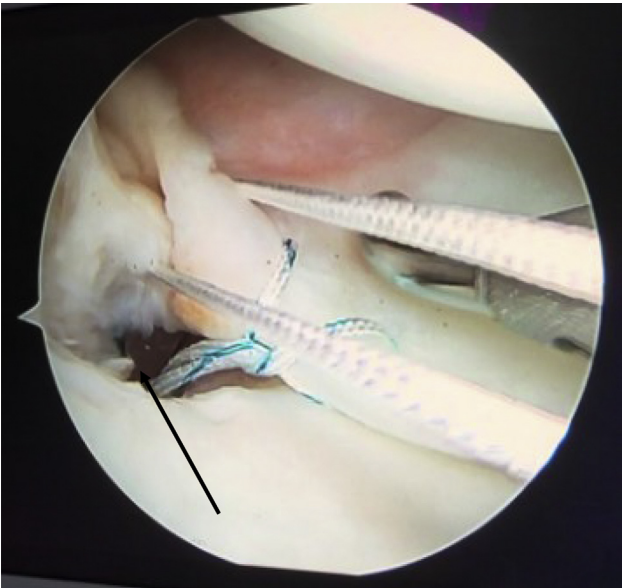


Fig 6. Passage of a horizontal mattress suture posterior to the luggage-tag suture, capturing the initial circumferential fibers in the body (supine position, right side, viewing from anterolateral portal). The ConMed suture passer is in the root or body. The white suture is 1 limb of the horizontal mattress suture. The black arrow indicates the Hewson suture passer. The luggage-tag suture is passed through the tibial tunnel.

increasing our footprint, this lateral tunnel is placed centrally over the cancellous bone for a maximum healing surface, with the passage of sutures medial to the transition zone for improved repair strength.⁴⁹

The suture type and technique have been investigated comparing multiple iterations, although no studies to date have compared the suture location and combination of suture constructs and materials that we suggest using. LaPrade et al.⁵⁰ have shown no significant difference between a single tunnel and double tunnels for MMPRT fixation; moreover, the transtibial pullout technique has a limited bungee effect and a relatively strong construct, with ultimate failure of approximately 400 N.^{17,51} The suture material and technique are the weakest link in the construct, with the strongest ultimate load to failure of 3 mm of displacement in braided tapes, although knot security is of concern and creep has been shown.^{19,49} The final strongest suture construct reported is the modified Mason-Allen stitch, with an ultimate failure load of 325 ± 77 N, although this is far lower than the ultimate tensile failure load of the posterior root of the native meniscus, reported as 359 ± 168 N to 678 ± 140 N in 2 studies.^{26,28,31} Our technique, using a luggage-tag suture and a horizontal mattress suture, is not biomechanically validated for strength; it does combine aspects of biomechanical studies to assess strength, suture pullout, displacement, strength of bony fixation, and restoration of anatomy. A recent study by Lee et al.⁵² described an increased healing rate of root repairs with atelocollagen augmentation with Mason-Allen suture repair.

Rehabilitation has not yet been fully explored after MMPRT repairs. Current biomechanical modeling of partial weight-bearing knee rehabilitation would place 60 ± 20 N of force through the posterior root, with the

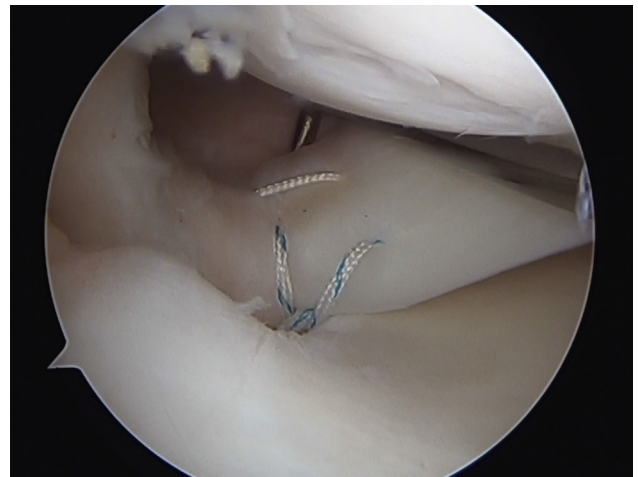


Fig 7. Suture configuration, with the luggage-tag suture (blue) in the anterior-central aspect and the horizontal mattress suture (white) in the peripheral aspect (supine position, right side, viewing from anterolateral portal).

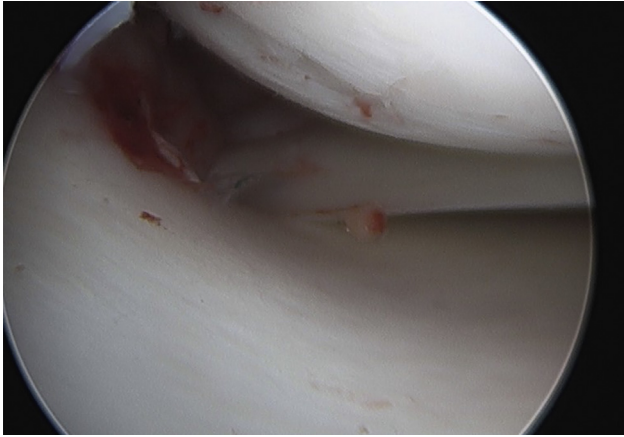


Fig 8. The medial meniscal root is reduced to the footprint and an ultrabraid is tied via a single tibial tunnel over an Endobutton. (Supine position, right side, view from anterolateral portal.)

maximum at 90° and internal rotation.⁵³ In our rehabilitation protocol, patients are non-weight bearing for 6 weeks, allowing 0° to 90° of range; limited internal rotation can be attempted.

Specific risks and considerations associated with our technique include tunnel proximity to the ACL tunnel, ensuring no convergence, and the theoretical risk of EndoButton subsidence if placed on metaphyseal bone at the BPTB harvest site. We pay particular attention to medial collateral ligament release, if required, and avoid this technique in valgus knee patients, and we place the EndoButton under the tibialis anterior fascia or in the bone defect from the BPTB tibial graft site. We ensure to traction the meniscus root into the anatomic footprint, ensure not to over reduce, but tension the sutures for compression at root, allowing known small amount of stretch of construct shown above.

The clinical benefits of posterior root tear repairs are well documented, with improved knee function scores, normalized kinematics, and a delay in degenerative joint disease, yet the rate of complete healing remains roughly 64%.^{9,10,38,54-57} Our technique has not been clinically validated in the literature but does follow published biomechanical and clinical principles. The future of this technique is to be biomechanically and clinically validated.

References

- Ozkoc G, Circi E, Gonc U, Irgit K, Pourbagher A, Tandogan RN. Radial tears in the root of the posterior horn of the medial meniscus. *Knee Surg Sports Traumatol Arthrosc* 2008;16:849-854.
- Bin SI, Kim JM, Shin SJ. Radial tears of the posterior horn of the medial meniscus. *Arthroscopy* 2004;20:373-378.
- Sonnery-Cottet B, Mortati R, Archbold P, Gadea F, Clechet J, Thauinat M. Root avulsion of the posterior horn of the medial meniscus in skeletally immature patients. *Knee* 2014;21:1291-1296.
- LaPrade CM, James EW, Cram TR, Feagin JA, Engebretsen L, LaPrade RF. Meniscal root tears: A classification system based on tear morphology. *Am J Sports Med* 2015;43:363-369.
- Daney BT, Aman ZS, Krob JJ, et al. Utilization of transtibial centralization suture best minimizes extrusion and restores tibiofemoral contact mechanics for anatomic medial meniscal root repairs in a cadaveric model. *Am J Sports Med* 2019;47:1591-1600.
- Allaire R, Muriuki M, Gilbertson L, Harner CD. Biomechanical consequences of a tear of the posterior root of the medial meniscus. Similar to total meniscectomy. *J Bone Joint Surg Am* 2008;90:1922-1931.
- Krych AJ, Johnson NR, Mohan R, et al. Arthritis progression on serial MRIs following diagnosis of medial meniscal posterior horn root tear. *J Knee Surg* 2018;31:698-704.
- Feucht MJ, Kühle J, Bode G, et al. Arthroscopic transtibial pullout repair for posterior medial meniscus root tears: A systematic review of clinical, radiographic, and second-look arthroscopic results. *Arthroscopy* 2015;31:1808-1816.
- Lee SS, Ahn JH, Kim JH, Kyung BS, Wang JH. Evaluation of healing after medial meniscal root repair using second-look arthroscopy, clinical, and radiological criteria. *Am J Sports Med* 2018;46:2661-2668.
- DePhillipo NN, Moatshe G, Brady A, et al. Effect of meniscocapsular and meniscotibial lesions in ACL-deficient and ACL-reconstructed knees: A biomechanical study. *Am J Sports Med* 2018;46:2422-2431.
- Lee JH, Lim YJ, Kim KB, Kim KH, Song JH. Arthroscopic pullout suture repair of posterior root tear of the medial meniscus: Radiographic and clinical results with a 2-year follow-up. *Arthroscopy* 2009;25:951-958.
- Seo HS, Lee SC, Jung KA. Second-look arthroscopic findings after repairs of posterior root tears of the medial meniscus. *Am J Sports Med* 2011;39:99-107.
- Koga H, Watanabe T, Horie M, et al. Augmentation of the pullout repair of a medial meniscus posterior root tear by arthroscopic centralization. *Arthrosc Tech* 2017;6:e1335-e1339.
- Lee DW, Haque R, Chung KS, Kim JG. Arthroscopic medial meniscus posterior root reconstruction using auto-gracilis tendon. *Arthrosc Tech* 2017;6:e1431-e1435.
- Prado-Novoa M, Perez-Blanca A, Espejo-Reina A, Espejo-Reina MJ, Espejo-Baena A. Initial biomechanical properties of transtibial meniscal root repair are improved by using a knotless anchor as a post-insertion tensioning device. *Sci Rep* 2020;10:1748.
- Holmes SW Jr, Huff LW, Barnes AJ, Baier AJ. Anatomic reinforced medial meniscal root reconstruction with gracilis autograft. *Arthrosc Tech* 2019;8:e209-e213.
- Robinson JR, Hernandez BA, Taylor C, Gill HS. Knotless anchor fixation for transosseous meniscal root repair using suture tape is inferior compared with button or screw fixation: A biomechanical study. *Orthop J Sports Med* 2020;8. 2325967120912185.
- Furumatsu T, Okazaki Y, Kodama Y, et al. Pullout repair using modified Mason-Allen suture induces better

- meniscal healing and superior clinical outcomes: A comparison between two surgical methods. *Knee* 2019;26:653-659.
19. Nakama GY, Aman ZS, Storaci HW, Kuczmarski AS, Krob JJ, Strauss MJ. Different suture materials for arthroscopic transtibial pull-out repair of medial meniscal posterior root tears: A human biomechanical study. *Orthop J Sports Med* 2019;7:2325967119873274.
 20. Okazaki Y, Furumatsu T, Miyazawa S, et al. A novel suture technique to reduce the meniscus extrusion in the pullout repair for medial meniscus posterior root tears. *Eur J Orthop Surg Traumatol* 2019;29:1805-1809.
 21. Okimura S, Mae T, Tachibana Y, et al. Biomechanical comparison of meniscus-suture constructs for pullout repair of medial meniscus posterior root tears. *J Exp Orthop* 2019;6:17.
 22. Steineman BD, LaPrade RF, Haut Donahue TL. Loosening of transtibial pullout meniscal root repairs due to simulated rehabilitation is unrecoverable: A biomechanical study. *Arthroscopy* 2019;35:1232-1239.
 23. Samy TM, Nassar WAM, Zakaria ZM, Farrag Abdelaziz AK. Medial meniscus posterior root tear repair using a 2-simple-suture pullout technique. *Arthrosc Tech* 2017;6:e579-e583.
 24. Camarda L, Pitarresi G, Lauria M, Fazzari F, D'Arienzo M. Three single loops enhance the biomechanical behavior of the transtibial pull-out technique for posterior meniscal root repair. *Arch Orthop Trauma Surg* 2017;137:1301-1306.
 25. Smith PA, Bley JA. Simplified arthroscopic lateral meniscal root repair involving the use of 2 cinch-loop sutures. *Arthrosc Tech* 2017;6:e73-e79.
 26. Mitchell R, Pitts R, Kim YM, Matava MJ. Medial meniscal root avulsion: A biomechanical comparison of 4 different repair constructs. *Arthroscopy* 2016;32:111-119.
 27. Lavender CD, Hanzlik SR, Caldwell PE III, Pearson SE. Transosseous medial meniscal root repair using a modified Mason-Allen suture configuration. *Arthrosc Tech* 2015;4:e781-e784.
 28. LaPrade RF, LaPrade CM, Ellman MB, Turnbull TL, Cerminara AJ, Wijdicks CA. Cyclic displacement after meniscal root repair fixation: A human biomechanical evaluation. *Am J Sports Med* 2015;43:892-898.
 29. Anz AW, Branch EA, Saliman JD. Biomechanical comparison of arthroscopic repair constructs for meniscal root tears. *Am J Sports Med* 2014;42:2699-2706.
 30. Lee DW, Kim MK, Jang HS, Ha JK, Kim JG. Clinical and radiologic evaluation of arthroscopic medial meniscus root tear re-fixation: Comparison of the modified Mason-Allen stitch and simple stitches. *Arthroscopy* 2014;30:1439-1446.
 31. Kopf S, Colvin AC, Muriuki M, Zhang X, Harner CD. Meniscal root suturing techniques: Implications for root fixation. *Am J Sports Med* 2011;39:2141-2146.
 32. Frank JM, Liechti DJ, Anavian J, Hackett TR. A transosseous bone bridge repair for posterior horn meniscal root tears during anterior cruciate ligament reconstruction. *Arthrosc Tech* 2017;6:e239-e243.
 33. Bonasia DE, Pellegrino P, D'Amelio A, Cottino U, Rossi R. Meniscal root tear repair: Why, when and how? *Orthop Rev (Pavia)* 2015;7:5792.
 34. Bhatia S, LaPrade CM, Ellman MB, LaPrade RF. Meniscal root tears: Significance, diagnosis, and treatment. *Am J Sports Med* 2014;42:3016-3030.
 35. Papalia R, Vasta S, Franceschi F, D'Adamio S, Maffulli N, Denaro V. Meniscal root tears: From basic science to ultimate surgery. *Br Med Bull* 2013;106:91-115.
 36. Vyas D, Harner CD. Meniscus root repair. *Sports Med Arthrosc Rev* 2012;20:86-94.
 37. Okazaki Y, Furumatsu T, Yamauchi T, et al. Medial meniscus posterior root repair restores the intra-articular volume of the medial meniscus by decreasing posteromedial extrusion at knee flexion. *Knee Surg Sports Traumatol Arthrosc* 2020;28:3435-3442.
 38. Kim CW, Lee CR, Gwak HC, et al. Clinical and radiologic outcomes of patients with lax healing after medial meniscal root repair: Comparison with subtotal meniscectomy. *Arthroscopy* 2019;35:3079-3086.
 39. Vaquero-Picado A, Rodríguez-Merchán EC. Arthroscopic repair of the meniscus: Surgical management and clinical outcomes. *EFORT Open Rev* 2018;3:584-594.
 40. Yoon KH, Park KH. Meniscal repair. *Knee Surg Relat Res* 2014;26:68-76.
 41. Markes AR, Hodax JD, Ma CB. Meniscus form and function. *Clin Sports Med* 2020;39:1-12.
 42. Johannsen AM, Civitarese DM, Padalecki JR, Goldsmith MT, Wijdicks CA, LaPrade RF. Qualitative and quantitative anatomic analysis of the posterior root attachments of the medial and lateral menisci. *Am J Sports Med* 2012;40:2342-2347.
 43. Steineman B, LaPrade R, Haut Donahue TL. Nonanatomic placement of posteromedial meniscal root repairs: A finite element study [published online January 1, 2020]. *J Biomech Eng*. <https://doi.org/10.1115/1.4045893>.
 44. Chahla J, LaPrade RF. Meniscal root tears. *Arthroscopy* 2019;35:1304-1305.
 45. Pache S, Aman ZS, Kennedy M, et al. Meniscal root tears: Current concepts review. *Arch Bone Jt Surg* 2018;6:250-259.
 46. Marzo JM, Gurske-DePerio J. Effects of medial meniscus posterior horn avulsion and repair on tibiofemoral contact area and peak contact pressure with clinical implications. *Am J Sports Med* 2009;37:124-129.
 47. Śmigielski R, Becker R, Zdanowicz U, Ciszek B. Medial meniscus anatomy-from basic science to treatment. *Knee Surg Sports Traumatol Arthrosc* 2015;23:8-14.
 48. Kwon SW, Kim JB, Kim CH, Hong SJ, Hong YC, Jang BW. Comparison of medial and lateral tibial tunnel in pullout repair of posterior root tear of medial meniscus: Radiologic, clinical, and arthroscopic outcomes. *J Orthop Surgery (Hong Kong)* 2020;28:2309499020918759.
 49. Robinson JR, Frank EG, Hunter AJ, Jermin PJ, Gill HS. The strength of transosseous medial meniscal root repair using a simple suture technique is dependent on suture material and position. *Am J Sports Med* 2018;46:924-932.
 50. LaPrade CM, LaPrade MD, Turnbull TL, Wijdicks CA, LaPrade RF. Biomechanical evaluation of the transtibial pull-out technique for posterior medial meniscal root repairs using 1 and 2 transtibial bone tunnels. *Am J Sports Med* 2015;43:899-904.
 51. Cerminara AJ, LaPrade CM, Smith SD, Ellman MB, Wijdicks CA, LaPrade RF. Biomechanical evaluation of a

- transtibial pull-out meniscal root repair: Challenging the bungee effect. *Am J Sports Med* 2014;42:2988-2995.
52. Lee DW, Jang HG, Lee YJ, Moon SG, Kim NR, Kim JG. Effect of atelocollagen on the healing status after medial meniscal root repair using the modified Mason-Allen stitch. *Orthop Traumatol Surg Res* 2020;106:969-975.
 53. Stärke C, Kopf S, Lippisch R, Lohmann CH, Becker R. Tensile forces on repaired medial meniscal root tears. *Arthroscopy* 2013;29:205-212.
 54. Furumatsu T, Okazaki Y, Hiranaka T, et al. An MRI-based suspension bridge sign can predict an arthroscopically favorable meniscal healing following the medial meniscus posterior root repair [published online April 10, 2020]. *J Orthop Sci*. <https://doi.org/10.1016/j.jos.2020.03.012>.
 55. Lee OS, Lee SH, Lee YS. Comparison of the radiologic, arthroscopic, and clinical outcomes between repaired versus unrepaired medial meniscus posterior horn root tear during open wedge high tibial osteotomy [published online July 9, 2019]. *J Knee Surg*. <https://doi.org/10.1055/s-0039-1692992>.
 56. Feucht MJ, Izadpanah K, Lacheta L, Südkamp NP, Imhoff AB, Forkel P. Arthroscopic transtibial pullout repair for posterior meniscus root tears. *Oper Orthop Traumatol* 2019;31:248-260.
 57. Furumatsu T, Miyazawa S, Fujii M, Tanaka T, Kodama Y, Ozaki T. Arthroscopic scoring system of meniscal healing following medial meniscus posterior root repair. *Int Orthop* 2019;43:1239-1245.