

Case Report

Neuromuscular hamartoma of the sciatic nerve: Case report and review of the literature

Sandi Lam, Ramesh Grandhi¹, Ricky Wong, Ronald Hamilton², Stephanie Greene¹Department of Surgery, University of Chicago, 5841 S. Maryland Ave, MC3026, J341, Chicago, IL, ¹Departments of Neurosurgery, ²Pathology, University of Pittsburgh, 4401 Penn Ave, Pittsburgh, PA, USA

E-mail: *Sandi Lam - slam@surgery.bsd.uchicago.edu; Ramesh Grandhi - grandhir@upmc.edu; Ricky Wong - ricky.wong@uchospitals.edu; Ronald Hamilton - hamiltonrl@upmc.edu; Stephanie Greene - stephanie.greene@chp.edu

*Corresponding author

Received: 01 September 12

Accepted: 07 November 12

Published: 18 January 13

This article may be cited as:

Lam S, Grandhi R, Wong R, Hamilton R, Greene S. Neuromuscular hamartoma of the sciatic nerve: Case report and review of the literature. Surg Neurol Int 2013;4:8.

Available FREE in open access from: <http://www.surgicalneurologyint.com/text.asp?2013/4/1/8/106266>

Copyright: © 2013 Lam S. This is an open-access article distributed under the terms of the Creative Commons Attribution License, which permits unrestricted use, distribution, and reproduction in any medium, provided the original author and source are credited.

Abstract

Background: Neuromuscular hamartomas are rare benign tumors with mature skeletal elements mixed with mature neural elements. They present typically as solitary lesions in childhood and have been reported to be associated with cranial nerves or large peripheral nerves such as the brachial plexus, median nerve, and sciatic nerve. To date, eight cases of sciatic nerve neuromuscular hamartomas have been reported. We present a case along with an outline for the natural history of the disease with a review of the literature of the reported cases dating back to 1895.

Case Description: An 11-year-old boy presented with progressive right lower extremity pain and atrophy. Magnetic resonance imaging revealed a large right sciatic nerve mass, and electromyography demonstrated evidence of ongoing denervation and reinnervation. Initial computed tomography-guided biopsy was unrevealing and subsequent open biopsy was consistent with neuromuscular choristoma.

Conclusion: Neuromuscular choristomas represent a rare disease. Symptoms of foot deformity, leg size discrepancy, and pain merit a complete work-up including spinal and peripheral nerve etiologies.

Key Words: Neuromuscular choristoma, neuromuscular hamartoma, peripheral nerve tumor, sciatic nerve tumor

Access this article online**Website:**www.surgicalneurologyint.com**DOI:**

10.4103/2152-7806.106266

Quick Response Code:**INTRODUCTION**

Neuromuscular hamartomas (also known as neuromuscular choristomas or benign triton tumors) are rare benign tumors with mature skeletal elements mixed with mature neural elements. They typically present as solitary lesions in childhood with no male/female preponderance, and have been reported to be associated with cranial nerves or large peripheral nerves

such as the brachial plexus, median nerve, and sciatic nerve.^[1,2,5,6,8-11,13,14] To date, eight cases of sciatic nerve neuromuscular hamartomas have been reported.^[2,3,7-10,12] This present case represents the ninth. We review the reports of all such cases dating back to 1895, and highlight the clinical presentation, work-up, diagnosis, and management of this rare condition, along with its apparent natural history as seen in the presentation of these cases.

CASE REPORT

History

This 11-year-old boy presented with a 3-year history of right buttock pain that radiated into his lower back and into his right lateral thigh. The pain was present most of the time regardless of activity such as walking or sitting. An initial workup involving magnetic resonance imaging (MRI) of the lumbar spine was unrevealing. The patient had significant atrophy of the right thigh, calf, and foot with an asymmetry in his shoe size with the right foot being three US shoe sizes smaller than the right. In December 2010, the patient presented to neurosurgical attention with progressive complaints of proximal right lower extremity pain, muscle spasms, and gait difficulty.

Examination

The patient's examination revealed a significant asymmetry in size as the measured circumference at the distal thigh was 53.5 cm at the left thigh versus 50.5 cm in the right thigh, 43 cm in the left calf versus 42 cm in the right calf. The length of his foot from the great toe to the heel was 27 cm in the left foot and 24 cm on the right foot. He had normal strength in the left lower extremity. His right lower extremity exhibited 5-/5 strength in the right hip flexor, 4+ in the quadriceps, 4+ in the hamstrings, 4+ in the hip abductor, 4+ in the hip adductor, 5- in the tibialis anterior, 4+ to 5- in the gastrocnemius, 5- in the extensor hallucis longus, 4+ in foot eversion, and 5- in foot inversion. He was unable to perform heel rise or toe rise on his right leg. He had slightly decreased sensation to light touch and pinprick in the posterior and medial portions of his right thigh, lateral aspect of the right leg, lateral right foot, second toe dorsally and fifth toe dorsally. The corresponding toes were noted to have nonpainful dorsal calluses [Figure 1]. The patient had negative straight leg raise bilaterally.

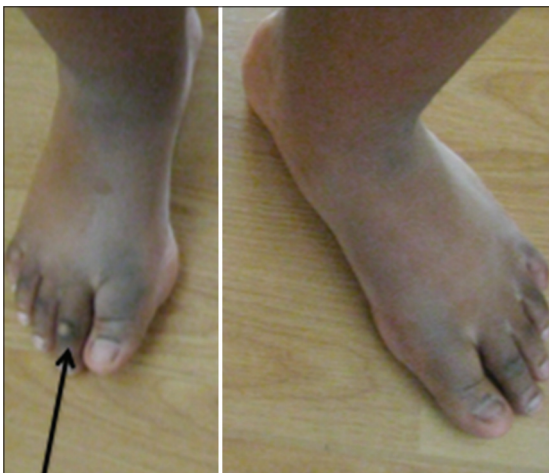

Figure 1: Foot asymmetry is evident, along with dorsal calluses (arrow) on affected left foot

Deep tendon reflexes were rated 2+ throughout except for an absent right ankle jerk reflex. Range of motion was full and symmetric in all lower extremity joints.

In addition, the patient exhibited tenderness to palpation in the infragluteal area in the right hamstring without radiation of pain, along with point tenderness in the region of the right knee lateral to the patella proximal to the head of the fibula. When walking, he complained of posterior thigh pain. The patient had no skin lesions overlying the right posterior thigh or elsewhere on his body, and no stigmata of neurofibromatosis. He had no scoliosis.

MRI studies revealed a lesion at the right sciatic nerve extending 30 cm from the sciatic notch to the distal thigh. The tumor appeared hypointense on T2-weighted images, isointense-to-hypointense signal on the T1-weighted image with mild heterogeneous internal enhancement in a longitudinal orientation after administration of gadolinium contrast [Figure 2]. Associated muscle atrophy in the sciatic nerve distribution was also noted. MRI of the pelvis demonstrated no extension superior to the sciatic notch.

The patient's electromyography (EMG) showed electrodiagnostic evidence of a right sciatic neuropathy with evidence of ongoing denervation and reinnervation as demonstrated by increased insertional activity, positive sharp waves, and fibrillation potentials in the distribution of muscles innervated by the sciatic nerve.

Operation//postoperative course

Given the patient's history and the need for tissue diagnosis to elucidate treatment options, the patient initially underwent an ultrasound-guided biopsy followed by a computed tomography (CT)-guided biopsy of the mass, both of which were unsuccessful at obtaining adequate tissue for histologic diagnosis. The patient underwent an open biopsy through exposure of the sciatic nerve via a posterior gluteus maximus-splitting approach. The whole sciatic nerve appeared involved and

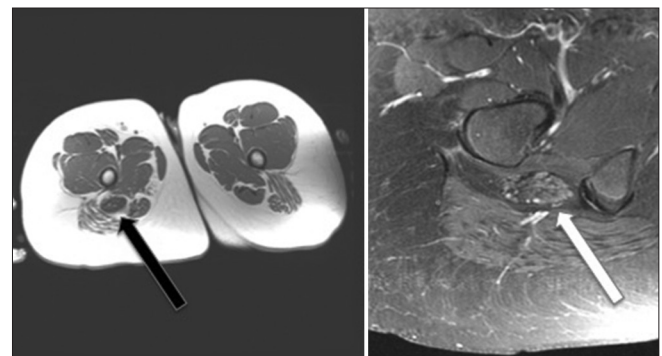


Figure 2: Precontrast (left) and postcontrast (right) axial T1-weighted magnetic resonance images of the lower extremity demonstrate the presence of a well-circumscribed, mildly heterogeneously enhancing mass in the location of the right sciatic nerve (arrows)

was notably hypertrophic, firm, and bulbous [Figure 3]. The epineurium was thick. Neurolysis revealed no visual evidence of intervening nonneural tissue among the large and fibrous fascicles. Two fascicles were selected for biopsy. Postoperatively, the patient had no new neurological deficits, and remained stable by subjective report and by clinical examination.

Pathology

Pathological examination showed the lesion to be a neuromuscular hamartoma (neuromuscular choristoma). Within the specimen, small nerve bundles and axons were seen intermixed with adjacent mature striated skeletal muscle bundles, surrounded by a dense collagenous matrix [Figure 4]. The skeletal muscle was noted to have small, bland, peripherally placed nuclei with mature features and no cellular atypia or atypical mitoses.

The specimens were embedded in paraffin and the sections were stained with hematoxylin and eosin and trichrome. A panel of immunohistochemistry stains was also performed. The S-100 and neurofilament stains showed normal nerve bundles. The Epithelial Membrane Antigen (EMA) stain was inconclusive. Desmin highlighted the hamartomatous striated muscle fibers intermingled with nerve bundles, and myogenin stain was negative for immature skeletal muscular elements.

DISCUSSION

Neuromuscular choristomas reported to date in the literature have involved cranial nerves and large peripheral nerves such as the brachial plexus, median nerve, or sciatic nerve. To our knowledge, this is the ninth reported case of sciatic nerve neuromuscular hamartoma [Table 1]. In extant reports of neuromuscular hamartomas of the sciatic nerve, most patients presented with progressive limb deformity and neurologic deficit. The discrepancy in size of the affected limb versus that of the normal

limb has been noted in five of the nine reported cases including our patient.^[2,3,7-10,12] A cavovarus foot was described in five of the cases as well.^[2,7,9,11,12] While unilateral foot deformity may suggest a spinal etiology such as diastematomyelia or tethered cord, this collection of reports highlights that in rare cases peripheral nerve lesions may produce this clinical sign as well. Most cases of neuromuscular choristoma occur in childhood and typically demonstrate a relatively benign clinical course though the natural history has not been well-understood.

A pattern emerges in the progression of this disease by laying out the cases in terms of age of diagnosis and presentation, describing the natural history in this literature review [Table 1]. In the youngest patient, the diagnosis was made by the presence of a palpable subcutaneous mass at birth. This child was reported to be neurologically normal and without lower extremity deformity. Similarly, the 2-year-old child starting walking at an appropriate age, then developed leg weakness and limp more than half a year later. He did not have a lower extremity deformity on examination. The other patients similarly did not have developmental delay with achieving the milestone of walking, and developed limping later. Cavovarus deformities are reported in the patients aged 4 years and above, as the patients aged 4, 5, 8, 11, and 18 years had this reported deformity. Atrophy and leg size discrepancy was present in all patients aged over 5 years. While the 8-year-old patient and those younger did not have pain symptoms, those who were aged 11 years and older reported progressive leg pain. The two adult patients, aged 42 and 68 years, were reported to have the diagnosis of congenital hip dysplasia as well as progressive lower extremity deformities. Even though the hip dysplasia is labeled as congenital (one of these cases is from 1895), we postulate that long-term progressive deformity to the affected lower extremity may affect the hip in the later stages of the effects of sciatic nerve neuromuscular hamartoma. The pattern seen is that the

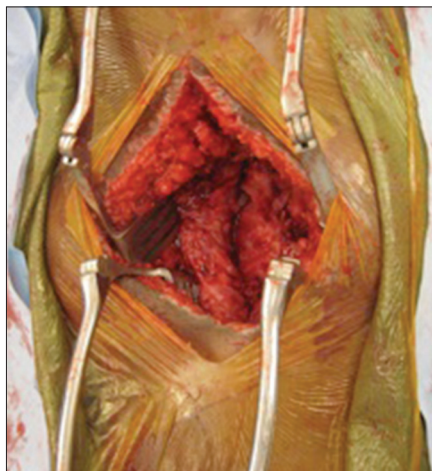


Figure 3: Intraoperative photograph at open biopsy showing the hypertrophic, firm, and bulbous sciatic nerve

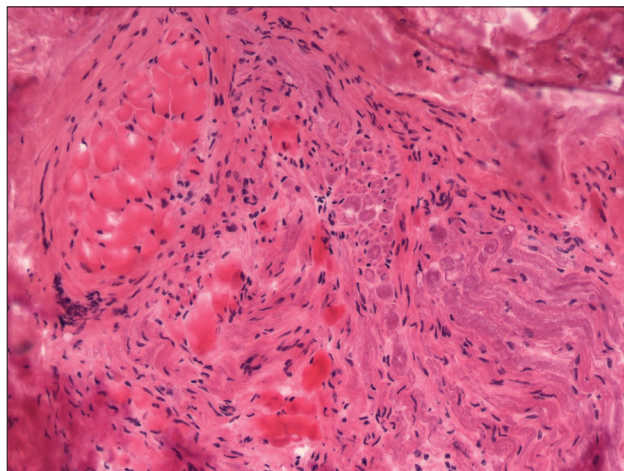


Figure 4: Photomicrograph: Neuromuscular choristoma showing skeletal muscle mixed with nerve fibers (H and E, magnification x200)

Table 1: Summary of cases of sciatic nerve neuromuscular hamartoma in the literature

Case	Age (years)/sex	Presenting symptoms	Intervention	Follow-up	Additional treatment	Ref
1	0/M	Posterior thigh palpable firm subcutaneous lump at birth	Partial resection	3.5 years	None. Normal sensory, motor, and limb development at follow up	[8]
2	2/M	Right sciatic distribution weakness	Partial resection	Lost to follow-up	None	[10]
3	4/F	Left leg cavovarus foot deformity and spasticity	Open biopsy	Not known	Fibrosis found upon resection of enlarging mass at 2 years	[3]
4	5/F	Right sciatic distribution weakness, cavovarus foot	Open biopsy	2.6 years	Fibromatosis at 4 months postbiopsy, 18 months chemotherapy, radical resection of sciatic nerve, recurrence 9 months after resection	[7]
5	8/M	Painless progressive right cavovarus foot deformity, weakness in right leg, smaller right leg, normal sensation. 4 year history of noticeable deformity	Open biopsy	Not known	None	[2]
Present case	11/M	Progressive right leg pain (3 year history) and weakness, hammertoes, small right leg and foot. >3 year history of noticeable deformity	Open biopsy	1.5 years	None	
6	18/M	Progressive 2 year history of pain, weakness and sensory disturbance in right sciatic distribution, right cavovarus foot, hammertoes, shorter right leg and smaller right foot. 7 year history of noticeable deformity	Open biopsy	8.6 years	Fibromatosis at 8 years postbiopsy treated with total resection with sciatic nerve preservation, radiotherapy	[9]
7	42/M	Deterioration of leg function, progressive left leg pain, congenital hip dysplasia	CT-guided biopsy	5 years	Fibromatosis at 3 years postbiopsy managed with observation	[7]
8	68/F	Progressive left cavovarus foot deformity, atrophy in left leg, left sciatic distribution weakness, congenital hip dysplasia	None	None	None. Diagnosis made at autopsy	[12]

clinical course is progressive in nature due to long-term effects on the sciatic nerve.

The MRI findings previously reported are also consistent with the description in our case, in that the lesion tends to appear with low-to-intermediate signal intensity on T1-weighted sequences with mild patchy enhancement and low signal intensity on T2-weighted imaging.^[5,7,9] A retrospective imaging review of cases that subsequently developed aggressive fibromatosis reported a statistically significant difference in the existence of low signal intensity areas, which varied from that of muscle, nerve or the neuromuscular choristoma itself.^[7] These findings suggested the fibromatosis may form near or within these low-intensity areas. Biopsy is generally necessary in order to make a definitive diagnosis of neuromuscular hamartoma.

Neuromuscular hamartomas of any nerve tend to be intercalated or closely associated with the parent nerve, which limits surgical resection options. Microscopically these lesions are usually composed of fascicles separated by fibrous tissue, with the neural tissue intimately associated with the skeletal muscle in nerve fibers or small nerves, and may be sharing the same perimysial sheath.^[11,13] The benefits achieved by total resection of the lesion must be weighed against the potential neurologic deficit from doing so. In our case, resection of the lesion in the absence of uninvolved nerve would

technically necessitate resection and grafting of the sciatic nerve and result in unacceptable neurologic deficit in an ambulatory patient. Such surgical decisions are made on a case-by-case basis. Some authors have described discrete lesions arising from the nerve that were resectable without new neurologic deficit.^[8] Other reports range from biopsy only,^[2,7,9] attempted resection,^[4,10] amputation,^[4,11] while others undertook complete resection of involved nerve with nerve grafting and expected postoperative paralysis of the affected limb.^[1]

The pathogenesis of this tumor is not clearly understood. Various theories proposed include incorporation of limb mesenchyme within the nerve sheaths of developing nerves undergoing peripheral extension, muscle entrapment in developing nerves, neuroectoderm giving rise to metaplastic mesenchymal components, and neural induction on surrounding mesenchyme into skeletal muscle (as in limb regeneration experiments on the Triton salamander).^[1,8-10,13] These lesions are thought to be slow-growing, as supported by the slowly progressive nature of clinical symptoms and low Ki-67 index. These tumors have normal karyotype.^[13] Regression has been reported in 1-3 years in both sciatic nerve and brachial plexus locations,^[8] while proliferation in size and progressive fibromatosis has also been reported,^[7] including a patient who required reoperation in a brachial plexus choristoma 35 years later.^[1]

An association between aggressive fibromatosis and neuromuscular hamartomas may exist.^[7] A total of 10 patients with neuromuscular hamartomas in the cranial nerves, brachial plexus, and sciatic nerves have been documented to develop fibromatosis during follow-up at the site of the hamartoma lesion after biopsy or surgical resection.^[7] It is possible that the trauma of surgery could be related to the pathogenesis of fibromatosis in these lesions. There is, however, a reported case of neuromuscular choristoma that demonstrated aggressive fibromatosis at initial biopsy, which suggests that there are likely to be other contributing factors.^[4] The lack of fibromatosis at initial biopsy in other patients may possibly represent sampling error. Some patients underwent a second surgery at the operative site due to putative recurrence, and in each case a postoperative reactive fibromatosis was found rather than tumor regrowth.^[4,7,11] It has been suggested that given the evolution and addition of MRI characterization drawn from an increasing number of reported cases of neuromuscular hamartoma, biopsy may eventually be avoided in favor of serial imaging and clinical follow-up in order to avoid the development of aggressive fibromatosis.^[11]

As neuromuscular hamartoma cases are rare and the natural history is not fully characterized, long-term serial follow-up is indicated. While unilateral foot deformity or limb size discrepancy necessitates workup for a spinal etiology such as diastematomyelia or tethered cord, these reports of neuromuscular hamartoma show that peripheral nerve lesions may also lead to this clinical picture.

REFERENCES

1. Awasthi D, Kline DG, Beckman EN. Neuromuscular hamartoma (benign "triton" tumor) of the brachial plexus. Case report. *J Neurosurg* 1991;75:795-7.
2. Bassett GS, Monforte-Munoz H, Mitchell WG, Rowland JM. Cavus deformity of the foot secondary to a neuromuscular choristoma (hamartoma) of the sciatic nerve. A case report. *J Bone Joint Surg Am* 1997;79:1398-401.
3. Boman F, Palau C, Floquet A, Floquet J, Lascombes P. [Neuromuscular hamartoma]. *Ann Pathol* 1991;11:36-41.
4. Bonneau R, Brochu P. Neuromuscular choristoma. A clinicopathologic study of two cases. *Am J Surg Pathol* 1983;7:521-8.
5. Castro DE, Raghuram K, Phillips CD. Benign triton tumor of the trigeminal nerve. *AJNR Am J Neuroradiol* 2005;26:967-9.
6. Chen KT. Neuromuscular hamartoma. *J Surg Oncol* 1984;26:158-60.
7. Hebert-Blouin MN, Scheithauer BW, Amrami KK, Durham SR, Spinner RJ. Fibromatosis: A potential sequela of neuromuscular choristoma. *J Neurosurg* 2012;116:399-408.
8. Louhimo I, Rapola J. Intraneural muscular hamartoma: Report of two cases in small children. *J Pediatr Surg* 1972;7:696-9.
9. Maher CO, Spinner RJ, Giannini C, Scheithauer BW, Crum BA. Neuromuscular choristoma of the sciatic nerve. Case report. *J Neurosurg* 2002;96:1123-6.
10. Markel SF, Enzinger FM. Neuromuscular hamartoma—a benign "triton tumor" composed of mature neural and striated muscle elements. *Cancer* 1982;49:140-4.
11. Mitchell A, Scheithauer BW, Ostertag H, Sepehrnia A, Sav A. Neuromuscular choristoma. *Am J Clin Pathol* 1995;103:460-5.
12. Orlandi E. Sopra un caso di rhabdomyoma del nervo ischiatico. *Arch Sci Med* 1895;19:113-37.
13. Van Dorpe J, Sciot R, De Vos R, Uytendaele A, Stas M, Van Damme B. Neuromuscular choristoma (hamartoma) with smooth and striated muscle component: Case report with immunohistochemical and ultrastructural analysis. *Am J Surg Pathol* 1997;21:1090-5.
14. Zwick DL, Livingston K, Clapp L, Kosnik E, Yates A. Intracranial trigeminal nerve rhabdomyoma/choristoma in a child: A case report and discussion of possible histogenesis. *Hum Pathol* 1989;20:390-2.