



Technique for Type IV SLAP Lesion Repair

Burak Altintas, M.D., Rafael Pitta, M.D., Erik M. Fritz, M.D., Brendan Higgins, M.D., and Peter J. Millett, M.D., M.Sc.

Abstract: Type IV SLAP tears involve bucket-handle tears of the superior labrum with the tears extending into the biceps tendon. Surgical treatment options involve either primary repair or biceps tenodesis. Recent literature has shown good clinical outcomes after subpectoral biceps tenodesis for the treatment of type II and IV SLAP lesions. The purpose of this article is to present our technique for arthroscopic superior labrum repair with suture anchors and open subpectoral biceps tenodesis with an interference screw.

Type IV SLAP tears involve bucket-handle tears of the superior labrum with the tears extending into the biceps tendon.¹ Surgical treatment options involve either primary repair or biceps tenodesis. A recent study reported that subpectoral biceps tenodesis for the treatment of type II and IV SLAP lesions is a safe and effective method.² The technique for SLAP repair is frequently performed with the use of suture anchors,³ whereas several techniques for subpectoral tenodesis of the long head of the biceps (LHB) tendon have been described in the literature.⁴ The bone-tunnel technique involves pulling the tendon through 2 holes⁵ or 3 holes⁶ in the proximal humerus, looping distally, and suturing to the muscle. Another technique uses a cortical button, for which 2 holes of different caliber are drilled in the anterior and posterior cortex for the fixation.⁷ An additional technique

for biceps tenodesis, which was recently described, uses suture anchors to fix the biceps tendon to the proximal humerus.⁸ In this article and [Video 1](#), we describe our technique for type IV SLAP repair, which involves using suture anchors for the superior labrum repair along with subpectoral tenodesis of the LHB with an interference screw for stable fixation to facilitate early rehabilitation and improve tendon-to-bone healing.

Surgical Technique

Diagnostic Arthroscopy

The patient is placed in the beach-chair position. After the administration of a regional interscalene block and the induction of general anesthesia, the operative extremity is draped free under sterile conditions with the arm secured in a pneumatic arm holder (Tenet T-Max Beach Chair and Spider arm positioner; Smith & Nephew, Memphis, TN). A standard posterior viewing portal is established, and under direct visualization, an anterosuperior portal is created. Diagnostic arthroscopy is then performed to identify and address any concomitant pathology. During this portion of the procedure, the LHB tendon, superior labrum, rotator cuff, cartilage surfaces, and surrounding structures are evaluated. The LHB tenotomy is performed with an arthroscopic radiofrequency ablation device introduced through the anterosuperior portal. Care is taken to perform the tenotomy directly at the superior labral insertion ([Fig 1](#)). It is important to carefully evaluate the mobilization of the LHB tendon after tenotomy and perform lysis of adhesions to the tendon, if present, to facilitate the distal retrieval of the tendon.

From the Steadman Philippon Research Institute (B.A., R.P., E.M.F., B.H., P.J.M.) and The Steadman Clinic (B.H., P.J.M.), Vail, Colorado, U.S.A.

The authors report the following potential conflict of interest or source of funding: B.A.'s position in the Steadman Philippon Research Institute (SPRI) is supported by Arthrex. E.M.F. and R.P. are employees of the SPRI. SPRI receives funding from Smith & Nephew, Arthrex, Siemens, and Össur. P.J.M. receives consultant's fees and royalties from Arthrex, Medbridge, and Springer Publishing; is a partner of the Steadman Clinic; owns stock and stock options in GameReady and VuMedi; and receives financial support for a part of his research from Arthrex. Full ICMJE author disclosure forms are available for this article online, as [supplementary material](#).

Received September 18, 2017; accepted October 7, 2017.

Address correspondence to Peter J. Millett, M.D., M.Sc., The Steadman Clinic, 181 W Meadow Dr, Ste 400, Vail, CO 81657, U.S.A. E-mail: drmillett@thesteadmanclinic.com

© 2017 by the Arthroscopy Association of North America. Published by Elsevier. This is an open access article under the CC BY-NC-ND license (<http://creativecommons.org/licenses/by-nc-nd/4.0/>).

2212-6287/171163

<https://doi.org/10.1016/j.eats.2017.10.004>

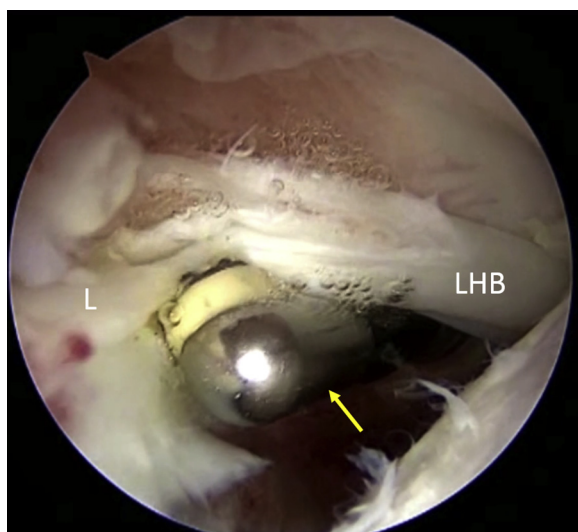


Fig 1. View of the right shoulder through the posterior viewing portal with the patient in the beach-chair position. Through the anterosuperior portal, an arthroscopic radio-frequency ablation device (arrow) is used to tenotomize the long head of the biceps tendon (LHB) directly at the superior labral insertion (L).

Arthroscopic Repair of Superior Labrum

The bucket-handle tear of the superior labrum is excised with a 5.5-mm shaver (Excalibur; Arthrex, Naples, FL) introduced from the anterosuperior portal (Fig 2). Then, the bone under the superior labrum is debrided to create a bleeding bone bed to facilitate healing of the repair while avoiding any additional damage to the superior labrum (Fig 3). Next, a spinal needle is inserted from the lateral aspect through the supraspinatus tendon to create a portal for anchor placement. The rotator cuff is then cut parallel to the fibers with a scalpel, and a 4-mm cannula (Arthrex) is inserted for instrumentation. The shaver is switched to this portal to complete the preparation of the bone bed on the superior glenoid. Subsequently, a drill sleeve for the suture anchor is placed through the lateral portal at the 12-o'clock position 1 to 2 mm onto the face of the superior glenoid (Fig 4). A tunnel is drilled, and the knotless suture anchor (3.0-mm Bio-SutureTak; Arthrex) is placed. The sutures are then loosened from the anchor inserter handle, and the inserter is gently removed with combined rotation and backward traction. Applying firm pressure on the drill sleeve or tapping the drill sleeve gently down to bone with a mallet before drilling is important to avoid skiving of either the sleeve or the drill bit. The blue suture planned as the post limb is retrieved through the anterosuperior portal with a suture grasper. A spinal needle is inserted just medial to the acromion and superior labrum, and a polydioxanone (PDS) suture is used as a suture shuttle around the superior labrum at the level

of the anchor (Fig 5). By use of this technique, the creation of a Neviaser portal through the rotator cuff is avoided because only the spinal needle penetrates the muscle. The PDS suture is retrieved through the anterosuperior portal, and the blue suture of the anchor is then shuttled in a retrograde fashion to create a simple suture configuration such that the post limb of the suture passes through the tissue. The blue suture and the black-and-white suture with the loop in the end are retrieved through the anterosuperior portal (Fig 6). After the blue post-limb suture is loaded through the looped end of the black-and-white passing suture, the other end of the black-and-white suture is pulled through the lateral portal. The knot is tightened to the desired tension and cut flush with the glenoid surface with an arthroscopic suture cutter. The aforementioned sequence is then repeated at the anterosuperior edge of the glenoid, followed by the anterior and—if needed—posterior labrum. However, instead of a PDS suture, a SutureLasso (Arthrex) is used to pass a flexible wire under the labrum to permit the passing of the post limb through the labrum. It is important that, at the end of the procedure, the joint appears well balanced.

Open Subpectoral Biceps Tenodesis

After the conclusion of diagnostic arthroscopy, the arm is positioned in 90° of abduction and 90° of elbow flexion with the volar aspect of the forearm pointed downward and parallel to the floor. This position orients the bicipital groove directly anteriorly. The inferior margin of the pectoralis major tendon and the axillary

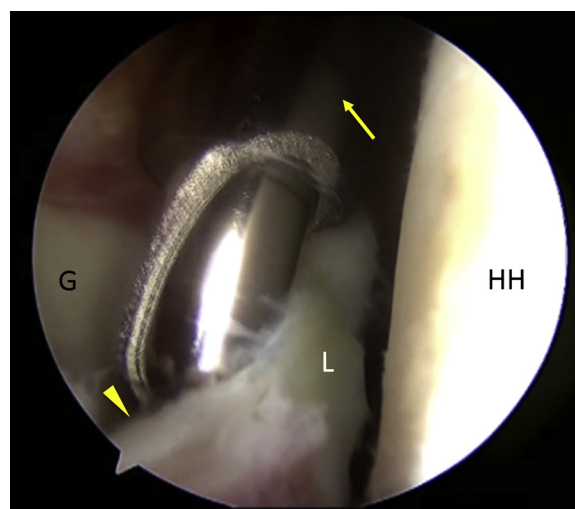


Fig 2. View of the right shoulder through the posterior viewing portal with the patient in the beach-chair position. Through the anterosuperior portal, a 5.5-mm arthroscopic shaver (arrow) is used to excise the bucket-handle tear (arrowhead) of the superior labrum (L). (G, glenoid; HH, humeral head.)

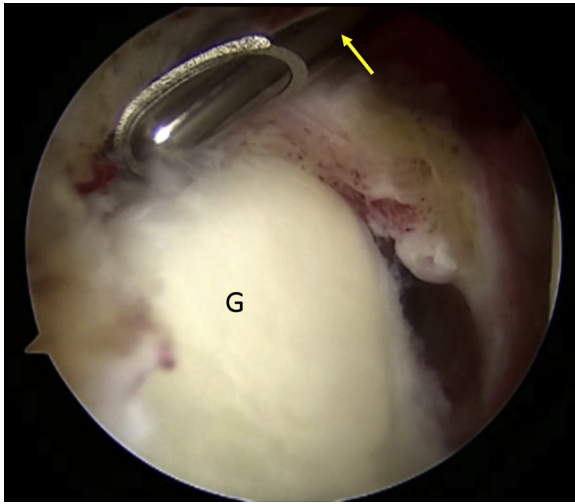


Fig 3. View of the right shoulder through the posterior viewing portal with the patient in the beach-chair position. Through the anterosuperior portal, a 5.5-mm arthroscopic shaver (arrow) is used to debride the bone under the superior labrum. This creates a bleeding bone bed to facilitate healing of the labrum. (G, glenoid.)

crease are palpated and marked with a pen (Fig 7). An incision is made extending from approximately 1 cm superior to 2 cm inferior to the inferior border of the pectoralis major tendon. The pectoralis major tendon and the short head of the biceps are identified. With the pectoralis major tendon retracted superiorly, the fascia overlying the coracobrachialis and short head of the biceps brachii can be visualized and incised within this interval. Blunt dissection then leads directly to the LHB

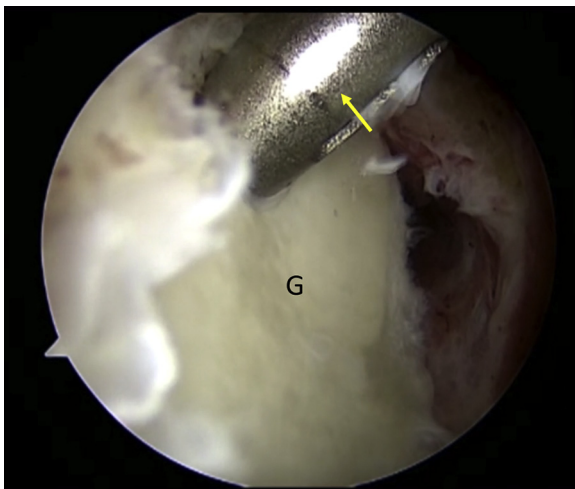


Fig 4. View of the right shoulder through the posterior viewing portal with the patient in the beach-chair position. Through the lateral portal, a drill sleeve (arrow) for the suture anchor is placed at the 12-o'clock position 1 to 2 mm onto the face of the superior glenoid (G). A tunnel is subsequently drilled and the knotless suture anchor placed (not visualized).

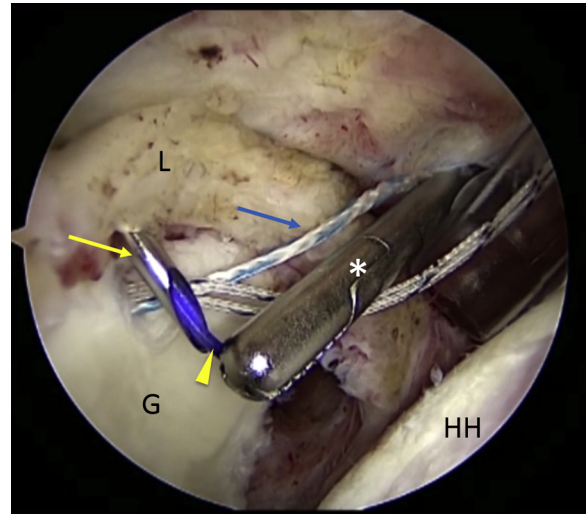


Fig 5. View of the right shoulder through the posterior viewing portal with the patient in the beach-chair position. A spinal needle (yellow arrow) is inserted just medial to the acromion and passed under the labrum (L). A polydioxanone suture (arrowhead) is passed through it, and an arthroscopic grasper (asterisk) is used to retrieve the polydioxanone suture through the anterosuperior portal for subsequent shuttling of the planned post limb (blue arrow). (G, glenoid; HH, humeral head.)

tendon. Forceful medial retraction of the short head of the biceps should be avoided to prevent injury to the musculocutaneous nerve. A right-angle clamp is then used to loop around the LHB tendon and remove it

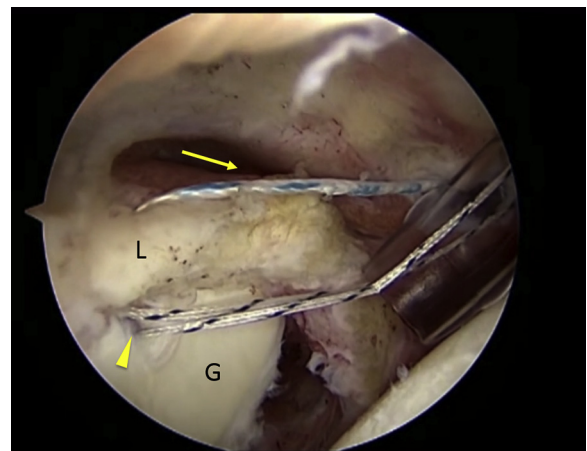


Fig 6. View of the right shoulder through the posterior viewing portal with the patient in the beach-chair position. The blue post limb (arrow) of the suture anchor has been shuttled under the labrum (L) with the polydioxanone suture and retrieved through the anterosuperior portal. Subsequently, the looped end of the black-and-white passing suture is retrieved through the anterosuperior portal and used to pass the blue post limb through the locking mechanism of the suture anchor (arrowhead) and out of the lateral portal. (G, glenoid.)

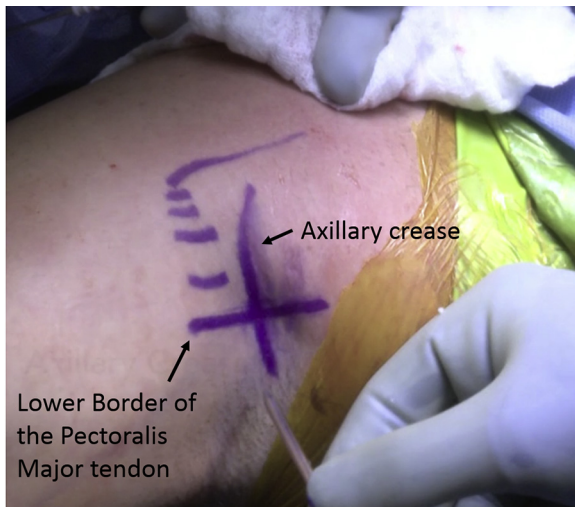


Fig 7. Anterior view of the right shoulder positioned in 90° of abduction with the patient in the beach-chair position before open subpectoral biceps tenodesis. The axillary crease and inferior border of the pectoralis major tendon are drawn with a marking pen.

through the incision (Fig 8). The tendon is whipstitched with No. 2 nonabsorbable high-strength suture (FiberWire; Arthrex) beginning approximately 2 cm proximal to the musculotendinous junction. The excess tendon proximal to the last suture is cut (Fig 9). After this, the soft tissue overlying the bicipital groove is incised longitudinally with electrocautery. The periosteum is stripped off with an elevator to prepare the cortical bed. A 7-mm (female patient) or 8-mm (male patient) reamer is used to create a unicortical bone tunnel. This is created as proximally as possible to make the tunnel more in the metaphyseal portion of the humerus and centrally in the bicipital groove to avoid causing a fracture. By placing one's finger on the medial side of the humerus, excellent precision control of the reamer is achievable. Then, 1 suture limb from the whipstitched tendon is passed through a specially designed driver (Tenodesis Driver; Arthrex), and an appropriately sized PEEK (polyether ether ketone) tenodesis screw (7 × 10 mm or 8 × 12 mm; Arthrex) is placed into the bone and advanced until it is flush with the anterior cortex of the humerus (Fig 10). During the insertion of the screw, it is important to avoid tendon twisting. The remaining suture limb is then tied to the suture limb that passed through the screw to enhance the fixation and prevent tendon slippage. The wound is irrigated and closed in a layered fashion. Pearls and pitfalls of the technique are outlined in Table 1.

Postoperative Rehabilitation

Postoperative rehabilitation depends on concurrent procedures. For isolated subpectoral biceps tenodesis, sling immobilization for 2 weeks with immediate full

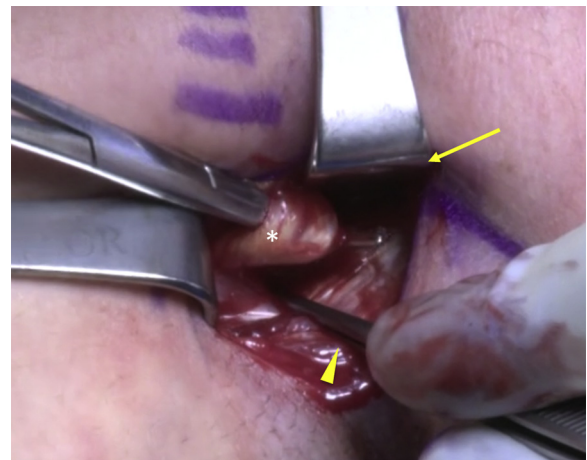


Fig 8. Anterior view of the right shoulder with the patient in the beach-chair position following a subpectoral approach. With the pectoralis major retracted superiorly (arrow) and the short head of the biceps gently retracted medially (arrowhead), the long head of the biceps tendon (asterisk) is exposed with blunt dissection and removed with a right-angle clamp.

active and passive range of motion is allowed. Patients are restricted from performing resisted elbow flexion maneuvers for at least 6 weeks after surgery. Overhead strengthening and heavy lifting are delayed for approximately 3 months.

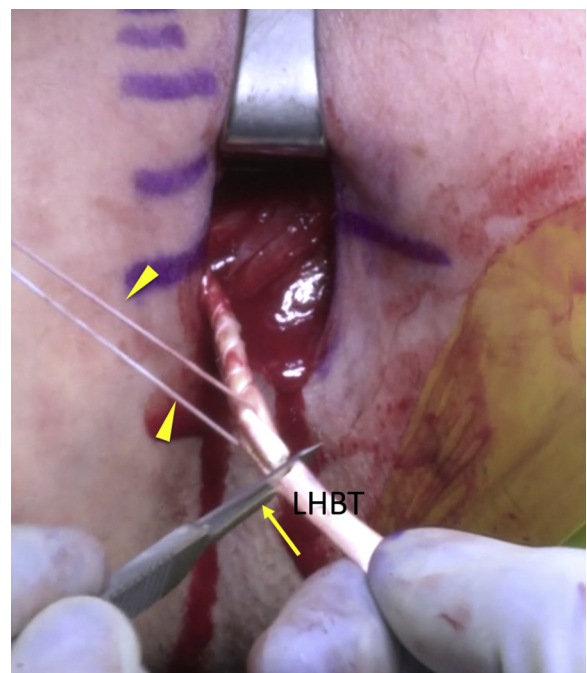


Fig 9. Anterior view of the right shoulder with the patient in the beach-chair position following a subpectoral approach. After the long head of the biceps tendon (LHBT) has been whipstitched using No. 2 nonabsorbable high-strength suture (arrowheads), the excess tendon is cut (arrow).

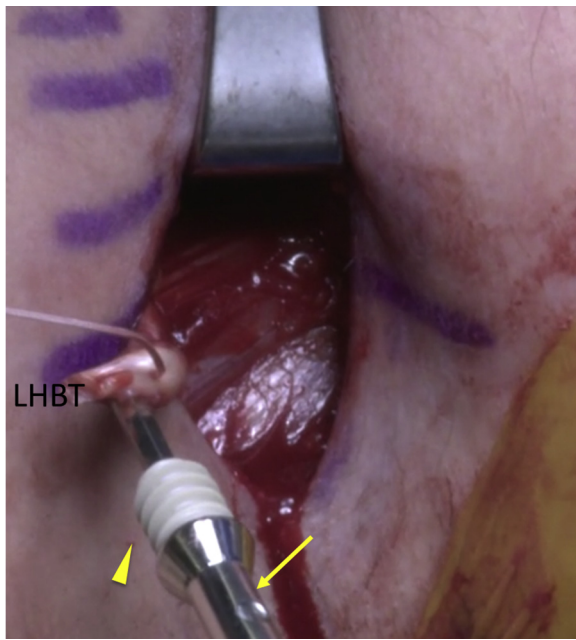


Fig 10. Anterior view of the right shoulder with the patient in the beach-chair position following a subpectoral approach. One suture limb from the whipstitched long head of the biceps tendon (LHBT) is passed through a specially designed driver (arrow) and an 8 × 12-mm PEEK (polyether ether ketone) tenodesis screw (arrowhead).

Discussion

Recent reviews have shown wide variability in the reported surgical techniques for the treatment of SLAP lesions while showing an increasing number of biceps tenodeses and decreasing SLAP repairs.^{3,9} For type IV SLAP lesions, we prefer to perform an arthroscopic labrum repair and a subpectoral biceps tenodesis to maintain glenohumeral stability. Subpectoral biceps tenodesis facilitates pain relief while maintaining biceps muscle strength and cosmesis in addition to preventing cramping.^{6,10} Although various techniques for subpectoral biceps tenodesis have been described, our technique with the interference screw has some biomechanical advantages. Subpectoral interference screw fixation, as used in this technique, showed

comparable strength to bone-tunnel and arthroscopic suture anchor fixation.¹¹ Although the use of a unicortical button for subpectoral biceps tenodesis provides biomechanical properties similar to the use of an interference screw, it puts the axillary nerve at risk.¹² Regarding tendon tensioning, arthroscopic supra-pectoral biceps tenodesis using an interference screw showed the tendency to over-tension the biceps and had a significantly decreased ultimate load to failure compared with an open subpectoral technique in matched cadaveric specimens.¹³

An analysis of 491 patients treated with subpectoral tenodesis with interference screw fixation showed only 12 complications (2.4%).¹⁴ The major complication in this group was a proximal humeral fracture that occurred through the tenodesis site because of a technical error in drill hole placement. A biomechanical study by Euler et al.¹⁵ investigated the optimal screw position by comparing tenodesis screws placed concentrically versus eccentrically relative to the bicipital groove. They showed a significant reduction in humeral strength with eccentric screw positioning. Therefore, it is of utmost importance to drill perpendicularly to the bone and stay centered to avoid a postsurgical humeral shaft fracture.¹⁵ In this study 1 patient needed to undergo revision for a prominent screw. Thus the surgeon must ensure that the screw is flush with the cortex during insertion. Advantages and disadvantages of our technique are outlined in [Table 2](#).

LaFrance et al.¹⁶ recommended the final resting spot of the most distal aspect of the musculotendinous junction of the LHB after tenodesis to be approximately 3 cm distal to the inferior edge of the pectoralis major tendon footprint on the humerus. However, because of the small incision and limited dissection, it is often not possible to visualize the complete musculotendinous junction of the LHB or the pectoralis major tendon footprint. Therefore, we recommend making an intra-operative assessment regarding the tendon tension before drilling for the insertion point.

With the tenodesis insertion 1 cm proximal to the distal border of the pectoralis major tendon, a cadaveric

Table 1. Pearls and Pitfalls

Surgical Step	Pitfalls	Pearls
Open approach	Difficulty identifying the interval between the pectoralis major and biceps	Palpate the inferior border of the pectoralis major and the axillary crease.
Identification of LHB	Iatrogenic injury to the neurovascular structures	Dissect between the pectoralis major laterally and the biceps medially.
Retrieval of LHB distally	Not possible because of proximal adhesions	Carefully perform arthroscopic evaluation and freeing of the intra-articular part of the LHB from any adhesions.
Creation of tendon insertion site in proximal humerus	Fracture	Drill perpendicular to the bone, and stay central to the bicipital sulcus.
Tendon fixation	Tendon twisting	Pay attention to the orientation of the LHB.

LHB, long head of biceps.

Table 2. Advantages and Disadvantages of Technique

Advantages
Good tendon-to-bone healing
Adequate tendon tensioning before fixation
Facilitation of pain reduction with resection of proximal LHB tendon
Disadvantages
Open approach with additional scar
Possibility of iatrogenic injury to neurovascular structures
Risk of fracture of proximal humerus
LHB, long head of biceps.

study confirmed the safety of the procedure using a bicortical method with respect to the neurovascular structures.¹⁷ The short head of the biceps provides a medial border to the musculocutaneous and axillary nerves. This should be kept in mind while dissecting between the short head of the biceps and the pectoralis major.

The fixation with an interference screw has the advantage of facilitating tendon-to-bone healing within the tunnel compared with the surface of the humeral cortex as with a suture button. In summary, the presented technique for subpectoral tenodesis of the LHB with interference screw fixation is a promising and reproducible method with protection of the neurovascular structures.

References

1. Snyder SJ, Karzel RP, Del Pizzo W, Ferkel RD, Friedman MJ. SLAP lesions of the shoulder. *Arthroscopy* 1990;6:274-279.
2. Gottschalk MB, Karas SG, Ghattas TN, Burdette R. Subpectoral biceps tenodesis for the treatment of type II and IV superior labral anterior and posterior lesions. *Am J Sports Med* 2014;42:2128-2135.
3. Kibler WB, Sciascia A. Current practice for the surgical treatment of SLAP lesions: A systematic review. *Arthroscopy* 2016;32:669-683.
4. Voss A, Cerciello S, Yang J, Beitzel K, Cote MP, Mazzocca AD. Open subpectoral tenodesis of the proximal biceps. *Clin Sports Med* 2016;35:137-152.
5. Said HG, Babaqi AA, Mohamadean A, Khater AH, Sobhy MH. Modified subpectoral biceps tenodesis. *Int Orthop* 2014;38:1063-1066.
6. Kane P, Hsaio P, Tucker B, Freedman KB. Open subpectoral biceps tenodesis: Reliable treatment for all biceps tendon pathology. *Orthopedics* 2015;38:37-41.
7. Snir N, Hamula M, Wolfson T, Laible C, Sherman O. Long head of the biceps tenodesis with cortical button technique. *Arthrosc Tech* 2013;2:e95-e97.
8. Su WR, Ling FY, Hong CK, Chang CH, Lin CL, Jou IM. Subpectoral biceps tenodesis: A new technique using an all-suture anchor fixation. *Knee Surg Sports Traumatol Arthrosc* 2014;23:596-599.
9. Erickson BJ, Jain A, Abrams GD, et al. SLAP lesions: Trends in treatment. *Arthroscopy* 2015;32:976-981.
10. Mazzocca AD, Rios CG, Romeo AA, Arciero RA. Subpectoral biceps tenodesis with interference screw fixation. *Arthroscopy* 2005;21:896.
11. Mazzocca AD, Bicos J, Santangelo S, Romeo AA, Arciero RA. The biomechanical evaluation of four fixation techniques for proximal biceps tenodesis. *Arthroscopy* 2005;21:1296-1306.
12. Arora AS, Singh A, Koonce RC. Biomechanical evaluation of a unicortical button versus interference screw for subpectoral biceps tenodesis. *Arthroscopy* 2013;29:638-644.
13. Werner BC, Lyons ML, Evans CL, et al. Arthroscopic suprapectoral and open subpectoral biceps tenodesis: A comparison of restoration of length-tension and mechanical strength between techniques. *Arthroscopy* 2015;31:620-627.
14. Millett PJ, Rios D, Martetschläger F, Horan MP. Complications following subpectoral biceps tenodesis with interference screw fixation. *Obere Extremität* 2014;9:276-279.
15. Euler SA, Smith SD, Williams BT, Dornan GJ, Millett PJ, Wijdicks CA. Biomechanical analysis of subpectoral biceps tenodesis. *Am J Sports Med* 2015;43:69-74.
16. LaFrance R, Madsen W, Yaseen Z, Giordano B, Maloney M, Voloshin I. Relevant anatomic landmarks and measurements for biceps tenodesis. *Am J Sports Med* 2013;41:1395-1399.
17. Sethi PM, Vadasdi K, Greene RT, Vitale MA, Duong M, Miller SR. Safety of open suprapectoral and subpectoral biceps tenodesis: An anatomic assessment of risk for neurologic injury. *J Shoulder Elbow Surg* 2015;24:138-142.