

# Aesthetic Units and Zones of Adherence, Relevance to Planning Incisions in Body Contouring Surgery

Laurence Kirwan, MD, FRCS

**Background:** Aesthetic units (AUs) and zones of adherence (ZAs) have been previously noted in the face and torso. A systematic classification of common AUs and ZAs has not been previously described for the torso and extremities. Contour and scars are equally important in obtaining the best result. Therefore, the six principles to consider in body contouring surgery (BCS) are that the resulting scar be anchored at a zone of adhesion; at the interface of AUs; concealed within flexion or extension skin creases, or placed according to conventional usage and experience; positioned on the medial aspect of a limb; hidden when nude, topless, or in a variety of clothing such as one-piece and two-piece swimsuits, crop tops, short sleeves, etc; and positioned to avoid a contracture across a flexion joint crease or a dehiscence across the extension aspect of a joint.

**Methods:** Images of male and female massive weight loss (MWL) patients with a history of MWL were reviewed and analyzed.

**Results:** AUs and ZAs are described and codified. An algorithm is provided to aid in planning incisions for BCS.

**Conclusion:** With the increase in BCS after MWL, a classification of AUs and ZAs is considered useful in planning surgery and optimizing the aesthetic result. (*Plast Reconstr Surg Glob Open* 2023; 11:e5093; doi: [10.1097/GOX.0000000000005093](https://doi.org/10.1097/GOX.0000000000005093); Published online 23 June 2023.)

## INTRODUCTION

In a letter to Robert Hooke in 1675, Isaac Newton made his most famous statement: “If I have seen further, it is by standing on the shoulders of Giants.” This statement is now often used to symbolize scientific progress and to give credit to those who have laid the foundations of our cognitive and practical skills. I would like to acknowledge the immeasurable knowledge and good sense that was handed down to me by Frederick McCoy, my program director and mentor at the University of Missouri Kansas City, without whom this article would probably not have seen the light of day.

Excluding fetal surgery,<sup>1</sup> a surgical incision results in a scar. The ideal scar is an invisible one. For a plastic surgeon, the choice of incision from the very first cut (direction and location) is not only the first step on a journey but akin to firing a cannonball. Once the ordinance leaves the barrel, trajectory and destination are, for all practical purposes, irrevocable and unchangeable.

Similarly, a “good incision” often predicts a successful outcome, and a bad one, the opposite. Frederick McCoy would say, “if you aim for less than perfection you will hit it every time.”<sup>2</sup> This article is an attempt to provide a trajectory for that aim, in creating an atlas of aesthetic surgery for the human body.

Burget and Menick<sup>3</sup> previously described aesthetic sub-units of the nose. It is interesting that the alar sill, while not noted as such, is also a zone of adherence (ZA). Figure 4, Chapter 1<sup>4</sup> shows the consequences of “patching holes,” and the result of ignoring aesthetic units (AUs). Gonzalez-Ulloa et al<sup>5</sup> and Millard<sup>6</sup> have also discussed the head and neck in terms of AUs. The body may also be divided into AUs<sup>7-14</sup> and ZAs<sup>15</sup> (Tables 1–4). It is important to note that even in cases of massive obesity, the skin does not simply hang like a “onesie” garment (Fig. 1) but is tethered by these ZAs.<sup>15</sup>

Choosing the ideal incision, particularly in body contouring surgery (BCS) and indeed, for all aesthetic and reconstructive procedures, is a choice between the good, the bad, and the ugly. This article is limited to below the clavicle and also excludes hands and feet. This does not

From *Kirwan Plastic Surgery, Norwalk, Conn.*

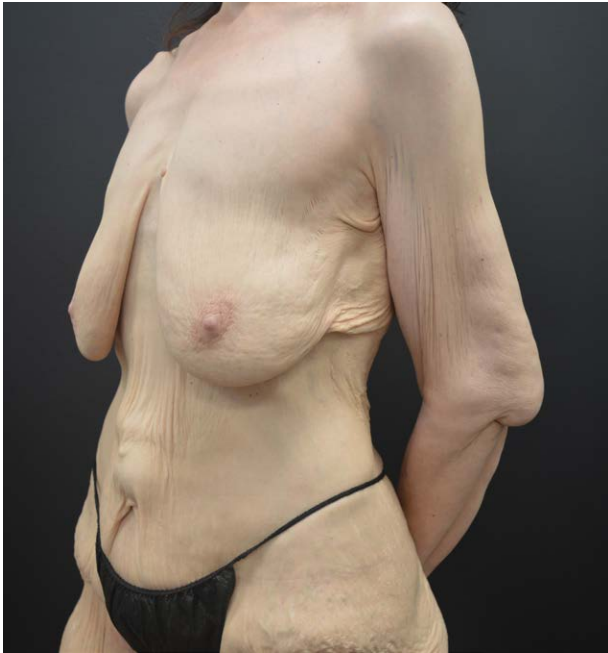Received for publication March 15, 2023; accepted May 5, 2023.

Copyright © 2023 The Authors. Published by Wolters Kluwer Health, Inc. on behalf of The American Society of Plastic Surgeons. This is an open-access article distributed under the terms of the [Creative Commons Attribution-Non Commercial-No Derivatives License 4.0 \(CCBY-NC-ND\)](https://creativecommons.org/licenses/by-nc-nd/4.0/), where it is permissible to download and share the work provided it is properly cited. The work cannot be changed in any way or used commercially without permission from the journal.

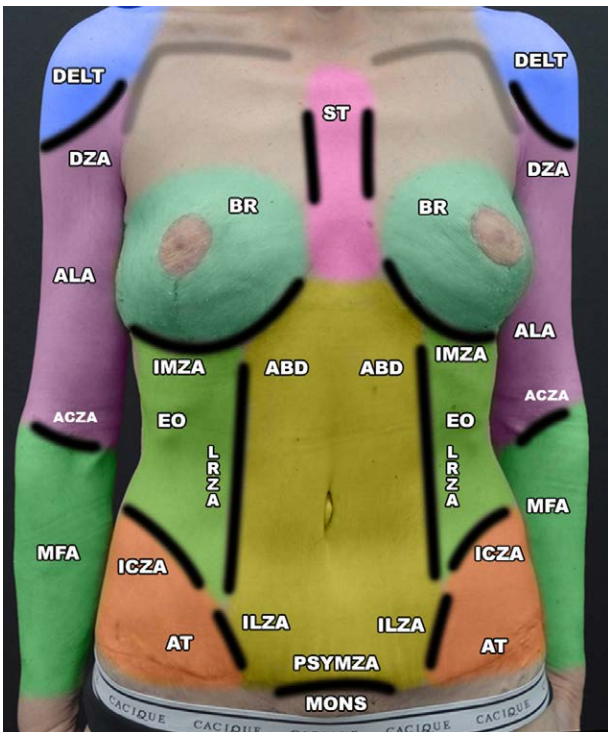
DOI: [10.1097/GOX.0000000000005093](https://doi.org/10.1097/GOX.0000000000005093)

Disclosure statements are at the end of this article, following the correspondence information.

Related Digital Media are available in the full-text version of the article on [www.PRSGlobalOpen.com](http://www.PRSGlobalOpen.com).



**Fig. 1.** A 56-year-old woman after 200-pound weight loss, oblique view.



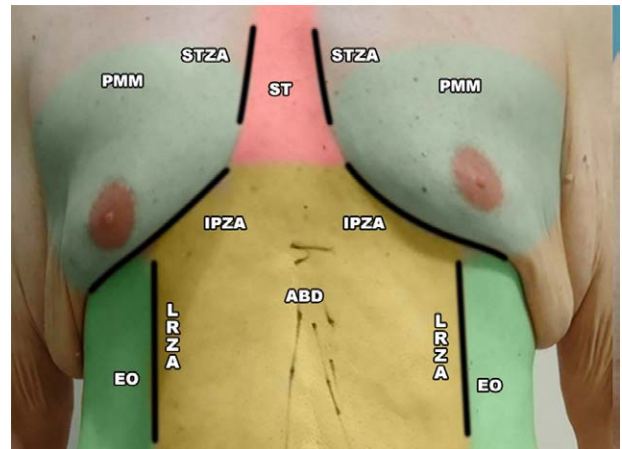
**Fig. 2.** AU distribution. Female, anterior torso and arm after LBL, brachioplasty, and mastopexy with curvilinear lateral chest extension. ACZA indicates antecubital FC ZA; BR, breast AU; DELT, deltoid muscle AU; DZA, deltoid insertion ZA; ICZA, iliac crest ZA; ILZA, iliac crest ZA; IMZA, inframammary fold ZA; LRZA, lateral rectus ZA; MFA, medial (ventral) forearm AU; MONS, mons pubis AU; PSYMZA, pubic symphysis ZA; ST, sternum AU.

### Takeaways

**Question:** The key problem is optimizing scar locations and preserving aesthetic units when performing body contouring surgery in patients after massive weight loss.

**Findings:** Aesthetic units, zones of adherence, and the medial aspect of the thigh or arm are used to guide incisions for body contouring surgery and provide patients with the optimal result.

**Meaning:** Planning body contouring surgery based on aesthetic units and zones of adhesion is a practical approach to optimize results.

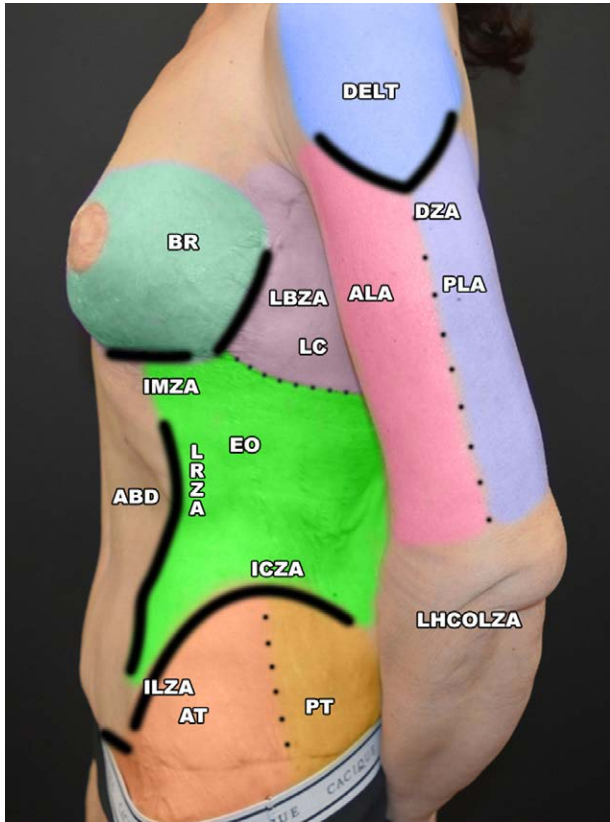


**Fig. 3.** AU distribution. Male, upper anterior torso after MWL. IPZA indicates caudal edge of PMM ZA; LRZA, lateral rectus ZA; STZA, sternum ZA.

imply that these anatomical regions are irrelevant, but for the purpose of this article that focuses on BCS, these anatomical parts are omitted.

“The superficial fascial system (SFS) produces many of the topographical landmarks of body-surface anatomy. The creases, plateaus, valleys, and bulges of our bodies are explained by the anatomy of the SFS and its relationships to skin, fat, and the musculoskeletal system. Understanding the anatomy and age-related pathologic changes of the SFS of the trunk and extremities may help explain body contour deformities and provide the [aesthetic] basis for surgical correction.”<sup>15</sup>

An AU may be determined in shape by an underlying muscle or group of muscles, such as the pectoralis major, rectus abdominis, or anterior leg compartment muscles, or may simply be the anterior or posterior anatomical aspect, such as the anterior and posterior thigh. AUs are bordered by other AUs. ZAs occur at the boundary of an AU but the converse does not apply. AUs are aesthetic building blocks and are applicable to all patients, nonobese, obese, and massive weight loss (MWL) patients alike (Tables 1–3). In this article, there is no attempt to



**Fig. 4.** AU distribution. Female, lateral torso and arm, after MWL, pre-operative. ABD indicates rectus abdominus muscle AU; BR, breast AU; DELT, deltoid muscle AU; DZA, deltoid insertion/lateral arm ZA; ICZA, lateral chest AU; ILZA, inguinal ligament ZA; IMZA, inframammary fold ZA; LBZA, lateral breast ZA; LC, lateral chest AU; LHZOLZA, lateral humeral condyle to olecranon ZA; LRZA, lateral rectus ZA.

**Table 1. AUs of the Upper Extremity**

AU	Description
DELT	Deltoid muscle
ALA	Anterior lateral arm
PLA	Posterior lateral arm
MFA	Medial (ventral) forearm
LFA	Lateral forearm

DELT, deltoid; LFA, lateral forearm; MFA, medial forearm.

**Table 2. AUs of the Anterior, Lateral, and Posterior Torso**

AU	Description
ST	Sternum
PMM	Pectoralis major muscle
BR	Breast
LC	Lateral chest
ABD	Rectus abdominis muscles
EO	External oblique muscle
MONS	Mons pubis
SC	Scapula
RH	Rhomboid muscles
PS	Paraspinal muscles
BUTT	Buttock
PER	Perineum

ABD, abdomen; BR, breast; BUTT, buttock; LC, lateral chest; PER, perineum; PS, paraspinal; SC, scapular.

**Table 3. AUs of the Lower Extremity**

AU	Description
PT	Posterior thigh
AT	Anterior thigh
PAT	Patellar
ML	Midline anterior leg: (anterior crest of tibia and medial subcutaneous surface)
LL	Lateral leg (overlying anterior compartment)
CF	Calf: medial and lateral gastrocnemius muscles
AK	Ankle: inferior to bellies of gastrocnemius muscles/ attachments to Achilles tendon

AK, ankle; BUTT, buttock; CF, calf (medial and lateral gastrocnemius); KN, knee; ML, medial leg; MT, medial thigh.

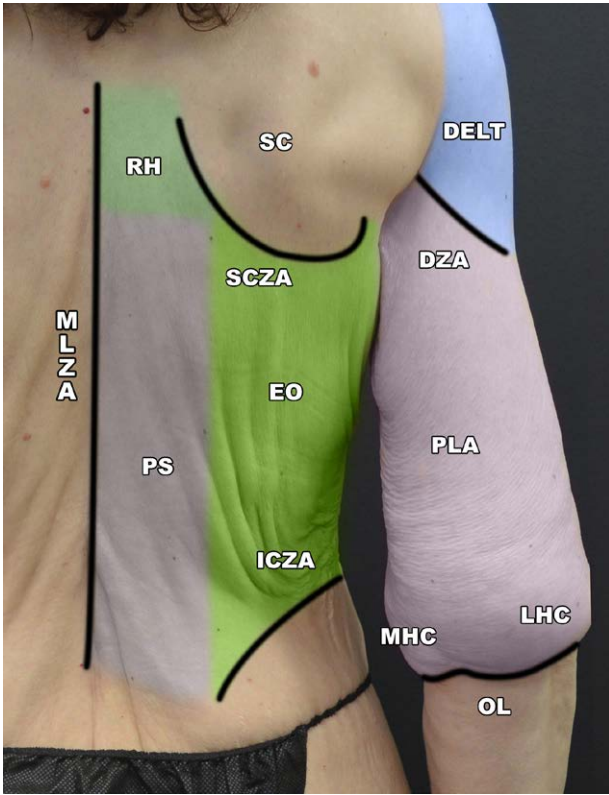
**Table 4. ZAs**

ZA	Anatomy
Upper extremity	
AX	Axilla
D	Deltoid insertion/lateral arm
BG	Bicipital groove
MHC-OL	Medial humeral condyle to olecranon
LHC-OL	Lateral humeral condyle to olecranon
AC	Antecubital FC
UL	Subcutaneous border of ulna
Anterior torso	
ST	Sternum
IM	Inframammary fold
IP	Caudal edge of PMM
LB	Lateral breast
LR	Lateral rectus
IC	Iliac crest
IL	Inguinal ligament
PSYM	Pubic symphysis
Posterior torso	
SC	Scapula
MLT	Midline torso spinous processes
GC	Gluteal crease
IPR	Ischio-pubic ramus
Lower extremity	
GT	Ilio-tibial tract/ greater trochanter
MT	Medial thigh (mid-medial thigh)
SP	Suprapatellar
PF	Popliteal fossa
IKN	Inferior knee (medial)
ML	Midline anterior leg (anterior crest of tibia and medial subcutaneous surface)
LL	Lateral leg: origin of peroneal muscles (lateral border of fibula).
GA	Gastrocnemius: caudal termination of medial and lateral bellies at Achilles tendon transition

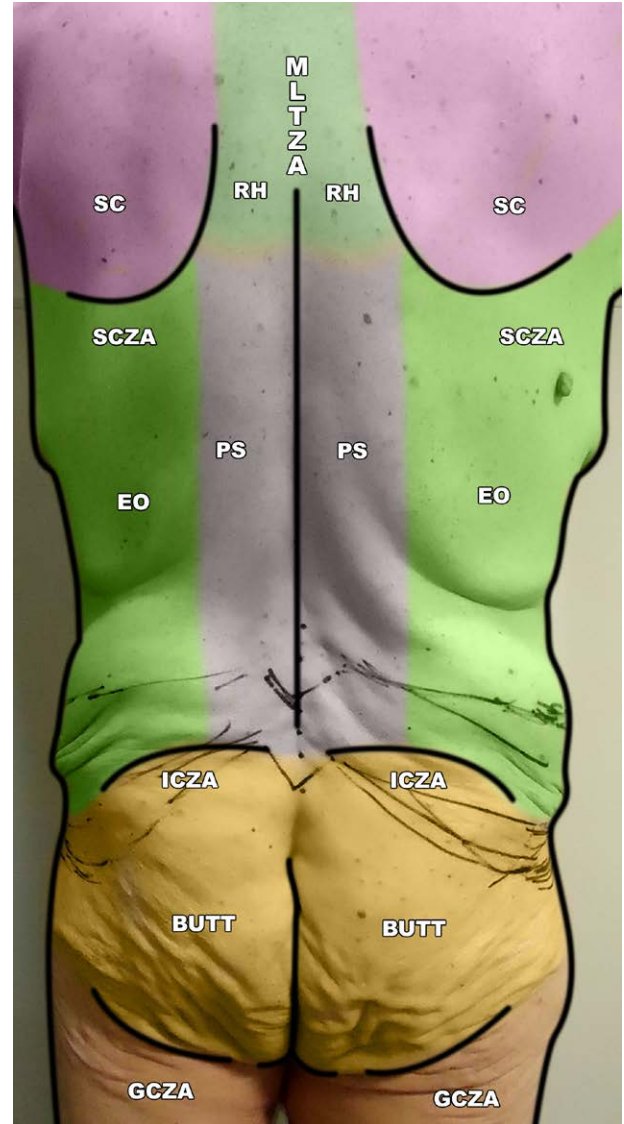
AX, axilla; BG, bicipital groove; DEL, deltoid; GA, gastrocnemius; GC, gluteal crease; GT, greater trochanter; IC, iliac crest; IL, inguinal ligament; IPR, ischio-pubic ramus; IKN, inferior-knee; LB, lateral breast; LHC, lateral humeral condyle; LL, lateral leg; LR, lateral rectus; MHC, medial humeral condyle; ML, midline leg; MLT, midline torso; MT, medial thigh; OL, olecranon; PF, popliteal fossa; PSYM, pubic symphysis; SC, scapular; SP, suprapatellar; ST, sternum.

subdivide AUs as proposed in liposculpture.<sup>16-20</sup> Breast subunits have also been previously described and are not further discussed.<sup>7-12</sup>





**Fig. 5.** AU distribution. Female, posterior torso, preoperative. DELT indicates deltoid muscle AU; DZA, deltoid insertion ZA; ICZA, iliac crest ZA; LHC, lateral humeral condyle; MLZA, midline torso spinous processes ZA; OL, olecranon; PLA, posterior lateral arm; PS, paraspinal muscles AU; SC, scapula AU; SCZA, scapula ZA.



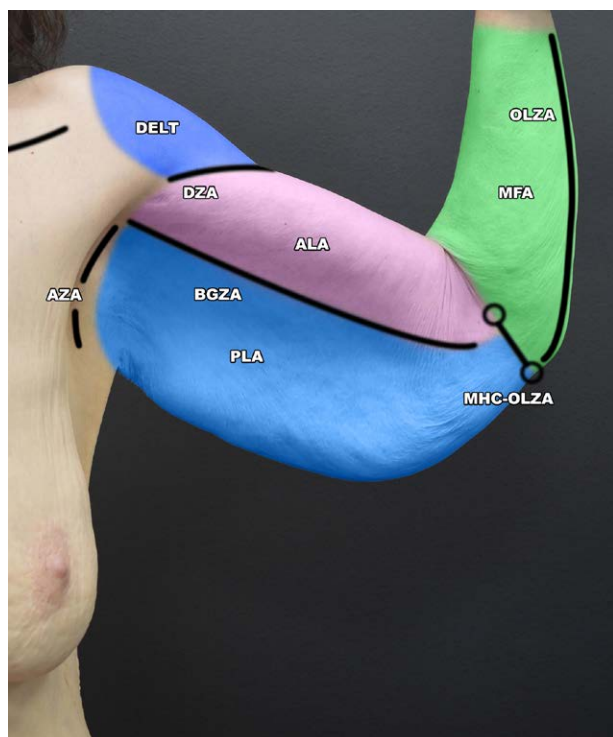
**Fig. 6.** AU distribution. Male, posterior torso, preoperative. BUTT indicates buttock AU; EO, external oblique muscle AU; GCZA, gluteal crease ZA; ICZA, iliac crest ZA; MLTZA, midline torso ZA; PS, paraspinal muscles AU; RH, rhomboid muscles AU; SC, scapula AU; SCZA, scapula ZA.

Five terms discussed in this article are defined as follows:

- A. Aesthetic unit, (AU) (Tables 1–3): marked as solid blocks of color (Figs. 2–10). A specific AU of the body is characterized by one of the following:
  1. An underlying muscle or group of muscles such as the external oblique (EO), pectoralis major, deltoid, and/or the muscle group of the anterior compartment of the leg.
  2. An AU such as the breast, mons pubis, or ankle
  3. A specific anatomical aspect such as anterior or posterior, for example, anterior thigh (AT) and posterior thigh (PT) and anterolateral (ALA) and posterolateral arm (PLA).
- B. Zone of adherence (ZA) (Table 4): marked as solid black lines (Figs. 2–10). The attachment of the SFS to the deep fascia or periosteum.<sup>15</sup> A ZA occurs at the boundary or interface of an AU (AUI) such as the junction of the hypogastrium and the inguinal ligament (the exception being the medial thigh ZA that occurs at the medial interface of the AT and PT AUs) but the opposite does not apply, in that an AUI is not always associated with a ZA (Figs. 5–9).<sup>15</sup>
- C. AU interface (AUI): the abutment of one or more AUs. This may coincide with a ZA (solid black line)

or may be a “soft” interface (dotted black line) with no ZA, such as the lateral AUI between ALA and PLA (Figs. 4, 8), lateral AUI between MFA and LFA, medial and lateral AUIs between the AT and PT, and the AUI between the rhomboid (RH) and paraspinal (PS) AUs (not illustrated in Figs. 5 and 6.) (Tables 1, 3).

- D. Extension crease (EC): It is a crease caused by muscle movement or skin redundancy in proximity to a ZA, but not by a ZA specifically, for example, the curvilinear flank line between the scapula (SC), RH, PS and EO AUs (Figs. 5, 6).
- E. Flexion crease (FC): It is a crease caused by muscle movement, or skin redundancy in proximity to a ZA, but not by a ZA specifically. Examples are the



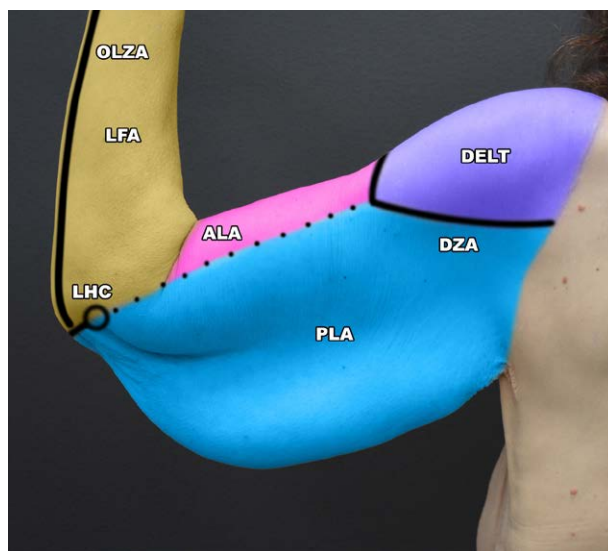
**Fig. 7.** AU distribution. Female left upper extremity anterior, preoperative. ALA indicates anterior lateral arm; AZA, axillary ZA; BGZA, bicipital groove ZA; DELT, deltoid muscle AU; DZA, deltoid insertion ZA; MFA, medial (ventral) forearm AU; MHC-OLZA, medial humeral condyle-olecranon ZA; PLA, posterior lateral arm; RH, rhomboid AU.

horizontal folds in the neck, anterior abdominal wall, and the oblique lines of the lateral inferior boundary of the décolletage where the medial superior breast abuts the sternal ZA (Table 2). FCs have been previously described.<sup>21–26</sup>

Depending on the procedure performed, the principles for optimal planning of a scar for BCS are that the incision satisfies one or more of the following six criteria, which may apply with different emphases (Table 5); (See Video [online], which displays the body contouring AUs and zones.)

Ideal scars should, therefore, be:

1. Anchored at a ZA.
2. At an AUI, but not transgressing an AUI.
3. Concealed within an FC or EC.
4. Positioned on the medial aspect of a limb.
5. Hidden when nude, topless, or in a variety of clothing such as one-piece or two-piece swimsuit, crop top, short-sleeved and sleeveless tops, Yoga pants, etc.
6. Positioned so as to avoid a contracture across a joint concavity or FC or a dehiscence across the extensor aspect of a joint. Examples of the former are incisions, which extend along the medial aspect of the knee and elbow when extending a vertical thigh lift and brachioplasty, respectively, and zig-zag incisions at the apex of the axilla with a brachioplasty



**Fig. 8.** AU distribution. Female left upper extremity posterior, preoperative. ALA indicates anterior lateral arm AU; DELT, deltoid muscle AU; DZA, deltoid insertion ZA; LFA, lateral forearm AU; LHC, lateral humeral condyle; OLZA, olecranon ZA; PLA, posterior lateral arm.

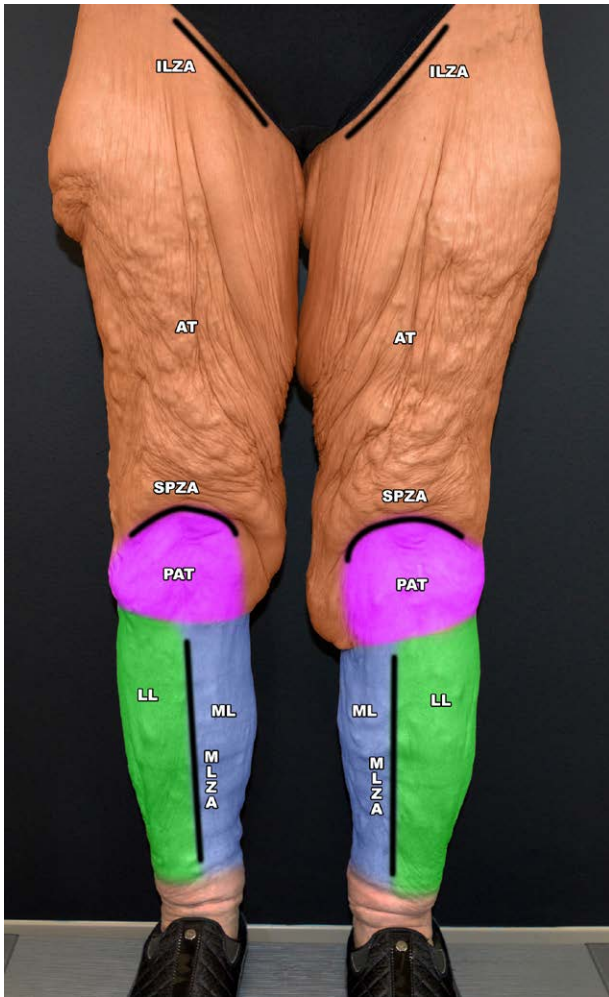
extending onto the lateral chest. Examples of the latter are curvilinear incisions in the EC between the SC, RH, PS and EO AUs.

## METHODS

This study is based on multiple patients in the United States and the United Kingdom who have presented for BCS during the author's 35 years in practice. This article draws on the application of solid plastic surgery principles during this time. As Frederick McCoy would have said, many of the observations are "measured scientifically by eye." Methods and results are limited by an analysis of three patients (two females and one male). There will obviously be variations between patients in the same way that there are anatomical variations of internal anatomy. Nonetheless, there is overall consistency, as evidenced by Lockwood's study of 12 fresh cadaver segments and 20 body-contour patients.<sup>15</sup>

Preoperative and postoperative male and female, anterior, posterior, and lateral views of the torso and upper and lower extremities were studied after MWL. AUs were identified that demarcated specific parts of the torso and extremities. AUs were defined as above. ZAs always demarcated boundaries of AUs but not vice versa (see above). No attempt was made to subdivide AUs further, as this was not felt to be relevant to planning BCS (Figs. 2–10). In the figures presented, AUs are filled with single blocks of color, and ZAs are identified as solid black lines. "Soft" AUs without a ZA are identified as dotted black lines. AUs are labeled by their abbreviations, without any additional suffix, whereas ZAs are labeled with their abbreviations plus the additional ZA suffix, to avoid confusion with AUs. AUIs are not labeled.





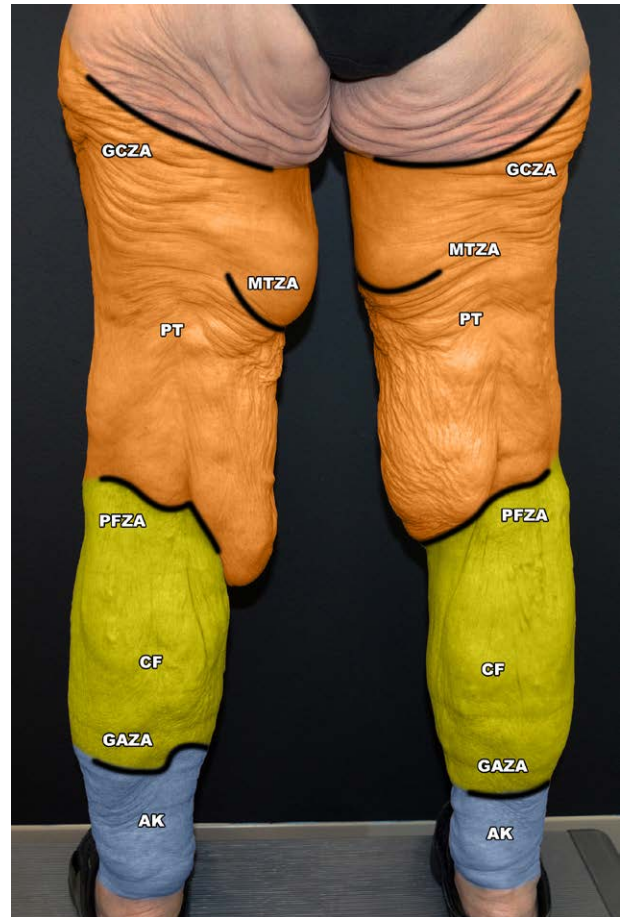
**Fig. 9.** AU distribution. Female lower extremity anterior, preoperative. AT indicates anterior thigh AU; ILZA, inguinal ligament ZA; LL, lateral leg AU; ML, midline anterior leg AU; MLZA, midline anterior leg ZA; PAT, patellar AU; SPZA, suprapatellar ZA.

AUs (Tables 1–3) and ZAs (Table 4) are tabulated and illustrated (Figs. 2–10).

### CASE EXAMPLES

#### Patient 1

Our patient is a 56-year-old White woman with the height of 5' 3" and maximum weight of 154kg. Her current weight is 73 kg and body mass index is 28kg/m<sup>2</sup> with history of self-induced weight loss of 81 kg over a period of 24 months and stable weight for 6 months. The patient lost a further 15 kg after consultation and before initial surgery. The patient was self-referred. She has no significant medical history. She is a nonsmoker and social drinker. In-patient surgery was performed at Greenwich Hospital, Greenwich, Connecticut. Preoperative view and postoperative views are shown 4.5 months after lower body lift (LBL) and 1 month after an extended brachioplasty contiguous with a mastopexy-breast autoaugmentation<sup>27–29</sup> (Figs. 11, 12).



**Fig. 10.** AU distribution. Female, lower extremity posterior, preoperative. AK indicates ankle AU; CF, calf AU; GAZA, gastrocnemius ZA; GCZA, gluteal crease ZA; MTZA, medial thigh ZA; PFZA, popliteal fossa ZA; PT, posterior thigh AU.

#### Patient 2

Our patient is a 34-year-old White woman with the height of 5' 6" and weight of 58 kg. Her body mass index is 20.7kg/m<sup>2</sup> with a history of self-induced weight loss of 77 kg and stable weight for an undetermined period. Patient was self-referred. She has no significant medical or surgical history. She is a nonsmoker and nondrinker. In-patient surgery was performed at the Princess Grace Hospital in London, United Kingdom. Preoperative view and postoperative views are shown 3 months after extended abdominoplasty and 1 month after breast lift and breast autoaugmentation<sup>27–29</sup> with an upper body lift (UBL) (Figs. 13, 14).

### RESULTS

AUs, ZAs, AUIs, ECs, and FCs are identical between men and women, except for the female curvilinear inframammary fold ZA, infra-pectoral ZA with the most caudal point at the breast meridian versus the male IPZA, which has an oblique medial-inferior to latero-superior direction.

**Table 5. Body Contouring Procedures: Choice of Scar Incisions, Based on Procedure and Clothing Considerations**

Surgical Site	Procedure	Scar Direction/Location	Visibility Considerations	Clothing Suggestions
Upper arm	Proximal brachioplasty	Transverse in axilla or with short “T” shaped extension along bicipital groove	Axilla and upper medial arm	Top with sleeves Sleeveless outfit Bikini top
Arm	Brachioplasty	Longitudinal with “V” break in axilla	Medial side of arm	Sleeveless or sleeved top
Arm and lateral chest	Extended brachioplasty	Vertical or curvilinear into IMF	Medial side of arm and lateral chest	Sleeveless or sleeved top
Elbow	Extended brachioplasty	Medial side of elbow	Medial side of elbow	Sleeveless or sleeved top
Lateral chest	Extended brachioplasty	Vertical	Beneath bra/crop top	Crop top
	Flank lift	Curvilinear: concave superiorly		Backless dress or one-piece swimsuit
Back	UBL	Horizontal	Beneath bra/crop top	Crop top
			Beneath T-shirt	Avoid backless dress
			Avoid extension to posterior midline	
Anterior chest (male)	Gynecomastia excision	Transverse at inferior border of PMM	Shirtless	Tight T-shirt
			Avoid extension to anterior midline if possible	“Muscle” tank top
Breast (female)	Mastopexy	Wise pattern mastopexy	Avoid extension to midline if possible	Sports bra
	Autoaugmentation	Lateral chest extension (horizontal)	May extend horizontally: (1) with or without flank-lift; (2) in a curvilinear fashion into the apex of the axilla, with or without a brachioplasty; and (3) with or without UBL	Crop top
		Lateral chest extension (curvilinear)		
Abdomen (female)	Abdominoplasty	Horizontal or high lateral	Beneath swimsuit	Thong
	Extended abdominoplasty			Two-piece
	LBL			One-piece
Abdomen (male)	Abdominoplasty	Horizontal	Beneath waistline of swim short	Swim shorts, that is, trainer type or full thigh
	Extended abdominoplasty			
	LBL			
Back (female)	LBL	Curvilinear-superior edge of buttock	Beneath swimsuit	Two-piece swimsuit
				One-piece swimsuit
Back (male)	LBL	Low posterior in men	Beneath swimsuit	Swim shorts
				Gym shorts
Thigh (proximal)	Upper MTL	Perineum/medial thigh junction	Perineal/thigh crease	Two-piece
	Anchor lift		Risk of caudal migration	One-piece Shorts
Thigh to knee	Vertical MTL	Vertical	Medial thigh	Swim shorts, that is, trainer type or full thigh (male)
			Medial knee	Bikini bottom (female)
				Yoga pants (female)
Calf	Calf-lift	Vertical	Medial	Yoga pants

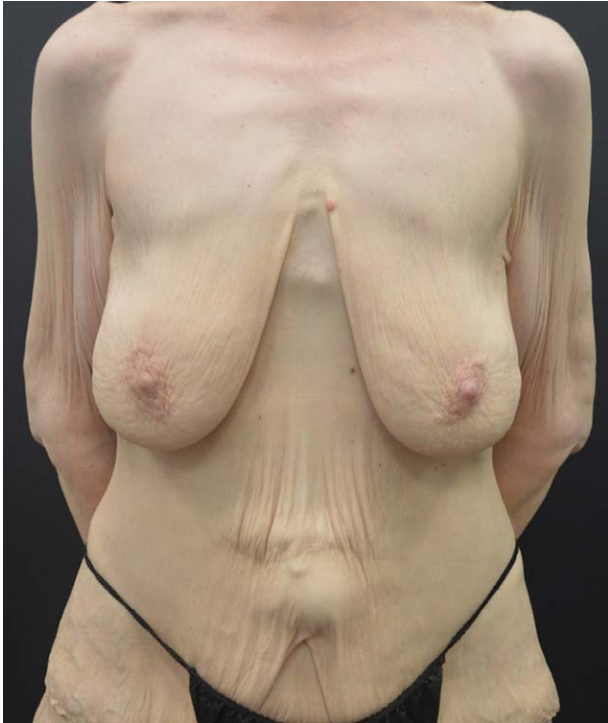
MTL, medial thigh lift.

## DISCUSSION

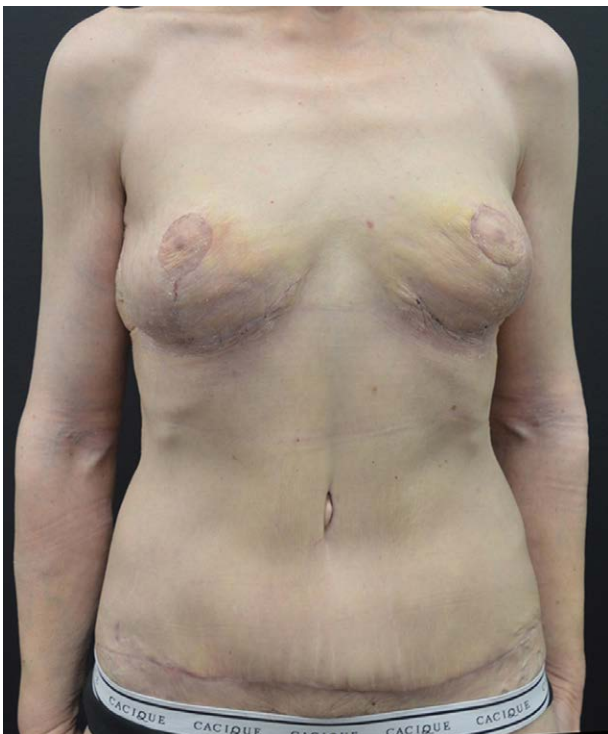
With increasing demand for BCS after MWL, both contour and resulting scars must be considered in obtaining the optimum result. The six principles in optimal planning of an incision for BCS have been stated above. Each of these principles has varying degrees of importance, depending on the procedure (Table 5).

AUs have been described from the cartographic viewpoint.<sup>13</sup> Others have discussed AUs as they pertain to liposuction.<sup>16–20</sup> Gusenoff et al<sup>14</sup> stressed the importance of AUs in the treatment of pseudogynecomastia. With regard to incisions, Courtiss et al<sup>21</sup> commented that “certainly a prime method by which a patient judges the competence of his surgeon is by the appearance of the resultant scar.” Webster<sup>22</sup> suggested that wrinkle lines should be followed when making skin incisions. “The simplest rule for making incisions in the most favorable direction is to follow

the natural wrinkle lines. These are usually recognizable on the face, the neck, the wrist, the axilla, the groin, or the back of the knee.”<sup>22</sup> Kraissl<sup>23</sup> further reviewed wrinkle lines with respect to the face and body, explaining differences in the scapular region between his lines and those of Langer.<sup>24–26</sup> Wilhelm et al<sup>30</sup> stated that Kraissl lines rather than Langer lines (LLs) may be the best guides for elective incisions of the body. However, excluding joints, in the lower extremities, LLs reconcile with modern surgical approaches (Fig. 21 from Kraissl article).<sup>23</sup> Kraissl incisions for the abdomen and back reconcile with current body contouring incisions and are similar to LL except in the midline of the back where Kraissl lines are vertical as compared with the horizontal lines of Langer (Figs. 17, 18 from Kraissl article).<sup>23</sup> Relaxed skin tension lines of the face have been described by Borges and Alexander.<sup>31</sup> Incision lines have been further analyzed by Paul.<sup>32</sup>



**Fig. 11.** A 56-year-old woman after self-induced MWL, preoperative front view.

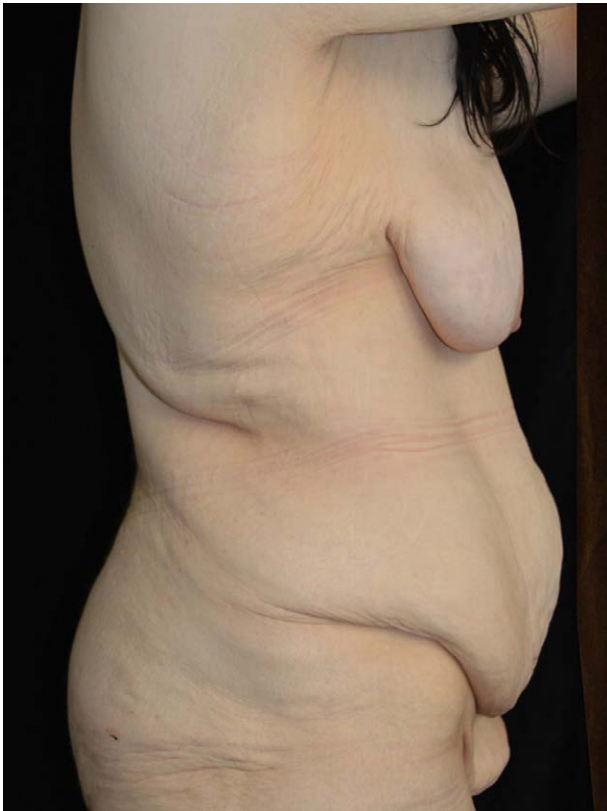


**Fig. 12.** A 56-year-old woman after self-induced MWL, 4.5 months after LBL, and 1 month after extended brachioplasty and mastopexy, postoperative front view.

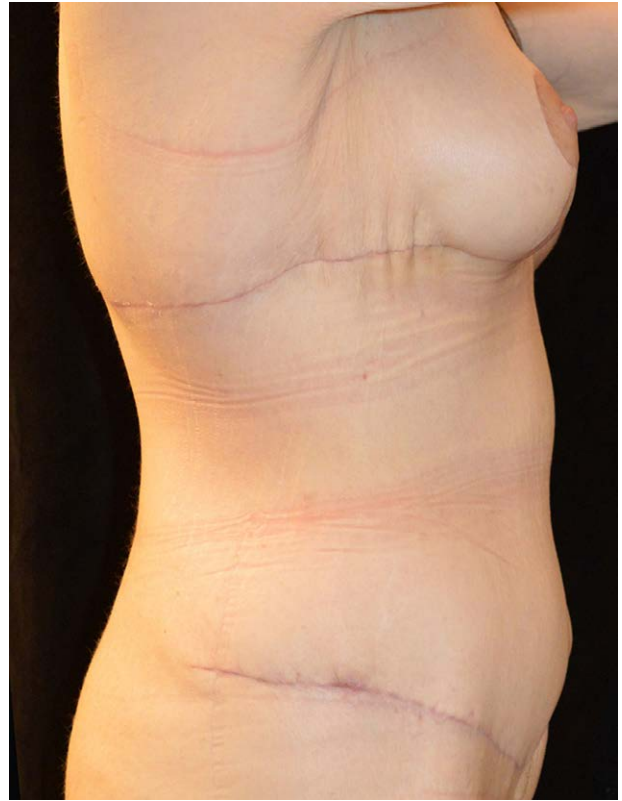When planning incisions for BCS, it is important to appreciate the topography of AUs, ZAs, FCs, ECs, joints, and skin tension lines.<sup>21-33</sup> One feature may override or mitigate against another. For example, the posterior LBL incision in the male is often lower than the iliac crest ZA, to ensure concealability beneath a swimsuit or a pants waistband, whereas in women, the incision should follow the iliac crest ZA along the superior curvilinear border of the buttock AU, which is coincidentally in a desirable position for concealability beneath a thong-style bikini bottom. See the LBL posterior scar in a woman (Fig. 2 by Rohrich et al<sup>34</sup>), which is not curvilinear and lies above the AUI, and the LBL posterior scar in a man, (Fig. 13 by Lockwood<sup>35</sup>), which demonstrates a low horizontal scar. Parenthetically, many articles of clothing highlight AUs and ZAs such as the “thong-style” bikinis and work-out “muscle” T shirts. (See figure, Supplemental Digital Content 1, which displays “muscle” T-shirt outlining scapula AUs, <http://links.lww.com/PRSGO/C624>.) The ideal incision for gynecomastia excision after MWL, also described as pseudo-gynecomastia,<sup>14</sup> is at the AUI between the PMM, abdomen (ABD), and EO AUs (Table 2). For women, inframammary fold (IMF) incisions permit the wearing of a crop top. In the female breast, it is important to avoid the upper medial quadrant in terms of scar visibility and to use the IMF as one border of an AU reconstruction.<sup>7</sup> A lower abdominoplasty scar permits wearing of high- or low-waisted pants. In contrast, a “fleur-de-lis” vertical scar precludes wearing an outfit such as a crop top, which exposes the midriff. Gynecomastia excision with a free nipple graft and a transverse scar through the center of the breast<sup>36</sup> and the “boomerang” scar<sup>37</sup> technique transgress the integrity of the PMM AU. High posterior curvilinear incisions<sup>38</sup> in an LBL prevent concealment of the scar below the waistband of pants, swim shorts, or a bikini bottom. UBL incisions, which cross the midline of the back will prevent wearing a low-backed dress or one-piece swimsuit.<sup>39</sup>

Results of reconstructive procedures are published in the contemporary plastic surgery literature, which ignore AUs and create a patchwork quilt-like appearance.<sup>40</sup> The concept of AUs, as described by Burget, Spear, and others,<sup>3-15</sup> is further elaborated in this article, in the context of torso and limb surgery (Tables 1-3). ZAs, previously described,<sup>15</sup> are cataloged and classified (Table 4). The concept of the interface between an AU and ZA (AUI) is defined. Clothing preferences are reviewed with respect to scar placement and AUs. This classification is intended to act as a basis for planning BCS and for measuring outcomes based on scar position and visibility. Finally, an algorithm is presented, which outlines the six primary decision points in planning incisions for different BCS procedures. The six decision points are represented as a horizontal row with columns of procedures below. A single procedure may occur in multiple columns since more than one decision point may affect the choice of incision (Fig. 15). (See Video [online], which displays the body contouring AUs and ZAs together with the principles of planning BCS.)





**Fig. 13.** A 34-year-old woman, after self-induced MWL, preoperative right-side view.

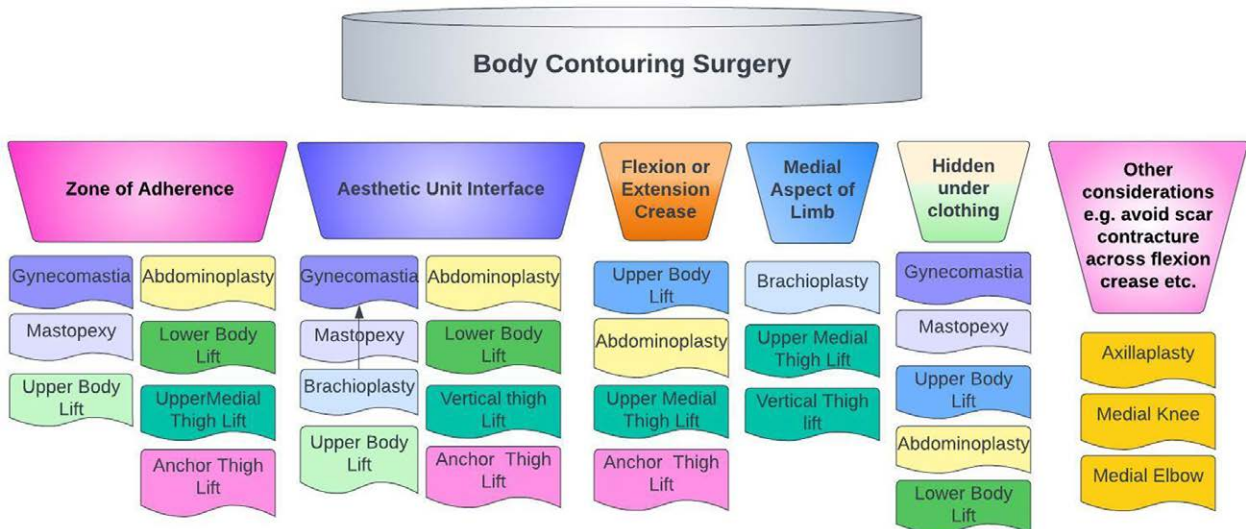


**Fig. 14.** A 34-year-old woman, 3 months after extended abdominoplasty and 1 month after breast lift and breast autoaugmentation, postoperative right-side view.

### CONCLUSIONS

This article describes a practical, comprehensive description of AUs and ZAs of the trunk and extremities. This is a metaphorical “quantum theory” for aesthetic and reconstructive surgery, combining multiple concepts and anatomical landmarks into one simple unifying theory

that applies to all elements of the practice of plastic surgery of the torso and extremities. This “atlas of aesthetics” is for planning and execution of BCS and also for other aesthetic and reconstructive surgery of these body parts. AUs, ZAs, and AUIs are not limited to the torso and extremities, but also occur in the head, neck, hands, and



**Fig. 15.** Body contouring surgery. Decision points in planning incisions.

feet, and a description of these may serve as subject matter for a publication by this or another author.

This article, with its presentation of AUs, ZAs, FCs, and ECs, and the accompanying figures may also serve as a useful addition to the curriculum for plastic surgeons in residency and fellowship training, as well as a guide for practicing plastic surgeons. At a minimum, it will stimulate a conversation and an exchange of ideas. Other authors may disagree or may choose to further improve on this analysis, as is the nature of scientific discourse. As plastic surgeons, we live and breathe the “aesthetic canons” of the human body, and it is inculcated into our training and practice that we be constantly mindful as to what will create a good, bad, or ugly result, with a view of avoiding, at all costs, the second and third options. Again, let us not forget the words of Dr. McCoy, past president of the ASPs (1976), “if you aim for less than perfection you will hit it every time.” Perfection must be our goal.

**Laurence Kirwan, MD, FRCS**

Kirwan Plastic Surgery  
Norwalk, Conn; and  
Section of Plastic Surgery  
Greenwich Hospital,  
Yale New Haven Health System  
Greenwich, Conn.  
E-mail: drkirwan@drkirwan.com

### DISCLOSURES

*The author has no financial interest to declare in relation to the content of this article.*

### ACKNOWLEDGMENTS

*This paper would not be of its current high quality without the unpaid efforts and recommendations of the anonymous reviewers of PRs Global Open to whom I express my sincere gratitude. I am always wiser and better informed after reading their comments (positive and negative), and the final draft is literally more readable and substantial after taking their recommendations into consideration.*

*Ethical Compliance: All procedures performed in studies involving human participants were in accordance with the ethical standards of the institutional and/or national research committee and with the 1964 Helsinki Declaration and its later amendments or comparable ethical standards.*

### REFERENCES

- Siebert JW, Burd AR, McCarthy JG, et al. Fetal wound healing: a biochemical study of scarless healing. *Plast Reconstr Surg*. 1990;85:495–502. PMID: 2315389.
- McCoy, FJ. *The Way It Was: The Life and Times of Frederick J. McCoy, 2016–2003 and Counting*. Private Printing; 2003.
- Burget GC, Menick FJ. The unit principle in nasal reconstruction. *Plast Reconstr Surg*. 1985;76:239–247.
- Burget GC, Menick FJ. *Aesthetic Reconstruction of the Nose*. St. Louis: Mosby, 1994.
- Gonzalez-Ulloa M, Castillo A, Stevens E, et al. Preliminary study of the total restoration of the facial skin. *Plast Reconstr Surg* (1946). 1954;13:151–161.
- Millard DR. Shaping and positioning the lip-switch flap in unilateral clefts. *Cleft Craft*. Boston: Little Brown, 1976:593–628.
- Spear SL, Davison SP. Aesthetic units of the breast. *Plast Reconstr Surg*. 2003;112:440–447.
- Restifo RJ. The “aesthetic unit” principle in late TRAM flap breast reconstruction. *Ann Plast Surg*. 1999;42:235–239.
- Coutinho M, Southern S, Ramakrishnan V, et al. The aesthetic implication of scar position in breast reconstruction. *Br J Plast Surg*. 2001;54:326–330.
- Hidalgo DA. Aesthetic refinement in breast reconstruction: complete skin-sparing mastectomy with autogenous tissue transfer. *Plast Reconstr Surg*. 1998;102:63–70.
- Gabka CJ, Maiwald G, Bohmert H. Immediate breast reconstruction for breast carcinoma using the periareolar approach. *Plast Reconstr Surg*. 1998;101:1228–1234.
- Hidalgo DA. Aesthetic refinement in breast reconstruction: complete skin-sparing mastectomy with autogenous tissue transfer. *Plast Reconstr Surg*. 1998;102:63–70.
- Teplica D, Coone E, Kirklys M, et al. Cartography and topographic mapping: the historical basis for the standardization of anatomical analysis and surgical mask-making to improve outcomes in body contouring. *Plast Reconstr Surg*. 2022;150:67–79.
- Gusenoff JA, Coon D, Rubin JP. Pseudogynecomastia after massive weight loss: detectability of technique, patient satisfaction, and classification. *Plast Reconstr Surg*. 2008;122:1301–1311.
- Lockwood TE. Superficial fascial system (SFS) of the trunk and extremities: a new concept. *Plast Reconstr Surg*. 1991;87:1009–1018.
- Mendieta C, Stuzin JM. Gluteal augmentation and enhancement of the female silhouette: analysis and technique. *Plastic Reconstr Surg*. 2018;14:306–311.
- Hoyos AE, Perez, ME, Domínguez-Millán, R. Male aesthetics for the gluteal area: anatomy and algorithm for surgical approach for dynamic definition body contouring. *Plast Reconstr Surg*. 2020;146:284–293.
- Hoyos AE, Cala LC, Perez ME, et al. High-definition liposculpture 18-year evolution: patient safety and aesthetic outcomes. *Plast Reconstr Surg*. 2023;151:737–747.
- Caridi RC. Defining the aesthetic units of the male chest and how they relate to gynecomastia based on 635 patients. *Plast Reconstr Surg*. 2018;142:904–907.
- Si L, Li Z, Li H, et al. Anatomical guidelines for thigh lipoplasty based on cadaveric dissection of the superficial fascial system in the thigh. *Plast Reconstr Surg*. 2023;151:293–302.
- Courtiss EH, Longacre JJ, deStefano GA, et al. The placement of elective skin incisions. *Plast Reconstr Surg*. 1963;31:31–44.
- Webster J. Deforming scars, their causes, prevention and treatment. *Pennsylvania M.J.* 1935;3:929.
- Kraissl CJ. The selection of appropriate lines for elective surgical incisions. *Plast Reconstr Surg*. 1951;8:1–28.
- Kirshner M, Shubert A. *Operations-Lehre Allgemeiner Teil*. Berlin: Julius Springer, 1927;1:326.
- Langer K. Zur Anatomie und Physiologie der Haut. Über die Spaltbarkeit der Cutis. Sitzungsbericht der Mathematisch-naturwissenschaftlichen Classe der Wiener Kaiserlichen Academie der Wissenschaften Abt. *Imperial Academy of Sciences Dept*. 1861;44.
- Langer K. On the anatomy and physiology of the skin. *Brit J Plast Surg*. 1978;31:3–8.
- Kirwan L. Breast autoaugmentation. *Can J Plast Surg*. 2007;15:73–76.
- Kirwan L, Wazir U, Mokbel K. Breast auto-augmentation: a versatile method of breast rehabilitation—a retrospective series of 107 procedures. *Arch Plast Surg*. 2015;42:438–445.
- Kirwan L. Lollipop mastopexy, combined periareolar and vertical mastopexy. *ANZ J Surg*. 2003;73(suppl):73.

30. Wilhelmi BJ, Blackwell SJ, Phillips LG. Langer's lines: to use or not to use. *Plast Reconstr Surg*. 1999;104:208–214. PMID 10597698
31. Borges AF, Alexander JE. Relaxed skin tension lines, Z-plasties on scars and fusiform excision of lesions. *Br J Plast Surg*. 1962;15:242.
32. Paul SP. Biodynamic excisional skin tension (best) lines: revisiting langer's lines, skin biomechanics, current concepts in cutaneous surgery, and the (lack of) science behind skin lines used for surgical excisions. *J Dermatol Res*. 2017;2:77–87.
33. Kirwan ZL. Anchor thighplasty. *Aesthet Surg J*. 2004;24:61–64.
34. Rohrich RJ, Gosman AA, Conrad MH, et al. Simplifying circumferential body contouring: the central body lift evolution. *Plast Reconstr Surg*. 2006;118:525–535.
35. Lockwood TE. Lower-body lift. *Aesthet Surg J*. 2001;21:355–370.
36. Mladick RA. Body contouring: gynecomastia. *Aesthet Surg J*. 2004;24:471–479.
37. Hurwitz DJ. Boomerang pattern correction of gynecomastia. *Plast Reconstr Surg*. 2015;135:433–436.
38. Hurwitz DJ, Beidas O, Wright L. Reshaping the oversized waist through oblique flankplasty with lipoabdominoplasty. *Plast Reconstr Surg*. 2019;143:960e–972e.
39. Hurwitz DJ. Aesthetic refinements in body contouring in the massive weight loss patient: trunk. *Plast Reconstr Surg*. 2014;134:1185–1195.
40. Mookerjee VG, Prassinos AJ, Alper DP, et al. Combined tripiet and V-Y advancement flaps for reconstruction of large lid-cheek junction defects. *Plast Reconstr Surg Global Open*. 2023;11:e4874.