

Atrial tachycardia in an electrically dissociated native right atrium after heart transplantation



Gloria C. Lehmann, MD, MPH, George F. Van Hare, MD, FHRS, Jennifer N. Avari Silva, MD, FHRS

From the Division of Pediatric Cardiology, Washington University in St. Louis School of Medicine, St Louis, Missouri.

Introduction

Symptomatic atrial tachyarrhythmia (AT) after heart transplantation occurs in nearly 10% of orthotopic heart transplant recipients, with atrial flutter (AFL) being the most common.¹ Case reports have described adult transplant recipients presenting with multiple ATs in the donor as well as native atria.^{2,3} However, there have been no reports of heart transplant recipients with biatrial anastomosis whose donor atria were in normal sinus rhythm while the native atria were in AT. We present our findings in a 19-year-old heart transplant recipient who underwent electrophysiology study and whose native atrium was found to be in atrial tachycardia while donor atrium was in normal sinus rhythm with normal 1:1 atrioventricular (AV) conduction.

Case report

A 19-year-old male subject with a history of hypoplastic left heart syndrome previously underwent orthotopic heart transplant with biatrial anastomosis on day of life 5. He experienced a syncopal episode while exercising. He had a normal echocardiogram with normal systolic function (unchanged from previous studies), electrocardiogram with normal sinus rhythm with right bundle branch block, and normal exercise stress test. He underwent electrophysiology study to evaluate for potential arrhythmias.

Transvenous quadripolar catheters were positioned in the high right atrium (HRA) and right ventricle with an esophageal lead positioned for left atrial recording. At baseline, the HRA signals showed 2 distinct atrial rhythms based on atrial electrogram morphology: the first with atrial tachycardia with an atrial cycle length (CL) of 220 ms and the second with an atrial CL of 900 ms. The ventricular rate was regular with a CL of 900 ms, which appeared to

demonstrate 1:1 AV conduction with the second atrial rhythm.

Given the patient's history of a biatrial anastomosis, we hypothesized that the patient's native atrium was in a regular atrial tachycardia (CL 220 ms) while donor heart was in normal sinus rhythm (CL 900 ms) with 1:1 AV conduction. To demonstrate this, the HRA catheter was repositioned into the donor atrium and atrial electrogram tracings revealed atrial tachycardia at CL 220 ms. Simultaneous fluoroscopy images were recorded confirming catheter location in the native right atrium and donor ventricle (Figure 1). The HRA catheter was then repositioned into the donor right atrium, near the tricuspid valve annulus, and demonstrated atrial CL of 900 ms (Figure 1). Atrial overdrive pacing at this site demonstrated 1:1 AV conduction with a Wenckebach CL of 400 ms. Overdrive pacing of the donor atrium did not disrupt native atrial tachycardia CL, suggesting unidirectional block (Figure 2). No atrial pacing was performed in the native atrium. At this juncture, the electrophysiology study was concluded. The patient was ultimately discharged home with no conclusive etiology for his syncope. After 1 year of follow-up, the patient has not had further syncopal events and has no complaints of palpitations or dizziness, despite remaining physically active (Figure 3).

Discussion

Atrial arrhythmias in post-heart transplant recipients has been well described in the literature.^{1,4,5} There are case reports of adult biatrial anastomosis heart transplant recipients who have presented with arrhythmias leading to findings of multiple atrial arrhythmias in both donor and native atria.^{2,3} The proposed mechanism of atrial arrhythmias in these patients is that the suture lines may constitute electrical lines of conduction block that facilitate incisional atrial arrhythmias and the remnant native atrium introduces a region of scarring that may play a role in the development of atrial arrhythmias.⁶ Atrial arrhythmias, particularly AFL, can be an indication of graft dysfunction, including either cellular or humoral rejection, or transplant-related coronary vasculopathy.⁴ This was not the case for our patient, who

KEYWORDS Atrial tachycardia; Orthotopic heart transplantation; Pediatric electrophysiology; Syncope; Biatrial anastomosis
(Heart Rhythm Case Reports 2016;2:356–359)

Address reprint requests and correspondence: Dr Jennifer N. A. Silva, Division of Pediatric Cardiology, Washington University School of Medicine/St Louis Children's Hospital, CB 8116-NWT, 1 Children's Place, St Louis, MO 63110. E-mail address: silva_j@kids.wustl.edu.

KEY TEACHING POINTS

- Atrial arrhythmias can occur in heart transplant recipients with biatrial anastomosis.
- In heart transplant recipients with biatrial anastomosis, the native atrium is usually electrically dissociated from the donor atrium. In this case, the donor atrium was in normal sinus rhythm with normal atrioventricular conduction while the native atrium was in atrial flutter. Radiofrequency ablation is not indicated in these patients.
- Three-dimensional electroanatomic mapping may be useful in elucidating the mechanism of atrial arrhythmias in post-heart transplant patients with biatrial anastomosis.

presented 19 years after orthotopic heart transplant, particularly since the arrhythmia was present in the nontransplanted tissue.

To our knowledge, this is the only report of a pediatric heart transplant patient whose donor heart was in normal sinus rhythm with normal 1:1 AV conduction while the native atrium was in atrial tachycardia. We were not only able to demonstrate these different distinct rhythms but also able to demonstrate that in the setting of this patient’s anatomy of the biatrial anastomosis, there was electrical disconnection between the native and donor atria. Thus there was no treatment or ablation indicated for this patient, who has since been asymptomatic with an unchanged electrocardiogram (Figure 3) and without subsequent episodes of syncope.

Symptomatic atrial arrhythmias in heart transplant recipients, as well as successful radiofrequency ablation, have been described.^{4,7,8} Three-dimensional electroanatomic mapping has been utilized to elucidate the mechanism of AFL in these patients.^{2,3} In one study, ablation in the native atrium was not performed because of electrical conduction block between the donor atrium and residual recipient atrial tissue,³ which was also observed in this case. There have been no previous studies that demonstrated the native atrium in AFL while the donor heart is in normal sinus rhythm.

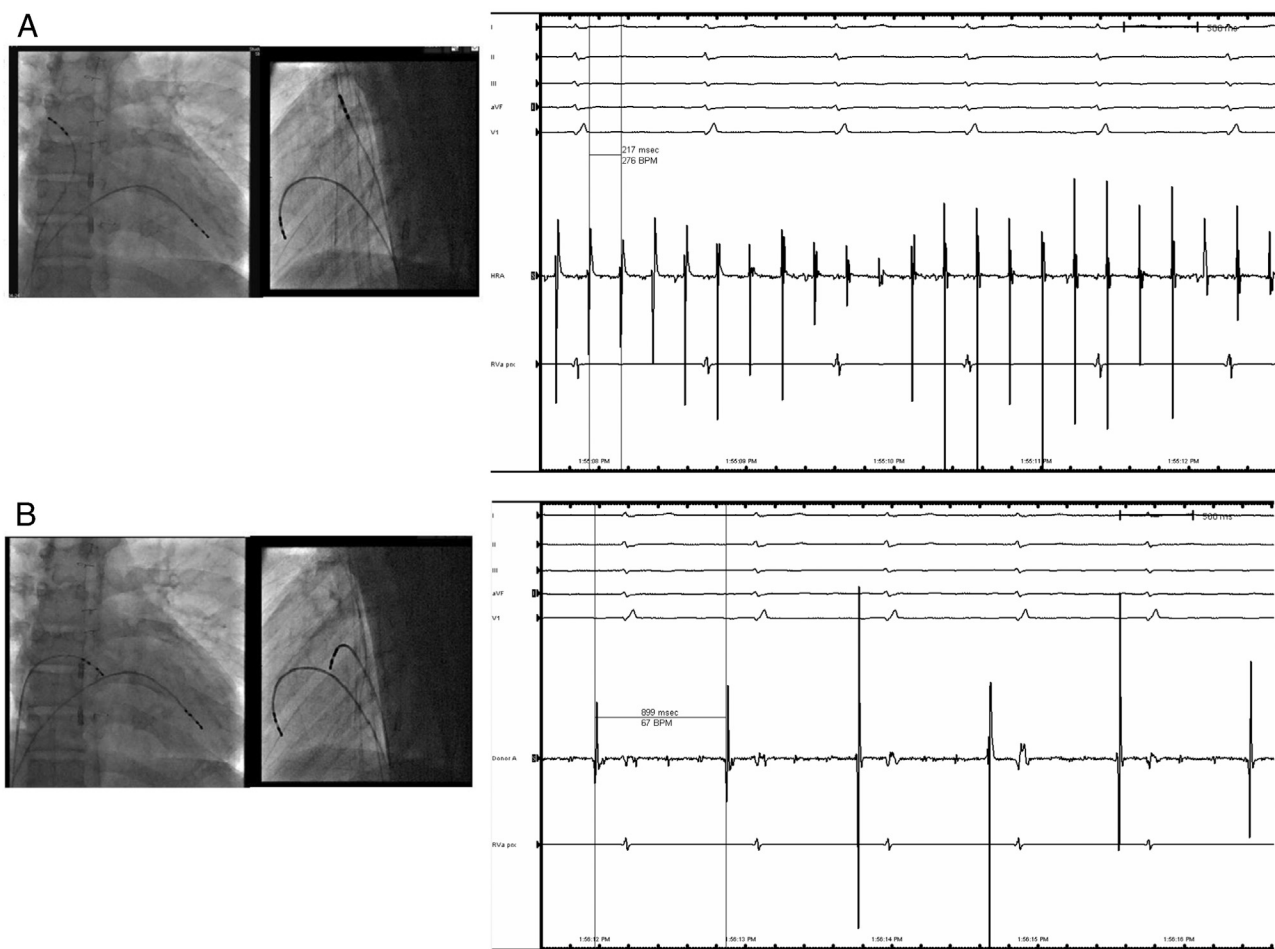


Figure 1 **A:** High right atrium (HRA) catheter positioned in the native atrium demonstrating atrial tachycardia with an atrial cycle length of 220 ms. Fluoroscopy images obtained in anteroposterior and lateral projections confirm catheter location in native atrium and right ventricle. **B:** HRA catheter positioned in the donor atrium demonstrated sinus rhythm with 1:1 atrioventricular conduction at a cycle length of 900 ms. Fluoroscopy images obtained in anteroposterior and lateral projections confirm catheter location in donor atrium and right ventricle.




Figure 2 Atrial overdrive pacing from the donor atrium at 500 ms (panel A) and 400 ms (panel B). **A:** Image shows the native atrial cycle length of 270 ms that is electrically independent, or dissociated from donor atrial pacing. **B:** There is atrioventricular Wenckebach again with A-A dissociation. In both panels, donor atrial pacing was unable to disrupt native atrial tachycardia cycle length, thus proving unidirectional block.

The reestablishment of electrical conduction between donor and native atria has been described in patients after orthotopic heart transplantation, occurring in $\leq 10\%$ of patients after heart transplantation.^{1,9} Many reentrant ATs in this population involve the surgical suture lines of the atrio-atrial anastomosis. This would seem unlikely in our patient, 19 years post-transplant, as the electrical reconnection between native and donor atria would have been apparent during electrophysiology study. In symptomatic patients, these circuits have been effectively treated with radiofrequency catheter ablation.

Conclusion

This is a case of a pediatric heart transplant recipient who underwent biatrial anastomosis in whom the native atrium was in atrial tachycardia while donor atrium was in normal sinus rhythm with normal AV conduction. Radiofrequency ablation was not indicated, as there was electrical conduction block and the atrial tachycardia in the native atrium was not hemodynamically relevant. Further studies, especially with the use of electroanatomic mapping, may be indicated to further elucidate the mechanism of atrial arrhythmias in some post-heart transplant patients with biatrial anastomosis.

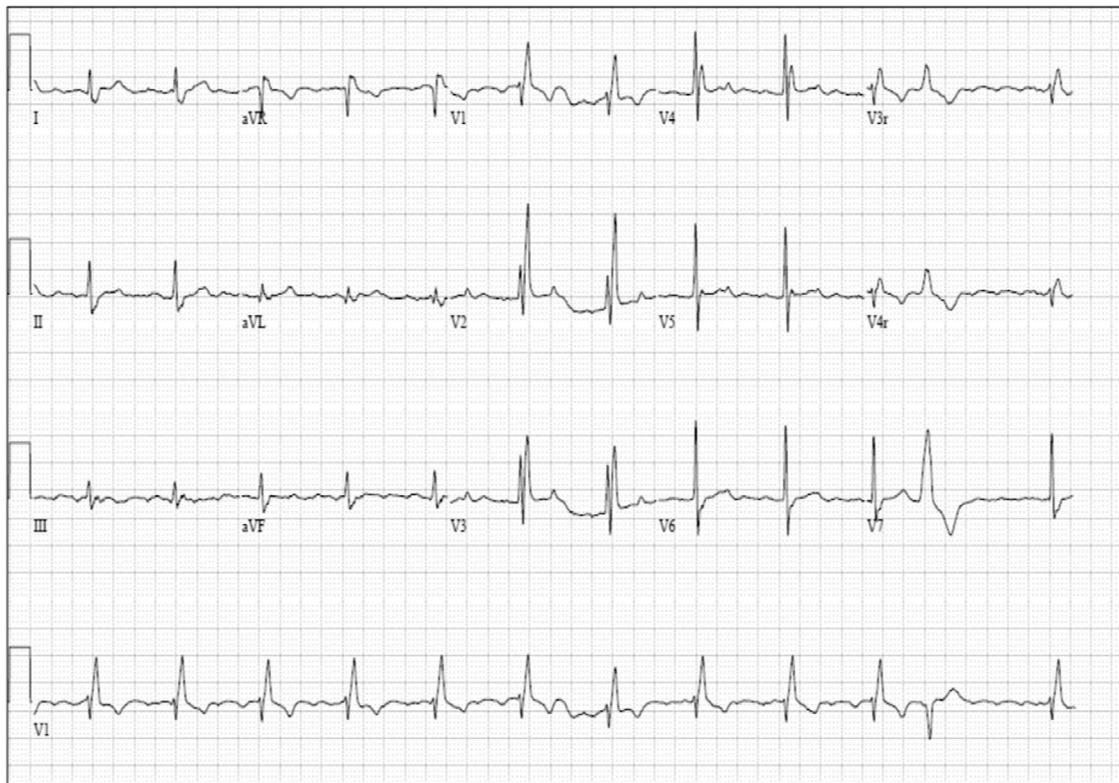

Figure 3 Postprocedure 12-lead electrocardiogram shows sinus rhythm with right bundle branch block. A single premature ventricular complex (PVC) is seen. Atrial flutter can also be appreciated, following the PVC.

References

- Vaseghi M, Boyle NG, Kedia R, Patel JK, Cesario DA, Wiener I, Kobashigawa JA, Shivkumar K. Supraventricular tachycardia after orthotopic cardiac transplantation. *J Am Coll Cardiol* 2008;51:2241–2249.
- Jin Q, Pehrson S, Jacobsen PK, Chen X. Mapping strategy for multiple atrial tachyarrhythmias in a transplant heart. *BMC Cardiovasc Disord* 2015;15:38.
- Nevzorov R, Ben-Gal T, Strasberg B, Haim M. Atrial flutter in a post-transplant recipient. *Isr Med Assoc J* 2012;14(7):448–449.
- Magnano AR, Garan H. Catheter ablation of SVT in transplanted heart: a case series and literature review. *Pacing Clin Electrophysiol* 2003;26(9):1878–1886.
- Rodríguez-Entem F, Exposito V, Gonzalez-Enriquez S, Garcia-Camarero T, Olalla J. Atrial flutter after heart transplantation: mechanism and catheter ablation. *Transplant Proc* 2010;42:2697–2701.
- Yamada T, Kumar V, Neal Kay G. Regularly irregular atrial tachycardia following orthotopic heart transplant: what is the mechanism? *J Cardiovasc Electrophysiol* 2014;25:105–106.
- Heist EK, Doshi SK, Singh JP, Di Salvo T, Semigran MJ, Reddy VY, Keane D, Ruskin JN, Mansour M. Catheter ablation of atrial flutter after orthotopic heart transplantation. *J Cardiovasc Electrophysiol* 2004;15(12):1366–1370.
- Li YG, Gronefeld G, Israel C, Lu SB, Wang QS, Hohnloser SH. Radiofrequency catheter ablation in patients with symptomatic atrial flutter/tachycardia after orthotopic heart transplantation. *Chin Med J* 2006;119(24):2036–2041.
- Lefroy DC, Fang JC, Stevenson LW, Hartley LH, Friedman PL, Stevenson WG. Recipient-to-donor atrioatrial conduction after orthotopic heart transplantation: surface electrocardiographic features and estimated prevalence. *Am J Cardiol* 1998;82(4):444–450.