



Results of Infrainguinal Bypass with a Composite Graft Combining Polytetrafluoroethylene and Vein Graft in Absence of Appropriate Saphenous Vein Graft

Myung Jae Jin¹, Ui Jun Park², Hyoung Tae Kim², and Young-Nam Roh²

¹Department of Surgery, Ilsan Paik Hospital, Inje University College of Medicine, Goyang, ²Division of Transplantation and Vascular Surgery, Department of Surgery, Keimyung University Dongsan Medical Center, Daegu, Korea

Purpose: Use of a composite graft combining a polytetrafluoroethylene graft with an autogenous vein is an option for limb salvage in the absence of an adequate single segment vein graft. We aimed to investigate the results of infrainguinal bypass with a composite graft.

Materials and Methods: We retrospectively reviewed 11 infrainguinal arterial bypasses on 11 limbs which underwent surgery from March 2012 to November 2016.

Results: Critical limb ischemia was common (63.6%) indication of bypass surgery and most (90.9%) of the patients had history of failed previous treatment including endovascular treatment (36.4%) and bypass surgery (72.7%). At the 2 years after graft implantations, primary patency and amputation-free survival of below-knee bypasses using composite graft were 73% and 76%, respectively.

Conclusion: Infrainguinal arterial bypasses with composite graft had an acceptable patency. In patients without other alternative conduits for revascularization, bypass with a composite graft can be an option.

Key Words: Infrainguinal, Bypass, Composite graft

Received March 25, 2017

Revised (1st) May 7, 2017

(2nd) May 22, 2017

Accepted May 22, 2017

Corresponding author: Young-Nam Roh

Division of Transplantation and Vascular Surgery, Department of Surgery, Keimyung University Dongsan Medical Center, 56 Dalseong-ro, Jung-gu, Daegu 41931, Korea

Tel: 82-53-250-7325

Fax: 82-53-250-7322

E-mail: ironman0913@hanmail.net

Conflict of interest: None.

Copyright © 2017, The Korean Society for Vascular Surgery

This is an Open Access article distributed under the terms of the Creative Commons Attribution Non-Commercial License (<http://creativecommons.org/licenses/by-nc/4.0>) which permits unrestricted non-commercial use, distribution, and reproduction in any medium, provided the original work is properly cited.

Vasc Spec Int 2017;33(2):65-71 • <https://doi.org/10.5758/vsi.2017.33.2.65>

INTRODUCTION

Currently, less number of infrainguinal bypass surgeries is being performed because of advances in endovascular therapy; however, a significant portion of patients still require arterial bypass as a definitive treatment in limb-threatening ischemia. Infrainguinal arterial reconstruction for limb salvage in the absence of an adequate great saphenous vein (GSV) remains challenging [1,2]. Furthermore, the patients undergoing bypass surgery for limb salvage, especially after failed endovascular therapy, are usually elderly, and the absence of a usable GSV is a common clinical scenario. High incidences of coronary artery bypass graft-

ing and reoperative lower extremity bypass surgery are also common risk factors in patients lacking an adequate saphenous vein graft.

In the absence of an adequate GSV, the use of a composite graft combining a polytetrafluoroethylene (PTFE) graft with an autogenous vein is an option; however, this is not a widely used option, and reports regarding this unusual combination of graft materials are rare. In this article, we report our experience with composite grafts combining a PTFE graft and an autogenous vein in infrainguinal bypass surgery.

MATERIALS AND METHODS

We performed a retrospective review of 11 infrainguinal arterial bypass surgeries performed on 11 limbs of 10 patients with chronic occlusion of the femoropopliteal arteries. The surgeries were performed from March 2012 to November 2016 in Ilsan-Paik Hospital by a board-certified vascular surgeon. Patients undergoing surgery for acute or subacute arterial occlusion or vascular trauma were excluded. A retrospective review of the electronic medical records was performed to identify the following variables: age, sex, comorbid conditions (diabetes mellitus, hypertension, hyperlipidemia, chronic kidney disease [CKD] stage III-V, ischemic heart disease, previous cardiac intervention, cerebrovascular accident, and tobacco use).

The composite graft was defined as a graft composed of both a PTFE and a segment of autogenous vein (saphenous vein or arm vein). Grafts including only a spliced autogenous vein segment (not using PTFE) or a vein patch at the distal anastomosis of the PTFE graft (Fig. 1) were not included in the composite graft group.

Preoperative mapping of the saphenous was done using ultrasonography. When all saphenous veins were exhausted or unavailable, the evaluation for arm veins was made. If a minimum diameter of 2 mm was seen on duplex scan, it was considered to be possible graft material. Our intra-operative criteria for an optimal vein included a minimum diameter of 2.0 mm, distensibility with gentle inflation, and

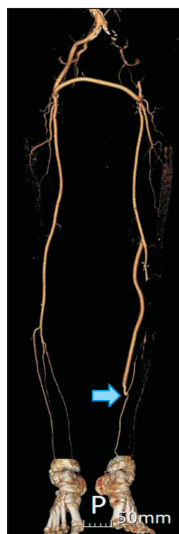


Fig. 1. Vein cuff at distal anastomosis for the anastomosis of the polytetrafluoroethylene graft to the posterior tibial artery (blue arrow). Vein cuff only at the distal anastomosis was not included in the composite graft. This popliteo-posterior tibial artery bypass graft was occluded on postoperative day 340.

the absence of sclerotic areas. If luminal diameter of the saphenous vein was too small in intra-operative findings, we considered the use of a composite graft in bypasses crossing the knee joint.

In cases of Trans-Atlantic Inter-Society consensus (TASC) C or D lesions, we preferred bypass surgery to endovascular treatment unless the patients had a severe comorbid condition including recent myocardial infarction (<6 weeks since infarction), symptomatic coronary artery disease, dialysis dependent-renal insufficiency, or severe chronic obstructive pulmonary disease. In lesions crossing the knee joint without an adequate length of GSV to cover the lesion, the author attempted to construct a composite graft with usable segments of the saphenous vein or arm vein. When there was no usable vein segment, bypass was performed with a PTFE graft, with or without a vein cuff. Fig. 2 shows the configurations of an infrainguinal bypass completed

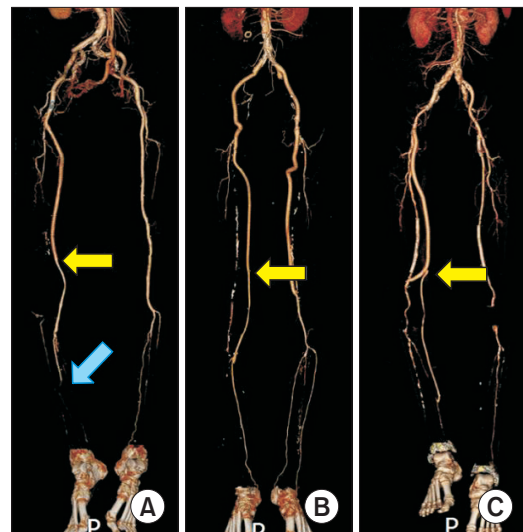


Fig. 2. Configurations used in infrainguinal bypass surgery with a composite graft in the absence of an appropriate single segment vein graft (yellow arrows: anastomosis between polytetrafluoroethylene graft and vein graft). (A) A 79-year-old female patient who underwent a right femoro-TPT bypass with a composite graft due to acute on chronic ischemia. Run-off vessels were very poor (blue arrow). Transmetatarsal amputation was needed but the limb was salvaged. (B) A 67-year-old male patient who underwent a right femoro-TPT bypass with a composite graft due to critical limb ischemia caused by a previous bypass graft occlusion. (C) A 73-year-old male patient who underwent a right femoro-above knee popliteal and posterior tibial artery graft bypass with a composite graft due to critical limb ischemia caused by a previous bypass graft occlusion. The patient had a history of multiple failed endovascular treatments. Transmetatarsal amputation was needed but the limb was salvaged. TPT, tibioperoneal trunk.

with a composite graft.

Follow-up examinations were performed within the first month of surgery, then at 3-month intervals for the first year, and semiannually thereafter. Duplex ultrasonography or computed tomography was used to image the graft during follow-up. Outcome variables included primary patency, limb salvage and amputation-free survival. Stenosis was defined as diameter reduction more than 50% on duplex ultrasonography or computed tomography. If the degree of stenosis is not clear on 2-dimensional image, the velocity criteria using peak systolic velocity ratio >2.4 on duplex ultrasonography was used. The grafts without stenosis were considered patent. Limb salvage was defined by freedom from major amputation (above the ankle). Any amputation at or distal to the Lisfranc level was not considered as a limb salvage failure. Amputation data were obtained through outpatient clinic follow-up.

Table 1. Baseline characteristics of the patients (n=11)

Variable	Value
Age (y)	72.9±8.2/73.0 (57.0-80.0)
Sex (male:female)	9 (81.8):2 (18.2)
Comorbidities	
Hypertension	6 (54.5)
Diabetes mellitus	7 (63.6)
Coronary artery disease	5 (45.5)
Cerebrovascular accident	4 (36.4)
Chronic kidney disease stage ≥III	2 (18.2)
Dyslipidemia	2 (18.2)
Smoking	8 (72.7)
Ex-smoker ^a	5 (45.5)
Current smoker ^b	3 (27.3)
Indication	
Claudication	4 (36.4)
Critical limb ischemia	7 (63.6)
Rest pain:Tissue loss	3 (27.3):4 (36.4)
Prior treatment	
None	1 (9.1)
Endovascular treatment (times)	4 (36.4)
1-2	2 (18.2)
≥3	2 (18.2)
Bypass surgery	8 (72.7)
Autogenous vein:PTFE	1 (9.1):7 (63.6)
TASC classification	
C lesion:D lesion	2 (18.2):9 (81.8)

Values are presented as mean±standard deviation/median (range) or number (%).

PTFE, polytetrafluoroethylene; TASC, Trans-Atlantic Inter-Society consensus.

^aNon-smoking period <1 year, ^bnon-smoking period ≥1 year.

Hypertension was defined as the use of antihypertensive medication for high blood pressure, or a systolic blood pressure ≥140 mmHg and/or diastolic blood pressure ≥90 mmHg. Diabetes mellitus was defined as the use of blood glucose-lowering medication and/or fasting glucose level of ≥126 mg/dL. Dyslipidemia was defined as the use of lipid-lowering medication and/or cholesterol >200 mg/dL and/or low-density lipoprotein-cholesterol >130 mg/dL. CKD stage ≥III was defined as glomerular filtration rate estimated by MDRD (Modification of Diet in Renal Disease) or CKD-Epidemiology Collaboration (EPI) equation <60 mL/min/1.73 m². Smoking included current smoker (non-smoking period <1 year) and ex-smoker (non-smoking period ≥1 year).

RESULTS

Table 1 shows patient demographics, comorbidities, the indications for revascularization, prior treatment, and the TASC classification. The median (range) age of the patients was 73.0 years (57.0-80.0 years); 63.6% had diabetes and 45.5% had coronary artery disease. A total of 72.7% of the

Table 2. Procedural details of bypass with composite graft (n=11)

Procedural details	Value
Concomitant Inflow procedure ^a	5 (45.5)
Iliac PTA	2 (18.2)
Ilio-fem bypass	2 (18.2)
Aorto-fem bypass	1 (9.1)
Proximal anastomosis	
External iliac artery	1 (9.1)
Common femoral artery	8 (72.7)
Superficial femoral artery	2 (18.2)
Distal anastomosis	
Above knee popliteal artery	0
Below knee popliteal artery	6 (54.5)
Crural	5 (45.5)
Tibioperoneal trunk	2 (18.2)
Posterior tibial artery	2 (18.2)
Anterior tibial artery	1 (9.1)
Peroneal artery	0
Crossing knee joint	
Above knee	0
Below knee	11 (100)
Graft material	
PTFE+GSV	10 (90.9)
PTFE+Arm vein	1 (9.1)

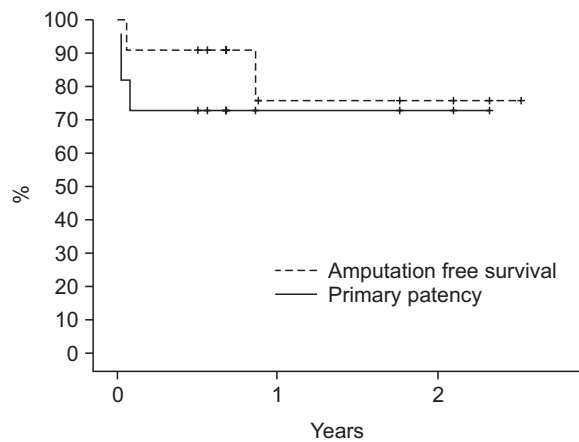
PTA, percutaneous transluminal angioplasty; PTFE, polytetrafluoroethylene; GSV, great saphenous vein.

^aInflow procedures which were performed perioperatively.

patients were ex-smoker or current smoker, critical limb ischemia was the indication of treatment in 63.6%. A total of 90.9% of the patients had history of prior treatment including endovascular treatment (36.4%) and bypass surgery (72.7%). All lesions (100%) were chronic total occlusion and most (81.8%) of the lesions were TASC D lesion.

The procedural details of bypass surgery are shown in Table 2. Concomitant inflow procedures were performed in 45.6%. A total of 72.7% of bypasses had their proximal anastomosis at the common femoral artery, 18.0% at superficial femoral artery, and 9.1% at external iliac artery. The distal anastomoses were to the below knee popliteal artery in 54.5%, tibioperoneal trunk in 18.2%, posterior tibial artery in 18.2%, and anterior tibial artery in 9.1%. All the procedures were crossing the knee joint. The composite grafts were composed of PTFE grafts combined with 10 great saphenous veins and 1 basilic vein.

Patients were followed-up for a mean 506.9 days (range, 182-920 days). There was no perioperative mortality or loss of follow-up. Three bypass graft were occluded, 1 patient required a major amputation, and 1 patient died with a salvaged limb during follow-up. The 2-year primary patency and amputation-free survival were 73% and 76%, respectively (Fig. 3).



Years	1	2
Primary patency	73%	73%
No. at risk	3	2
No. of event	3	0
Amputation free survival	76%	76%
No. at risk	4	3
No. of event	2	0

Fig. 3. Kaplan-Meier curve demonstrating primary patency and amputation-free survival (mean follow-up duration=506.9±302.9 days, range=182-920 days).

DISCUSSION

Although numerous studies conclusively support the use of saphenous vein grafts for lower extremity arterial reconstruction [3-8], the absence of an acceptable saphenous vein graft with an optimal diameter of appropriate length is common. In the absence of an appropriate GSV graft, other autogenous options include the small saphenous vein or an arm vein. However, data regarding the optimal conduit for below-knee arterial bypass in the absence of a usable single segment GSV are not robust and results have been mixed [1,9-14]. In addition, despite the time-consuming and technically difficult procedure for harvesting unusual autogenous veins, vein quality cannot be guaranteed in many cases. Therefore, we favored using a composite graft than using an arm vein or a spliced vein graft in the absence of an adequate single segment GSV.

All bypasses in the composite graft crossed the knee joint in this series. Generally, intermediate-term patency of below knee bypasses using PTFE grafts has been reported to be low [15-22]. In the series of this study, the composite grafts were used to minimize the disadvantage of PTFE graft crossing the knee joint. Eight patients (72.7%) had history of previous bypass surgeries; in 7 patients among these, the previous bypasses were using PTFE graft due to lack of appropriate saphenous vein graft. Nevertheless, with the selective combination of PTFE and short segment of vein, we could complete the reoperative bypasses minimizing the disadvantage of PTFE graft.

A composite graft has several advantages. First, the procedures required for completing a composite graft are simple and technically easy. These procedures are illustrated in Fig. 4. We prefer completing the distal anastomosis first because it can be performed easily with good visibility at the anastomosis site. Although composite grafts necessitate an additional anastomosis between a vein graft and a PTFE graft (Fig. 4C), this anastomosis is not technically difficult because it is usually performed in a relatively superficial layer (Fig. 4C). The large caliber and stiff features of the PTFE graft are also helpful in preventing a purse string effect at this anastomosis. Especially in cases of saphenous vein duplication, the duplication site can be used as this anastomosis site using the T-junction technique (making a common channel at the bifurcation site). Second, a composite graft can eliminate the risk of juxta-anastomosis site stricture, which is common in the proximal part of a long bypass using a reversed saphenous vein. The large caliber of the ringed PTFE graft allows sufficient proximal graft flow. Third, a composite graft retains the advantages of autogenous vein graft in bypasses crossing the knee joint. The vein component of the composite graft is flexible and

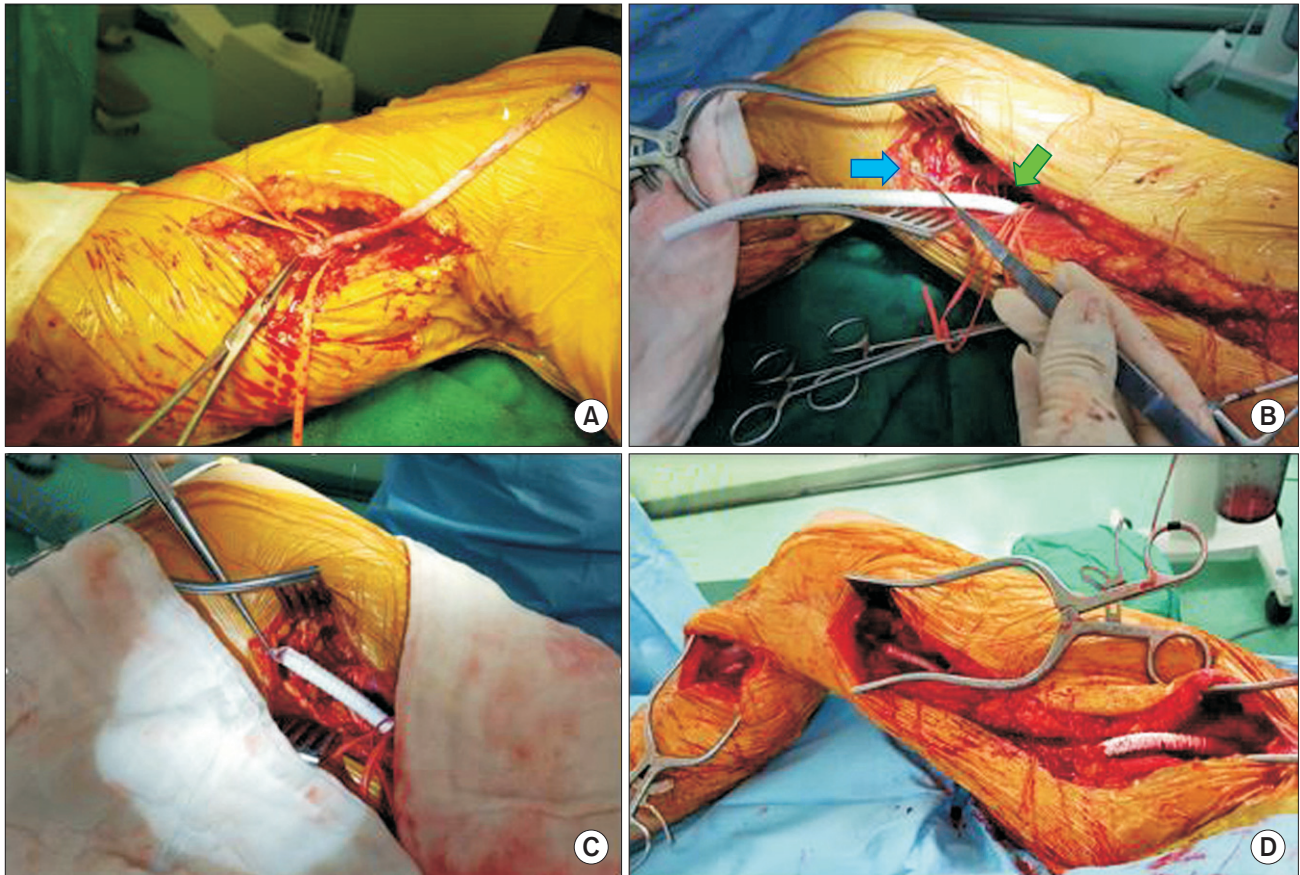


Fig. 4. Femoro-TPT bypass with composite graft using a PTFE graft and the proximal part of the ipsilateral great saphenous vein. (A) Distal anastomosis of the short segment reversed great saphenous vein at the TPT. (B) Tunneled ringed 6 mm PTFE graft anastomosed proximally to the common femoral artery (green arrow) and saphenous vein graft tunneled to above the knee (blue arrow). (C) Anastomosis between the PTFE and saphenous vein grafts. (D) Completion of anastomosis: above knee segment was composed of PTFE graft and distal segment crossing the knee joint was composed of a reversed saphenous vein graft. TPT, tibioperoneal trunk; PTFE, polytetrafluoroethylene.

makes the distal anastomosis feasible and redundant.

Three conditions are necessary to maintain the patency of a composite graft. First, sufficient inflow must be obtained. To overcome the thrombogenic effect of the PTFE graft, inflow should be abundant. In this study, concomitant inflow procedures were performed in 45.5% of bypasses. Second, only an autogenous vein of good quality with a large diameter must be used. Prior studies have reported unfavorable outcomes of composite prosthetic-autogenous grafts [11,23,24]; however, these studies have a possibility of selection bias, and the details of the procedures using composite grafts were not well described. Third, the operation must be performed in a planned manner. Thorough evaluation for the usable vein segment and careful selection of the distal anastomosis site are essential. In our series, bypasses with composite grafts were planned preoperatively in 9 cases. In other 2 cases, the decision of using composite graft was made intra-operatively, and these 2

bypass grafts were occluded immediately after the surgery postoperatively. We believe precise preoperative planning is an important factor. Our principle is to avoid the placement of an artificial graft crossing the knee joint and to use only a good quality vein in the composite graft. We believe that this strategy is essential to maintain the primary patency of composite grafts. In addition, the composite graft can be used as a type of sequential bypass grafting (Fig. 2C). This sequential bypass graft using PTFE and autogenous vein graft is a useful and safe therapeutic option [25].

In this study, we showed that a composite graft combining a PTFE graft and a segment of autogenous vein is a safe and technically simple option in below the knee bypass. Although a large scale study is needed to confirm the long-term patency, the composite graft bypass showed a durable primary patency in the intermediate-term. Although endovascular treatments are being provided as a first-line treatment, the long term durability of endovascular treatments

must be proved especially in chronic long segmental femoropopliteal occlusion. Cautious interpretation of the current results of endovascular treatment in femoropopliteal lesion is needed considering the lesion morphology and length. In addition to current endovascular treatment, bypass surgery with composite graft is an option to treat patients with poor vein quality, especially when other therapeutic options fail.

The major limitations of this study are the retrospective design, the small number of patients, and the short follow-up duration. In addition, all the procedures were performed

by one vascular surgeon in single institution; therefore, the reproducibility of the results should be verified in a larger study.

In conclusion, Infrainguinal arterial bypass with a composite graft combining an autogenous vein and a PTFE graft resulted in an acceptable graft patency. In patients without appropriate autogenous vein graft, a composite graft can be used. Even if the vein graft is not of adequate length, a short segment of autogenous vein can be used as a part of composite graft.

REFERENCES

- Hölzenbein TJ, Pomposelli FB Jr, Miller A, Contreras MA, Gibbons GW, Campbell DR, et al. Results of a policy with arm veins used as the first alternative to an unavailable ipsilateral greater saphenous vein for infrainguinal bypass. *J Vasc Surg* 1996;23:130-140.
- Taylor LM Jr, Edwards JM, Brant B, Phinney ES, Porter JM. Autogenous reversed vein bypass for lower extremity ischemia in patients with absent or inadequate greater saphenous vein. *Am J Surg* 1987;153:505-510.
- Londrey GL, Ramsey DE, Hodgson KJ, Barkmeier LD, Sumner DS. Infrapopliteal bypass for severe ischemia: comparison of autogenous vein, composite, and prosthetic grafts. *J Vasc Surg* 1991;13:631-636.
- de Mello AV, Santos CM, Silva JL, Souza MT, Portilho MA, Guimarães AV, et al. In situ saphenous vein arterial bypass for infrainguinal revascularization: initial experience using an open technique. *Int Angiol* 1991;10:126-132.
- Taylor LM Jr, Edwards JM, Porter JM. Present status of reversed vein bypass grafting: five-year results of a modern series. *J Vasc Surg* 1990;11:193-205; discussion 206.
- Leather RP, Shah DM. Experiences with in situ lower extremity saphenous vein bypass procedures. *Surg Annu* 1988;20:257-271.
- Fogle MA, Whittemore AD, Couch NP, Mannick JA. A comparison of in situ and reversed saphenous vein grafts for infrainguinal reconstruction. *J Vasc Surg* 1987;5:46-52.
- Rogers DM, Rhodes EL, Kirkland JS. In situ saphenous vein bypass for occlusive disease in the lower extremity. *Surg Clin North Am* 1986;66:319-331.
- Arvela E, Söderström M, Albäck A, Aho PS, Venermo M, Lepäntalo M. Arm vein conduit vs prosthetic graft in infrainguinal revascularization for critical leg ischemia. *J Vasc Surg* 2010;52:616-623.
- Armstrong PA, Bandyk DF, Wilson JS, Shames ML, Johnson BL, Back MR. Optimizing infrainguinal arm vein bypass patency with duplex ultrasound surveillance and endovascular therapy. *J Vasc Surg* 2004;40:724-730; discussion 731.
- Faries PL, Logerfo FW, Arora S, Pulling MC, Rohan DI, Akbari CM, et al. Arm vein conduit is superior to composite prosthetic-autogenous grafts in lower extremity revascularization. *J Vasc Surg* 2000;31:1119-1127.
- Faries PL, Arora S, Pomposelli FB Jr, Pulling MC, Smakowski P, Rohan DI, et al. The use of arm vein in lower-extremity revascularization: results of 520 procedures performed in eight years. *J Vasc Surg* 2000;31:50-59.
- Sesto ME, Sullivan TM, Hertzner NR, Krajewski LP, O'Hara PJ, Beven EG. Cephalic vein grafts for lower extremity revascularization. *J Vasc Surg* 1992;15:543-549.
- McPhee JT, Barshes NR, Ozaki CK, Nguyen LL, Belkin M. Optimal conduit choice in the absence of single-segment great saphenous vein for below-knee popliteal bypass. *J Vasc Surg* 2012;55:1008-1014.
- Wijesinghe LD, Beardsmore DM, Scott DJ. Polytetrafluoroethylene (PTFE) femorodistal grafts with a distal vein cuff for critical ischaemia. *Eur J Vasc Endovasc Surg* 1998;15:449-453.
- Jakobsen HL, Baekgaard N, Christoffersen JK. Below-knee popliteal and distal bypass with PTFE and vein cuff. *Eur J Vasc Endovasc Surg* 1998;15:327-330.
- Calligaro KD, Syrek JR, Dougherty MJ, Rua I, Raviola CA, DeLaurentis DA. Use of arm and lesser saphenous vein compared with prosthetic grafts for infrapopliteal arterial bypass: are they worth the effort? *J Vasc Surg* 1997;26:919-924; discussion 925-927.
- Parsons RE, Suggs WD, Veith FJ, Sanchez LA, Lyon RT, Marin ML, et al. Polytetrafluoroethylene bypasses to infrapopliteal arteries without cuffs or patches: a better option than amputation in patients without autologous vein. *J Vasc Surg* 1996;23:347-354; discussion 355-356.

- 19) Quiñones-Baldrich WJ, Prego AA, Ucelay-Gomez R, Freischlag JA, Ahn SS, Baker JD, et al. Long-term results of infrainguinal revascularization with polytetrafluoroethylene: a ten-year experience. *J Vasc Surg* 1992;16:209-217.
- 20) Veith FJ, Gupta SK, Ascer E, White-Flores S, Samson RH, Scher LA, et al. Six-year prospective multicenter randomized comparison of autologous saphenous vein and expanded polytetrafluoroethylene grafts in infrainguinal arterial reconstructions. *J Vasc Surg* 1986;3:104-114.
- 21) Lundgren F; Swedish External Support Study (SWEXSUS). External support of a polytetrafluoroethylene graft improves patency for bypass to below-knee arteries. *Ann Vasc Surg* 2013;27:1124-1133.
- 22) Takagi H, Goto SN, Matsui M, Manabe H, Umemoto T. A contemporary meta-analysis of Dacron versus polytetrafluoroethylene grafts for femoropopliteal bypass grafting. *J Vasc Surg* 2010;52:232-236.
- 23) Feinberg RL, Winter RP, Wheeler JR, Gregory RT, Snyder SO Jr, Gayle RG, et al. The use of composite grafts in femorocrural bypasses performed for limb salvage: a review of 108 consecutive cases and comparison with 57 in situ saphenous vein bypasses. *J Vasc Surg* 1990;12:257-263.
- 24) Perler BA, Burdick JF, Williams GM. The multiple sequential distal bypass graft: seven-year follow-up. *J Vasc Surg* 1987;6:296-300.
- 25) Mahmood A, Garnham A, Sintler M, Smith SR, Vohra RK, Simms MH. Composite sequential grafts for femorocrural bypass reconstruction: experience with a modified technique. *J Vasc Surg* 2002;36:772-778.