

Case Report

Pure divergent dislocation of the index and middle finger carpometacarpal joints: A rare case

A. Zaizi^{a,*}, T. El Yaacoubi^a, A. El Bahraouy^a, O. Zamani^b, J. Boukhris^a, S. Bouabid^a, M. Boussouga^a

^a Department of Orthopaedic Surgery & Traumatology II, Military Hospital Mohammed V, Rabat 10100, Morocco

^b Department of Radiology, Military Hospital Mohammed V, Rabat 10100, Morocco

ARTICLE INFO

Keywords:

Carpometacarpal joint
Divergent
Dislocation
Hand
Wrist

ABSTRACT

A pure divergent dislocation involving the index and middle finger carpometacarpal joints is an extremely rare injury. We present a case of 21-year-old military man, victim of a motor vehicle accident, admitted at the emergency department unable to move his left hand with major swelling. X-rays and CT scan showed a dorsal dislocation of second and palmar dislocation of the third carpometacarpal joints without associated fracture. In the Operating room under general anesthesia, patient underwent closed reduction and internal fixation with percutaneous K-Wires followed by cast immobilization during 6 weeks. Physiotherapy was started progressively after k-wires removal. At two months follow-up, results were excellent and patient has recovered all of his range of motion and hand activities, at one-year follow-up he was able to perform all military exercises such as pumping and climbing.

Introduction

Hand injuries are frequent following motor or bike accidents, they are usually metacarpal or phalangeal fractures, rarely interphalangeus or metacarpophalangeal dislocation, even rarer carpometacarpal (CMC) dislocations that represent less than 1% of all hand injuries. Only few cases of divergent carpometacarpal joint dislocations were reported, cases between major and auricular fingers third and fourth, auricular and little finger fourth and fifth and case involving divergent dislocation between the index and the three ulnar fingers carpometacarpal joints. But divergent dislocation between second and third CMC joints in our knowledge was never reported until our observation that report the mechanism of injury, clinical presentation, management, anatomic and functional results.

Case report

A 21-year old military man, was injured at his left hand following a motorbike accident against back of a car during sudden stop, he kept holding the handle brake until the collision. He was transported to the emergency department feeling a severe pain in the right foot and left hand. There was big swelling with a tenderness at the left hand without neurovascular deficiencies or skin wound. The anteroposterior radiograph of the hand showed loss of parallelism and apparent shortening of the second and third metacarpals. Lateral radiograph showed complete dorsal dislocation of the second metacarpal base against divergent dislocation of the third

* Corresponding author.

E-mail address: Dr.abderra@gmail.com (A. Zaizi).

<https://doi.org/10.1016/j.tcr.2019.100222>

Accepted 7 July 2019

Available online 18 July 2019

2352-6440/ © 2019 The Authors. Published by Elsevier Ltd. This is an open access article under the CC BY-NC-ND license (<http://creativecommons.org/licenses/by-nc-nd/4.0/>).

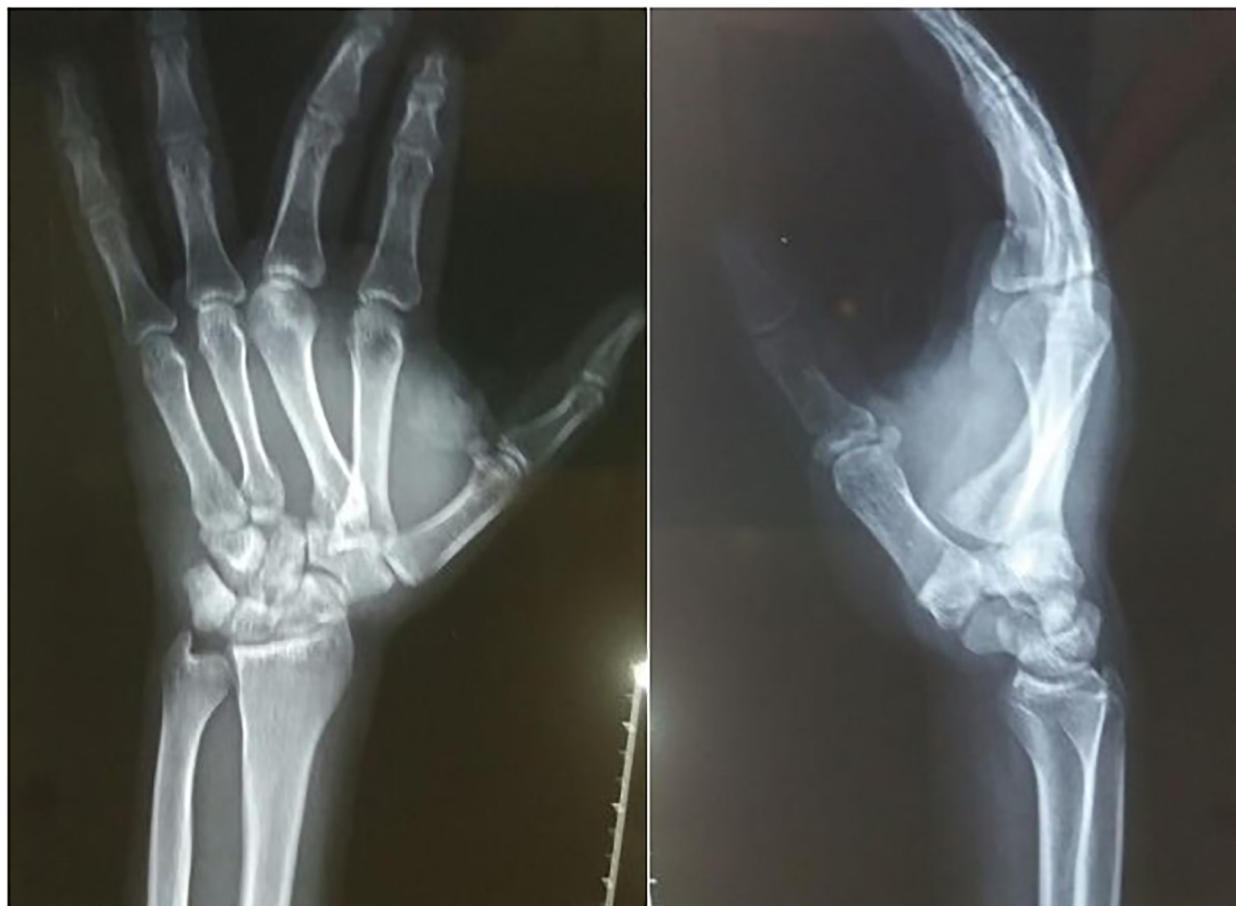

Fig. 1. X-rays showing divergent dislocation of 2nd and 3rd CMC joint (dorsal displacement of 2nd and palmar displacement of 3rd CMC joint).

metacarpal base in volar direction, without any associated fracture (Fig. 1). CT scan showed well directions of the two dislocations and eliminate any additional lesion (Fig. 2). Under general anesthesia and supine position, surgeon reduced the dislocation by applying longitudinal traction to the index and middle fingers with pressure over the base of the dislocated metacarpals while a second surgeon applied a counter traction to the forearm. A fluoroscopic check indicated appropriate metacarpals alignment and wrist joints reduction, then dislocations were stabilized with three percutaneous 1.5 mm K-wires; two longitudinally across the carpometacarpal joints and one transversal intermetacarpal. Postoperative X-rays revealed excellent reduction and alignment of the CMC joints (Fig. 3).

A plaster cast keeping wrist in neutral position was applied for 6 weeks. Then Kirshner wires and plaster cast were removed, followed by progressive physiotherapy for 4 weeks. X-rays were performed during follow-up to ensure the absence of redislocation. At two months follow-up, results were excellent and patient has recovered all of his range of motion and hand activities, after one-year follow-up clinical and radiological control showed no recurrence of CMC instability (Fig. 4) nor reduced strength of the hand, no chronic pain and no signs of osteoarthritis of CMC joints were observed, he was able to perform all military exercises such as pumping and climbing (Fig. 5).

Discussion

Divergent carpometacarpal dislocations between two metacarpals are very rare orthopedic injuries with only four reported cases, described first by Hartwig in 1979, Gunther in 1985, Busa in 1998 and Dillon in 2005 [1–5]. But pure divergent dislocation involving the second and third CMC was never reported to our knowledge, because of their strong stabilizers provided by dorsal, volar and transverse metacarpal ligaments and long flexors and extensors of hand along with the intrinsic muscles and geometry of the articular surfaces of CMC joints.

These injuries occur mainly in young adults, the main etiologies are a high-energy trauma following a road traffic accident essentially motorbike accidents [5,6]. It is difficult to explain the exact mechanism of the CMC joints dislocations; the most likely mechanism is a palmar force transmitted through the metacarpal shaft or metacarpal base from the handles of a motorcycle during the impact leading to dorsal dislocation of the low stronger CMC joints usually the fourth and fifth ones. Therefore, the divergent

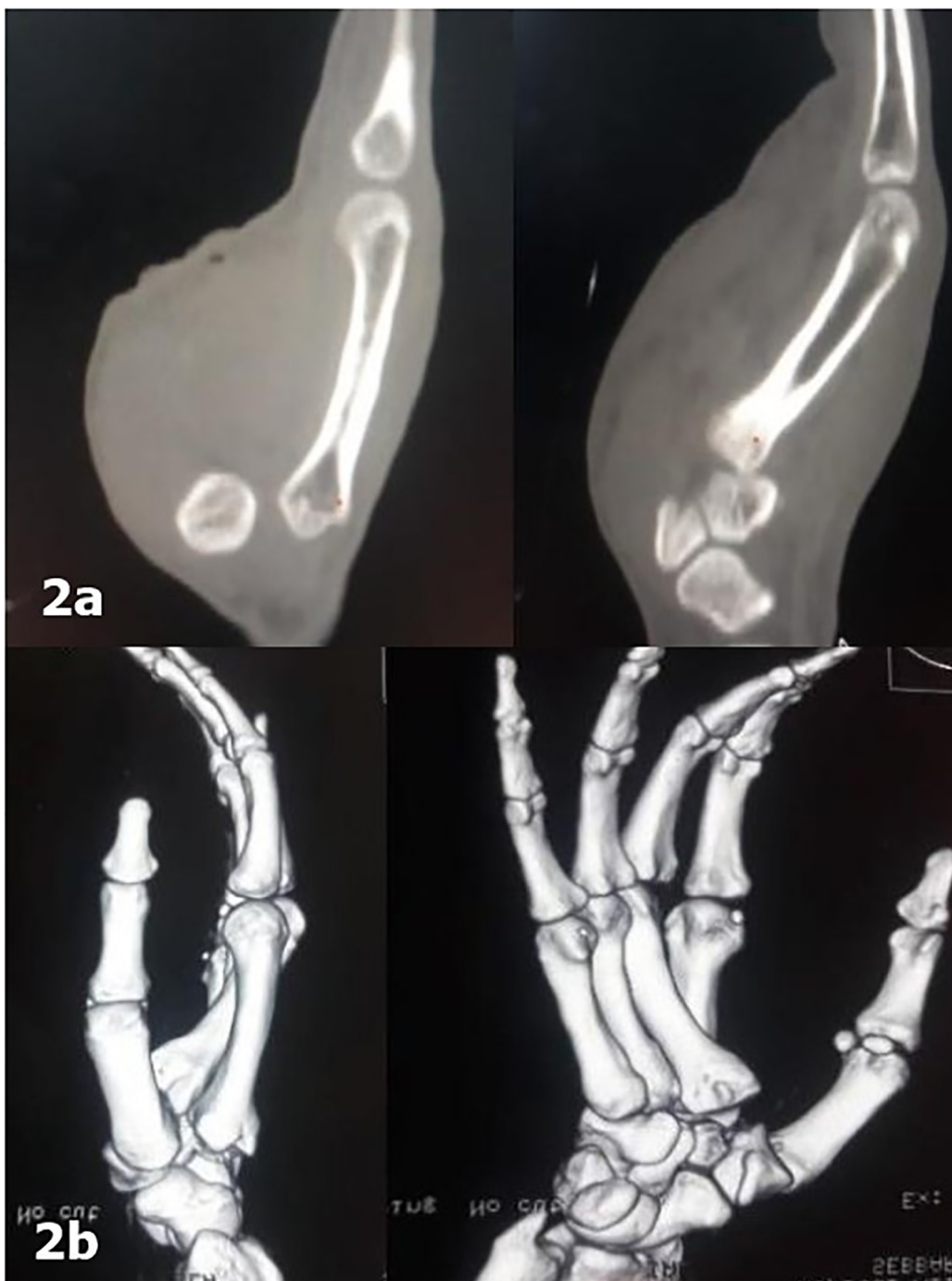

Fig. 2. Sagittal (a) and 3D CT-scan (b) showing divergent dislocation of 2nd and 3rd CMC joint.

dislocation is very complicated to produce, they need multiple forces to the hand including deceleration and rotation, even more enough forces to dislocate the keystone of the hand corresponding to the third CMC joint [8]. Gunther suspected a torsional force pushing the carpus to rotate on a fixed metacarpal base with the hand firmly fixed on the motorbike handle [7].

Anteroposterior radiographs showed apparent shortening of metacarpals and loss of parallelism between metacarpal bases and carpal bones, but CMC dislocation can be concealed by overlapping of the joints. A strict lateral X-ray view of the hand confirms the diagnosis, sometimes additional oblique radiographs can be useful.

CT scan should be performed to confirm diagnosis and exclude associated fractures of the hand and the wrist. In the context of a polytrauma concomitant injuries take more attention of clinicians in the ED, and lead to misdiagnosis or delayed management of the

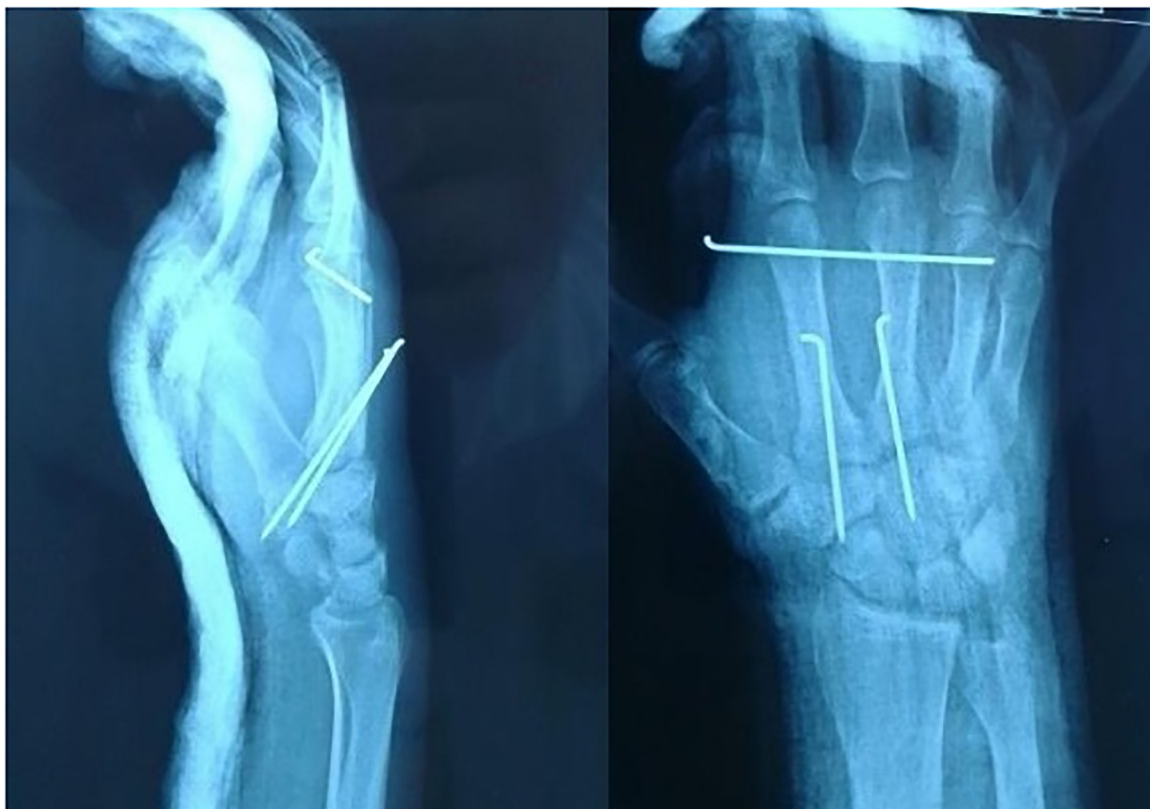


Fig. 3. Postoperative X-rays showing good reduction and percutaneous K-wires.

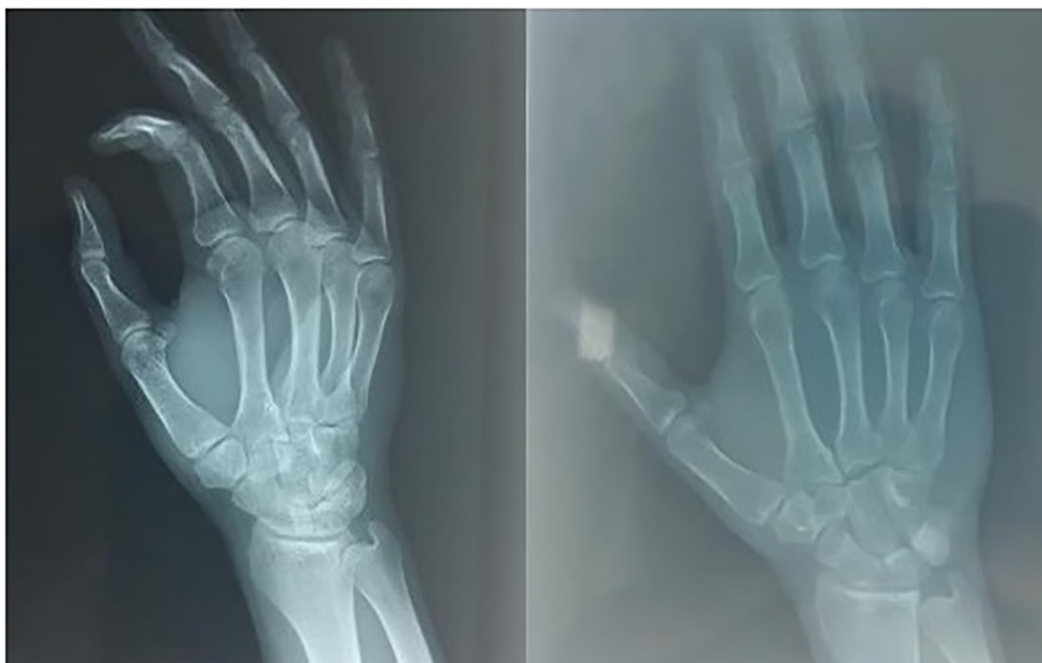

Fig. 4. Hand X-rays after K wires removal.

hand injury. In our case there was no associated or vital trauma, the diagnosis was easier and treatment was urgent by closed reduction. The choice of treatment depends on the severity and stability of the CMC joints, and the time of the hand injury

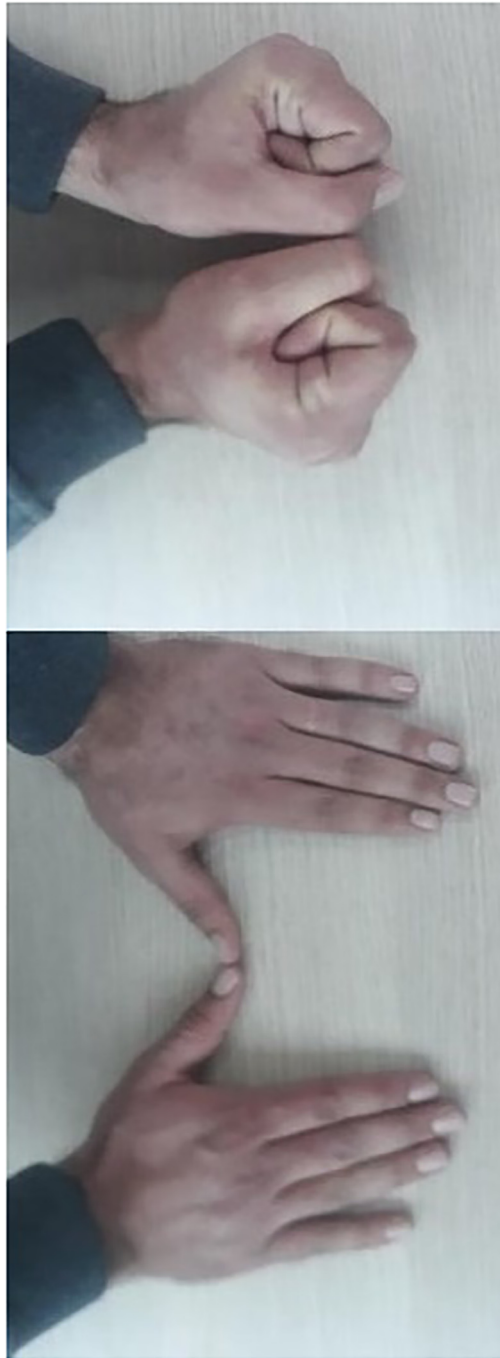

Fig. 5. Clinical images showing normal anatomy and hand function.

management, closed reduction is usually possible when the dislocation is recent and of less than 10 days. However, old dislocation of nearly 15 days open reduction is required and best achieved by the dorsal approach. Cases presenting very late and or features of degenerative changes may have to be arthrodesed, there is a high risk of redislocation after closed reduction, as compared to open reduction. Many authors recommend open reduction especially in an associated fracture to guarantee anatomic reduction.

Lawlis and Gunther demonstrated that results obtained after CMC dislocation of the four rays were better than those obtained in patients who had dislocated the second and third rays [9]. Moreover, complications such as the persistence of residual pain of the hand, a decrease in grip strength, subluxations, secondary displacements, and osteoarthritis have been reported in the literature [10].

Physiotherapy of hand and wrist joints is crucial to avoid postoperative stiffness and improved grip strength, prevent osteoarthritis and improve muscle function.

Consent

Patient gives informed consent for publication.

Declaration of Competing Interest

The authors report no conflicts of interest. The authors alone are responsible for the content and writing of the paper.

Acknowledgements

This research received no specific grant from any funding agency in the public, commercial, or not-for-profit sectors.

References

- [1] R. Kumar, R. Malhotra, Divergent fracture-dislocation of the second carpometacarpal joint and the three ulnar carpometacarpal joints, *J. Hand Surg.* 26 (1) (2001) 123–129.
- [2] R.H. Hartwig, D.S. Louis, Multiple carpometacarpal dislocations: a review of four cases, *J. Bone Joint Surg.* 61 (6A) (1979) 906–908.
- [3] S.F. Gunther, P.D. Bruno, Divergent dislocation of the carpometacarpal joints: a case report, *J. Hand Surg.* 10A (1985) 197–201.
- [4] R. Busa, G. Internullo, A. Caroli, Divergent dislocation of the fourth and fifth carpometacarpal joints, *J. Hand Surg.* 23 (3) (1998) 529–531.
- [5] J. Dillon, J. Street, K. Mahalingham, Divergent dislocation of the ring and little finger carpometacarpal joints—a rare injury pattern, *Acta Orthop. Belg.* 71 (3) (2005) 353–356.
- [6] L.Z. Jilani, M. Abbas, S. Goel, M.N. Akhtar, Multiple volar dislocations of the carpometacarpal joints with an associated fracture of the first metacarpal base, *Chin. J. Traumatol.* 17 (1) (2014) 38–40.
- [7] G. Silk, N. Vetharajan, H. Nagata, Volar dislocation of the second and third carpometacarpal joints – the Lisfranc injury of the hand? *Hand Surg. Rehabil.* 37 (5) (2018) 320–323.
- [8] S.F. Gunther, The carpometacarpal joints, *Orthop. Clin. North Am.* 15 (1984) 259–277.
- [9] J.F. Lawlis, S.F. Gunther, Carpometacarpal dislocations. Long-term follow up, *J. Bone Joint Surg.* 73 (1) (1991) 52–59.
- [10] A. Das, S. Mishra, D. Panda, Clinical outcomes in management of dislocation of carpometacarpal joints of hand: a rare orthopaedic presentation, *Int. J. Res. Orthop.* 4 (2) (2018) 274–279.