

# Etanercept-induced generalization of chronic, localized, anogenital bullous pemphigoid in a psoriatic patient

Erin N. Wilmer, MD,<sup>a</sup> Nils Becker, MD,<sup>b</sup> Allison Chen, BA,<sup>a</sup> and George Kroumpouzou, MD, PhD<sup>a</sup>  
*Providence, Rhode Island and Lexington, Massachusetts*

**Key words:** anogenital; bullous pemphigoid; drug eruption; etanercept; immunobullous disease; tumor necrosis factor—alpha.

## INTRODUCTION

Up to 20% of cases of bullous pemphigoid (BP) show an atypical presentation, exhibiting localized distribution or non-bullous lesions, such as eczematous, urticarial, prurigo-like, and erythema multiforme-like papules and plaques.<sup>1</sup> These atypical presentations can be associated with a delay in diagnosis and thus require a high degree of suspicion. We present a case of recalcitrant BP localized to the anogenital region with subsequent generalization after administration of etanercept, a tumor necrosis factor—alpha (TNF- $\alpha$ ) inhibitor. Our review of bibliographic databases did not find any cases with similar distribution and course. TNF- $\alpha$  inhibitors are used in the treatment of pemphigus and pemphigoid. With expanding use of TNF- $\alpha$  inhibitors and longer follow-up periods, there are increasing reports of autoimmune diseases associated with these therapies, including autoimmune bullous disease and systemic lupus erythematosus.<sup>2</sup> This case highlights that caution should be exercised when considering anti-TNF- $\alpha$  therapy for autoimmune bullous diseases.

## CASE REPORT

A 79-year-old white woman with a history of psoriasis and diabetes type 2 presented with recalcitrant, perianal/perineal, and perivaginal inflammatory erosions that were unresponsive to potent topical corticosteroids (Fig 1). Biopsy found lichenoid interface dermatitis with eosinophils and a subepidermal cleft. Direct immunofluorescence results (DIF) were negative. The histopathologic

### Abbreviations used:

BP: bullous pemphigoid  
 DIF: direct immunofluorescence  
 TNF- $\alpha$ : tumor necrosis factor—alpha

differential diagnosis included a lichenoid hypersensitivity reaction, lichenoid contact dermatitis, and a primary immunobullous disorder, likely BP. Laboratory testing found normal serology findings, with the exception of mild eosinophilia (0.67 K/ $\mu$ L; normal, <0.45 K/ $\mu$ L), and a normal urinalysis result. The eruption did not respond to courses of hydroxychloroquine, mycophenolate mofetil, and oral antibiotics or narrowband ultraviolet light B and aminolevulinic acid photodynamic therapy. Oral corticosteroid tapers provided only temporary benefit, and diabetes was a contraindication to longer systemic steroid treatment.

Lesions remained relatively stable for 16 months, and at that time etanercept was administered for a psoriasis flare. Within 3 days of starting etanercept, the patient had generalized, pruritic, urticarial, and bullous lesions (Fig 2). Biopsy of a bullous lesion on the left upper thigh found a subepidermal blister with eosinophils (Fig 3). DIF of perilesional skin of both the right arm and perianal area found linear C3 and IgG at the dermal—epidermal junction (Fig 4). There was no IgA or IgM deposition. A salt-split skin immunofluorescence study on the perianal specimen found IgG and C3 localized to the blister roof, confirming the diagnosis of BP and ruling out epidermolysis bullosa acquisita. The patient was

Brown University Department of Dermatology<sup>a</sup> and StrataDx.<sup>b</sup>

Funding sources: None.

Conflicts of interest: None declared.

This case was presented at a Meeting of the New England Dermatological Society at Brown University on October 31, 2015.

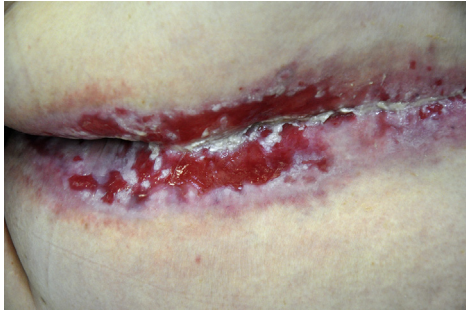Correspondence to: George Kroumpouzou, MD, PhD, 593 Eddy Street, APC 10, Providence, RI 02903. E-mail: [gk@gkderm.com](mailto:gk@gkderm.com).

JAAD Case Reports 2016;2:25-7.

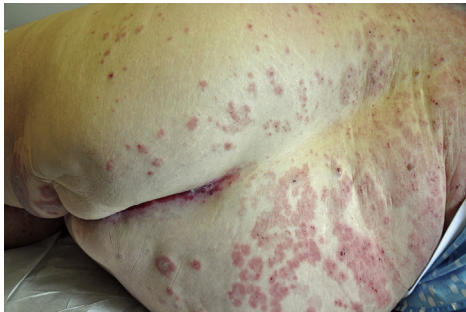2352-5126

© 2015 by the American Academy of Dermatology, Inc. Published by Elsevier, Inc. This is an open access article under the CC BY-NC-ND license (<http://creativecommons.org/licenses/by-nc-nd/4.0/>).

<http://dx.doi.org/10.1016/j.jidcr.2015.12.006>



**Fig 1.** Large, confluent erosions in the perianal/perineal area and midgluteal fold.



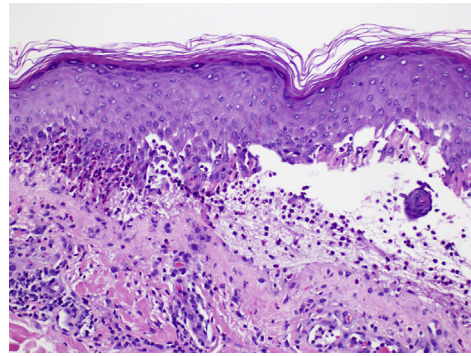
**Fig 2.** Generalized pruritic, urticarial and bullous lesions developed immediately after starting etanercept.

treated successfully with dapsone, with new bulla formation ceasing 3 weeks into dapsone treatment at 100 mg/d. The lesions and pruritus further improved at a dapsone dose of 150 mg/d.

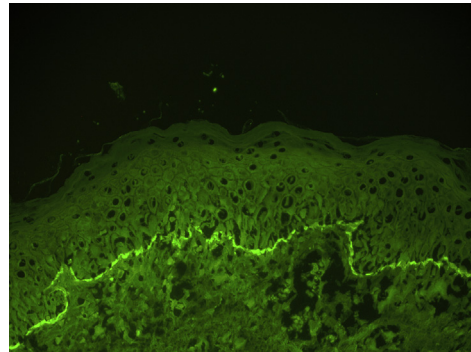
## DISCUSSION

Localized BP is uncommon and requires a high index of suspicion.<sup>1</sup> There are rare reports of pediatric genital BP and 1 report of perineal/perianal BP in an adult.<sup>3,4</sup> Adult BP localized to both perianal/perineal and perivaginal areas, such as that seen in our patient, is an exceedingly rare presentation. The differential diagnosis of BP localized to the genital and perianal area includes lichen sclerosus et atrophicus, irritant dermatitis, intertrigo, bullous lichen planus, and immunobullous diseases, such as pemphigus vulgaris and epidermolysis bullosa acquisita. The clinical course, histology, and immunofluorescence studies help differentiate among these entities. In this case, the original DIF result of the perianal eruption was negative, possibly because of concomitant use of topical corticosteroids. Repeat DIF after a period of nonsteroid use is indicated if BP is suspected and the initial DIF result is negative.

TNF- $\alpha$  inhibitors have been used for the treatment of autoimmune bullous diseases; however, there are rare reports of paradoxical development of pemphigus and BP during anti-TNF- $\alpha$  therapy.<sup>5-10</sup>



**Fig 3.** Biopsy section of a bullous lesion on the left upper thigh shows a subepidermal blister with prominent eosinophils. (Hematoxylin-eosin stain; original magnification,  $\times 200$ ).



**Fig 4.** DIF: linear C3 deposition at the dermal-epidermal junction. (Original magnification,  $\times 100$ ).

In each of these cases, BP developed months to years after initiation of TNF- $\alpha$  inhibitor treatment, in contrast to this case in which localized BP generalized immediately after administration of an anti-TNF- $\alpha$  agent. In our case, a causal relationship between etanercept and generalized BP is supported by the onset of generalization immediately after etanercept administration and improvement of the eruption after discontinuation of the drug. Furthermore, this finding is supported by similar reports in the literature.<sup>5,10</sup> Case reports of pemphigus and BP induced by TNF- $\alpha$  inhibitors indicate that patients achieved both clinical and serologic remission after cessation of the TNF- $\alpha$  inhibitor. In a case of etanercept-induced BP, the presence of circulating autoantibodies against the BP180 antigen decreased into the normal range after removal of the offending biologic drug.<sup>10</sup> Similarly, Boussemart et al<sup>8</sup> reported a case of infliximab-associated pemphigus foliaceus with normalization of antidesmoglein 1 autoantibodies after cessation of infliximab therapy. Rechallenge in select patients resulted in re-emergence of pemphigus/pemphigoid.<sup>6,10</sup>

The pathogenetic mechanism of TNF- $\alpha$  inhibitor-induced BP has yet to be deciphered, although several hypotheses exist. TNF- $\alpha$  appears to play an important role in BP, as abnormal levels of TNF- $\alpha$  have been identified in the serum and blister fluid of patients, and serum TNF- $\alpha$  levels correlate with disease severity.<sup>8</sup> Liu et al<sup>11</sup> found that TNF- $\alpha$  can drive eosinophils to secrete either helper T cell (Th)1 or Th2 cytokines, depending on the chemokine profile of the microenvironment.<sup>11</sup> Thus, an individual's unique inflammatory state may affect the downstream consequences of TNF- $\alpha$  inhibition and can explain the ability of anti-TNF agents to both treat and promote BP. TNF- $\alpha$  inhibitors may also alter the regulatory T-cell function, leading to loss of B-cell suppression and promotion of autoantibody production. Another theory is that TNF- $\alpha$  inhibitors may act as haptens that alter basement membrane proteins and render them susceptible to immune attack.<sup>12</sup> In this case, it is possible that exposure of the BP180 antigen or the inflammatory microenvironment in the eroded anogenital plaques may have hastened the immune response generated by etanercept, resulting in almost immediate generalization. Further studies are needed to better elucidate the mechanism of action of TNF- $\alpha$  inhibitors and to determine how the cytokine milieu may affect TNF-induced alterations in Th1/Th2 balance.

This case highlights that treatment with TNF- $\alpha$  inhibitors can be associated with generalization of localized BP. Caution should be exercised when contemplating anti-TNF- $\alpha$  therapy for the treatment of autoimmune bullous disorders. Additionally, TNF- $\alpha$  inhibitors should be considered in the etiologies of autoimmune bullous disease.

#### REFERENCES

1. della Torre R, Combesure C, Cortés B, et al. Clinical presentation and diagnostic delay in bullous pemphigoid: a prospective nationwide cohort. *Br J Dermatol*. 2012;167:1111-1117.
2. Ramos-Casals M, Brito-Zerón P, Soto MJ, Cuadrado MJ, Khamashta MA. Autoimmune diseases induced by TNF-targeted therapies. *Best Pract Res Clin Rheumatol*. 2008;22:847-861.
3. Patsatsi A, Lazaridou E, Papagaryfallou I, Sotiriadis D. Bullous pemphigoid of the perineum and perianal area: a rare localized form in adults. *Acta Derm Venereol*. 2008;88:401.
4. Farrell AM, Kirtschig G, Dalziel KL, et al. Childhood vulval pemphigoid: a clinical and immunopathological study of five patients. *Br J Dermatol*. 1999;140:308-312.
5. Bordignon M, Belloni-Fortina A, Pigozzi B, Tarantello M, Alaibac M. Bullous pemphigoid during long-term TNF-alpha blocker therapy. *Dermatology*. 2009;219:357-358.
6. Daulat S, Detweiler JG, Pandya AG. Development of pemphigus vulgaris in a patient with psoriasis treated with etanercept. *J Eur Acad Dermatol Venereol*. 2009;23:483-484.
7. Stausbøl-Grøn B, Deleuran M, Sommer Hansen E, Kragballe K. Development of bullous pemphigoid during treatment of psoriasis with adalimumab. *Clin Exp Dermatol*. 2009;34:e285-e286.
8. Boussemart L, Jacobelli S, Batteux F, et al. Autoimmune bullous skin diseases occurring under anti-tumor necrosis factor therapy: two case reports. *Dermatology*. 2010;221:201-205.
9. Kluk J, Goulding JM, Bhat J, Finch TM. Drug-induced bullous pemphigoid: cases triggered by intravenous iodine and etanercept. *Clin Exp Dermatol*. 2011;36:871-873.
10. Mochizuki M, Fujine E, Tawada C, Kanoh H, Seishima M. Pemphigoid nodularis possibly induced by etanercept. *J Dermatol*. 2013;40:578-579.
11. Liu LY, Bates ME, Jarjour NN, Busse WW, Bertics PJ, Kelly EA. Generation of Th1 and Th2 chemokines by human eosinophils: evidence for a critical role of TNF-alpha. *J Immunol*. 2007;179:4840-4848.
12. Stavropoulos PG, Soura E, Antoniou C. Drug-induced pemphigoid: a review of the literature. *J Eur Acad Dermatol Venereol*. 2014;28:1133-1140.