

EP CASE REPORT

doi:10.1093/europace/euz153

Usefulness of high-definition propagation and voltage map in atrial macro-reentrant tachycardia

Roberto Mantovan*, Leonardo Corò, Giuseppe Allocca, Nadir Sitta, and Luigi Rivetti

Department of Cardiology, "S. Maria dei Battuti" Hospital, AULSS 2 Veneto, Via Brigata Bisagno, Conegliano (TV), Italy

* Corresponding author. Tel: +39 0438 663613; fax: +39 0438 663759. E-mail address: rmantovan@alice.it

A 58-year-old man presented for radiofrequency (RF) ablation of atypical incessant flutter (AAF) (Supplementary material online, Figure S1A and B). He had previously undergone two procedures for the ablation of paroxysmal atrial fibrillation (AF) with extensive isolation of pulmonary veins (PVI) 8 and 6 years earlier, with no recurrence of AF.

The AAF was mapped with the Orion™ multipolar basket catheter, the Rhythmia three-dimensional electroanatomic mapping system (Boston Scientific, USA) and a decapolar diagnostic catheter (Livewire, Abbott, USA) positioned at the coronary sinus. A standard ablation catheter was used for RF ablation (IntellaTip, Boston Scientific, USA).

The voltage map revealed a wide area of low voltages around the four pulmonary veins. Ultra-high-resolution activation mapping showed a macro-reentry with cranio-caudal activation of the posterior wall of the left atrium and a clear point of slow conduction able to maintain the circuit. In contrast, double potentials were evident over the whole posterior wall adjacent to the slowing area, indicating a conduction block (Figure 1A and B).

Radiofrequency delivery to the slow conduction area interrupted the arrhythmia in a few seconds (Supplementary material online, Video S1). The ablation catheter recorded low-quality electrogram signals, with no prolonged duration at the actual ablation spot. Therefore, additional RF deliveries to this spot were performed in order to consolidate the lesion. No entrainment manoeuvres were performed. The

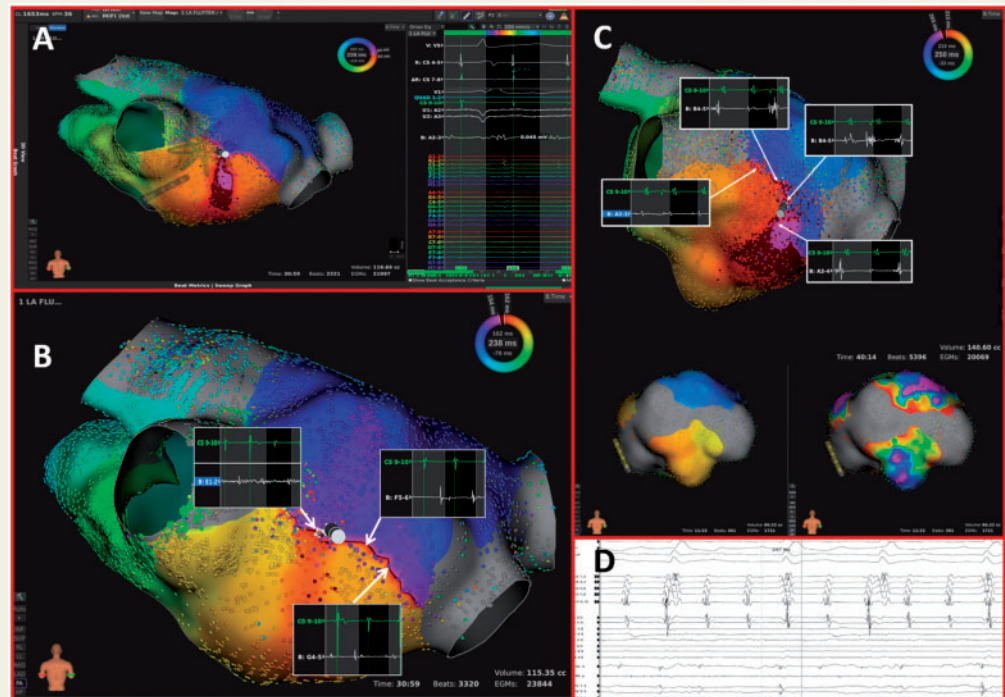


Figure 1 (A) Ultra-high-resolution activation mapping revealed a macro-reentry with cranio-caudal activation of the posterior wall of the left atrium and a clear point of slow conduction able to maintain the circuit. (B) Double potentials along the whole posterior wall adjacent to the slowing area, indicating a conduction block. (C) Line of spaced double potentials/no potentials extending laterally to the critical isthmus and continuous line of block along the posterior wall of the atrium, validated through the Orion catheter. (D) Signals recorded at the actual ablation spot through the ablation catheter.

arrhythmia was no longer inducible at the end of the procedure. After a few weeks, the arrhythmia recurred with the same morphology, cycle and activation pattern ([Supplementary material online, Figure S2A and B](#)) and a new ablation procedure was scheduled.

The voltage map was similar to that of the first procedure. The activation map revealed an isthmus of markedly slowed conduction located close to the right pulmonary veins, while a line of spaced double potentials or absence of potentials extended laterally to the critical isthmus ([Figure 1C](#)). The arrhythmia was interrupted after a few seconds of delivery ([Supplementary material online, Video S2](#)), and a continuous line of block was created along the posterior wall of the atrium and validated by means of the Orion catheter ([Figure 1C](#)). Also in this case, the ablation catheter did not show any significant signals at the ablation spot ([Figure 1D](#)). The patient remained free from AAF recurrence and symptoms after 6-month follow-up.

In our case, high-definition mapping was pivotal in detecting the critical isthmus and the residual slow conduction area, while the ablation catheter recording could not lead to an effective ablation. PVI with extensive encircling of the pulmonary veins may favour subsequent atrial macro-reentry; targeted lesions in a few small areas may therefore be sufficient to ensure procedural success and prevent post-procedural arrhythmic occurrences.

Interestingly, in the present case, we were not able to precisely identify the critical site(s) of arrhythmia conduction by using a standard ablation catheter, owing to the absence of a clearly detectable local signal. The presence of double potentials during AAF may represent only 'functional' areas of block. Interrupting AAF by means of RF and achieving its non-inducibility do not seem to be sufficient endpoints for a lasting successful result. Thus, it is necessary to create a continuous line of block across the whole anatomical isthmus that determines the arrhythmia conduction.

In conclusion, ultra-high-resolution mapping seems to be of primary importance in patients who have undergone extensive catheter ablation for the treatment of AF or who have substrate-related atrial tachycardia.

[Supplementary material](#) is available at *Europace* online.

Funding

This paper was published as part of a supplement supported by a grant by Boston Scientific Italy.

Conflict of interest: none declared.