



Surgical Experience with Descending Necrotizing Mediastinitis: A Retrospective Analysis at a Single Center

Ju Sik Yun, M.D.^{1,*}, Cho Hee Lee, M.D.^{2,*}, Kook Joo Na, M.D., Ph.D.¹, Sang Yun Song, M.D., Ph.D.¹, Sang Gi Oh, M.D., Ph.D.², In Seok Jeong, M.D., Ph.D.²

¹Department of Thoracic and Cardiovascular Surgery, Chonnam National University Hwasun Hospital, Chonnam National University Medical School, Hwasun;

²Department of Thoracic and Cardiovascular Surgery, Chonnam National University Hospital, Chonnam National University Medical School, Gwangju, Korea

ARTICLE INFO

Received October 6, 2022

Revised November 4, 2022

Accepted November 7, 2022

Corresponding author

Kook Joo Na

Tel 82-61-379-7662

Fax 82-61-379-7665

E-mail kjna1125@hanmail.net

ORCID

<https://orcid.org/0000-0003-0923-1414>

*These two authors contributed equally to this work as first authors.

[†]This article was presented at the 54th Autumn Annual Meeting of the Korean Society for Thoracic and Cardiovascular Surgery in Pyoungchang, Korea, November 3–5, 2022.

Background: We analyzed our experience with descending necrotizing mediastinitis (DNM) treatment and investigated the efficacy of video-assisted thoracoscopic surgery (VATS) for mediastinal drainage.

Methods: This retrospective analysis included patients who underwent surgical drainage for DNM at our hospital from 2005 to 2020. We analyzed patients' baseline characteristics, surgical data, and perioperative outcomes and compared them according to the mediastinal drainage approach among patients with type II DNM.

Results: Twenty-five patients (male-to-female ratio, 18:7) with a mean age of 54.0±12.9 years were enrolled in this study. The most common infection sources were pharyngeal infections (60%). Most patients had significantly increased white blood cell counts, elevated C-reactive protein levels, and decreased albumin levels on admission. The most common DNM type was type IIB (n=16, 64%), while 5 and 4 patients had types I and IIA, respectively. For mediastinal drainage, the transcervical approach was used in 15 patients and the trans-thoracic approach (VATS) in 10 patients. The mean length of hospital stay was 26.5±23.8 days, and the postoperative morbidity and in-hospital mortality rates were 24% and 12%, respectively. No statistically significant differences were found among patients with type II DNM between the transcervical and VATS groups. However, the VATS group showed shorter mean antibiotic therapy duration, drainage duration, and hospital stay length than the transcervical group.

Conclusion: DNM manifested as severe infection requiring long-term inpatient treatment, with a mortality rate of 12%. Thus, active treatment with a multidisciplinary approach is crucial, and mediastinal drainage using VATS is considered relatively safe and effective.

Keywords: Descending necrotizing mediastinitis, Infections, Surgery, Video-assisted thoracic surgery

Introduction

Deep neck infections resulting from odontogenic, pharyngeal, or other causes can spread along the 3 cervical fascial planes to the mediastinum. Descending necrotizing mediastinitis (DNM) is a serious progressive infectious disease caused by descending deep neck infections, which, although not prevalent, can lead to the development of sepsis and often fatal outcomes.

The diagnostic criteria for DNM, presented by Estrera et al. [1] in 1983 based on their experience with the treat-

ment of patients with mediastinitis as a complication of oropharyngeal infections, are as follows: (1) clinical signs of severe cervical infection, (2) presence of characteristic radiographic features of mediastinitis, (3) confirmed necrotizing mediastinal infection during surgery or postmortem examination or both, and (4) an established relationship between the oropharyngeal infection and the development of the necrotizing mediastinal process.

Endo et al. [2] provided treatment recommendations with DNM classified according to the anatomical extent of the infection; however, no definitive treatment method



for DNM has yet been established. In particular, although transcervical mediastinal drainage is usually performed, debate continues regarding whether additional drainage is required and what method should be implemented. Despite recent advances in antibiotic therapy and diagnostic and treatment techniques, many studies still have explored effective surgical drainage techniques due to the rapidly progressive nature of the disease, which leads to a swift deterioration of the patient's condition.

Therefore, in this study, we analyzed our experience treating patients with DNM at our hospital and examined the efficacy of transthoracic mediastinal drainage using video-assisted thoracoscopic surgery (VATS) in comparison with transcervical mediastinal drainage.

Methods

Study design and population

The present study protocol was reviewed and approved by the Institutional Review Board of Chonnam National University Hwasun Hospital, which waived the requirement for informed patient consent based on the retrospective nature of the work (approval no., CNUHH-2022-179).

We retrospectively reviewed the records of 27 patients who underwent mediastinal drainage at the Department of Thoracic Surgery and cervical drainage at the Department of Otolaryngology of our hospital from 2005 to 2020. Twenty-five patients who underwent surgery under the diagnosis of DNM were included in the analysis, while those in whom the mediastinal infection was due to other causes (esophageal cancer in 1 case and phlegmonous esophagitis in 1 case) were excluded.

All patients underwent neck and chest contrast-enhanced computed tomography (CT) before surgery to confirm the diagnosis of DNM based on the aforementioned diagnostic criteria and to evaluate the extent of the infection. Based on the CT findings and according to the Endo classification, DNM was classified as type I (localized in the upper mediastinum above the tracheal bifurcation), type IIA (extending to the lower anterior mediastinum), or type IIB (extending to the lower anterior and posterior mediastinum). If DNM was confirmed, emergency surgery was performed as soon as possible.

Surgical treatment

Cervical drainage was performed at the Department of Otolaryngology through a collar incision with multiple

drainage tips. In most cases, closed wound drainage was performed, but in some cases, open wound drainage was maintained for postoperative irrigation and dressing. Mediastinal drainage was performed at the Department of Thoracic Surgery. Until 2013, it was performed using the transcervical approach for all patients with DNM. Thereafter, the approach was determined according to the Endo classification: transcervical for patients with type I DNM and transthoracic using VATS for patients with type II DNM. For reference, VATS was introduced in our hospital in the late 1990s and has been actively applied in various fields, such as lung and esophageal cancers, since the early 2000s.

Transcervical mediastinal drainage was performed through a collar incision made at the Department of Otolaryngology. Based on the CT findings, the space through which the infection descended within the mediastinum was dissected using fingers, and a nasogastric or chest tube was placed. Transthoracic mediastinal drainage was performed using VATS. The right-sided approach was used, mainly using three ports (11-mm ×1, 5-mm ×2). The right-sided approach was preferred because the upper mediastinal and lower paraesophageal space could be easily accessed at the same time. No particular difficulty was experienced during the operation. In the paraesophageal space, the most common mediastinitis location, the upper mediastinal pleura was opened first above the azygos vein, and the lower mediastinal pleura was opened below the inferior pulmonary vein or at the carina level. The procedure was performed as carefully as possible to avoid injuring the trachea and esophagus. After evacuating the pus and performing sufficient irrigation, chest tubes were inserted through the mediastinal pleura openings and positioned to drain adequately even after surgery (Fig. 1). In the case of mediastinitis with pleural effusion or involvement of the anterior mediastinal (substernal) space, the tube was placed in a suitable position. All procedures were completed without difficulty, and no cases required conversion to thoracotomy.

Postoperative care

After surgery, patients were transferred to a general ward or the intensive care unit (ICU), depending on their condition. The neck and chest wounds were checked and dressed daily. On average, all patients underwent follow-up neck and chest CT on the sixth day after surgery for reevaluation. Based on the CT findings, it was determined whether additional drainage was required or the drainage tube was removed.

Antibiotic therapy was prescribed based on the results of

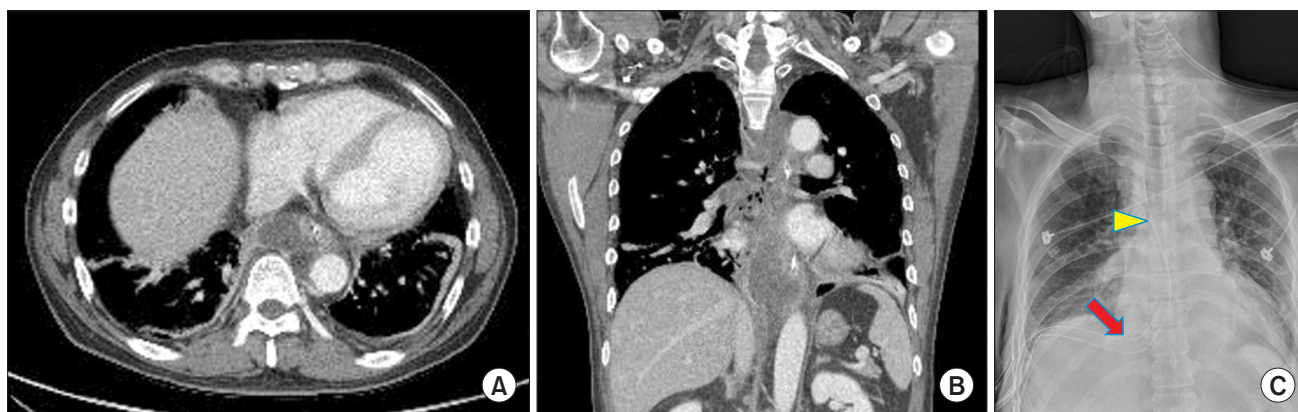


Fig. 1. Representative images of a 50-year-old male patient with Endo type II descending necrotizing mediastinitis. Preoperative axial (A) and coronal (B) computed tomography images show an abscess with gas shading in the prevertebral (paraesophageal) space invading the lower posterior mediastinum. (C) A postoperative chest X-ray obtained immediately after surgery showing the chest tubes located in the upper (arrowhead) and lower (arrow) mediastinal spaces.

the microbiological culture test performed using specimens collected during surgery in consultation with the Department of Infectious Diseases. Therapy was discontinued according to the clinical features and laboratory findings. Patients were discharged when intravenous antibiotic use was not required, and all vital signs had normalized.

Statistical analysis

Data were presented as means with standard deviations or medians with ranges. Categorical variables were compared using the Pearson chi-square test or the 2-tailed Fisher exact test, as appropriate. The t-test was used to compare independent continuous variables. A p-value less than 0.05 was considered to indicate statistical significance. Statistical analyses were performed using IBM SPSS Statistics for Windows ver. 19.0 (IBM Corp., Armonk, NY, USA).

Results

Patients' characteristics

The preoperative baseline characteristics of all patients are shown in Table 1. The patients' median age was 53 years, with a male-to-female ratio of approximately 2:1 (18:7), and diabetes mellitus was the most prevalent underlying disease (24%). The most common sources of infection were pharyngeal and odontogenic infections, accounting for 60% and 28% of cases, respectively. In the other 3 cases, DNM occurred after blunt trauma, acupuncture treatment at an oriental clinic, and the removal of an esophageal foreign body (fishbone).

Table 1. Preoperative baseline characteristics (N=25)

Characteristic	Value
Age (yr)	54.0±12.9 (median, 53)
Sex	
Male	18 (72)
Female	7 (28)
Underlying disease	
Diabetes mellitus	6 (24)
Hypertension	3 (12)
Renal insufficiency	1 (4)
Source of infection	
Odontogenic	7 (28)
Pharyngeal	15 (60)
Other	3 (12)
Time to hospital admission (day)	5.8±3.7 (median, 6)
Laboratory findings	
White blood cell count (/mL)	17,000.0±565.7
C-reactive protein (mg/dL)	25.9±17.4
Albumin (g/dL)	2.6±0.1
Endo classification	
Type I	5 (20)
Type IIA	4 (16)
Type IIB	16 (64)

Values are presented as mean±standard deviation or number (%), unless otherwise indicated.

Most patients presented with sore throat or neck swelling, and the median time from symptom onset to hospital admission was 6 days. On admission, the mean white blood cell count and C-reactive protein (CRP) level were significantly elevated, while albumin levels were decreased, indicating a pre-septic condition or sepsis due to severe inflammation. According to the Endo classification, the most common DNM type on preoperative CT was IIB, with 16 cases (64%).

Surgical approach

In 16 patients diagnosed with deep neck infection and DNM on hospital admission, cervical and mediastinal drainage procedures were performed simultaneously. The remaining 9 patients initially underwent cervical drainage at the Department of Otolaryngology, and mediastinal drainage was performed after DNM was identified on the follow-up CT. Tracheotomy was required in 2 patients to secure the airway. Among the 15 patients who underwent transcervical mediastinal drainage, 10 had type I DNM, and 5 had type II DNM, while all 10 patients who underwent VATS had type II DNM (Table 2).

Postoperative outcomes

Streptococcus viridans was the most frequently isolated etiological agent in 64% of cases. Postoperatively, 13 patients required ICU treatment and were transferred to a

general ward after a mean of 4.5 days. The mean antibiotic therapy duration, drainage duration, and length of hospital stay were 24.8, 17, and 26.5 days, respectively. Reoperation was performed in 2 patients for mediastinal drainage (infection had progressed to the anterior mediastinal space postoperatively in 1 patient, and infection-related bleeding occurred in the other patient) and 3 patients for cervical drainage. Postoperative complications occurred in 6 patients: 1 case each of pericardial effusion, wound infection, arrhythmia, and infection-related bleeding, and 2 cases of pneumonia with acute respiratory distress syndrome. In the last 3 patients, the complications resulted in in-hospital death, with a mortality rate of 12%. One patient with infection-related bleeding had recurrent bleeding despite 3 reoperations. Of the 2 patients with pneumonia and acute respiratory distress syndrome, 1 was the oldest patient (80 years old), and the other was a 49-year-old patient who had severe sepsis since admission and died within 5 days after surgery (Table 2).

Table 2. Surgical data and perioperative outcomes (N=25)

Variable	Value
Microbiological culture	
<i>Streptococcus viridans</i>	16 (64)
<i>Acinetobacter baumannii</i>	2 (8)
Other ^{a)}	7 (28)
Mediastinal drainage	
Transthoracic (VATS)	10 (40)
Transcervical	15 (60)
Intensive care unit stay (day) ^{b)}	4.5±7.9
Duration of antibiotic therapy (day)	24.8±19.0
Hospital stay length (day)	26.5±23.8
Drainage duration (day)	17.4±14.1
Morbidity	6 (24)
In-hospital mortality	3 (12)

Values are presented as number (%) or mean±standard deviation, unless otherwise indicated.

VATS, video-assisted thoracoscopic surgery.

^{a)}In 3 patients, the cultures showed no growth. ^{b)}Among the 25 patients, 13 were admitted to the intensive care unit postoperatively.

Comparison according to the mediastinal drainage approaches

Table 3 shows the comparison of outcomes according to the mediastinal drainage approach in patients with type II DNM. There were no statistically significant differences between the 2 groups; however, the antibiotic therapy duration (8 days), drainage duration (4 days), and hospital stay length (8 days) were shorter in the VATS group than in the transcervical drainage group.

Discussion

DNM is a severe, life-threatening infection with a reported mortality rate of 10%–30% that develops gradually after a deep neck infection [3]. Infections originating in the deep neck space spread to the mediastinum through the retropharyngeal, pretracheal, and prevertebral spaces along

Table 3. Comparison of perioperative outcomes in patients with type II descending necrotizing mediastinitis

Variable	VATS (n=10)	Transcervical (n=10)	p-value
Intensive care unit stay (day)	6.9±8.9	4.1±8.4	0.482
Duration of antibiotic therapy (day)	21.9±7.8	29.8±28.7	0.409
Hospital stay length (day)	23.4±8.2	31.7±36.3	0.490
Drainage duration (day)	14.6±6.1	18.4±21.1	0.590
Morbidity	3 (30)	3 (30)	1.000
In-hospital mortality	2 (20)	1 (10)	1.000

Values are presented as mean±standard deviation or number (%), unless otherwise indicated.

VATS, video-assisted thoracoscopic surgery.

the cervical fascial planes, affected by gravity, respiration, and negative intrathoracic pressure [4,5]. Since not all deep neck infections progress to DNM, prior studies have examined the risk factors. Kimura et al. [6] reported that age ≥ 55 years, a neutrophil-to-lymphocyte ratio ≥ 13 , and a CRP level ≥ 30 mg/dL before deep neck infection treatment were clinical predictors of DNM. In addition, old age, a comorbidity (diabetes), oral intake of glucocorticoids before hospital admission, involvement of 2 or more spaces (particularly the retropharyngeal space), and gas on the initial CT scan were also reported as risk factors for DNM [7,8].

The leading causes of DNM are odontogenic, tonsillar, and pharyngeal infections, but it may be challenging to identify the primary source clearly when the infection is spread through multiple spaces. In the past, odontogenic sources were the most common; however, with the development and increased use of antibiotics and improved oral hygiene, odontogenic sources are gradually decreasing in frequency, and pharyngeal sources are becoming more frequent [9,10]. In this study, pharyngeal infections were the DNM source in 60% of cases. The microbiological results show a variety of aerobic and anaerobic bacteria and often mixed infections, with many reports that stating that the most frequently isolated bacteria were *Streptococcus* spp. [4,11], and similar results were shown in this study.

The most common chief complaints on admission are neck swelling or pain and dysphagia. Chest discomfort caused by mediastinitis or symptoms due to sepsis may also occur, but those symptoms are often quite ambiguous. Hence, CT is essential for accurate diagnosis and evaluation of the extent of DNM to establish an appropriate treatment plan. In addition, performing follow-up CT after surgical drainage can determine the therapeutic effect and identify new or untreated space involvement [11,12]. Although Endo's classification has been the most widely used classification system for DNM using CT, new classifications have recently been reported to compensate for its limitations. Guan et al. [13] proposed the DNM classification: type Ia limited to the anterosuperior mediastinum; type I, invading the anterior mediastinum; type II, invading the posterior mediastinum; and type III, invading both the anterior and posterior mediastinum. They reported that when the transcervical approach for mediastinal drainage was used for type Ia DNM and the thoracoscopic approach for the other types, good treatment outcomes were obtained, with an overall mortality rate of 9.4%. Sugio et al. [14] proposed adding lower mediastinum infections limited to the posterior mediastinum as type IIC to the existing Endo classification. According to this proposed clas-

sification, 11 of the 16 patients with type II DNM in this study would be classified as type IIC, accounting for a large proportion. However, this is unlikely to change the mediastinal drainage approach, and Sugio et al. [14] also reported differences in mortality only between types I and II.

Effective DNM treatment requires using appropriate antibiotics, securing the airway, controlling the neck infection source, and performing reliable cervical and mediastinal drainage, and a multidisciplinary approach is emphasized [4,15]. In terms of the surgical approach for mediastinal drainage, Endo et al. [2] suggested transcervical drainage in type I, subxiphoid incision in type IIA, and right standard thoracotomy in type IIB DNM. Although various approaches have been attempted, including transcervical, subxiphoid, median sternotomy, posterolateral thoracotomy, mediastinoscopy, and VATS, no consensus has been clearly established. Hsu et al. [16] reported that transcervical mediastinal drainage with extensive debridement is crucial for a good outcome in DNM. However, since most of their patients had type I DNM (72%), this technique cannot be universally accepted, as it would likely not apply to patients with type II DNM. In these patients, a suction system that can act in the opposite direction to gravity, or additional methods, such as continuous saline irrigation suggested by Ohashi et al. [17], will be needed to perform adequate drainage after surgery if only the cervical approach is used. Most will not disagree that active transthoracic mediastinal drainage is necessary despite the concerns of pleural contamination in type II DNM that has progressed to the lower mediastinum.

Although numerous studies have employed median sternotomy, a clamshell incision, or posterolateral thoracotomy as conventional and invasive methods [9,18,19], increasingly many studies are reporting successful results using VATS, which is less invasive and enables a view of the entire thoracic cavity [20-22]. This is because VATS induces less trauma to patients who are vulnerable due to the infection, enabling rapid recovery while providing effects similar to the open approach. In this study, we found no significant differences when comparing the transcervical and VATS groups; however, the effective drainage in the VATS group shortened the hospital stay by approximately 8 days.

Essential factors in determining the prognosis of patients with DNM include comorbidities (particularly diabetes), old age, Endo type II, and progression to septic shock [12,23]. This study had similar findings. Namely, the patients who died in the hospital were old (80 years old) or had severe sepsis (elevated CRP) identified from the time of admission. Therefore, early diagnosis and prompt active

treatment, including effective drainage, are the most important factors for a good prognosis in DNM with rapid progression.

This study has several limitations. First, the target sample size was small, although a long-term period was analyzed. In addition, we found no statistically significant differences in our comparison according to the mediastinal drainage approach. However, as studies on the diagnosis and treatment of DNM in Korea are scarce, this study attempted to examine the overall clinical course. Furthermore, it is expected that the efficacy of mediastinal drainage using the VATS approach would be demonstrated if more patients were recruited. Thus, further multicenter large-scale studies are warranted to confirm our findings.

In conclusion, based on the experience at our hospital, relatively good outcomes can be achieved in DNM treatment through rapid diagnosis, a multidisciplinary approach, and appropriate drainage according to the Endo classification. Although our findings are limited due to a lack of statistical significance, mediastinal drainage using VATS in patients with Endo type II DNM is expected to bring an excellent therapeutic effect by providing efficient drainage while being less invasive in vulnerable patients with severe infections.

Article information

ORCID

Ju Sik Yun: <https://orcid.org/0000-0002-5167-3454>
 Cho Hee Lee: <https://orcid.org/0000-0001-9271-9650>
 Kook Joo Na: <https://orcid.org/0000-0003-0923-1414>
 Sang Yun Song: <https://orcid.org/0000-0002-2084-8143>
 Sang Gi Oh: <https://orcid.org/0000-0001-9394-4980>
 In Seok Jeong: <https://orcid.org/0000-0002-2249-0667>

Author contributions

Conceptualization: JSY, SYS, KJN. Data curation: JSY, CHL, SGO. Formal analysis: JSY, CHL, ISJ. Methodology: JSY, SYS, KJN. Project administration: KJN, SGO, ISJ. Visualization: JSY, KJN. Writing—original draft: all authors. Writing—review & editing: all authors. Final approval of the manuscript: all authors.

Conflict of interest

No potential conflict of interest relevant to this article was reported.

Funding

This research did not receive any specific grant from funding agencies in the public, commercial, or not-for-profit sectors.

References

1. Estrera AS, Landay MJ, Grisham JM, Sinn DP, Platt MR. *Descending necrotizing mediastinitis*. *Surg Gynecol Obstet* 1983;157:545-52.
2. Endo S, Murayama F, Hasegawa T, et al. *Guideline of surgical management based on diffusion of descending necrotizing mediastinitis*. *Jpn J Thorac Cardiovasc Surg* 1999;47:14-9. <https://doi.org/10.1007/BF03217934>
3. Foroulis CN, Sileli MN. *Descending necrotizing mediastinitis: review of the literature and controversies in management*. *Open Surg J* 2011;5:12-8. <https://doi.org/10.2174/1874300501105010012>
4. Ma C, Zhou L, Zhao JZ, et al. *Multidisciplinary treatment of deep neck infection associated with descending necrotizing mediastinitis: a single-centre experience*. *J Int Med Res* 2019;47:6027-40. <https://doi.org/10.1177/0300060519879308>
5. Karkas A, Chahine K, Schmerber S, Brichon PY, Righini CA. *Optimal treatment of cervical necrotizing fasciitis associated with descending necrotizing mediastinitis*. *Br J Surg* 2010;97:609-15. <https://doi.org/10.1002/bjs.6935>
6. Kimura A, Miyamoto S, Yamashita T. *Clinical predictors of descending necrotizing mediastinitis after deep neck infections*. *Laryngoscope* 2020;130:E567-72. <https://doi.org/10.1002/lary.28406>
7. Petitpas F, Blancal JP, Mateo J, et al. *Factors associated with the mediastinal spread of cervical necrotizing fasciitis*. *Ann Thorac Surg* 2012;93:234-8. <https://doi.org/10.1016/j.athoracsur.2011.09.012>
8. Kang SK, Lee S, Oh HK, et al. *Clinical features of deep neck infections and predisposing factors for mediastinal extension*. *Korean J Thorac Cardiovasc Surg* 2012;45:171-6. <https://doi.org/10.5090/kjtc.2012.45.3.171>
9. Ridder GJ, Maier W, Kinzer S, Teszler CB, Boedeker CC, Pfeiffer J. *Descending necrotizing mediastinitis: contemporary trends in etiology, diagnosis, management, and outcome*. *Ann Surg* 2010;251:528-34. <https://doi.org/10.1097/SLA.0b013e3181c1b0d1>
10. Vieira F, Allen SM, Stocks RM, Thompson JW. *Deep neck infection*. *Otolaryngol Clin North Am* 2008;41:459-83. <https://doi.org/10.1016/j.otc.2008.01.002>
11. Sumi Y. *Descending necrotizing mediastinitis: 5 years of published data in Japan*. *Acute Med Surg* 2014;2:1-12. <https://doi.org/10.1002/ams2.56>
12. Prado-Calleros HM, Jimenez-Fuentes E, Jimenez-Escobar I. *Descending necrotizing mediastinitis: systematic review on its treatment in the last 6 years, 75 years after its description*. *Head Neck* 2016;38 Suppl 1:E2275-83. <https://doi.org/10.1002/hed.24183>

13. Guan X, Liang X, Liang X, Wang F, Qian W, Zhang W. *A new classification of descending necrotizing mediastinitis and surgical strategies*. *Ann Transl Med* 2021;9:356. <https://doi.org/10.21037/atm-21-121>
14. Sugio K, Okamoto T, Maniwa Y, et al. *Descending necrotizing mediastinitis and the proposal of a new classification*. *JTCVS Open* 2021; 8:633-47. <https://doi.org/10.1016/j.xjon.2021.08.001>
15. Ho CY, Chin SC, Chen SL. *Management of descending necrotizing mediastinitis, a severe complication of deep neck infection, based on multidisciplinary approaches and departmental co-ordination*. *Ear Nose Throat J* 2022 Jan 13 [Epub]. <https://doi.org/10.1177/01455613211068575>
16. Hsu RF, Wu PY, Ho CK. *Transcervical drainage for descending necrotizing mediastinitis may be sufficient*. *Otolaryngol Head Neck Surg* 2011;145:742-7. <https://doi.org/10.1177/0194599811406064>
17. Ohashi T, Kawago M, Ota F, et al. *Combination treatment by the cervical approach with mediastinal drainage and continuous saline irrigation for descending necrotizing mediastinitis type IIb: a three-case series*. *J Surg Case Rep* 2022;2022:rjac237. <https://doi.org/10.1093/jscr/rjac237>
18. Kocher GJ, Hokschi B, Caversaccio M, Wiegand J, Schmid RA. *Diffuse descending necrotizing mediastinitis: surgical therapy and outcome in a single-centre series*. *Eur J Cardiothorac Surg* 2012;42:e66-72. <https://doi.org/10.1093/ejcts/ezs385>
19. Palma DM, Giuliano S, Cracchiolo AN, et al. *Clinical features and outcome of patients with descending necrotizing mediastinitis: prospective analysis of 34 cases*. *Infection* 2016;44:77-84. <https://doi.org/10.1007/s15010-015-0838-y>
20. Min HK, Choi YS, Shim YM, Sohn YI, Kim J. *Descending necrotizing mediastinitis: a minimally invasive approach using video-assisted thoracoscopic surgery*. *Ann Thorac Surg* 2004;77:306-10. [https://doi.org/10.1016/s0003-4975\(03\)01333-x](https://doi.org/10.1016/s0003-4975(03)01333-x)
21. Son HS, Cho JH, Park SM, Sun K, Kim KT, Lee SH. *Management of descending necrotizing mediastinitis using minimally invasive video-assisted thoracoscopic surgery*. *Surg Laparosc Endosc Percutan Tech* 2006;16:379-82. <https://doi.org/10.1097/01.sle.0000213726.72709.62>
22. Shimizu K, Otani Y, Nakano T, Takayasu Y, Yasuoka Y, Morishita Y. *Successful video-assisted mediastinoscopic drainage of descending necrotizing mediastinitis*. *Ann Thorac Surg* 2006;81:2279-81. <https://doi.org/10.1016/j.athoracsur.2005.07.096>
23. Sarna T, Sengupta T, Miloro M, Kolokythas A. *Cervical necrotizing fasciitis with descending mediastinitis: literature review and case report*. *J Oral Maxillofac Surg* 2012;70:1342-50. <https://doi.org/10.1016/j.joms.2011.05.007>