

β -Blocker-Induced Liver Injury: A Class Effect With Incidental Rechallenge

Natalie E. Mitchell, MD¹, William Harner, MD², and Jeffrey Laczek, MD³

¹Department of Internal Medicine, Walter Reed National Military Medical Center, Bethesda, MD

²Department of Pulmonology and Critical Care, Walter Reed National Military Medical Center, Bethesda, MD

³Department of Gastroenterology, Walter Reed National Military Medical Center, Bethesda, MD

ABSTRACT

Drug-induced liver injury is a common cause of acute liver failure. β -blockers are a widely prescribed class of medications; however, hepatotoxicity is a rare adverse effect of this medication of which clinicians must be aware. This case suggests that hepatotoxicity may be a class effect of β -blockers.

INTRODUCTION

Drug-induced liver injury (DILI) accounts for approximately 10% of the cases of acute hepatitis and is the most common cause of acute liver failure in the United States.^{1,2} Given its nonspecific initial symptoms and varied liver injury pattern, it can be a difficult presentation to recognize. In addition, DILI is a diagnosis of exclusion and one that requires determination of causality, which may be clinically challenging.² We present a rare case of β -blocker-induced hepatotoxicity.

CASE REPORT

A 30-year-old white man was transferred to our facility with a 2-day history of nausea, nonbloody emesis, dark urine, and acholic stools. His medical history was significant for obesity (body mass index 35 kg/m²), hypertension, and seasonal allergies. The medication regimen at time of presentation included telmisartan 80 mg daily, carvedilol 6.25 mg twice daily, and cetirizine 10 mg daily. Carvedilol was started 1 month before presentation. He denied any recent supplement use, endorsed alcohol consumption of 250 mL wine 3 times weekly, and smoked one pack of cigarettes daily.

On admission, the patient was hypotensive and physical examination was notable for trace sublingual icterus with nontender hepatomegaly and no stigmata of chronic liver disease. Laboratory studies were significant for aspartate transaminase (AST) and alanine transaminase (ALT) 2686 U/L and 2494 U/L, respectively, with international normalized ratio 2.5 and bilirubin 6.9 mg/dL. Serum ethanol level was 163 mg/dL, acetaminophen level was undetectable, and urine drug screen was negative. An evaluation for autoimmune and infectious causes of acute hepatitis was unrevealing, including negative antinuclear, antimitochondrial, antismooth muscle antibody, Epstein-Barr virus, cytomegalovirus, and herpes simplex virus titers. Hepatitis A IgM antibody, hepatitis B surface antigen, hepatitis B core IgM, and hepatitis C antibody were negative. Hepatitis B surface antibody was positive. Ceruloplasmin was normal. Serum ferritin was 8,030 ng/mL with elevated transferrin saturation to 100% with gradual downtrend and normalization at time of discharge. A liver ultrasound demonstrated mild hepatic steatosis with patent hepatic vasculature.

All antihypertensives were held on admission to the hospital. Over the next 3 days, the patient's laboratory results significantly improved (AST 271 U/L, ALT 640 U/L, and bilirubin 3.6 mg/dL), and his international ratio levels normalized. He was discharged home with his carvedilol still held with normalization of AST and ALT during a follow-up 2 weeks later.

However, the patient was noted to be hypertensive during his outpatient appointment and was initiated on metoprolol succinate 25 mg daily. Within 2 days of starting this new medication, he developed nausea, nonbloody emesis, dark urine, and acholic stools. Transaminase levels were significantly elevated to AST 1326 U/L and ALT 968 U/L with total bilirubin 6.6 mg/dL. Metoprolol succinate was discontinued because of symptomatic improvement and rapid normalization of liver-associated enzymes (Figure 1).

DISCUSSION

We present a patient with a temporal relationship between significant liver injury and β -blocker usage on 2 separate occasions with 2 different β -blockers and negative workup for additional etiologies. The patient's rapid improvement in transaminase levels after the withdrawal of both carvedilol and metoprolol succinate in conjunction with a Roussel Uclaf Causality Assessment Method score >8 (highly probable) supports DILI from β -blocker exposure as the most likely explanation for the aforementioned case.²

In cases of DILI related to β -blockers, individuals typically develop constitutional symptoms with predominately hepatocellular damage and hyperbilirubinemia with a rapid resolution of laboratory abnormalities after cessation of β -blockers, which is identical to our patient's presentation and clinical course.³ Liver biopsy was not performed given high suspicion for DILI.²

β -blocker idiosyncratic hepatotoxicity is a rare adverse effect documented in only a few cases reports.³⁻⁶ Both metoprolol and carvedilol are metabolized through major first-pass hepatic oxidation pathways with metabolism subject to CYP2D6 genetic polymorphism.^{4,5,7} Although the pathogenesis of

β -blocker-related hepatotoxicity is uncertain, theoretical mechanisms in this patient include pre-existing genetic polymorphisms or the potential for impaired oxidative metabolism, secondary to likely nonalcoholic fatty liver disease in the setting of morbid obesity, which certainly may have predisposed him to the development of DILI.⁸ The above additionally provides a plausible explanation for the β -blocker class effect seen in this particular patient.

In summary, although severe hepatotoxicity is an uncommon side effect of β -blocker therapy, clinicians should be aware of this potential outcome as this class of medications is widely prescribed, particularly in patients with advanced liver disease. In addition, providers should recognize that DILI may be a class effect of β -blockers, so patients who suffer liver injury should be appropriately counseled and ideally avoid treatment with another β -blocker in the future.

DISCLOSURES

Author contributions: NE Mitchell wrote manuscript. W. Harner and J. Laczek revised the manuscript. J. Laczek is the article guarantor.

Financial disclosure: None to report.

Previous presentation: This case was presented at the American College of Gastroenterology Annual Scientific Meeting; October 13–18, 2017; Orlando, Florida.

Informed consent was obtained for this case report.

Received March 11, 2019; Accepted September 30, 2019

REFERENCES

- Zimmerman HJ. Drug-induced liver disease. *Clin Liver Dis*. 2000;4(1):73–96.
- Fisher K, Vuppalanchi R, Saxena R. Drug-induced liver injury. *Arch Pathol Lab Med*. 2015;139(7):876–87.
- Dumortier J, Guillaud O, Gouraud A, et al. Atenolol hepatotoxicity: Report of a complicated case. *Ann Pharmacother*. 2009;43(10):1719–23.
- Hagmeyer KO, Stein J. Hepatotoxicity associated with carvedilol. *Ann Pharmacother*. 2001;35(11):1364–6.
- Larrey D, Henrion J, Heller F, et al. Metoprolol-induced hepatitis: Rechallenge and drug oxidation phenotyping. *Ann Intern Med*. 1988;108(1):67–8.
- Rua J, Prata AR, Marques R, et al. Carvedilol-induced liver injury, a rare cause of mixed hepatitis: A clinical case. *GE Port J Gastroenterol*. 2019;26(3):196–201.
- Blake CM, Kharasch ED, Schwab M, Nagele P. A meta-analysis of CYP2D6 metabolizer phenotype and metoprolol pharmacokinetics. *Clin Pharmacol Ther*. 2013;94(3):394–9.
- Massart J, Begriche K, Moreau C, Fromenty B. Role of nonalcoholic fatty liver disease as risk factor for drug-induced hepatotoxicity. *J Clin Transl Res*. 2017;3(Suppl 1):212–32.

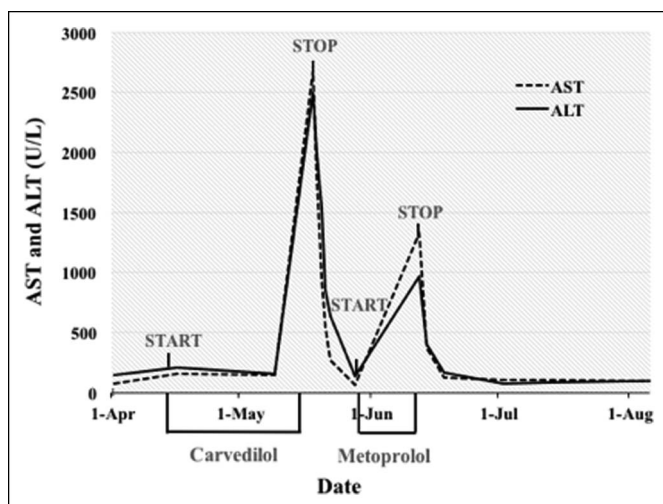


Figure 1. The trend of liver-associated enzymes and β -blocker usage. Line plot demonstrates liver-associated enzyme elevation in relation to initiation of carvedilol and metoprolol succinate and normalization following cessation of aforementioned medications. ALT, alanine transaminase; AST, aspartate transaminase.

Written work prepared by employees of the Federal Government as part of their official duties is, under the U.S. Copyright Act, a "work of the United States Government" for which copyright protection under Title 17 of the United States Code is not available. As such, copyright does not extend to the contributions of employees of the Federal Government.