

RESEARCH

Open Access



The comparison of percutaneous kyphoplasty and vertebroplasty for the management of stage III Kummell disease without neurological symptoms

Hanwen Li[†], Yingchuang Tang[†], Zixiang Liu, Huilin Yang, Zhigang Zhang^{*}, Kai Zhang^{*} and Kangwu Chen^{*}

Abstract

Purpose: To compare the clinical and radiological outcomes of percutaneous kyphoplasty (PKP) and percutaneous vertebroplasty (PVP) in the treatment of stage III Kummell disease without neurological deficit.

Methods: This retrospective study involved 41 patients with stage III Kummell disease without neurological deficit who underwent PKP or PVP from January 2018 to December 2019. Demographic data and clinical characteristics were comparable between these two groups before surgery. Operation time, volume of injected bone cement, intraoperative blood loss and time of hospital stay were analyzed. Visual analog scale (VAS) scoring and Oswestry disability index (ODI) scoring were assessed for each patient before and after operation. Radiographic follow-up was assessed by the height of anterior (Ha), the height of middle (Hm), Cobb's angle, and Vertebral wedge ratio (VWR). The preoperative and postoperative recovery values of these data were used for comparison.

Results: The two groups showed no significant difference in demographic features ($p > 0.05$). What's more, the operation time, intraoperative blood loss, and time of hospital stay revealed no sharp statistical distinctions either ($p > 0.05$), except PKP used more bone cement than PVP (7.4 ± 1.7 mL vs 4.7 ± 1.4 mL, $p < 0.05$). Radiographic data, such as the Ha improvement ratio ($35.1 \pm 10.2\%$ vs $16.2 \pm 9.4\%$), the Hm improvement ratio ($41.8 \pm 11.3\%$ vs $22.4 \pm 9.0\%$), the Cobb's angle improvement ($10.0 \pm 4.3^\circ$ vs $3.5 \pm 2.1^\circ$) and the VWR improvement ratio ($30.0 \pm 10.6\%$ vs $12.7 \pm 12.0\%$), were all better in PKP group than that in PVP group ($p < 0.05$). There were no statistical differences in the improvement of VAS and ODI 1-day after the surgery between these two groups ($p > 0.05$). However, at the final follow-up, VAS and ODI in PKP group were better than that in PVP ($p < 0.05$). Cement leakage, one of the most common complications, was less common in the PKP group than that in the PVP group (14.3% vs 45.0% , $p < 0.05$). And there was 1 case of adjacent vertebral fractures in both PKP and PVP (4.8% vs 5.0% , $p > 0.05$), which showed no statistical difference, and there were no severe complications recorded.

[†]Hanwen Li and Yingchuang Tang contributed equally to this article

*Correspondence: zhangzhigang@suda.edu.cn; zhangkaimessi@163.com; chenkangwu@suda.edu.cn

Department of Orthopedic Surgery, The First Affiliated Hospital of Soochow University, Suzhou 215006, Jiangsu, China



© The Author(s) 2022. **Open Access** This article is licensed under a Creative Commons Attribution 4.0 International License, which permits use, sharing, adaptation, distribution and reproduction in any medium or format, as long as you give appropriate credit to the original author(s) and the source, provide a link to the Creative Commons licence, and indicate if changes were made. The images or other third party material in this article are included in the article's Creative Commons licence, unless indicated otherwise in a credit line to the material. If material is not included in the article's Creative Commons licence and your intended use is not permitted by statutory regulation or exceeds the permitted use, you will need to obtain permission directly from the copyright holder. To view a copy of this licence, visit <http://creativecommons.org/licenses/by/4.0/>. The Creative Commons Public Domain Dedication waiver (<http://creativecommons.org/publicdomain/zero/1.0/>) applies to the data made available in this article, unless otherwise stated in a credit line to the data.

Conclusions: For stage III Kummell disease, both PKP and PVP can relieve pain effectively. Moreover, PKP can obtain more satisfactory reduction effects and less cement leakage than PVP. We suggested that PKP was more suitable for stage III Kummell disease without neurological deficit compared to PVP from a vertebral reduction point of view.

Keywords: Kummell's disease, PVP, PKP, OVCF

Introduction

Kummell's disease, first reported by Kummell in 1895 [1], was a delayed complication of osteoporotic vertebral compression fracture (OVCF). The main characteristic is that patients with a slight trauma tend to develop a symptomatic and progressive angular kyphosis after a short asymptomatic period. It is also known as nonunion after OVCF or delayed vertebral osteonecrosis after trauma [2]. Kummell's disease was divided into three stages based on different clinical symptoms, radiographs, and the magnetic resonance imaging [3]. To be specific, the vertebral body height loss is less than 20% in stage I of Kummell disease, with or without adjacent intervertebral disc degeneration; in stage II the vertebral body height loss is greater than 20% and is always along with adjacent intervertebral disc degeneration. Stage III Kummell disease is characterized by posterior breakage with or without spinal cord compression. Conservative treatment was once performed for Kummell's disease but it is often ineffective [4]. In previous studies, PVP and PKP were reported to achieve a good effect in the treatment of stage I and II Kummell disease [5, 6]. But for the stage III Kummell disease, the treatment remains controversial [7].

The traditional surgery treatment aimed to correct kyphosis, achieve decompression, fixation, and fusion, but it has more destruction of paravertebral muscles and ligament and more blood loss [8]. What's worse, to those who have severe osteoporosis, internal fixation has a high probability of failure [8]. PKP or PVP may be the candidate treatment for stage III Kummell disease. In our study, we retrospectively analyzed and compared the safety and efficacy of the PVP and PKP for treating patients who suffered from stage III Kummell disease without nerve injury.

Materials and methods

Inclusion and exclusion criteria

This is a retrospective study.

Inclusion criteria ①Bending on clinical symptoms and imaging examination, patients who met the reported diagnostic criteria [3] for stage III Kummell disease; ②Bone density T value < -2.5 on dual-energy X-ray absorptiometry (DXA), which is in accordance with the diagnostic criteria for osteoporosis; ③Magnetic

resonance imaging (MRI) showed no spinal canal involvement and no nerve injury, which is consistent with the symptoms; ④Only one single responsible vertebra is involved.

Exclusion criteria ①Patients with pathological vertebral fracture, serious internal medical diseases, like spinal metastatic tumor, vertebral tuberculosis. ②Patients with severe cardiopulmonary, liver and kidney dysfunction who cannot tolerate surgery. ③Patients with incomplete clinical data.

Patients

41 patients with stage III Kummell disease without neurologic deficits who underwent PKP or PVP between January 2018 and December 2019 were recruited. Demographic data for the 2 groups are presented in Table 1.

All patients received conservative treatment for at least 3 months before admission; thus, we did not diagnose Kummell's disease before 3 months [9]. The patients were informed of the advantages and disadvantages of PKP and PVP before they made the choice. Meanwhile, they were instructed that there was no sufficient evidence-based medicine showing which one was better.

Table 1 Demographic data of patients

Variable	PKP Group	PVP Group	P Value
Number of patients	21	20	
Age, mean \pm SD	70.7 \pm 7.3	70.0 \pm 7.4	0.758
Sex, number			
Male	6	5	0.796
Female	15	15	
Medical history (months), mean \pm SD	5.6 \pm 2.9	5.6 \pm 2.8	0.981
BMD, mean \pm SD	-3.5 \pm 0.4	-3.3 \pm 0.5	0.386
Responsible segment, number			
T10	1	1	0.951
T11	0	1	
T12	2	2	
L1	11	9	
L2	4	5	
L3	2	1	
L4	1	1	
Follow-up (months), mean \pm SD	37.7 \pm 7.7	39.6 \pm 5.1	0.355

Surgical information

For PKP group, patients were performed in a prone, lordotic posture to maintain posterior extension of the spine under general anesthesia. The standard procedure for PKP surgery can be referred to our previously published article [10]. In short, after disinfection, bilateral transpedicular puncture was performed, bilateral balloons were placed under the endplate through the working tunnel. Balloons were inflated gently to restore the height of the affected vertebra and deflated after elevating the superior endplate. After the balloon was removed, polymethylmethacrylate cement was used to fill the preformed hollow. The whole process was monitored by C-arm fluoroscopy.

For PVP groups, most of the steps are similar, but without the balloon. After a working tunnel was established, polymethylmethacrylate bone cement was pushed into the vertebra directly.

Clinical and radiologic assessment

The visual analogue scale (VAS score 0–10; 0 no pain at all; 10 the worst imaginable) system was employed to evaluate back pain control. Impact on the patient's daily life was assessed using the Oswestry Disability Index (ODI) questionnaire [11, 12]. Radiographs were taken to measure the rate of cement leakages and refracture, the anterior, middle and posterior vertebral heights, Cobb's angle and Vertebral wedge ratio [11] of the fractured vertebral body before and after surgery. The operation time, amounts of cement injected, time of hospital stay and intraoperative blood loss of the two procedures were recorded.

All radiographic measurements were performed in a double-blinded fashion by 2 orthopedic surgeons.

Statistical analysis

SPSS 21.0 software was applied to carry out all analyzes. Data was calculated as mean \pm standard deviation. Preoperative and postoperative measurement data were assessed by using paired t-test and χ^2 test. A P value < 0.05 was considered statistically significant.

Results

There were no significant differences between groups in terms of preoperative demographic data (Table 1). All patients tolerated the operation well. For average operation time, PKP group was 52.6 ± 15.9 min and PVP group was 46.3 ± 12.8 min. Blood loss during the operation was minimal, 18.1 ± 4.6 mL in PKP group and 17.6 ± 3.7 mL in PVP group. The average volume of cement injected in PKP and PVP group was 7.4 ± 1.7 mL and 4.7 ± 1.4 mL, respectively (Table 2).

Table 2 Comparison of operation time, intraoperative blood loss, hospitalization stays, and volume of cement injected

Variable	PKP Group	PVP Group	P value
Operation time (min)	52.6 ± 15.9	46.3 ± 12.8	0.167
Intraoperative blood loss (mL)	18.1 ± 4.6	17.6 ± 3.7	0.707
Hospitalization stays (days)	3.5 ± 0.7	3.6 ± 0.6	0.716
Cement volume (mL)	7.4 ± 1.7	4.7 ± 1.4	< 0.001

Table 3 Mean improvement in VAS and ODI

Variable	PKP group	PVP group	P value
VAS-preoperative	8.1 ± 0.9	8.2 ± 0.8	0.978
VAS-postoperative	2.4 ± 0.5^a	2.3 ± 0.7^a	0.658
VAS-final follow-up	2.5 ± 0.5^{ab}	3.1 ± 0.7^{ac}	0.004
ODI (%)—preoperative	80.2 ± 6.8	81.4 ± 5.7	0.540
ODI (%)—postoperative	25.5 ± 3.5^a	25.5 ± 2.9^a	0.979
ODI (%)—final follow-up	25.8 ± 2.9^{ab}	31.7 ± 3.9^{ac}	< 0.001

^a P < 0.05 versus preoperative values

^b P > 0.05 versus postoperative values

^c P < 0.05 versus postoperative values

Patients had follow-up from 24 to 48 months. There were significant improvements in both groups ($p < 0.05$) in the VAS, ODI score at the 1-day postoperatively and at the final follow-up compared with the preoperative values (Table 3). In PKP group, the VAS pain score decreased from a preoperative value of 8.1 ± 0.9 to a postoperative value of 2.4 ± 0.5 ($p < 0.05$), and further 2.5 ± 0.5 at final follow-up. In PVP group, this score also decreased from a preoperative value of 8.2 ± 0.8 to a postoperative value of 2.3 ± 0.7 ($p < 0.05$), and finally 3.1 ± 0.7 . There was no significant difference in VAS score at the 1-day postoperatively between the PVP group and PKP group ($p > 0.05$). However, at the final follow-up, PKP group turned out to be a better procedure ($p < 0.05$). As for the ODI score, the same trend was observed.

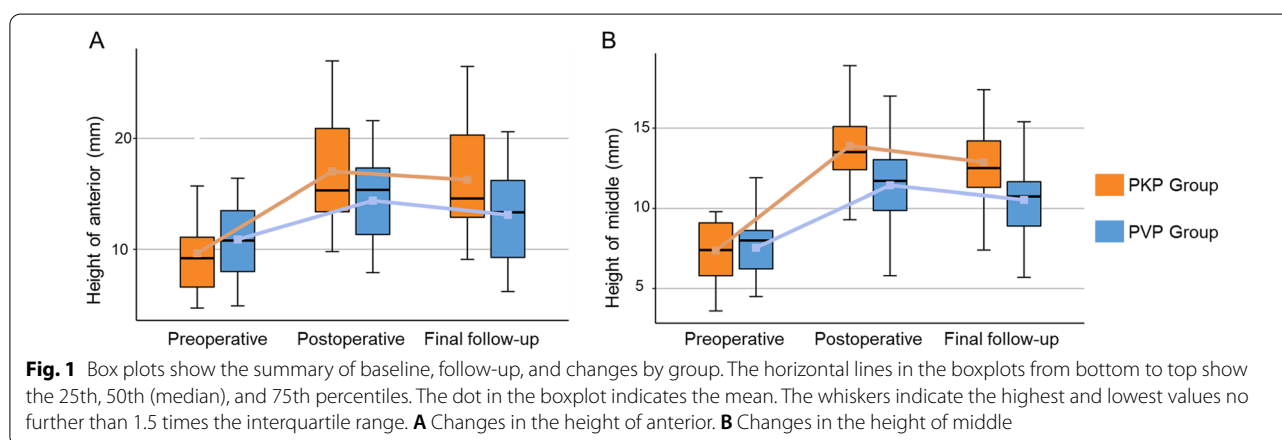
Significant increases of the anterior and middle vertebral heights were observed after surgery too ($p < 0.05$). However, the change of the posterior was not significant ($p = 0.273$). The improvements of PKP and PVP group in Cobb's angle were $10.0 \pm 4.3^\circ$ and $3.5 \pm 2.1^\circ$, and in VWR were $30.0 \pm 10.6\%$ and $12.7 \pm 12.0\%$, respectively (Table 4). PKP displayed better recovery capability than PVP ($p < 0.05$). What's more, the correction was almost maintained at the final follow-up (Fig. 1). Asymptomatic cement leakage occurred with 9 cases in PVP group and 3 cases in PKP group (Table 4), the probability of bone cement leakage was lower in the PKP group ($p < 0.05$). Adjacent vertebral fractures occurred in 1 case of the

Table 4 Clinical and radiographic data

Variable	PKP group	PVP group	P value
Vertebral body height ratios improvement (%) ^a			
Anterior	35.1 ± 10.2	16.2 ± 9.4	< 0.001
Middle	41.8 ± 11.3	22.4 ± 9.0	< 0.001
Posterior	8.0 ± 8.6	5.6 ± 4.7	0.273
Cobb's angle improvement	10.0 ± 4.3	3.5 ± 2.1	< 0.001
VWR improvement (%) ^b	30.0 ± 10.6	12.7 ± 12.0	< 0.001
Cement leakage, number	3	9	0.025
Adjacent vertebral fractures, number	1	1	0.972

^a Vertebral body height ratio (%) = (fractured vertebral body height/normal vertebral body height) × 100%

^b VWR, Vertebral wedge ratio (%) = (fractured vertebral body anterior height/fractured vertebral body posterior height) × 100%



PKP group and 1 case of the PVP group. There was not significant difference in the number of adjacent vertebral fractures between the two groups ($p > 0.05$). There was no other serious complication.

Illustrative case

Vertebral body height and local kyphotic angle showed significant recovery after PKP surgery (Fig. 2), PVP can also restore vertebral height, but not as good as PKP (Fig. 3). Both PKP and PVP will lose a little vertebral height during the follow-up.

Discussion

Kummell's disease is characterized by delayed osteoporotic vertebral collapse and chronic back pain [9, 13]. Conservative treatment tends to be ineffective [14], patients with stage III Kummell disease often have severe osteoporosis and it is a huge risk for them to undergo open surgery [15–17]. Therefore, open surgery may not be the first choice for these patients. Given the possibility of technical difficulty and cement leakage [18], PKP and PVP are still cautious for severe OVCF treatment. The

treatment for stage III Kummell disease without neurological deficits remains controversial.

Studies have shown that both PKP and PVP can relieve the chronic pain and correct the kyphosis in stage I and II Kummell disease [19, 20]. Similar phenomenon was observed in our study, we found that PKP and PVP both could effectively alleviate patients' back pain in stage III Kummell disease. The VAS score and ODI score was significantly improved after surgery in both groups. However, there was no significant difference in VAS or ODI score between the two groups at one day after surgery, but VAS and ODI score in PKP group was significantly lower than that in PVP group at final follow-up. This may be due to the Cobb's angle correction. As we know, kyphosis tends to cause chronic pain [21]. In our study, we found that Ha, Hm improvement ratio and Cobb's angle, VWR improvement in PKP group were obviously better than that in PVP group. Moreover, we also discovered that the average volume of bone cement in PKP group was more than that in PVP group. The possible reason may be that bone cement is usually confined to the vertebral fissure in PVP treatment, while in PKP treatment, bone cement can maintain the correction of

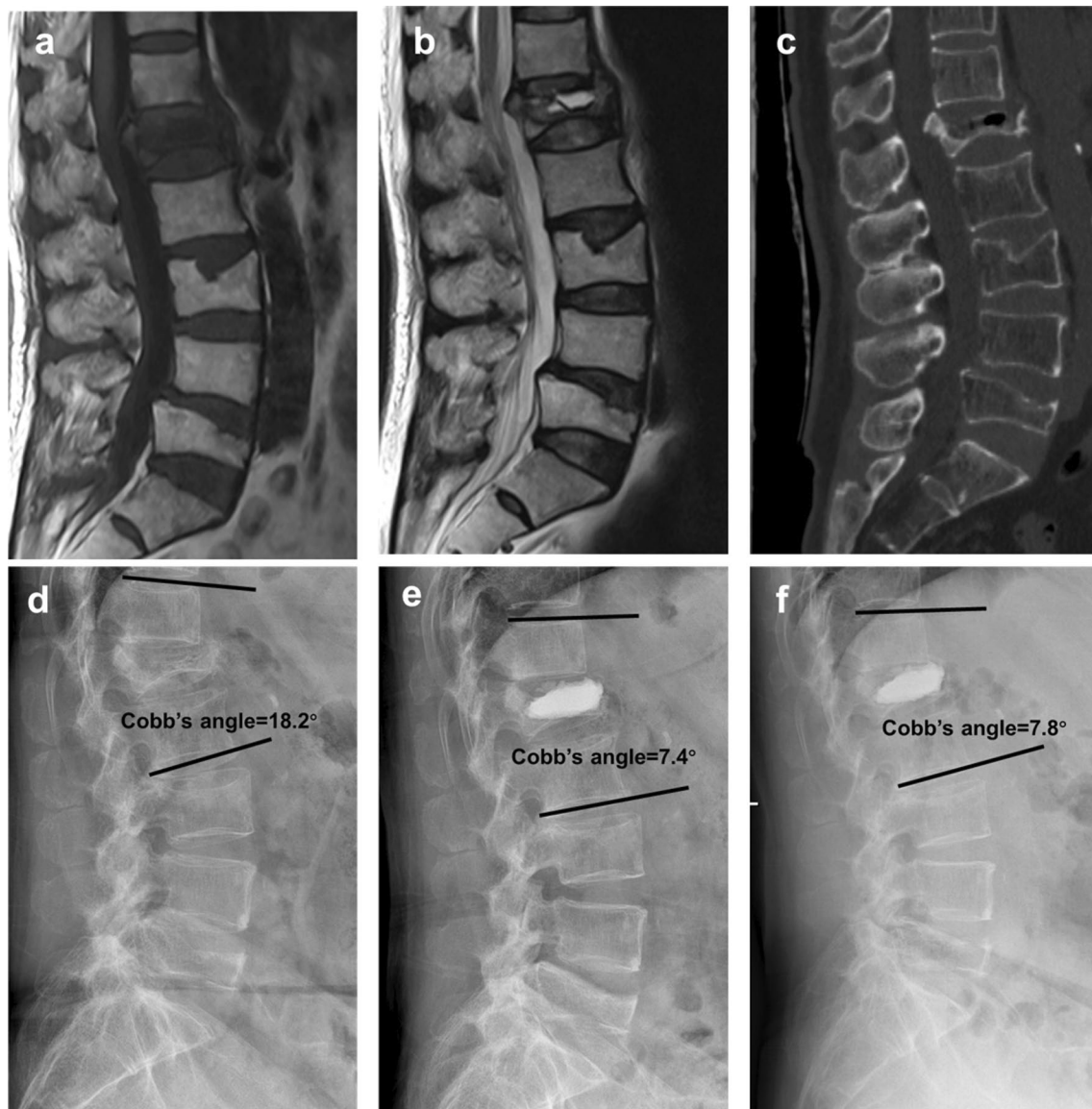

Fig. 2 A 64-year-old woman who had L1 stage III Kummell disease without neurological symptom was treated with PKP. **a–c** The preoperative MRI T1WI, MRI T2WI and CT films showed a chronic osteoporotic vertebral compressive fracture. **d–f** The preoperative, postoperative and final follow-up X-ray films displayed the vertebral height and Cobb's angle was well recovered

hyperextension kyphosis with the help of an expanded balloon. In a word, both PKP and PVP can effectively treat stage III Kummell disease and PKP can achieve better vertebral height restoration and kyphosis correction than PVP.

The most common complications of PKP and PVP are bone cement leakage and adjacent vertebral fractures [22, 23]. Wang et al. reported that compared with vertebroplasty, kyphoplasty significantly decreased the risk of cement leakage through a meta-analysis and systematic review [24]. Chang et al. found that for the

treatment of Kummell's disease, PKP has a lower rate of bone cement leakage than PVP (10.7% vs 17.2%) [25]. In our study, PKP showed a better way to avoid cement leakage than PVP (14.3% vs 45.0%), and none of these patients had obvious symptoms. The reason was mainly related to the fact that the PKP group could squeeze the surrounding cancellous bone during balloon expansion and reduce the bone cement leakage. There was 1 case of adjacent vertebral fractures in both PKP and PVP (4.8% vs 5.0%), which showed no statistical difference. This may be due to improved postoperative rehabilitation and

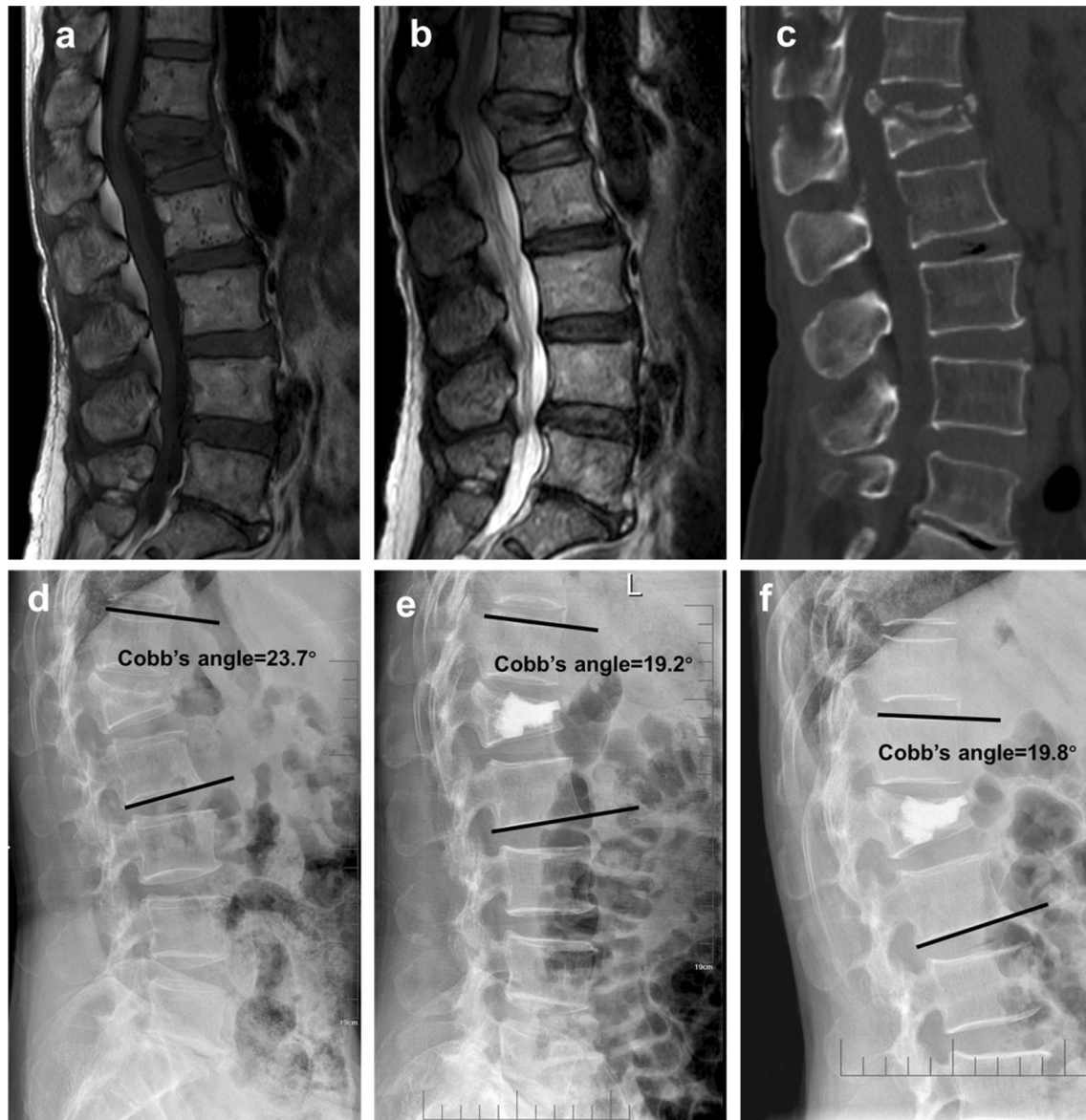

Fig. 3 A 63-year-old woman who had L1 stage III Kummell disease without neurological symptom was treated with PVP. **a–c** The preoperative MRI T1WI, MRI T2WI and CT films showed a chronic osteoporotic vertebral compressive fracture. **d–f** The preoperative, postoperative and final follow-up X-ray films displayed the vertebral height and Cobb's angle was recovered a little

anti-osteoporosis treatment, but also related to the small sample size. To sum up, PKP and PVP are both effective quality methods, but PKP is superior in terms of cement leakage.

According to our experience, paying enough attention before and after surgery can greatly reduce the complications of surgery. Although severe vertebral collapse and incomplete posterior wall of the vertebral body is present in stage III Kummell disease, thorough

preoperative imaging examination, such as MRI and CT coronal and sagittal reconstruction, is of great importance for us to decide whether PVP or PKP can be used. Intraoperatively, precise puncture technique, moderate balloon dilation and ideal balloon placement are critical. In our experience, the ideal location of the balloon is in the anterior 3/4 of the vertebral body. What's more, appropriate bone cement injection is helpful to reduce the leakage rate of bone cement. For patients with anterior wall defect indicated by preoperative

imaging, we used graded infusion of bone cement. A small amount of bone cement is injected to firstly seal the rupture, thus improving vertebral stability. Postoperatively, patients need to receive systematic and personalized anti-osteoporosis therapy, which is important for the prevention and treatment of complications.

However, this study also had some limitations. The number of intraoperative fluoroscopy and radiation dose were not counted in this study, which will be improved in our future study. The sample size of this study is still small, and a large sample randomized controlled study is needed.

Conclusion

To conclude, both PVP and PKP are effective in pain relief for stage III Kummell disease without neurological deficit, they have the advantages of small trauma, short operation time, and quick recovery. Compared with PVP, PKP could achieve better vertebral height restoration and kyphosis correction. Furthermore, PKP exists less cement leakage than PVP.

Acknowledgements

Thanks are due to Weifeng Duan for valuable discussion.

Author contributions

HL wrote the manuscript with support from HY, ZZ, KZ and KC. HL, YT and ZL collected the data. HL and YT performed the analysis. KC, ZZ and KZ supervised the project. All authors read and approved the final manuscript.

Funding

This study was supported by the National Nature Science Foundation of China (grant no. 81802682), the Natural Science Foundation of Jiangsu Province (grants no. BK20220095).

Availability of data and materials

The data that support the findings of this study are included in this manuscript, and the original files are available from the corresponding author upon reasonable request.

Declarations

Ethics approval and consent to participate

This study was approved by the Institutional Ethics Committee of Soochow University. All procedures performed in studies involving human participants were in accordance with the ethical standards of the institutional research committee and with the 1964 Helsinki Declaration and its later amendments or comparable ethical standards. All patients were approved for treatment by written informed consent.

Consent for publication

Not applicable.

Competing interests

The authors declare that they have no conflict of interest.

Received: 19 April 2022 Accepted: 16 August 2022

Published online: 20 August 2022

References

- Kummell H. Die rarefizierende ostitis der wirbelkörper. *Dtsch Med Wochenschr.* 1985;21(1):180–1.
- Young WF, Brown D, Kendler A, Clements D. Delayed post-traumatic osteonecrosis of a vertebral body (Kummell's disease). *Acta Orthop Belg.* 2002;68(1):13–9.
- Li KC, Wong TU, Kung FC, Li A, Hsieh CH. Staging of Kummell's disease. *J Musculoskelet Res.* 2004;8(1):43–55.
- Zhang C, Wen T, Li C, Ruan D, He Q. Cluster phenomenon of vertebral refractures after posterior pedicle screw fixation in a patient with glucocorticosteroid-induced Kummell's disease: a treatment dilemma. *Arch Osteoporos.* 2021;16(1):93.
- Huang Y, Peng M, He S, Tang X, Dai M, Tang C. Clinical efficacy of percutaneous kyphoplasty at the hyperextension position for the treatment of osteoporotic Kummell disease. *Clin Spine Surg.* 2016;29(4):161–6.
- Chen B, Li Y, Xie D, Yang X, Zheng Z. Comparison of unipedicular and bipedicular kyphoplasty on the stiffness and biomechanical balance of compression fractured vertebrae. *Eur Spine J.* 2011;20(8):1272–80.
- Xiong XM, Sun YL, Song SM, Yang MY, Zhou J, Wan D, Deng XG, Shi HG. Efficacy of unilateral transverse process-pedicle and bilateral puncture techniques in percutaneous kyphoplasty for Kummell disease. *Exp Ther Med.* 2019;18(5):3615–21.
- Bokov A, Isrellov A, Skorodumov A, Aleynik A, Simonov A, Mlyavykh S. An analysis of reasons for failed back surgery syndrome and partial results after different types of surgical lumbar nerve root decompression. *Pain Physician.* 2011;14(6):545–57.
- Huang YS, Hao DJ, Wang XD, Sun HH, Du JP, Yang JS, Gao J, Xue P. Long-Segment or Bone Cement-Augmented Short-Segment Fixation for Kummell Disease with Neurologic Deficits? A Comparative Cohort Study. *World Neurosurg.* 2018;116:e1079–86.
- Wang G, Yang H, Chen K. Osteoporotic vertebral compression fractures with an intravertebral cleft treated by percutaneous balloon kyphoplasty. *J Bone Joint Surg Br.* 2010;92(11):1553–7.
- Khan M, Kushchayev SV. Percutaneous vertebral body augmentations: the state of art. *Neuroimaging Clin N Am.* 2019;29(4):495–513.
- Zhang Y, Shi L, Tang P, Zhang L. Comparison of the efficacy between two micro-operative therapies of old patients with osteoporotic vertebral compression fracture: a network meta-analysis. *J Cell Biochem.* 2017;118(10):3205–12.
- Liu F, Chen Z, Lou C, Yu W, Zheng L, He D, Zhu K. Anterior reconstruction versus posterior osteotomy in treating Kummell's disease with neurological deficits: a systematic review. *Acta Orthop Traumatol Turc.* 2018;52(4):283–8.
- Pluijm SM, Tromp AM, Smit JH, Deeg DJ, Lips P. Consequences of vertebral deformities in older men and women. *J Bone Miner Res.* 2000;15(8):1564–72.
- Lee GW, Yeom JS, Kim HJ, Suh BG. A therapeutic efficacy of the transpedicular intracorporeal bone graft with short-segmental posterior instrumentation in osteonecrosis of vertebral body: a minimum 5-year follow-up study. *Spine.* 2013;38(4):E244–250.
- Nakashima H, Imagama S, Yukawa Y, Kanemura T, Kamiya M, Deguchi M, Wakao N, Sato T, Matsuzaki K, Yoshida G, et al. Comparative study of 2 surgical procedures for osteoporotic delayed vertebral collapse: anterior and posterior combined surgery versus posterior spinal fusion with vertebroplasty. *Spine.* 2015;40(2):E120–126.
- Chen L, Dong R, Gu Y, Feng Y. Comparison between balloon kyphoplasty and short segmental fixation combined with vertebroplasty in the treatment of Kummell's disease. *Pain Physician.* 2015;18(4):373–81.
- Zhang C, Wang G, Liu X, Li Y, Sun J. Failed percutaneous kyphoplasty in treatment of stage 3 Kummell disease: a case report and literature review. *Medicine.* 2017;96(47): e8895.
- Chen GD, Lu Q, Wang GL, Zou J, Yang HL, Yang Y, Luo ZP. Percutaneous kyphoplasty for Kummell disease with severe spinal canal stenosis. *Pain Physician.* 2015;18(6):E1021–1028.
- Park JW, Park JH, Jeon HJ, Lee JY, Cho BM, Park SH. Kummell's disease treated with percutaneous vertebroplasty: minimum 1 year follow-up. *Korean J Neurotrauma.* 2017;13(2):119–23.
- Jaromi M, Nemeth A, Kranicz J, Laczko T, Betlehem J. Treatment and ergonomics training of work-related lower back pain and body posture problems for nurses. *J Clin Nurs.* 2012;21(11–12):1776–84.

22. Chen W, Xie W, Xiao Z, Chen H, Jin D, Ding J. Incidence of cement leakage between unilateral and bilateral percutaneous vertebral augmentation for osteoporotic vertebral compression fractures: a meta-analysis of randomized controlled trials. *World Neurosurg.* 2019;122:342–8.
23. Zhan Y, Jiang J, Liao H, Tan H, Yang K. Risk factors for cement leakage after vertebroplasty or kyphoplasty: a meta-analysis of published evidence. *World Neurosurg.* 2017;101:633–42.
24. Wang B, Zhao CP, Song LX, Zhu L. Balloon kyphoplasty versus percutaneous vertebroplasty for osteoporotic vertebral compression fracture: a meta-analysis and systematic review. *J Orthop Surg Res.* 2018;13(1):264.
25. Chang JZ, Bei MJ, Shu DP, Sun CJ, Chen JB, Xiao YP. Comparison of the clinical outcomes of percutaneous vertebroplasty vs kyphoplasty for the treatment of osteoporotic Kummell's disease: a prospective cohort study. *BMC Musculoskelet Disord.* 2020;21(1):238.

Publisher's Note

Springer Nature remains neutral with regard to jurisdictional claims in published maps and institutional affiliations.

Ready to submit your research? Choose BMC and benefit from:

- fast, convenient online submission
- thorough peer review by experienced researchers in your field
- rapid publication on acceptance
- support for research data, including large and complex data types
- gold Open Access which fosters wider collaboration and increased citations
- maximum visibility for your research: over 100M website views per year

At BMC, research is always in progress.

Learn more biomedcentral.com/submissions

