



Case report

Sliding ureteral inguinal hernia: An uncommon embryological trick. Case report and literature review

Roberta Maria Isernia^{a,*}, Giuseppe Massimiliano De Luca^b, Alessandro De Luca^c,
Lucia Franzoso^d, Lorenzo Ramon Navazio^e, Riccardo Caruso^f, Valentina Ferri^f,
Benedetto Ielpo^g, Simone Giungato^c

^a National Institute of Gastroenterology, Saverio de Bellis Research Hospital, Castellana Grotte, Italy

^b University of Bari "A. Moro", Department of Biomedical Sciences and Human Oncology, Unit of Academic General Surgery "V. Bonomo", Bari, Italy

^c Department of General Surgery, "San Pio" Hospital, Castellaneta, Italy

^d Department of Anesthesia and Intensive Care, Santissima Annunziata Hospital, Taranto, Italy

^e Department of Anesthesia and Intensive Care, Policlinico di Bari, University of Bari "A. Moro", Bari, Italy

^f General Surgery Department, Hospital Universitario HM Sanchinarro, HM Hospitales, Universidad CEU San Pablo, Madrid, Spain

^g HPB Unit, University Parc Salut Mar Hospital, Barcelona, Spain

ARTICLE INFO

Keywords:

Bladder

Ureter

Inguinal hernia

Groin hernia

ABSTRACT

Introduction: Inguinoscrotal herniation of the bladder is a rare clinical entity, with a frequency between 0.5% and 4% of all inguinal hernias. When the whole bladder and ureters migrate into the scrotum, it may cause urinary disorders as hydronephrosis.

Case report: A 77-year-old male patient suffering from hypertrophic obstructive cardiomyopathy, obesity and diabetic disease presented with urinary disorders and left-sided inguinoscrotal hernia. Under clinical suspicion of sigmoid colon involvement in the inguinal canal, abdominal and pelvic computed tomography (CT scan) with endovenous contrast was performed, revealing a left inguinoscrotal hernia, containing the sigmoid colon and the left pelvic ureter causing left hydronephrosis.

Discussion: Without create urinary bladder wall leakage, the content of the hernial sac was reduced into the abdominal cavity. Previous subarachnoid anesthesia a left hernioplasty was performed by means of Lichtenstein's method with self-fixating mesh (*Bard Adhesix*) and subsequent complete resolution of the hydronephrosis.

Conclusion: Ureter involvement should be suspected when a clinical inguinal hernia is diagnosed concurrently with unexplained hydronephrosis, renal failure, or urinary tract infection, as in the case described. When suspected, the preoperative diagnosis, particularly with CT scan, is essential to avoid complications and to reduce risk of bladder and ureter injuries during hernia repair.

1. Introduction

Cases of ureteral inguinal hernias in adults with native kidneys (in particular the distal segment) are extremely uncommon phenomenon. Most of these cases are reported in patients with transplanted ureter caused by the different position of the renal graft.

Fewer than 10 cases have been reported, with most being symptomatic and diagnosed preoperatively [1].

2. Case report

A 77-year-old man was referred by his family physician to the General Surgeon with a history of hypertrophic obstructive cardiomyopathy, obesity and diabetic disease presented with urinary disorders and a lump in the left groin causing occasional discomfort and constipation. Although most of the time he could not feel it, he recently had a few episodes of pain when it protruded and had difficulty reducing it.

Under clinical suspicion of sigmoid colon involvement in the inguinal canal, abdominal and pelvic computed tomography (CT scan) with endovenous contrast was performed, revealing a left inguinoscrotal

* Corresponding author.

E-mail address: Roberta.Isernia@hotmail.it (R.M. Isernia).

<https://doi.org/10.1016/j.ijscr.2022.107006>

Received 4 January 2022; Received in revised form 26 March 2022; Accepted 31 March 2022

Available online 2 April 2022

2210-2612/© 2022 The Authors. Published by Elsevier Ltd on behalf of IJS Publishing Group Ltd. This is an open access article under the CC BY-NC-ND license (<http://creativecommons.org/licenses/by-nc-nd/4.0/>).

hernia, containing the sigmoid colon and the left pelvic ureter causing left hydronephrosis (Fig. 1). He had no history of renal disease. His serum creatinine and urea were within normal ranges.

Examination revealed a groin hernia extended mildly into the left hemiscrotum and partially reducible.

He was booked for a routine left groin hernia repair under sub-arachnoid block, performed by a young surgeon (<40 years old) but with a good experience in this kind of surgery. Intraoperatively a huge indirect sliding hernia was found with a considerable amount of fat, initially thought to be a large lipoma of the cord. The cord structures were easily identified and preserved. Further dissection of the herniated contents revealed a deeper component of fatty tissue with a white tubular structure amidst the herniated contents.

Without injure the urinary bladder wall integrity, the content of the hernial sac was reduced into the abdominal cavity. A left Lichtenstein hernioplasty was performed with self-gripping mesh (*Bard Adhesix*) and subsequent complete resolution of the hydronephrosis (Fig. 2).

The postoperative course was uneventful with a complete resolution of the constipation in first postoperative day. The discharge was performed with a regular clinical and ultrasound follow up, only a small subcutaneous hematoma resolved in 15 days. The patient was treated and discharged with 2 tablets a day of Siben®, a combination of Bromelain 200 mg and Boswellia Serrata Casperome® 200 mg, for 30 days on an empty stomach, starting from the first post-surgery day, to reduce edema and prevent the formation of postoperative seroma [2].

This patient had a very excellent perspective and he received the appropriate treatment, considering that this kind of surgery has a good tolerability.

3. Methods

This work has been reported in line with the SCARE 2020 criteria [3].

This paper is a literature review with a selection of 22 articles, only English papers and the query mesh was performed with the followed keys words: ureter, inguinal hernia, groin hernia.

On this presuppose we have elaborated a clinical classification that considered sliding inguinal hernias which contain the ureter, bladder and intestinal tract in no kidney transplanted patients.

According the literature review, we have elaborated this likely topographic and physopathologic classification in order to better define the uncommon eventualities and anatomical variants.

3.1. Madrid 2021 classification

Grade 1: ureter slides in the groin canal without create hydronephrosis.

Grade 2: ureter slides in the groin canal creating hydronephrosis.

Grade 3: ureter slides in the groin canal creating hydronephrosis and intestinal occlusion for the herniation of small bowel or sigma.

Grade 4: ureter slides in the groin canal without create neither hydronephrosis nor intestinal occlusion for the herniation of small bowel or sigma.

Grade 5: ureter slides in the groin canal creating hydronephrosis with herniation of bladder.

Grade 6: ureter slides in the groin canal without create hydronephrosis with herniation of bladder.

Grade 7: ureter slides in the groin canal creating hydronephrosis and homolateral kidney failure.

4. Discussion

Ureter inguinal hernias are nearly always indirect [4]. This kind of hernia can include the ureter alone or, frequently, other abdominal sliding organs within the hernia sac (bladder, bowel tracts, etc.). Kidneys and urinary tracts present normal conformation, although renal ptosis may be found. The embryological process of rotation may support this thesis.

From a clinical point of view, independent of the kind of hernia, urinary symptoms such as dysuria, frequency and urgency may be present associated with the intestinal symptoms due to bowel occlusion. This particular symptomatology in a patient with inguinal hernia is of particular value and should arouse suspicion that ureter may be a part of the hernia. In these cases, a preoperative excretory urogram should always be performed [5].

Ureteral strangulation is rare, and signs of obstructive uropathy do not form part of clinical findings in these cases, but we have reported a case of urosepsis. For this reason, the correct management of this clinical setting should consider the option of urostomy or direct surgery approach like uretherolithothomia o ureterorrafia [6] (Table 1).

In most cases, dissection and simple ureteral replacement (followed by hernioplasty technique) is the most advisable treatment. Whenever herniated ureter appears damaged with significant dilatation, a peristalsis, inflammation or necrosis, a ureter resection followed by an ureterocystostomy should be performed [8].

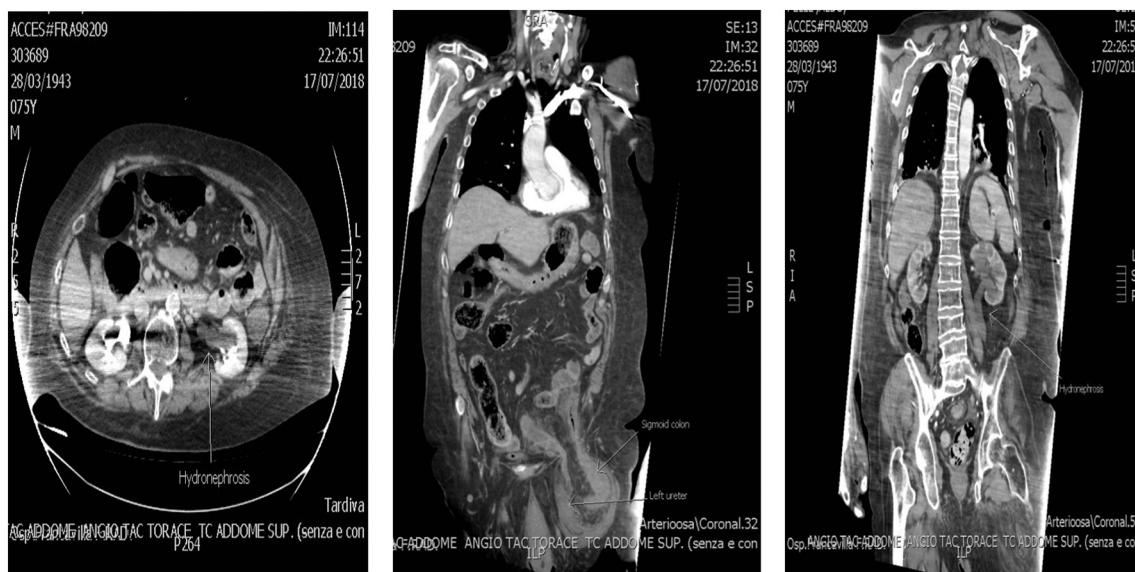


Fig. 1. CT scan: individuation a left inguinoscrotal hernia, containing the sigmoid colon and the left pelvic ureter causing left hydronephrosis.

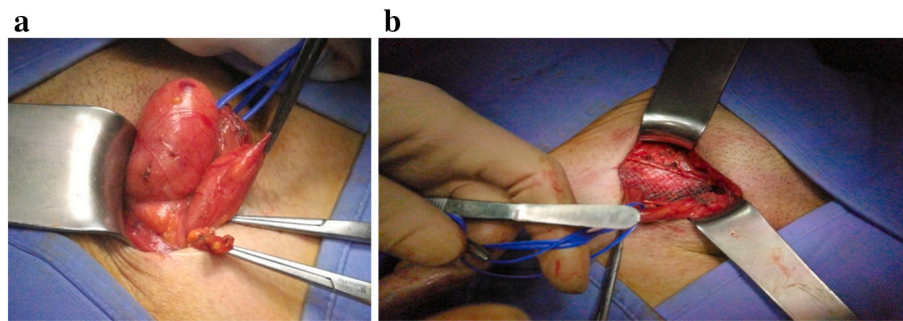


Fig. 2. a Intraoperative view: ureter (blue loop) after isolation from peritoneal sac hernia.
b Last procedure: Lichtenstein hernioplasty was performed with self-gripping mesh.

Table 1

Main clinical findings of uretero-inguinal hernias reported by authors.

Age at onset	66 years
Sex	100% M
Acquired/congenital	100% acquired
Classification	Grade 2 to 5
Other abdominal organ herniation	Sigma, bladder
Clinical examination	90% inguino-scrotal hernia, one case of urosepsis
Type of hernia	Indirect Lichtenstein hernioplasty, 25% ureterolithothomia o ureterorrafia
Surgical therapy	Subarachnoid or general
Anesthesia	
Urinary system	
Anatomical	No
Malformations	No
Surgery complication	None
Recurrence	
Grade of hydronephrosis	39% severe, 33% moderate

In this paper we focused on the ureteral sliding in no transplanted patients. In a previous review of Bertolaccini et al. [4] they report 139 cases but without separate these two categories. This trial tries to considerate the different clinical sitting of these patients with a prognosis and outcome completely different. We assert that a transplant patient should have anatomical, surgical, clinical and prognostic features totally different from a no transplanted patient. For this reason, we have proposed a new classification based on pretty clinical patterns.

Considering embryologic development, the left ureter is located posterior to the descending and the sigmoid colon; in the male the ureters intersect with the gonadal vessels, which emerge from the internal inguinal ring before bending medially to reach the prostate.

The ureter at the level of the marginal flexure, the point where it crosses the iliac vessels, is only 4–6 mm wide (in the middle part it is 8–15 mm wide), therefore even a slight stenosis at this level can cause hydronephrosis and even faster than in other cases pyonephrosis [11].

Laterally the ureter, in its passage through the iliac region, is in more or less immediate relationship with the testicular and ovarian vessels; the ureter crosses the testicular artery at the level of the third lumbar vertebra while the left testicular vein, being tributary to the left renal vein, laterally follows the left ureter [15].

Forward, the left ureter is covered by the sigmoid colon and its meso that, at this point, forms the intersigmoid dimple: the left ureter is located on the floor of this dimple at the level of the posterolateral margin. Therefore, this proximity can be a reason for its transport in the inguinal canal [7].

Sliding inguinal hernias could be completing asymptomatic or create a dangerous clinical pattern since to acute renal failure; for this reason, to avoid a misdiagnosis of this situation is important to perform a correct imaging asset and consequentially the surgical therapy (hernioplastia) that, in most of cases, is resolute with or without the treatment of acute

renal failure [9].

The main item of this study is the importance of consider every aspect of a benign disease too, like inguinal hernia; in particular the take home message states that is mandatory to evaluate overall the clinical setting of a patient, because is frequent to misunderstand subclinical patterns that, if neglected, could lead to dangerous consequences.

5. Conclusion

Sliding inguinal hernias which contain the ureter in no kidney transplanted patients reported in the literature are rare [14]. Definitive management involves repair of the hernia with care taken to preserve the ureters [10]. We have performed a literature review with a clinical classification to have a better evaluation for prognosis in relation of hydronephrosis grade and the consequent risk operative evaluation [12,13].

Consent

Written informed consent was obtained from the patient for publication of this case report and accompanying images. A copy of the written consent is available for review by the Editor-in-Chief of this journal on request.

Provenance and peer review

Provenance and peer review not commissioned, externally peer-reviewed.

Ethical approval

This study is exempt from ethical approval in our institution.

Funding

This research did not receive any specific grant from funding agencies in the public, commercial, or not-for-profit sectors.

Guarantor

Roberta Maria Isernia
Giuseppe Massimiliano De Luca.

Research registration number

This study has not a registration.

CRedit authorship contribution statement

Isernia RM, De Luca GM: study design, writing the paper

De Luca GM, Giungato S: study concept
 De Luca A, Giungato S: data collection
 Navazio LR, Franzoso L: data analysis
 Ferri V, Caruso R, Ielpo B: data interpretation.

Declaration of competing interest

Authors declare they don't have any conflict of interests.

References

- [1] A.C.M. Won, G. Testa, Chronic obstructive uropathy due to uretero-inguinalhernia: a case report, *Int. J. Surg. Case Rep.* 3 (8) (2012) 379–381, <https://doi.org/10.1016/j.ijscr.2012.04.004>.
- [2] G. De Luca, A. Tromba, A. De Luca, L. Franzoso, A. Aubed, F. Serinelli, S. Giungato, One single drug combination of bromelain and Boswellia serrata casperome®: effects on postoperative edema in open incisional abdominal hernia repair. Prospective randomized clinical trial, *Global SURGERY* 5 (1-4) (2019) 2396–7307. ISSN: 2396-7307.
- [3] R.A. Agha, T. Franchi, C. Sohrabi, G. Mathew, for the SCARE Group, The SCARE 2020 guideline: updating consensus Surgical Case REport (SCARE) guidelines, *International Journal of Surgery* 84 (2020) 226–230.
- [4] L. Bertolaccini, G. Giacomelli, R.E. Bozzo, L. Gastaldi, M. Moroni, Inguino-scrotal hernia of a double district ureter: case report and literature review, *Hernia* 9 (3) (2005 Oct) 291–293, <https://doi.org/10.1007/s10029-004-0296-4>. Epub 2005 Oct 22.
- [5] C. Hwang, F. Miller, D. Dalton, W. Hartz, Case report. Accidental ureteral ligation during an inguinal hernia repair of patient with crossed fused renal ectopia, *Clin. Imaging* (2002) 26:306.
- [6] M. Giglio, M. Medica, F. Germinale, M. Raggio, F. Campodonico, R. Stubinski, et al., Scrotal extraperitoneal hernia of the ureter: case report and literature review, *Urol. Int.* 66 (2001) 166–168.
- [7] O. Feyisetan, M.S. Floyd Jr., A. Samsudin, Obstructive uropathy secondary to bilateral ureteroinguinoscrotal herniation, *Int. Braz. J. Urol.* 42 (3) (2016 May-Jun) 621–622, <https://doi.org/10.1590/S1677-5538.IBJU.2015.0006>.
- [8] J. Giuly, G. Francois, D. Giuly, C. Leroux, R. Nguyen Cat, Intrascrotal herniation the ureter, *Ann. Chir.* 127 (2002) 218–220.
- [9] M. Renzulli, G. Marzocchi, G. Vara, B. Corcioni, A.M. Ierardi, C. Gaudiano, R. Golfieri, Inguinal ureter herniation evaluated with magnetic resonance imaging: a case report, *J. Med. Case Rep.* 14 (1) (2020 Oct 27) 202, <https://doi.org/10.1186/s13256-020-02521-7>.
- [10] W.L. Percival, Ureter within a sliding inguinal hernia, *Can. J. Surg.* 26 (1983) 283–286.
- [11] E. Gogor, C. Stroszczynski, M. Froehner, Extraperitoneal inguinoscrotal herniation of the ureter: a rare case of recurrence after hernia repair, *Urol. Int.* 83 (1) (2009) 113–115, <https://doi.org/10.1159/000224879>. Epub 2009 Jul 27.
- [12] M.E. Barns, A. Vasudevan, E.L. Marsdin, Obstructive uropathy in the context of ureteroinguinal hernia: experience of challenges in surgical management of an unwell patient, *BMJ Case Rep.* 13 (8) (2020 Aug 24), e235060, <https://doi.org/10.1136/bcr-2020-235060>.
- [13] W. Massoud, P. Eschwege, P. Hajj, A. Awad, L.A. Iaaza, J. Chabenne, Y. Hammoudi, S. Droupy, G. Benoit, Hydronephrosis secondary to sliding inguinal hernia containing the ureter, *Urol. J.* 8 (4) (2011 Fall:) 333–334.
- [14] F.P. Prete, A. Pezzolla, V. De Leo, G. Di Palma, F. Prete, Inguino-scrotal herniation of the ureter containing stones, *Hernia* 20 (6) (2016 Dec) 887–890, <https://doi.org/10.1007/s10029-015-1400-7>. Epub 2015 Jul 15.
- [15] S. Belhassen, A. Elezzi, S. Hidouri, R. Laamiri, S. Mosbahi, A. Ksaa, L. Sahnoun, M. Mekki, M. Belguith, A. Nouri, Ureterocele associated with simplex ureter in children: clinical and therapeutic features, *Pan Afr. Med. J.* 9 (38) (2021 Apr) 345, <https://doi.org/10.11604/pamj.2021.38.345.15142>.