

Comparing the Sensitivity and Specificity of Two-Dimensional Shear Wave Elastography and Fine Needle Aspiration in Determining Malignant Thyroid Nodules

Abstract

Background: Malignancy in thyroid nodules is a common clinical problem, and epidemiological studies have shown that it is increasing. Since malignancy is a very important problem in treating patients and misdiagnosis leads to many physical and financial damages, the importance of diagnostic methods becomes more important. Hence, the aim of this study was to investigate the sensitivity and specificity of the two dimensional-shear wave elastography (2D-SWE) diagnostic method in comparison with fine-needle aspiration (FNA) in determining the malignant thyroid nodules. **Materials and Methods:** This study is cross-sectional which was performed on 57 thyroid nodules are proven by conventional ultrasound. Afterward, 2D-SWE images were taken with the help of a superSonic ultrasound machine. Then, FNA was performed from the thyroid nodules and the specimens were evaluated in a single specialized thyroid pathology center. The results of conventional sonography and 2D-SWE were compared with histopathologic results as a gold standard method. The elasticity quantity was recorded by measuring the amount of the appropriate quantities by a recording machine and analyzed using the SPSS and MedCalc software. **Results:** From 57 nodules studied, 50 nodules were evaluated with benign diagnosis and 7 nodules with the malignant diagnosis. Among all the parameters recorded by the machine, SWE. ratio provided the highest surface area under the curve and the highest sensitivity and specificity with 0.94, 100% and 84%, respectively, and a cut-off point of 1.7. **Conclusion:** The 2D-SWE method and the conventional ultrasound can be good references for decision making about with the thyroid nodules.

Keyword: *Fine-needle aspiration, malignancy, two-dimensional shear wave elastography, thyroid nodules, ultrasound*

Introduction

Single or multiple thyroid nodules are one of the most common reasons for referrals of the head and neck patients or to specific clinics for endocrine disorders.^[1] The thyroid nodule is not only prevalent in Iran but also in the whole world as includes an amount of 19% and 68% of the general population.^[2,3] In the meantime, the important thing is that thyroid gland cancers appear to be in the form of a nodule.^[4] However, only a few thyroid nodules are malignant,^[2] and unfortunately, the prevalence of thyroid nodules has increased in recent years.^[5] Therefore, it is necessary to use a precise and appropriate method to detection malignancy of the thyroid nodules to prevent unnecessary surgeries in this field. The methods used to evaluate quantitatively and qualitatively the thyroid nodules include measuring the serum level

of thyroid-stimulating hormone, radioisotope scans, fine-needle aspiration (FNA), frozen section during surgery and finally conventional or advanced ultrasound.

In recent years, contrast-enhanced ultrasound and elastography^[2,6-8] by determining the structure of atypical nodules have come to help the conventional sonography to show information about perfusion and elasticity of the tissue with high quality. High-resolution ultrasound is one of the most distinguished methods for detecting thyroid nodules. This method, in spite of having limitations in the diagnosis and differentiation of benign nodules from malignant, especially atypical nodules, is generally cited as a source.

Since the malignancy or benignity of thyroid nodules are directly associated with the stiffness of the nodules, and this

**Maryam Farghadani,
Sayyid Amir
Tabatabaei,
Roozbeh Barikbin,
Armindokht
Shahsanai¹,
Maryam
Riahinezhad,
Saleh Jafarpishe**

*From the Departments of
Radiology and ¹Community
and Family Medicine, Isfahan
university of Medical Sciences,
Isfahan, Iran*

*Address for correspondence:
Dr. Sayyid Amir Tabatabaei,
Department of Radiology,
Isfahan University of Medical
Sciences, Isfahan, Iran.
E-mail: tabasamir@gmail.com*

This is an open access journal, and articles are distributed under the terms of the Creative Commons Attribution-NonCommercial-ShareAlike 4.0 License, which allows others to remix, tweak, and build upon the work non-commercially, as long as appropriate credit is given and the new creations are licensed under the identical terms.

For reprints contact: reprints@medknow.com

How to cite this article: Farghadani M, Tabatabaei SA, Barikbin R, Shahsanai A, Riahinezhad M, Jafarpishe S. Comparing the sensitivity and specificity of two-dimensional shear wave elastography and fine needle aspiration in determining malignant thyroid nodules. *Adv Biomed Res* 2019;8:30.

Received: October, 2018. **Accepted:** December, 2018.

Access this article online

Website: www.advbiores.net

DOI: 10.4103/abr.abr_215_18

Quick Response Code:



is more common in papillary thyroid carcinoma as the most common cause of malignancy of the thyroid gland nodules, it seems necessary and logical to refer to the optimal, reliable, and cited methods of supplementary recognition.^[9] Elastography is a new ultrasound tool that can assess the stiffness of various tissues such as breast, thyroid, prostate, liver, and kidney, and on the other hand, by monitoring surgical procedures, also evaluates the efficacy of these procedures.^[10] Studies have proved the value of diagnostic quasi-static elastography in determining the structure of thyroid nodules.^[11] However, the quasi-static elastography depends heavily on the operator, whereas the two-dimensional-shear wave elastography (2D-SWE) is independent and repeatable. The SWE, which is based on Young's modulus (quantitative elasticity values), works on the combination of the radiation force induced in a tissue and the recording of images that reflects these shear waves, is able to estimate the tissue stiffness.^[12,13] The stiffer tissue in Young's modulus (kPa) is higher.

Therefore, the present study was conducted with the aim of quantitative estimation of 2D-SWE for thyroid malignant nodules and the identification of interfering factors in a 2D-SWE, we hope that this method will be a good way to diagnose, evaluate, and treat thyroid nodules.

Materials and Methods

This cross-sectional study was conducted in Isfahan in 2017 and 2018 in patients with thyroid nodules, whose nodules were approved by conventional ultrasound which is done in an easy and accessible way and according to the criteria for entry and exit.

Inclusion criteria

Patients with 18 years of age or older which have a thyroid nodule selected for FNA or surgery.

1. Existence solid or nearly solid thyroid nodules in the previous ultrasound (in patients with multiple nodules, a nodule that is more suspected or larger was scheduled to undergo FNA)
2. Patients have no previous treatment for thyroid nodules and no history of radiotherapy in the head and neck area
3. Completely cystic nodules were not studied.

Exclusion criteria

Patients with unknown FNA pathology were followed up for 6 months after the study. In patients who had surgery for 6 months after performing FNA, the results of 2D-SWE were compared with the result of the surgical nodule pathology, and patients with unspecified FNA which after 6 months of FNA did not undergo surgery, were removed from the study.

In the present study, the patients were referred to the 2D-SWE imaging center on the basis of their history,

examination, disease records, and clinical and para-clinical findings.

In the first meet with the patients, the purpose of the study and the manner in which it was implemented was described to them in detail and an informed written consent of the patients was taken. After recording the required personal data and recording the medical history of the thyroid gland, the patients were studied using a 2D-SWE.

It should be noted that for patients with multiple thyroid nodules, a nodule or nodules based on 2D-SWE had more chance for malignancy were marked and finally, after doing 2D-SWE, by Radiology Resident, from those nodules, FNA were performed.

Sher wave elastography

Following conventional ultrasound by using supersonic US machine (SuperSonic Imagine, Aix en Provence, France), 2D-SWE was recorded by the same operator and transducer. When the SWE mode was activated, the transducer was held without movement and pressure. To evaluate surface nodules, more gels were used to prevent the nodule from being exposed to a transducer pressure. In the color box, the blue-colored machine was matched with soft areas and red with stiffer areas. When the images were kept in stable condition for about 10 s, the operator froze the image and stored the frozen image to match with the standard images of the machine.

Young's modulus (quantitative elasticity values) was measured. Two round quantification regions of interests (ROIs) (Q-Box™) were used to measure the lesion stiffness: One with a size of 2 mm in the stiffest area of the lesion and the other with the largest possible size in the entire lesion.

The area was selected with three features: (1) This area corresponds to the solid part of the nodule. (2) The selected area should not be in calcified or necrotic areas. (3) It was tried that the largest area be selected from the stiffest part of the lesion. The Young's modulus (quantitative elasticity values) was displayed in the ROI on the monitor, and the six quantities measured below were recorded by the machine.

- SWE. Ratio
- SWE. Whole. mean
- SWE. whole. mean
- SWE. mean
- SWE. mean
- SWE. mean
- SWE. Max.

During the measurement, another area of the normal thyroid tissue surrounding the nodule with the size of 2 mm at the same depth was measured and was recorded. The whole process took about 5 min for each nodule.

Finally, the results were analyzed by analyzing the standard SWE parameter and determining the cut-off value to

determine the probability of malignant or benign thyroid nodules. In this regard, the data were evaluated statistically after entering to SPSS version 21 (Chicago: SPSS Inc. IBM Corp.) and Med Calc software version 13.3.3.3 (Health Care Computer Systems Ltd. Data-Med, P.O. Box 148) and using the receiver operating characteristic curve, Mann–Whitney, and Chi-square tests, at a significant level of 0.05.

Results

Among 57 nodules studied, 50 nodules (87.7%) were diagnosed with benignity and 7 nodules (12.3%) with malignancy. The two groups did not differ significantly in terms of gender distribution ($P = 0.63$) and age ($P = 0.91$) [Table 1].

Regarding the type of pathology, benign follicular nodule had the highest number in the benign group as well as papillary thyroid carcinoma in the malignant group [Table 2].

Predicting the diagnosis of malignancy through the diagnostic function of the main views of conventional

Table 1: Summary of patient's demographic information

Parameter	Benign, n (%)	Malignant, n (%)	χ^2	P		
Sex						
Female	39 (68.4)	6 (10.5)	0.22	0.63		
Male	11 (19.3)	1 (1.8)				
Parameter	Mean	SD	Mean	SD	t -test value	P
Age	43.28	13.456	42.71	8.61	0.10	0.91

SD: Standard deviation

Table 2: Frequency distribution of pathology types

Type of pathology	Benign, n (%)	Malignant, n (%)
Benign follicular nodule	16 (28.10)	0
Cystic degeneration	7 (12.3)	0
Adenomatous goiter	4 (7)	0
Benign follicular nodule with cystic degeneration	4 (7)	0
Papillary thyroid carcinoma	0	6 (10.5)
Lymphocytic thyroiditis	4 (7)	0
Subacute granulomatous thyroiditis	1 (1.8)	0
Fibrotic lesion	2 (3.5)	0
Hashimoto thyroiditis	2 (3.5)	0
colloid cyst	1 (1.8)	0
Colloid goiter with cystic degeneration	1 (1.8)	0
Vascular lesion	3 (5.3)	0
Follicular lesion	1 (1.8)	0
Subacute granulomatous thyroiditis	1 (1.8)	0
Follicular carcinoma	0	1 (1.8)
Colloid goiter	3 (5.3)	0

ultrasound scales, only was significant in the presence of micro calcification (71.4% sensitivity and 82.9% specificity, $P = 0.002$) and the nodule shape (28.5% sensitivity and 97.9% specificity, $P = 0.004$). In the meantime, the remaining views did not show a significant difference. The best predictor of malignancy in conventional ultrasound was also micro calcification due to its sensitivity and specificity [Table 3].

The measured 2D-SWE values shows a significant difference between the two diagnostic groups for 57 thyroid nodules with SWE. ratio ($P < 0.001$), SWE. whole. Mean ($P = 0.03$), SWE. mean ($P = 0.03$), and SWE. min ($P = 0.03$), as mainly the meanings in the malignant group have taken much higher values. SWE. whole. min and SWE. max did not show a significant difference between the two groups ($P > 0.05$). The nodule size did not show significant differences between the two groups ($P = 0.25$). In other words, the size of the node was not evaluated for benign or malignant factors [Table 4].

The values corresponding to the area under the curve (AUC), the predictive value, and the sensitivity and specificity indicate that SWE. ratio reported the highest level (AUC = 0.94) [Figure 1].

SWE. mean with an area under the curve of 0.79 and SWE. whole. mean and SWE. min with the same area under the curve of 0.74 had the most area under the curve. By looking at the sensitivity and specificity of each parameter, it found that SWE. ratio with a sensitivity of 100% and specificity of 84% is a convenient option to choose cut-off point (cut-off value >1.7) [Figure 2].

Sensitivity for SWE. whole. mean, SWE. whole. min, SWE. mean, SWE. min, SWE. max was 71.4%, 71.4%, 85.7%, 57.1%, and 71.4%, respectively and the specificity with 74%, 80%, 66%, 82%, and 84% was reported [Table 5].

Discussion

Results achieved from 57 thyroid nodules from patients in Isfahan showed that the majority of patients had benign nodules with 87.7% of the total population. Although the majority in the study were women, it seems that thyroid nodules do not have a significant relationship with gender ($P = 0.63$) and age was also not an effective factor ($P = 0.91$). The pathological type performed was highest in benign follicular nodule and papillary thyroid carcinoma in benign and malignant groups, respectively. Five absolute parameters of 2D-SWE and SWE. ratio were taken to evaluate the stiffness of the nodule. The results showed that all 2D-SWE measurements in malignant nodules are more than benign nodules which these inequality in SWE. ratio, SWE. whole. mean, SWE. mean and SWE. min became significant ($P > 0.05$). Among all calculated values, SWE. ratio got the highest under the curve area and the highest sensitivity and specificity with values of 0.94, 100% and 84%, respectively. Accordingly,

Table 3: Diagnostic function of main conventional ultrasound imaging

Parameter	Benign, n (%)	Malignant, n (%)	χ^2	P	Sensitivity (%)	Specificity (%)
Echogenicity						
Hypo echogenicity	21 (38.2)	3 (5.5)	0.002	0.96	57.1 (18.90-8.1)	43.7 (29.5-58.8)
Nonhypo echogenicity	27 (49.1)	4 (7.3)				
Echotexture						
Inhomogeneous	30 (54.4)	6 (10.9)	1.45	0.22	85.7 (42.1-99.6)	37.5 (24-52.6)
Homogeneous	18 (32.7)	1 (1.8)				
Margin						
Poor	10 (18.2)	2 (3.6)	0.21	0.64	28.7 (3.7-71)	79.1 (65-89.5)
Well	38 (69.1)	5 (9.1)				
Shape						
Irregular	1 (1.8)	2 (3.6)	8.31	0.004	28.5 (3.7-71)	97.9 (88.99-9.9)
Oval	47 (85.5)	5 (9.1)				
Halo sign						
Absence	38 (69.1)	7 (12.7)	1.78	0.18	100 (100-59)	20.8 (10.5-35)
Presence	10 (18.2)	0				
Aspect ratio						
≥ 1	3 (5.5)	1 (1.8)	0.58	0.44	14.2 (1.4-57.9)	93.7 (82.8-98.7)
< 1	45 (81.8)	6 (10.9)				
Micro calcifications						
Presence	8 (14.8)	5 (9.3)	9.86	0.002	71.4 (29-96.3)	82.9 (69.2-92.4)
Absence	39 (72.2)	2 (3.7)				
Nodular vascularization						
Absence of blood flow	5 (8.9)	0	1.14	0.76	85.7 (42.1-99.6)	28.6 (16.6-43.3)
Peripheral vascularization	9 (16.1)	1 (1.8)				
Peri-and interanodular vascularization	34 (60.7)	6 (16.7)				
Markedly increased vascularization	1 (1.8)	0				
Color Doppler flow						
I-II type	14 (25)	1 (1.8)	0.63	0.42	14.3 (1.4-57.9)	28.6 (3.7-71)
III-IV type	35 (62.5)	6 (10.7)				

Table 4: Two-dimensional shear wave elastography measurements of thyroid nodules and size of nodules

Parameter	Benign		Malignant		Mann-Whitney U	P
	Mean	SD	Mean	SD		
SWE. ratio	1.43	0.92	3.51	1.48	3.75	<0.001
SWE. whole. mean	24.74	18.70	49.01	35.93	2.11	0.03
SWE. whole. min	8.06	9.15	5.21	7.72	1.24	0.21
SWE.mean	43.64	32.96	83.30	46.72	2.50	0.01
SWE. _{min}	33.10	24.01	66.00	41.33	2.09	0.03
SWE. _{max}	53.41	45.03	90.65	56.55	1.89	0.06
Size of nodule	23.58	13.37	19.50	14.22	1.16	0.25

SD: Standard deviation, SWE: Shear wave elastography

Table 5: Diagnostic function of two-dimensional shear wave elastography parameters in detection of thyroid nodules

Parameter	AUC	Cut-off value	Sensitivity (%)	Specificity (%)	PPV (%)	NPV (%)
SWE.ratio	0.94 (0.84, 0.98)	>1.7	100 (59, 100)	84 (70.9, 92.8)	46.7 (21.3, 73.4)	100 (91.6, 100)
SWE.whole.mean	0.74 (0.61, 0.85)	>31.2	71.4 (29, 96.3)	84 (70.9, 92.8)	38.5 (13.68, 9.4)	95.5 (85.5, 99.4)
SWE.whole.min	0.64 (0.50, 0.76)	≤ 0.4	57.1 (18.90, 4.1)	82 (68.6, 91.4)	30.8 (9.1, 61.4)	93.2 (81.3, 98.6)
SWE.mean	0.79 (0.66, 0.89)	>39.6	85.71 (42.1, 99.6)	66 (51.2, 78.8)	26.1 (10.2, 48.4)	97.1 (84.7, 99.9)
SWE. _{min}	0.74 (0.61, 0.85)	>41.9	71.4 (29, 96.3)	80 (66.3, 90)	33.3 (11.61, 8.6)	65.2 (83.99, 8.4)
SWE. _{max}	0.71 (0.57, 0.82)	>51.5	71.4 (29, 96.3)	74 (59.7, 85.4)	27.8 (9.7, 53.5)	99.95 (82.99, 7.4)

AUC: Under the curve area, SWE: Shear wave elastography, PPV: Negative predictive value, NPV: Positive predictive value

the best cut-off point can be considered by referring to SWE. ratio (cut-off value >1.7). On the other hand,

the diagnostic function of the main views of ultrasound scans showed the presence of microcalcification as the

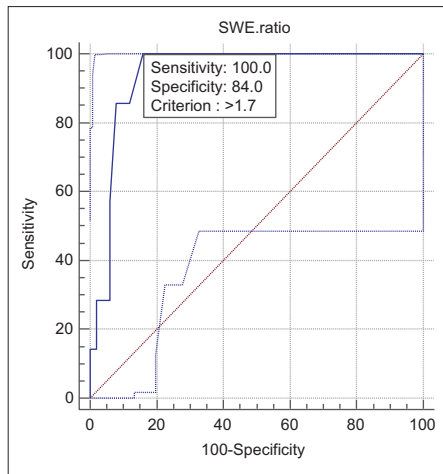


Figure 1: The fitting of Receiver Operating Characteristic curve for shear wave elastography.ratio and Figure 2 shows the fitting of Receiver Operating Characteristic curve for all the parameters

most common predictor of malignancy in conventional ultrasound. However, due to the sensitivity and specificity obtained for microcalcification of 71.4% and 82.9%, which is far less than SWE. ratio values, it is possible to say that 2D-SWE has a good diagnostic accuracy.

As we know, a little study that examined and compared the structure of thyroid nodules by the 2D-SWE method was found. Meanwhile, Liu *et al.* in a study on 331 thyroid nodules found that 101 nodules were malignant and 230 were benign. In this study, all were meaningfully evaluated among the features of thyroid nodules in conventional ultrasonography which was not heterogeneous and inconsistent with the present study. Since the implementation method was partly inspired by the project, perhaps the only reason for the heterogeneity of the results can be generalized to the sample size. On the other hand, the best predictor of microcalcification was evaluated, which is consistent with this study. From the aspect of 2D-SWE, SWE. mean it had the highest area under the curve with $AUC = 0.808$ which reported a sensitivity, specificity and the cut-off point with 66.3%, 39.3%, and 84.4%, respectively, Although the sensitivity and specificity were significantly lower than the results of the study, but was not consistent with the present study in terms of the selected parameter.^[7]

Sebag *et al.* also evaluated 146 thyroid nodules using 2D-SWE and found that out of 93 nodules, 29 were malignant, in their study, malignant nodules showed a very high SWE-max index relative to benign nodules and a cut-off value of 65 kPa with a sensitivity of 85.2% and a specificity equal to 93.9% was reported.^[5]

Bhatia *et al.* admitted that malignant nodules are generally stiffer than benign nodules and optimal cut-off value found for 2-mm ROI is equal to 34.5 kPa to diagnose papillary thyroid cancers from benign nodules with sensitivity of 76.9% and specificity equal to 71.1%.^[8]

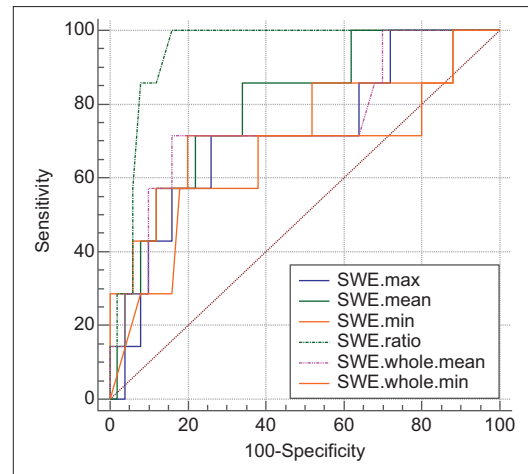


Figure 2: Performance curve (receiver operating characteristic) for measuring two dimensional-shear wave elastography

In the present study, nodule size was not evaluated for benign or malignant effects. In a study by Kim *et al.* in a 2D-SWE study, the size of nodules did not correlate with the benign or malignant nodules^[9] and therefore, it is consistent with the present study.

Another studies showed that the size of the nodule was not associated with papillary thyroid carcinoma.^[14-16] Although achieving more consistent results requires more sample volumes for more favorable citation, it is clear that the present study has few shortcomings. One can refer to the sample size as well as the purposeful and unpredictable sampling more clearly, the criteria for selecting patients in this study led to subversion, this means that this population does not represent a population of screenings, also choosing patients was from the population of the patients ready to undergo FNA or surgery, on the other hand, the 2D-SWE was only performed by a radiologist. Therefore, the lack of repetition in the measurement and meter can lead to a measuring error by the researcher.

Conclusion

The 2D-SWE method, with significant capabilities in providing information related to thyroid nodules, and using conventional ultrasonography can be the appropriate reference for important decisions regarding these patients.

Financial support and sponsorship

Isfahan University of Medical Sciences

Conflicts of interest

There are no conflicts of interest.

References

1. Dean DS, Gharib H. Epidemiology of thyroid nodules. *Best Pract Res Clin Endocrinol Metab* 2008;22:901-11.
2. Moon JH, Hyun MK, Lee JY, Shim JI, Kim TH, Choi HS, *et al.* Prevalence of thyroid nodules and their associated clinical parameters: A large-scale, multicenter-based health checkup

- study. *Korean J Intern Med* 2018;33:753-62.
3. Kitahara CM, Sosa JA. The changing incidence of thyroid cancer. *Nat Rev Endocrinol* 2016;12:646-53.
 4. Bahar A, Kashi Z, Akha A. The result of fine- needle- aspiration of thyroid nodule in patient referred to Imam Hospital Sari 2003-2011. *J Mazand Univ Med Sci* 2012;22:11-6.
 5. Sebag F, Vaillant-Lombard J, Berbis J, Griset V, Henry JF, Petit P, *et al.* Shear wave elastography: A new ultrasound imaging mode for the differential diagnosis of benign and malignant thyroid nodules. *J Clin Endocrinol Metab* 2010;95:5281-8.
 6. Magri F, Chytiris S, Capelli V, Alessi S, Nalon E, Rotondi M, *et al.* Shear wave elastography in the diagnosis of thyroid nodules: Feasibility in the case of coexistent chronic autoimmune Hashimoto's thyroiditis. *Clin Endocrinol (Oxf)* 2012;76:137-41.
 7. Liu B, Liang J, Zheng Y, Xie X, Huang G, Zhou L, *et al.* Two-dimensional shear wave elastography as promising diagnostic tool for predicting malignant thyroid nodules: A prospective single-centre experience. *Eur Radiol* 2015;25:624-34.
 8. Bhatia KS, Tong CS, Cho CC, Yuen EH, Lee YY, Ahuja AT, *et al.* Shear wave elastography of thyroid nodules in routine clinical practice: Preliminary observations and utility for detecting malignancy. *Eur Radiol* 2012;22:2397-406.
 9. Kim H, Kim JA, Son EJ, Youk JH. Quantitative assessment of shear-wave ultrasound elastography in thyroid nodules: Diagnostic performance for predicting malignancy. *Eur Radiol* 2013;23:2532-7.
 10. Veyrieres JB, Albarel F, Lombard JV, Berbis J, Sebag F, Oliver C, *et al.* A threshold value in shear wave elastography to rule out malignant thyroid nodules: A reality? *Eur J Radiol* 2012;81:3965-72.
 11. Shuzhen C. Comparison analysis between conventional ultrasonography and ultrasound elastography of thyroid nodules. *Eur J Radiol* 2012;81:1806-11.
 12. Liu BX, Xie XY, Liang JY, Zheng YL, Huang GL, Zhou LY, *et al.* Shear wave elastography versus real-time elastography on evaluation thyroid nodules: A preliminary study. *Eur J Radiol* 2014;83:1135-43.
 13. Ferraioli G, Tinelli C, Dal Bello B, Zicchetti M, Filice G, Filice C, *et al.* Accuracy of real-time shear wave elastography for assessing liver fibrosis in chronic hepatitis C: A pilot study. *Hepatology* 2012;56:2125-33.
 14. Kwon HJ, Kang MJ, Cho JH, Oh JY, Nam KJ, Han SY, *et al.* Acoustic radiation force impulse elastography for hepatocellular carcinoma-associated radiofrequency ablation. *World J Gastroenterol* 2011;17:1874-8.
 15. Wang Y, Dan HJ, Dan HY, Li T, Hu B. Differential diagnosis of small single solid thyroid nodules using real-time ultrasound elastography. *J Int Med Res* 2010;38:466-72.
 16. Tozaki M, Fukuma E. Pattern classification of ShearWave™ Elastography images for differential diagnosis between benign and malignant solid breast masses. *Acta Radiol* 2011;52:1069-75.