

Received: 2018.01.02
Accepted: 2018.02.28
Published: 2018.06.15

e-ISSN 1941-5923
© Am J Case Rep, 2018; 19: 694-698
DOI: 10.12659/AJCR.908793

An Unusual Cause of Cauda Equina Syndrome: Lumbar Epidural Venous Engorgement

Authors' Contribution:
Study Design A
Data Collection B
Statistical Analysis C
Data Interpretation D
Manuscript Preparation E
Literature Search F
Funds Collection G

ABF 1 **Husam A. Altahan**
BF 1 **Roaa R. Amer**
E 1 **Areej A. Madani**
ABEF 2 **Eman A. Bakhsh**

1 College of Medicine, King Saud bin Abdulaziz University for Health Sciences,
Riyadh, Saudi Arabia
2 Department of Neuroradiology, King Fahad Medical City, Riyadh, Saudi Arabia

Corresponding Author: Husam Altahan, e-mail: Husam-tahan@hotmail.com, Altahan066@ksau-hs.edu.sa, altahhanhu@ngha.med.sa
Conflict of interest: None declared

Patient: Female, 42
Final Diagnosis: Cauda Equina syndrome due to extensive DVT
Symptoms: Back pain • incontinence • swelling legs • weakness of the lower limbs
Medication: —
Clinical Procedure: —
Specialty: Neurology





Objective: Rare disease
Background: Epidural venous plexus (EVP) engorgement occurs due to many conditions, so it can be easily misdiagnosed. This becomes problematic when the diagnosis requires prompt treatment for a good outcome, especially when it results in cauda equina syndrome (CES). We report a case of extensive ilio caval thrombosis leading to epidural venous plexus and ascending lumbar vein engorgement as an outcome of deep venous thrombosis (DVT) due to probable adverse effects of oral combined contraceptive pills (OCCP).

Case Report: A 42-year-old woman presented to a rural medical facility with bilateral lower-limb swelling and skin darkening for 2 days. She was transferred to a tertiary medical facility where her condition deteriorated to severe CES. A lower-limbs ultrasonography confirmed the presence of extensive DVT extending to the lower segment of the inferior vena cava. Spine magnetic resonance imaging showed abnormal enhancement of the conus medullaris with thick enhanced cauda equina nerve roots, consistent with a possible case of Guillain-Barré syndrome. However, there was engorgement of the EVP extending to the ascending lumbar, azygos, and hemiazygos veins, which was misdiagnosed. The patient was managed immediately with low-molecular-weight heparin and steroids. She died 4 weeks after admission due to hospital-acquired pneumonia and acute respiratory distress syndrome, probably due to the high dose of steroids.

Conclusions: Acute CES has a wide differential diagnosis. This report describes an unusual cause of CES and emphasizes the importance of early recognition to avoid misdiagnosis and management delay. Early identification of this clinical entity markedly decreases morbidity and mortality and thus improves the prognosis. Likewise, underlying causing factors such as venous congestion due to OCCP-related DVT should be considered in the diagnosis.

MeSH Keywords: Cauda Equina • Central Nervous System Vascular Malformations • Diagnosis • Venous Thrombosis

Full-text PDF: <https://www.amjcaserep.com/abstract/index/idArt/908793>

 2023  —  5  21



Background

Epidural venous plexus engorgement can be seen in multiple conditions, including pregnancy, bony disease, disc herniation, external spinal canal compression, and deep venous thrombosis (DVT) [1–3]. Extensive thrombosis resulting in extreme epidural varices has been described as a very rare etiology of nerve root or cord compression [1]. The majority of reported cases were associated with mild neurological symptoms, including pain, dermatomal sensory deficits, and motor deficits. Only a few cases in the literature, locally and internationally, describe extensive thrombosis in the caval system leading to complete paraplegia. If early diagnosis and management are commenced before the progression into neural infarction, the symptoms can be regressed and resolved [4]. Here, we report a case of extensive ilio caval thrombosis leading to epidural venous plexus and ascending lumbar vein engorgement due to extensive DVT, and the rapid course of treatment provided to the patient. The underlying cause of cauda equina syndrome was later recognized as epidural venous engorgement due to DVT, which resulted in delayed and ineffective treatment of the patient.

Case Report

A 42-year-old woman with no significant prior medical and surgical history was presented to a rural emergency department (ED) in Qasim, with limited medical services. She reported acute bilateral lower-limb swelling and skin darkening that had begun to appear 2 days ago. Based on bedside ultrasound results and the clinical symptoms, a presumptive diagnosis of DVT was made, and a prescription of a low-molecular-weight heparin (LMWH), called Enoxaparin, was promptly administered once daily at 1.5 mg/kg/day. Upon request, she was transferred to the ED of our tertiary-care hospital in Riyadh. In our ED, the patient developed acute severe lower back pain with lower-limb weakness, numbness, fecal incontinence, and urinary retention over a period of 2 hours. The patient had no previous history of recent upper respiratory tract infection or thrombosis; however, she had experienced mild intermittent back pain for the past year, for which she did not seek any medical attention. She also reported the use of oral combined contraceptives (OCCP) – ethinyl estradiol and drospirenone (Yasmin) – beginning 2 months before presentation.

On examination, her lower limbs were both swollen, and the skin was red tinged with blue. Her lower-limb pulses were intact. A motor exam of the lower limbs showed significant weakness and sensory loss to fine touch in both legs. The plantar responses were flexor bilaterally. Spine examination was difficult to conduct due to severe pain. An abdominal examination showed a distended bladder up to the umbilical level.

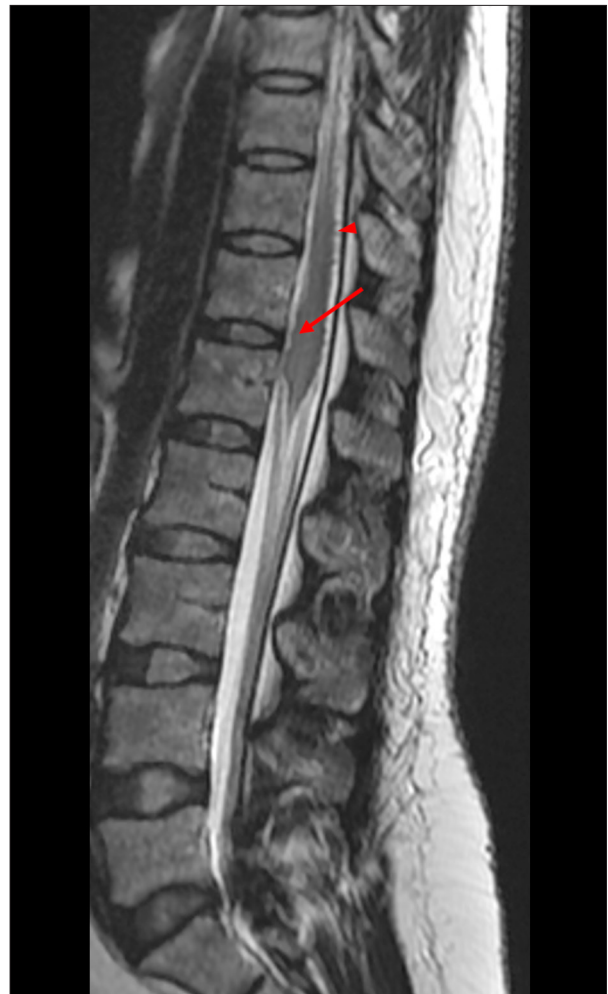

Figure 1. Sagittal T2-weighted MRI image showing an enlarged conus medullaris with diffuse ill-defined T2 hyperintensity at the T12-L1 level (arrow) in conjunction with enlarged epidural veins located at the posterior surface of the lower cord and the conus region (arrowhead).

Anal sphincter tone was lost. A urinary catheter was inserted and drained 4 liters of urine immediately after insertion. The patient was immediately given subcutaneous LMWH for the DVT and steroids for suspected spinal cord compression.

Initial laboratory tests, including complete blood count and coagulation profile, were negative. The official lower-limb ultrasound report confirmed the presence of extensive DVT with acute partial thrombosis of the right common femoral vein and complete thrombosis of the left lower-limb veins extending to the left external iliac vein and the lower segment of the inferior vena cava (IVC), indicating lesions in lower motor neurons (LMNL). Furthermore, initial spinal magnetic resonance imaging (MRI) showed an enlarged conus medullaris with intramedullary diffuse T-2 hyperintensity extending from T12 to

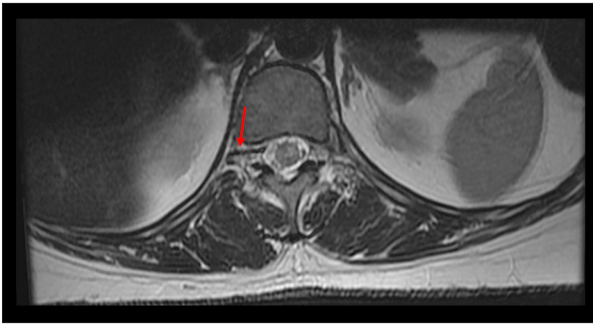


Figure 2. Axial T2-weighted MRI image confirming the presence of an ill-defined intramedullary conus lesion with prominent enlarged epidural veins (arrow) and a vertebral venous plexus.

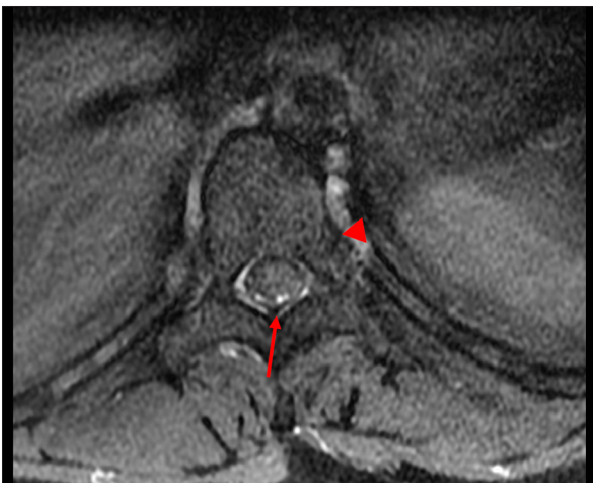

Figure 3. Post-contrast axial T1-weighted MRI image with fat suppression, showing the absence of enhancement of the intramedullary lesion, whereas enhancement is seen posterior to the spinal cord along the dilated prominent posterior epidural vessels (arrow) with a prominent perivertebral venous plexus (arrowhead).

L1, with enlarged posterior epidural veins (Figure 1) and enlarged ascending lumbar veins (Figure 2). However, the post-contrast axial T-1 image showed abnormal enhancement of the enlarged epidural veins, which was misinterpreted as abnormal enhancement of the conus medullaris, and was reported as possible spinal cord thrombosis leading to arachnoiditis or Guillain-Barré syndrome (GBS) (Figure 3). In conclusion, there was no evidence of spinal cord compression. Thus, the differential diagnosis included neuromyelitis optica-like disease and inflammatory or immunological disease.

The patient was admitted to our Neurology Department for further workup and management, with a diagnosis of non-compressive CES. Extensive serological and immunological tests, including those for herpes simplex I/II, cytomegalovirus, VDRL, FTA-abs, hepatitis B, antinuclear antibodies, complement

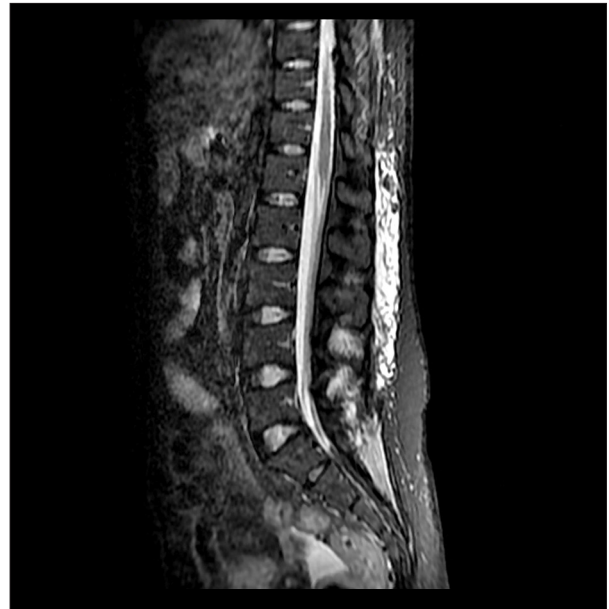

Figure 4. Sagittal T2-weighted MRI image showing regression of the conus medullaris lesion and the engorged epidural vessels presenting significant evidence suggesting DVT.

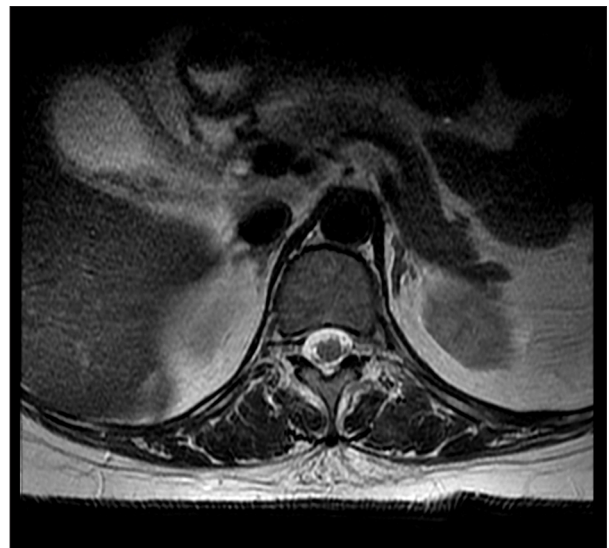

Figure 5. Axial T2-weighted MRI image confirms the regression of the intramedullary diffuse T2 conus lesion.

(C3, C4), 1-glycoprotein, ANCA-p, ANCA-c, and HTLV-I/II, yielded normal results. All tumor markers were negative. Vitamin B12 and E levels were normal. Homocysteine and coagulation factor levels were all normal, and factor 5 Leiden mutation was negative. A lumbar puncture was done to look for signs of GBS, but it only showed mild leukocytosis with normal protein levels. Abdominal and pelvic computed tomography showed no evidence of tumors or metastasis, ruling out the possibility of a paraneoplastic cause for the patient's condition.

The electrophysiologic studies (electromyography and nerve conduction studies) were performed at admission and were reported normal. Because of the patient's condition, an inferior vena cava filter was inserted to prevent pulmonary embolism and avoid further complications. The patient received multiple rounds of intravenous immunoglobulins based on the initial differential diagnosis. However, her condition continued to deteriorate. One month after admission, a repeat whole-spine MRI showed improvement of the intramedullary lesions and epidural venous plexus engorgement (Figures 4, 5). No evidence of an arteriovenous malformation or fistula (AVM/AVF) was detected on spinal MRI, which was confirmed by angiography. The characteristic radiological pattern on MRI raised the possibility of epidural venous engorgement. Treatment with anticoagulants was continued and endovascular stenting of the thrombosed veins was considered. Unfortunately, 4 weeks after admission, she developed hospital-acquired pneumonia and acute respiratory distress syndrome. Resuscitative efforts were initiated but proved to be futile.

Discussion

As originally described by Gilbert Breschet and Batson, the vertebral venous system is a large, valveless, low-pressure system classified into caval, pulmonary, portal, and vertebral divisions [5,6]. The venous drainage of the spinal cord consists of 2 systems: intrinsic and extrinsic [6,7]. The intrinsic venous system is composed of an epidural venous plexus that eventually drains into the extrinsic venous system [6,7]. The extrinsic venous system is composed of the pial venous plexus in addition to the anterior and posterior spinal veins that eventually join the caval system, mainly the innominate veins at the cervical level, the azygos vein at thoracic level, and the ascending lumbar vein at the lumbar level [7].

The epidural venous plexus anastomoses with the ascending lumbar veins via the intervertebral vein [7]. These ascending lumbar veins then drain into the vena cava via segmental lumbar veins [7]. Thus, any obstruction in the lower segment of the caval system results in hypertension in the ascending lumbar veins, which refluxes into the epidural venous plexus, causing its engorgement and leading to CES. This, in turn, can lead to spinal cord infarction and thrombosis if the diagnosis was missed and treatment delayed.

In our patient, there was a delay in treatment due to misdiagnosis of CES due to epidural venous engorgement. No advanced imaging modality was undertaken when the patient initially presented, and treatment was initiated based on the initial bedside Doppler ultrasound results and clinical suspicion of DVT and its extensiveness in causing lumbar engorgement. Upon the patient's arrival at our facility, MRI was done

to exclude spinal cord compression. Compression was excluded, and the pattern seen on the initial spinal MRI was consistent with spinal cord thrombosis, which was misinterpreted as possible arachnoiditis or GBS. An important contributing factor further complicating the situation was an overly-distended bladder which could have compressed the pelvic venous return, further impeding the venous return. This may have resulted in venous thrombosis that prevented the nearby tissues from receiving oxygenated blood and adequate nutrient exchange causing significant tissue damage.

It is also important to consider AVM/AVF in the differential diagnosis of such cases of CES, as it was considered a possible diagnosis on radiological imaging presenting similar MRI patterns for epidural venous engorgement. Another differential includes Foix-Alajouanine Syndrome (FAS), a congestive myelopathy that is hypothesized to occur due to a decrease in arteriovenous pressure gradient and a decrease in cord perfusion as a result of an existing AVF [8]. In FAS, the MRI pattern usually shows the same pattern of hyperintensity on T2-weighted images and decreased signal enhancement on T1-weighted images [9,10]. Therefore, both FAS and DVT leading to epidural venous plexus engorgement can present as CES. In this context, the diagnostic attributes of occult AVF due to thrombosis of draining veins that confirm FAS are discussed elsewhere [11,12]. As a result, our patient's angiogram and whole-spine MRI confirmed the absence of an AVM, which made the diagnosis of FAS much less likely, and suggesting a diagnosis of DVT.

In our case, no clear cause of this radiological pattern was identified. Henceforth, considering that our patient had extensive venous thrombosis that may have led to venous congestion and neurological sequela. This was most probably due to the use of OCCP. The link between OCCP containing estrogen and DVT is well established in the literature [13]. However, recent studies have illustrated that the addition of progestin contributes to an increased risk of DVT, but not if it was used alone, as it was shown by a systematic review [14,15]. One study shows that overall, OCCP increases the risk of thrombosis by 5-fold, and drospirenone, which is what our patient was using, specifically increases the risk by 6.3-fold [16]. The risk of DVT is high even in the first few months of using OCCP.

Our patient was using ethinyl estradiol and drospirenone (Yasmin) for 2 months prior to the onset of her symptoms, which appears to be the only possible explanation for her DVT. Correspondingly, researchers have previously acknowledged that currently available oral contraceptives, especially those containing drospirenone (a fourth-generation progestin), present several thrombotic risk factors, including trauma, tumor, and other venous thromboembolic events such as pulmonary embolism [17]. Several studies have also reported

cases associated with OCCP-related deep vein thrombosis in the cerebral, bilateral, and pelvic regions [18]. However, DVT extending to the lower segment of inferior vena cava with engorgement of the conus medullaris with thick enhanced cauda equina nerve roots is an unusual occurrence with respect to OCCP use [14].

Treatment of cases such as ours consists of managing the disease and its secondary complications, as well as identifying and rectifying the underlying causative factor, which in our case was the use of OCCP. In our patient, the disease was complicated by an extensive area of thrombosis involving the right femoral vein and left external iliac vein, for which an IVC filter was inserted. The treatment options for such a complication could be noninvasive, such as using oral or intravenous anticoagulants, or invasive, such as using catheter-directed thrombolysis or power pulse spray [19]. Other feasible treatment options include mechanical thrombectomy and balloon venoplasty [19]. If all other options fail, surgical thrombectomy or bypass surgery may be considered [20,21]. However, for our patient, commencement of noninvasive anticoagulants was considered to aid in attaining improved MRI findings related to intramedullary lesions and epidural venous plexus engorgement. Most cases described in the literature also had a favorable prognosis with our treatment. Nevertheless, there is no doubt that delayed diagnosis and lack of recognition of DVT due to OCCP may have led to a poor outcome, which may

have been the case in our patient. Her delayed diagnosis was due to being misdiagnosed with other more common diseases such as GBS for which she was given intravenous immunoglobulin (IVIg) without positive results, in addition to the initial incorrect MRI report. Furthermore, the results of the MRI and angiography, which showed no evidence of AVM, made the diagnosis of FAS far less likely owing to the rare association with CES and factors related to epidural venous engorgement. Due to this ambiguity, other causes of DVT were left unchecked. Likewise, an OCCP-related DVT should have been considered and might have directed the treatment towards more effective anticoagulation therapy.

Conclusions

Acute cauda equina syndrome (CES) has a wide differential diagnosis. However, atypical etiologies are important to keep in mind when encountering such cases. This report describes a cause of extensive ilio caval thrombosis leading to engorgement of the epidural venous plexus as an unusual cause of CES, which was probably generated due to the use of OCCP. Therefore, we emphasize the importance of recognition of venous congestion caused by DVT due to adverse effects related to OCCP to avoid misdiagnosis and delay in management. Early identification of this clinical entity markedly decreases morbidity and mortality, thus improving the patient's prognosis.

References:

1. Mohit AA, Fisher DJ, Matthews DC et al: Inferior vena cava thrombosis causing acute cauda equina syndrome: Case report. *J Neurosurg*, 2006; 104(1 Suppl.): 46-49
2. Hanley EN Jr, Howard BH, Brigham CD et al: Lumbar epidural varix as a cause of radiculopathy. *Spine*, 1994; 19(18): 2122-26
3. Donmez FY: Epidural venous plexus engorgement: What lies beneath? *Case Rep Radiol*, 2015; 2015: 965106
4. Go MR, Baril DT, Leers SA, Chaer RA: Acute cauda equina syndrome secondary to ilio caval thrombosis successfully treated with thrombolysis and pharmacomechanical thrombectomy. *J Endovasc Ther*, 2009; 16(2): 223-27
5. Nathoo N, Caris EC, Wiener JA, Mendel E: History of the vertebral venous plexus and the significant contributions of Breschet and Batson. *Neurosurgery*, 2011; 69: 1007-14
6. Tobinick E, Vega CP: The cerebrospinal venous system: anatomy, physiology, and clinical implications. *MedGenMed*, 2006; 8(1): 53
7. Miyasaka K, Asano T, Ushikoshi S et al: Vascular anatomy of the spinal cord and classification of spinal arteriovenous malformations. *Interv Neuroradiol*, 2000; 6(Suppl. 1): 195-98
8. Krishnan P, Banerjee TK, Saha M: Congestive myelopathy (Foix-Alajouanine Syndrome) due to intradural arteriovenous fistula of the filum terminale fed by anterior spinal artery: Case report and review of literature. *Ann Indian Acad Neurol*, 2013; 16(3): 432-36
9. Salomão R, Canêdo NHS, Abrão GP et al: Foix-Alajouanine syndrome mimicking a spinal cord tumor. *Rev Assoc Med Bras*, 2017; 63(7): 564-65
10. Kumar A, Deopujari CE, Mhatre M: Misdiagnosis in a case of non-compressive myelopathy due to a lumbar spinal intradural fistula supplied by the Artery of Adamkiewicz. *Surg Neurol Int*, 2011; 2: 12
11. Hurst RW, Kenyon LC, Lavi E et al: Spinal dural arteriovenous fistula: The pathology of venous hypertensive myelopathy. *Neurology*, 1995; 45(7): 1309-13
12. Matsubara T, Akutsu H, Watanabe S et al: Histologically proven venous congestive myelopathy without concurrent vascular malformation: Case reports and review of the literature. *Surg Neurol Int*, 2012; 3: 87
13. Trenor CC III, Chung RJ, Michleson AD et al: Hormonal contraception and thrombotic risk: A multidisciplinary approach. *Pediatrics*, 2011; 127(2): 347-57
14. Tepper NK, Whiteman MK, Marchbanks PA et al: Progestin-only contraception and thromboembolism: A systematic review. *Pediatrics*, 2016; 94(6): 678-700
15. Kim JY, Kim YS: Pulmonary embolism and deep vein thrombosis related to oral contraceptive use. *Obstet Gynecol Sci*, 2013; 56(4): 273-76
16. van Hylckama Vlieg A, Helmerhorst FM, Vandenbroucke JP et al: The venous thrombotic risk of oral contraceptives, effects of oestrogen dose and progestogen type: Results of the MEGA case-control study. *BMJ*, 2009; 339: b2921
17. Larivée N, Suissa S, Khosrow Khavar F et al: Drospirenone containing oral contraceptive pills and the risk of venous thromboembolism: A systematic review of observational studies. *BJOG*, 2017; 124(10): 1490-99
18. Lambert M, Marboeuf P, Midulla M et al: Inferior vena cava agenesis and deep vein thrombosis: 10 patients and review of the literature. *Vasc Med*, 2010; 15(6): 451-59
19. Sildiroglu O, Ozer H, Turba UC: Management of the thrombosed filter-bearing inferior vena cava. *Semin Intervent Radiol*, 2012; 29(1): 57-63
20. Jost CJ, Gloviczki P, Cherry KJ Jr. et al: Surgical reconstruction of iliofemoral veins and the inferior vena cava for nonmalignant occlusive disease. *J Vasc Surg*, 2001; 33(2): 320-27
21. Davenport DL, Xenos ES: Early outcomes and risk factors in venous thrombectomy: An analysis of the American College of Surgeons NSQIP dataset. *Vasc Endovascular Surg*, 2011; 45(4): 325-28