

# Ultrasonographic and macroscopic comparison of the thickness of the capsule, corium, and soft tissues in bovine claws: an *in vitro* study

Goksen Cecen<sup>1</sup>, Hakan Salci<sup>1,\*</sup>, Deniz Seyrek Intas<sup>1</sup>, Nureddin Celimli<sup>1</sup>, Gulsum Ulke Caliskan<sup>2</sup>

<sup>1</sup>Department of Surgery, Faculty of Veterinary Medicine, Uludag University, 16059 Bursa, Turkey

<sup>2</sup>Department of Veterinary, Ihsangazi Vocational School of Higher Education, Kastamonu University, 37200 Kastamonu, Turkey

This study aimed to compare thickness of the capsule, corium, and soft tissues measured ultrasonographically and macroscopically in selected regions of bovine claws. A hundred and twenty claws (n = 120) of 15 healthy Holstein bovines were obtained. After cleaning the claws, ultrasonographic measurement of the capsule, corium, and soft tissues was performed while submerging the claws in a water bath. Macroscopic measurements were taken after cutting of the claws axially. These values were compared statistically. According to the macroscopic measurements, the mean thickness  $\pm$  standard deviation (SD) of the capsule for dorsal wall and sole was  $6.2 \pm 0.1$  and  $9.5 \pm 0.4$  mm, respectively. The thickness of the corium and soft tissues for dorsal wall and sole was  $4.5 \pm 0.1$  and  $5.3 \pm 0.1$  mm, respectively. Ultrasonographically, the mean thickness  $\pm$  SD of the capsule for dorsal wall and sole was  $4.7 \pm 0.1$  and  $7.8 \pm 0.3$  mm, respectively. The thickness of the corium and soft tissues for dorsal wall and sole was  $4.3 \pm 0.1$  and  $5.9 \pm 0.2$  mm, respectively. Findings demonstrated that ultrasonography can be reliably to measure of the thickness of the hoof capsule, corium, and soft tissue in bovine claw.

**Keywords:** bovine claw, ultrasound

## Introduction

The most common clinical methods for estimating sole horn thickness in cattle involve compression of the sole horn with a finger or indirect palpation with a hoof nipper [14-16]. Previous studies [6,15] on bovine claws have involved measuring sole horn thickness and the underlying soft tissue layer by ultrasonography. Although this technique is a useful diagnostic tool, its usage in bovine claw is still being debated among practitioners [6,11,15].

The application of ultrasonography for measuring the sole horn and underlying soft tissue layer in healthy bovine claws was first introduced and tested in a preliminary study performed by Kofler *et al.* [6]. This group investigated preparation of the claws, the use of various transducer frequencies, and different ultrasound machines. A subsequent study by the same researchers demonstrated that bovine claws were a derivative form of skin [6]. Therefore, the use of diagnostic ultrasound for examining the sole horn and underlying soft tissue layer could be promising. The authors also evaluated sole horn thickness with

the underlying soft tissues, and assessed differences between the dorsal wall and sole in bovine claws by ultrasonographic imaging. In other studies [6,15,16], thickness of the corium and soft tissue of the hind claws in dairy cattle was measured by ultrasound and appropriate techniques have been described. Additionally, the relationship between differences in the measured thickness and biomechanics of the claw has been discussed in veterinary practice [16]. The objective of the present study was to compare thickness of the capsule, corium, and soft tissues measured by ultrasonography and macroscopically in selected regions of the paries unguales and sole in bovine claws. Results of the investigation emphasized the usefulness of ultrasonography in bovines.

## Materials and Methods

This study included all claws of 15 Holstein dairy cows (n = 120) of different ages and weighing between 230 and 450 kg. The claws were randomly collected from a slaughterhouse in Bursa (Turkey). The animals were not lame and were clinically

Received 30 Apr. 2014, Revised 21 Jul. 2014, Accepted 27 Sep. 2014

\*Corresponding author: Tel: +90-224-294-0841; Fax: +90-224-294-0873; E-mail: [hsalci@uludag.edu.tr](mailto:hsalci@uludag.edu.tr)

Journal of Veterinary Science • Copyright © 2015 The Korean Society of Veterinary Science. All Rights Reserved.

This is an Open Access article distributed under the terms of the Creative Commons Attribution Non-Commercial License (<http://creativecommons.org/licenses/by-nc/3.0>) which permits unrestricted non-commercial use, distribution, and reproduction in any medium, provided the original work is properly cited.

pISSN 1229-845X

eISSN 1976-555X

healthy. After slaughter, the samples were transferred to Uludag University Faculty of Veterinary medicine Department of Surgery Clinics where they were cleaned in order to eliminate artifacts during ultrasonographic examination as previously recommended [6].

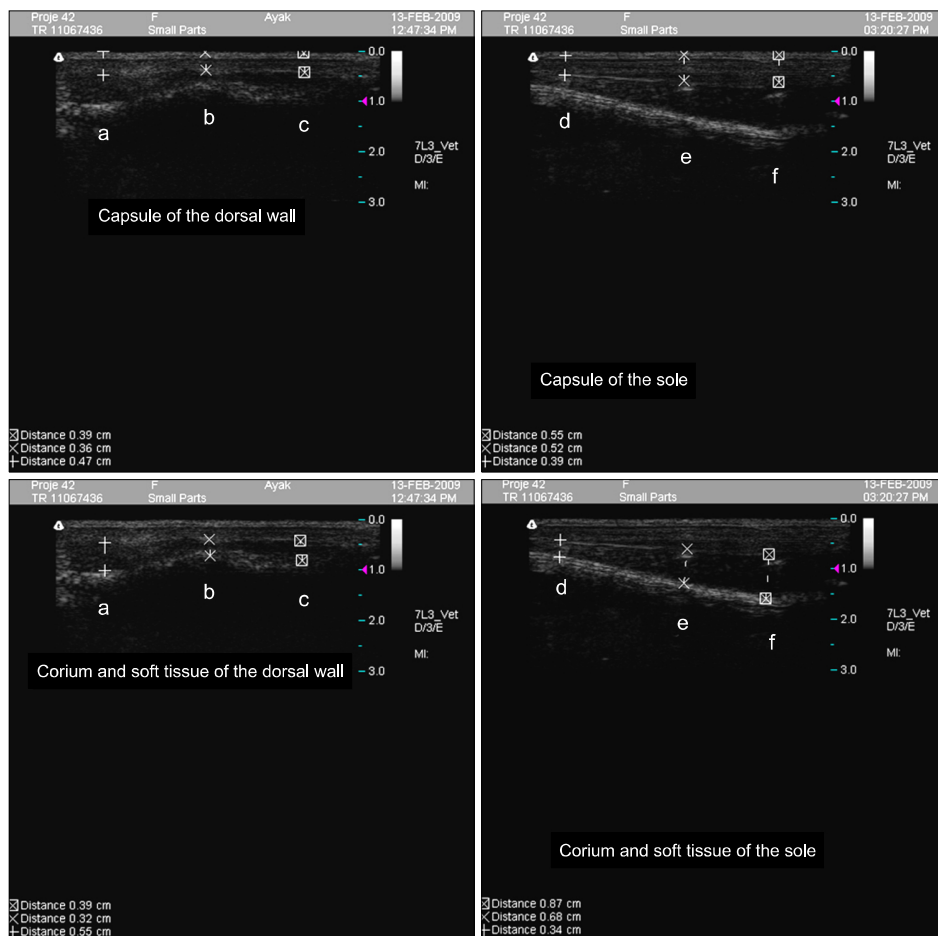Ultrasonography was performed with a 5~7.5 MHz linear transducer (Terason, USA) in a water bath. Because bony surfaces reflected the ultrasonographic waves, thickness of the capsule, corium, and soft tissues of all claws (Fig. 1) was measured from different points in the dorsal wall (a, b, and c) and sole (d, e, and f). Accuracy of the ultrasonographic measurement points was established by placing an injector needle. These points had diagnostic importance for identifying cases of laminitis as previously described [6]. The measurement points presented in Fig. 2 represented the (a) distance between the surface of the third phalanx (P3) and outer surface of the claw horn below the extensor process, (b) midpoint of the dorsal margin of P3 perpendicular to the dorsal claw wall, (c) a few millimeters proximal to the apex of P3 perpendicular to the dorsal claw wall,

(d) a few millimeters palmar/plantar to the apex of P3 at the solar margin of P3 perpendicular to the sole, (e) midpoint of the solar margin of P3 perpendicular to the solar surface of P3, and (f) cranial to the tuberculum flexorium perpendicular to the solar surface of P3. After the claw was cut sagittally with a band saw (Shandon, Turkey), macroscopic measurements were performed with a compass (Max Extra, China) at the sole and dorsal wall (Fig. 3).

SPSS software (ver. 13.0, SPSS, USA) was used to perform the statistical analysis. Continuous variables are expressed as the mean ± standard deviation (SD). Differences between the ultrasonographic and macroscopic measurements were compared with a Mann-Whitney U test. Relationships between variables were tested with Pearson's correlation analysis. *P* values < 0.05 were considered significant.

## Results

Ultrasonographically, the horn capsule of the claw had



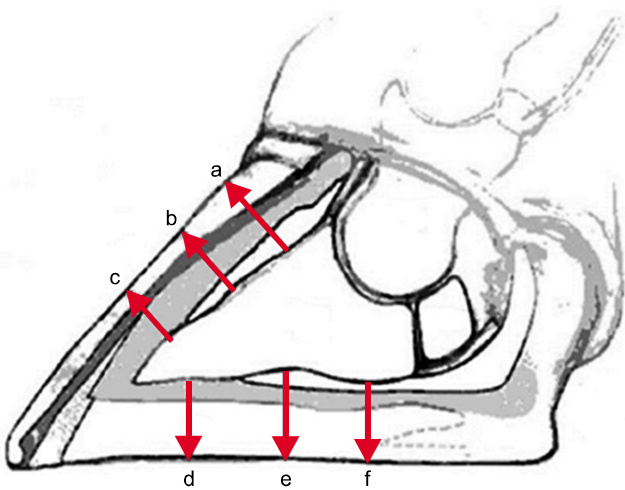
**Fig. 1.** Ultrasonographic measurement points (a, b, c, d, e, and f) for the capsule, corium, and soft tissue in the sole and dorsal wall of the bovine claw.

moderate echogenicity with echogenic spots homogeneously distributed. The boundary of the corium layer was not clearly discernible. However, a relatively significant and very thin echogenic line was identified. The soft tissues (corium and subcutis) appeared as a hypoechoic layer with a homogeneous echo pattern and could be seen in all claws. The bone surface appeared as a hyperechoic line. At the sole, this line could be followed from the apex along the central concavity up to the tuberculum flexorium. The insertion area of the flexor tendon, the articular surfaces of the P3, and distal sesamoid bone were observed when the probe was moved towards the heel. Distinction between the horn and soft tissues was more difficult

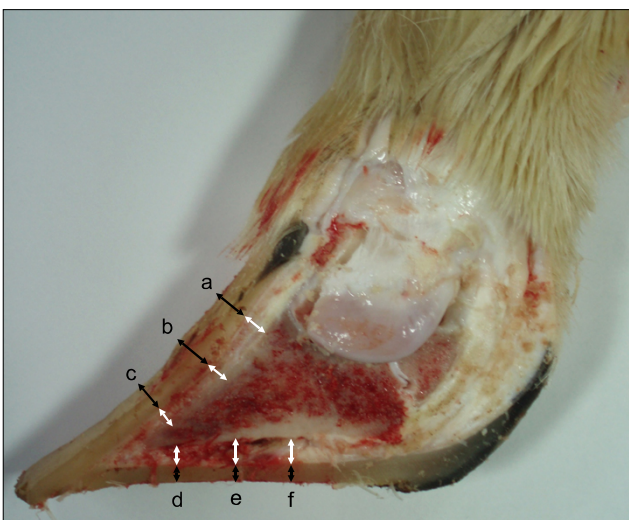
at the apex of the claw compared to weight-bearing surfaces. Imaging of the capsule, soft tissues, and bone surface was more difficult when the sole was thick.

Ultrasonographic examination was easily performed on the smooth surface of the dorsal wall. The capsule and corium had almost the same level of echogenicity. Although the transition line from the capsule to the corium was not as distinct at the sole, it could be seen as a thin echogenic line. The P3 surface was observed as a bright hyperechoic line. Image quality was reduced with the presence of horizontal grooves on the dorsal wall.

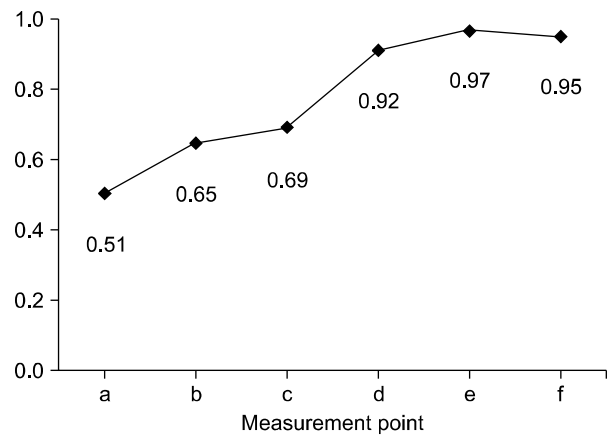
Average thickness of the capsule at different measurement points ranged from 0.51 to 0.69 cm at the dorsal wall and from 0.92 to 0.95 cm at the sole (Fig. 4). Average thickness of the corium with soft tissues at different measurement points ranged from 0.40 to 0.52 cm at the dorsal wall and from 0.40 to 0.62 cm at the sole (Fig. 5). Comparison of the ultrasonographic and macroscopic measurements revealed that ultrasonographic



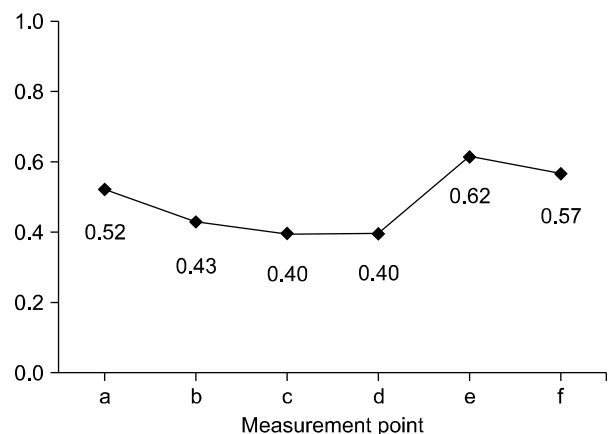
**Fig. 2.** Schematic view of the measurement points (a, b, c, d, e, and f) in the bovine claw.



**Fig. 3.** Macroscopic view of the measurement points (a, b, c, d, e, and f) in the bovine claw. (black and white arrows indicate the capsule, corium, and soft tissue thickness, respectively).



**Fig. 4.** Capsule thickness (cm) for 15 bovines at different measurement points (macroscopic).



**Fig. 5.** Corium and soft tissue thickness (cm) for 15 bovines at different measurement points (macroscopic).

**Table 1.** Thickness of the capsule and corium with the subcutaneous tissue (cm) at different measurement points determined ultrasonographically (US) or macroscopically (M)

	Capsule						Corium with subcutaneous tissues					
	a	b	c	d	e	f	a	b	c	d	e	f
US	0.49	0.47	0.47	0.70	0.77	0.76	0.46	0.43	0.44	0.52	0.66	0.62
M	0.52	0.65	0.71	0.88	0.96	0.93	0.54	0.45	0.41	0.40	0.61	0.56

**Table 2.** Correlation coefficients determined by comparison of ultrasonographic and macroscopic measurements at different locations

Measurement point	Capsule	Corium with subcutaneous tissues
a	0.5	0.5
b	0.5	0.5
c	0.6	0.4
d	0.9	0.1
e	0.8	0.1
f	0.7	0.1

**Table 3.** Ratio of the capsule: corium with subcutaneous tissue values at different measurements points defined ultrasonographically (US) or macroscopically (M)

	a	b	c	d	e	f
M	1.0	1.5	1.7	2.2	1.6	1.7
US	1.1	1.1	1.1	1.3	1.2	1.2

values for the capsule were smaller than the macroscopic measurements. Contrarily, ultrasonographic measurements of the corium with soft tissues were greater than (or equal to) macroscopic measurements at points c, d, e, and f (Table 1). Differences between the ultrasonographic and macroscopic measurements were all statistically significant except those taken at point a. However, the correlation coefficients were relatively large. Values for the corium and soft tissues measured ultrasonographically and macroscopically showed a very weak statistical relationship, especially data for the sole (Table 2). The ratio of capsule to soft tissue thickness determined macroscopically indicated that the dorsal horn capsule becomes gradually thicker towards distal points (a~c), reaches a maximum at the sole at point d, decreases at point e, and becomes thicker again at point f. Ultrasonographic measurements showed a very similar pattern (Table 3).

The relationship of age and body weight with macroscopic thickness measurements of the capsule showed that these

**Table 4.** Correlation coefficients demonstrating the relationship of tissue thickness measured macroscopically with age and body weight

	Measurement point					
	a	b	c	d	e	f
Capsule						
Age		0.4	0.4	0.5	0.5	0.4
Body weight		0.2	0.4	0.5	0.5	0.4
Corium with subcutaneous tissues						
Age		0.4	0.5	0.5	ns	ns
Body weight		0.5	0.4	0.4	ns	ns

ns: not significant.

factors did not have a very strong positive correlation for any measurement points. A significant positive correlation between corium with soft tissue measurements and age or body weight were found only at measurements points a, b, and c (Table 4). Location of the claw was not associated with any differences in thickness of either the capsule or soft tissues ( $p > 0.05$ ).

## Discussion

Thickness and hardness of the claws can affect ultrasonic sound waves in cattle. Penetration of the waves depends on water content of a tissue. If an anatomic structure has a high water content, better ultrasonographic image can be obtained [2,8]. Kofler *et al.* [6] reported that freezing of the claws for storage and thawing in a water bath prior to ultrasonography leads to a high water content in the horn tissue and results in a relatively soft sole horn that helps facilitate imaging of the various structures. The sole horn of fore claws in cattle is harder than the hind claws due to a lower water content. Aside from differences in water content, different numbers of horny tubules also affect penetration of ultrasound waves in the dorsal wall and sole [3,13,16]. In the present study, specimens were ultrasonographically examined in a water bath to enhance image quality. Consequently, the sole horn, corium, soft tissues, and P3 surface could be identified easily. Quality of images

from the dorsal wall and sole significantly differed. Images of the sole could be obtained clearly without artifacts. In contrast, optimal images of the dorsal wall took more time to obtain due to the dryer and harder dorsal claw wall, but were easily acquired for the smooth surface of the dorsal wall.

Water content of the horn leads to prolongation of the examination time and optimization of image quality [6]. A study investigating horn quality of bovine claws [12] demonstrated that water content of the sole horn in fore claws was lower (19.8%) compared to sole horn of the hind claws (25.0%). Similarly, water content of the wall horn of the fore claws and hind claws was 10.2% and 14.7%, respectively. Ultrasonographic performed in the present study produced satisfactory results, but a longer examination time in the water bath has a disadvantage.

Previously, a sagittal section of a claw was used to determinate the gross pathology of the foot [4]. Thus, macroscopic examination and measurement with a compass were performed in sagittal sections of the claws. Kofler *et al.* [6] noted that the sole appeared as a heterogeneous structure on ultrasonographic images. In the current study, the horn layer was hypoechoic and homogenous. Additionally, differences between the dorsal wall and sole were not detected.

Although anatomical measurements of the capsule and soft tissues of the dorsal wall and sole have been reported in several studies [1,4,6,9,17], a few methodological differences can be found. In general, capsule thickness varies greatly in the sole. In contrast, soft tissue values do not widely differ. Kofler *et al.* [6] measured capsule thickness at three different points in 100 cows that were a different breed, gender, and age than the animals used in the present study. Compared to our study results, the values reported by Kofler *et al.* were nearly half. In other publications, soles were designated as 'thin' if the sole horn thickness was  $< 5$  mm. [5,7,10,14]. In the present investigation, sole thickness was about 5 mm, which was related to a higher dorsal wall thickness as previously described [5,10].

It has been reported that thickness of the lateral claw sole is significantly less than the medial claw in cows [7]. Van Amstel *et al.* [17] reported sole thickness as  $4.23 \pm 0.18$  mm and  $5.15 \pm 0.18$  mm for lateral and medial claws, respectively. In the present study, sole thickness less than 5 mm was not observed, and differences between sole thickness of the lateral and medial claws were not significant. Browne *et al.* [1] evaluated beef bulls and dairy heifers 19~20 months old and reported values lower than ours. Greenough *et al.* [4] reported lower sole thickness in 8-month-old Charolais crossbred calves similar to the values we observed. Moreover, there was a moderate positive correlation between sole thickness and age.

Kofler *et al.* [6] reported high correlation coefficients (0.91 to 0.88) for sole horn thickness measured by ultrasonography or anatomic reference values for 100 claws. The presented study results on correlation coefficients obtained from measurements of the soft tissues under the capsule were 0.51 to 0.64. It was

suggested that this might be due to technical errors with correctly placing calipers on the inner surface of the horn capsule. In our study, correlation coefficients were between 0.5 and 0.9 depending on the measurement points. According to Kofler *et al.* [6], lower correlation coefficients for dorsal wall measurements could be related to suboptimal image quality. However, a low correlation of the corium with soft tissues at the sole might be due to measurement errors caused by irregularities at the sole and the presence of soft tissues. Kofler *et al.* [6] measured sole horn thickness using ultrasound at three different points in cows. The soles were thicker than 5 mm with values of  $6.4 \pm 2.2$  mm,  $6.9 \pm 2.2$  mm, and  $6.8 \pm 2.1$  mm. In cows with thin soles, the corium and soft tissue thickness at the same measurement points was  $3.2 \pm 1.0$  mm,  $7.1 \pm 1.5$  mm, and  $5.4 \pm 1.3$  mm at the sole, and  $4.3 \pm 0.9$  mm at the dorsal wall. Our results were similar to data from Kofler *et al.* [6] at the same points. Claw horn corrections prior to measuring are required by some researchers [4,7,17] as well as the use of cows with thin soles in the study by Kofler *et al.* [6]. These factors can be the reason for differences in the results.

Van Amstel *et al.* [16] showed that the subsolar soft tissue layer of the lateral hind claws is significantly thicker (4.29 mm) than the medial hind claws (3.92 mm). This difference was statistically significant although it was not clinically significant. In the current study, difference in the thickness of the solar soft tissues of the claws (medial claws ranged from 2.8 to 6.1 mm while lateral claws ranged from 3.0 to 6.0 mm) may be related to size of the cows. Larger cows probably have a thicker soft tissue layer. It has been suggested that excessive load on the lateral claw of the hind legs of heavier animals may also be a factor that promotes hypertrophy of the soft tissue layer in the claw [16]. In the present study, distances between the surface of the dorsal claw wall and P3 surface as well as thickness of the capsule and corium with underlying soft tissues measured separately were greater in the lateral claws compared to the medial claws. However, thickness of the corium and underlying soft tissue was not significantly different when comparing the lateral and medial claws. The authors [15,16] suggested that some measurement errors may result from cutting the claws with a saw for macroscopic measurements or minor disruption of anatomical structures. Therefore, a higher number of cases or another explanation should be considered when planning further studies. In conclusion, our findings demonstrated that ultrasonography is a reliable tool for veterinary practitioners to measure thickness of the hoof capsule, corium, and soft tissue in bovine claws.

## Acknowledgments

This study was supported by the Scientific and Technological Research Council of Turkey (project no. 107O817).

## Conflicts of Interest

There is no conflict of interest.

## References

1. **Browne MP, Hukins DWL, Skakle JMS, Knight CH, Hendry KAK, Wilde CJ, Galbraith H.** X-ray diffraction patterns and anatomical properties of claw tissues of beef and dairy cattle. *J Agric Sci* 2007, **145**, 623-633.
2. **Bushberg JT, Seibert JA, Leidholdt EM Jr, Boone JM.** The Essential Physics of Medical Imaging. 2nd ed. pp. 469-554, Lippincott Williams & Wilkins, Philadelphia, 2002.
3. **Dietz O, Prietz G.** Quality and status of cattle hoof horn. *Monatsh Veterinarmed* 1981, **36**, 419-422.
4. **Greenough PR, Vermunt JJ, McKinnon JJ, Fathy FA, Berg PA, Cohen RDH.** Laminitis-like changes in the claws of feedlot cattle. *Can Vet J* 1990, **31**, 202-208.
5. **Greenough PR.** Bovine Laminitis and Lameness: a hands-on approach. pp. 176, Saunders/Elsevier, Toronto, 2007.
6. **Kofler J, Kübber P, Henninger W.** Ultrasonographic imaging and thickness measurement of the sole horn and underlying soft tissue layer in bovine claws. *Vet J* 1999, **157**, 322-331.
7. **Nuss K, Paulus N.** Measurements of claw dimensions in cows before and after functional trimming: a post-mortem study. *Vet J* 2006, **172**, 284-292.
8. **Nyland TG, Mattoon JS.** Veterinary Diagnostic Ultrasound. pp. 3-17, Saunders, Philadelphia, 1995.
9. **Räber M, Lischer ChJ, Geyer H, Ossent P.** The bovine digital cushion – a descriptive anatomical study. *Vet J* 2004, **167**, 258-264.
10. **Shakespeare AS.** Inadequate thickness of the weight-bearing surface of claws in ruminants. *J S Afr Vet Assoc* 2009, **80**, 247253.
11. **Shearer JK, van Amstel SR.** Functional and corrective claw trimming. *Vet Clin North Am Food Anim Pract* 2001, **17**, 53-72.
12. **Simmins PH, Brooks PH.** Supplementary biotin for sows: effect on claw integrity. *Vet Rec* 1988, **122**, 431-435.
13. **Singh SS, Murray RD, Ward WR.** Histopathological and morphometric studies on the hooves of dairy and beef cattle in relation to overgrown sole and laminitis. *J Comp Pathol* 1992, **107**, 319-328.
14. **Toussaint Raven E, Haalstra RT, Peterse DJ.** Cattle Footcare and Claw Trimming. pp. 75-106, Farming Press, Ipswich, 1985.
15. **van Amstel SR, Palin FL, Rorhbach BW, Shearer JK.** Ultrasound measurement of sole horn thickness in trimmed claws of dairy cows. *J Am Vet Med Assoc* 2003, **223**, 492-494.
16. **van Amstel SR, Palin FL, Shearer JK.** Measurement of the thickness of the corium and subcutaneous tissue of the hind claws of dairy cattle by ultrasound. *Vet Rec* 2004, **155**, 630-633.
17. **van Amstel SR, Shearer JK, Palin FL.** Moisture content, thickness, and lesions of sole horn associated with thin soles in dairy cattle. *J Dairy Sci* 2004, **87**, 757-763.