

Posterolateral Corner Reconstruction of the Knee Using Gracilis Autograft and Biceps Femoris



Shanaka Senevirathna, M.B.B.S., F.R.C.S. (Tr & Orth), Bruno Stragier, M.D., and Guido Geutjens

Abstract: We introduce our technique for posterolateral corner reconstruction, which is based on the principle described in Arciero's technique for anatomic reconstruction of lateral collateral ligament (LCL) and popliteofibular ligament (PFL) to gain static stability in varus strain and external rotation. This technique uses a doubled gracilis autograft to reconstruct the PFL and a split biceps tendon transfer to reconstruct the LCL. Using this technique an anatomical LCL and PFL reconstruction can be performed in combination with anterior cruciate ligament or posterior cruciate ligament reconstruction without contralateral graft harvest or allograft. The technique also enables an isolated reconstruction of LCL or PFL when required and can be performed to augment an acute repair.

Posterolateral corner (PLC) lesions have been estimated to occur in 16% of all knee ligament injuries and 9.1% of acute knee injuries with hemarthrosis.¹ They are often associated with concomitant anterior cruciate ligament (ACL) or posterior cruciate ligament (PCL) injury or both (87%).²⁻⁵ Injury to the PLC in isolation accounts for less than 30% of PLC injuries.^{2,6} The mechanism of injury to the PLC usually involves a varus stress following a direct blow to the anteromedial knee, hyperextension, or twisting of the knee.⁷ Failure to detect these injuries has been shown to be an important cause of recurrent instability and failed cruciate ligament reconstruction.⁸⁻¹²

Advancements in magnetic resonance imaging (MRI) and evolution of physical examination have resulted in a more consistent and timely diagnosis of this significant injury.¹³⁻¹⁵ Grade 3 PLC injuries require surgical

stabilization to prevent persistent instability and varus thrust gait, which predisposes to accelerated medial compartmental osteoarthritis. Reconstructive techniques are recommended over repair for grade 3 PLC injuries due to greater reoperation rates involved with repairs.^{10,14,16-20} An anatomic reconstruction of the primary static stabilizers of the PLC of the knee best improves the knee stability and functional and clinical outcomes.¹⁸

Surgical techniques designed to stabilize chronic grade III PLC injuries have evolved over the past 30 years. We introduce our unique technique for PLC reconstruction with concomitant ACL or PCL reconstruction using hamstring autografts.

Our technique of PLC reconstruction is based on the principle described in Arciero's technique²¹ for anatomic reconstruction of lateral collateral ligament (LCL) and popliteofibular ligament (PFL) to gain static stability in varus strain and external rotation. It carries the advantage of not having to harvest hamstrings from the other knee in the case of concomitant ACL or PCL reconstruction, if a quadrupled or tripled semitendinosus graft is used for the ACL or PCL reconstructions.

A PFL reconstruction is carried out with a doubled gracilis autograft fixed in to the fibula with a cortical suspensory fixation (ENDOBUTTON) over the anterior cortex of fibula through a single oblique tunnel and femoral fixation over popliteus attachment site. Using a doubled gracilis tendon graft has the advantage of enabling a stronger construct to restore the static

From the Royal Wolverhampton Hospitals NHS Trust, Wolverhampton (S.S.); and Royal Derby Hospital, Derby (B.S., G.G.), United Kingdom.

The authors report that they have no conflicts of interest in the authorship and publication of this article. Full ICMJE author disclosure forms are available for this article online, as [supplementary material](#).

Received October 5, 2021; accepted December 17, 2021.

Address correspondence to Shanaka Senevirathna, Royal Wolverhampton Hospitals NHS Trust, Wednesfield Road, Wolverhampton, United Kingdom, WV10 0QP. E-mail: Shanakasenevirathna@NHS.Net

© 2022 The Authors. Published by Elsevier Inc. on behalf of the Arthroscopy Association of North America. This is an open access article under the CC BY-NC-ND license (<http://creativecommons.org/licenses/by-nc-nd/4.0/>).

2212-6287/211418

<https://doi.org/10.1016/j.eats.2021.12.030>

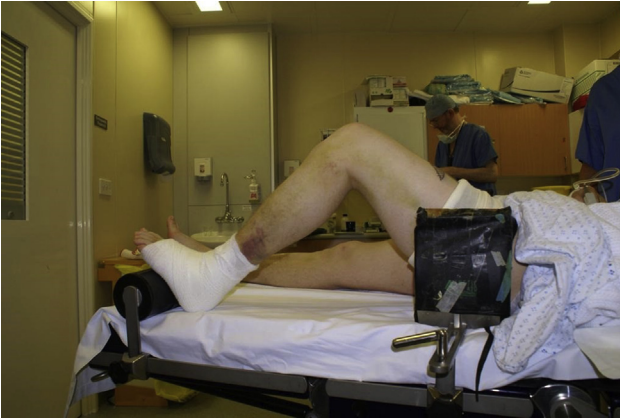

Fig 1. Right knee, surgical image demonstrating the patient positioning, supine with the knee flexed to 70° with a lateral thigh support and one foot support.

stability in external rotation and posterior translation as an added advantage over a single-stranded hamstring graft sling.

We perform an anatomical LCL reconstruction with a split biceps tendon transfer to the LCL attachment over lateral epicondyle. Requirements for split biceps tendon transfer procedure include an intact proximal tibiofibular joint and intact biceps femoris tendon insertion to the fibula head.¹¹

In patients with a concomitant ACL injury, we carry out a single-bundle ACL reconstruction with a tripled or quadrupled semitendinosus (semi-T) tendon autograft. We perform a split biceps tendon transfer to reconstruct



Fig 2. Surgical image of the popliteofibular ligament graft (doubled gracilis tendon graft), which should be at least 8 cm in length. This figure shows a graft measuring up to a length of 11 cm, which will be subsequently shortened to leave an appropriate length to avoid the graft bottoming out in the intraosseous tunnel. Only 2 to 2.5 cm should be left in the tunnel. The 2 limbs will be whip-stitched together to facilitate adequate tensioning and fixation.

LCL and a doubled ipsilateral gracilis tendon to reconstruct the PFL.

In combined ACL and PLC reconstruction, PLC reconstruction is performed before tightening the ACL graft to avoid the ACL tension causing abnormal external rotation of the tibia due to lack of posterolateral structures.²² In contrast with combined PCL and PLC injuries, the PCL will be tightened and fixed first, for the same reasons explained previously.

Patients are initially seen in our knee clinic with MRI scans, and detailed clinical examination is carried out by the operating surgeon. In addition to cruciate ligament tests, a specific PLC evaluation is performed. The Dial test (at 30° and 90° knee flexion) and the varus stress test (at 0° and 30° knee flexion) are performed respectively in prone and supine position. The results of these tests will be compared with those of the contralateral uninvolved knee and will be considered normal when no difference is found between the involved and uninvolved knee.²³ The posterolateral drawer test and external rotation recurvatum tests are performed to confirm popliteal complex injuries and concomitant cruciate ligament involvement.²⁴ In cases of chronic posterolateral instability in a knee with varus mechanical alignment long leg alignment radiographs will be obtained to calibrate the severity of the deformity and re alignment procedures will be performed before staged ligament reconstruction.^{6,25,26}

Surgical Steps and Technique for Posterolateral Corner Reconstruction (With Video Illustration)

Under general anesthesia, patient is positioned supine with the knee flexed to 70° with a lateral thigh support and one foot support. Examination under anesthesia will be carried out to confirm the preoperative diagnosis (Fig 1, Video 1).

Table 1. Classification of Damage in PLC Structures

Classification	Scale of Damage	Damaged Structures
Type A	10° increase in external rotation of the tibia	PFL, popliteus tendon
Type B	10° increase in external rotation of the tibia Slight varus relaxation (5- to 10-mm increase in varus load test)	PFL, popliteus tendon LCL
Type C	10° increase in external rotation of the tibia Severe varus relaxation (>10 mm increase in varus load test)	PFL, popliteus tendon LCL, capsule avulsion, cruciate ligament

LCL, lateral collateral ligament; PFL, popliteofibular ligament; PLC, posterolateral corner.

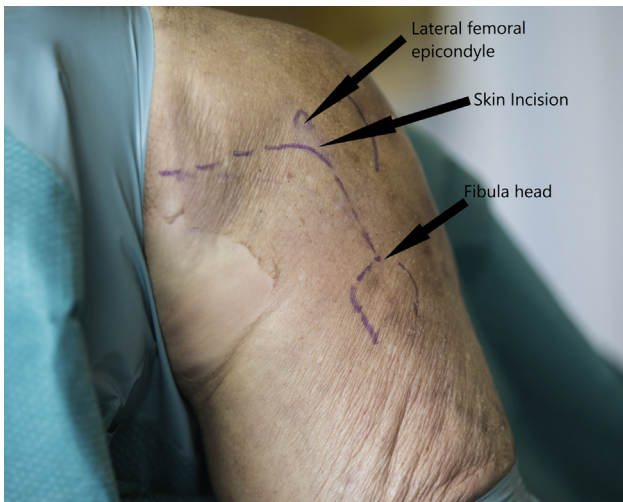


Fig 3. Right knee lateral side, skin incision will be made extending from lateral epicondyle to a point just anterior to fibula head with the knee in 70° flexion.

Hamstring autografts are harvested through a 2-cm longitudinal/oblique incision, made 2 cm medial and inferior to the tibial tuberosity in the line of the hamstring tendons. Sartorius fascia is split over the superior border of the gracilis tendon. Gracilis tendon and semi-T tendons are retracted out with a Lahey's forceps and temporarily held with nerve tapes. Tendons

are harvested using a Pigtail tendon stripper (Arthrex, Largo, FL), after releasing the accessory bands along the inferior border of the tendons. Tendon ends will be whip-stitched with No. 2 ETHIBOND EXCEL (Ethicon, Somerville, NJ) sutures and double stranded gracilis graft is prepared to a minimum length of 8 cm (Fig 2).

Arthroscopic evaluation is performed to detect increase lateral compartment opening with application of varus knee stress ("drive-through" sign).²⁷ Surgical reconstruction is performed in Fanelli B/C (Table 1)²⁵ chronic PLCR injuries upon clinical findings, MRI findings, and if the drive-through sign is present.

An incision is made extending from lateral epicondyle to a point just anterior to fibula head with the knee in 70° of flexion (Fig 3). Dissection is carried down to the iliotibial band (ITB), creating a posterior based vascularized skin flap. The common peroneal nerve is identified, released, and protected throughout the procedure (Fig 4).

A 4-cm horizontal fascial incision is made posterior to the fibular head, just anterior to and in line with the biceps tendon (Fig 5). The fibers of the lateral gastrocnemius muscle are elevated from the fibula exposing the posterior aspect of the fibular head. The LCL footprint of the fibula is identified by the attached remnants of the LCL, located approximately 8.2 mm posterior to

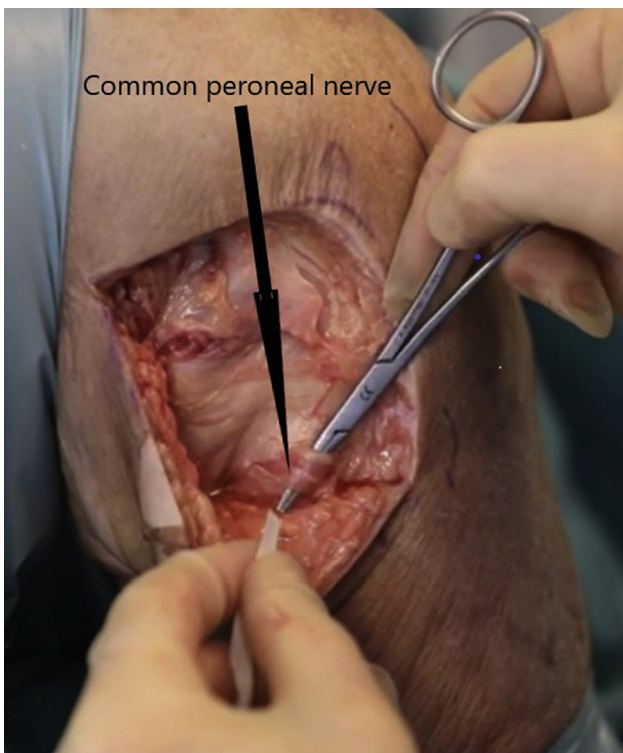


Fig 4. Right knee lateral side in 70° of flexion. The common peroneal nerve should be identified and protected throughout the procedure.

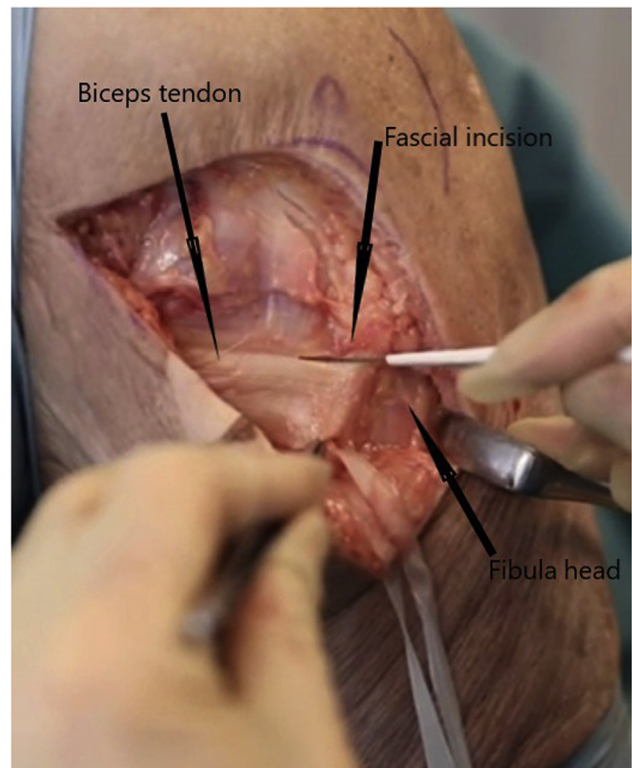


Fig 5. Right knee lateral side in 70° of flexion. A 4-cm horizontal fascial incision is made posterior to the fibular head, just anterior to and in line with the biceps tendon.

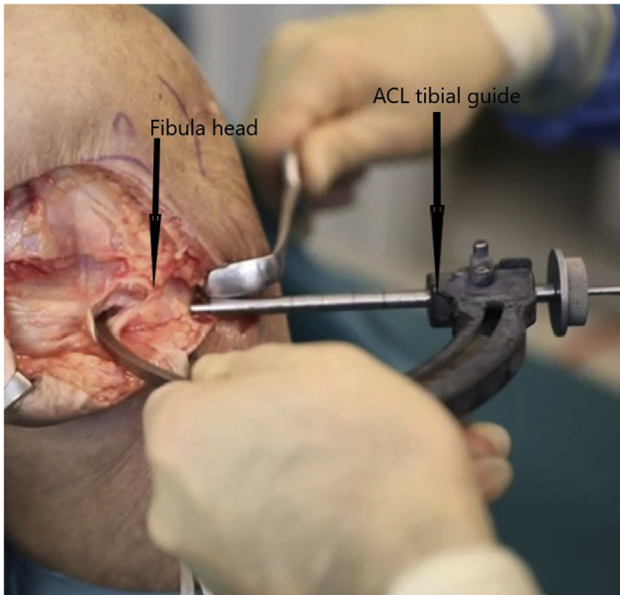


Fig 6. Right knee lateral side in 70° of flexion. Surgical image of passing a 2.4-mm guide pin using the ACL tibial guide (set to 60°) from anterolateral aspect of proximal fibula over the lateral collateral ligament footprint directed proximally towards the popliteofibular ligament attachment (tubercle) located on the posteromedial aspect of the fibular head (through the area of maximum fibula diameter).

the anterior margin of the fibular head and 28.4 mm distal to the fibular styloid tip.^{6,28}

A fibular tunnel is created from the anterolateral aspect of proximal fibula over the LCL footprint directed proximally towards the PFL attachment (tubercle) located on the posteromedial aspect of the

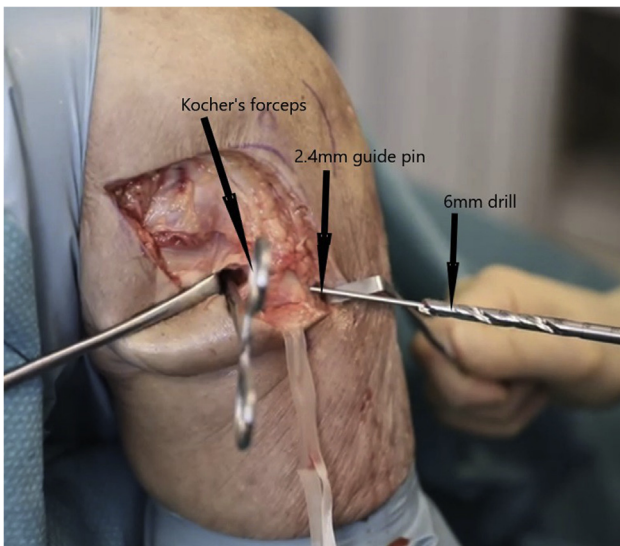


Fig 7. Right knee lateral side in 70° of flexion. Surgical image of creating a 6-mm tunnel in the fibula head by reaming over the guide pin while the tip of the guide pin is held with a Kocher forceps.

fibular head. This is done by passing a 2.4-mm guide pin using the Smith & Nephew ACL tibial guide (set to 60°) at the area of maximum fibula diameter while protecting the nerve (Fig 6). (The anatomical PFL attachment over the fibula also can be located on average 2 mm distal to the tip of the fibular styloid process on its posteromedial downslope).²⁸ Once the guide pin has advanced through the posterior cortex of the fibula, the ACL guide is removed and the tip of the guide pin is held with Kocher forceps while reaming the tunnel over the guide pin. This step secures a good control to avoid eccentric reaming causing an iatrogenic fracture and also eliminate the risk of causing injury to the nerve and to posterior structures (Fig 7). A 4.5-mm to 6-mm tunnel is then created by drilling over the guide pin. An arthroscopic punch (ACUFEX; Smith & Nephew, Andover, MA) is used to clear the tunnel entrance to facilitate graft passage.

A suture passing pin (Smith & Nephew) or FiberStick (Arthrex) is passed from anterior to posterior in the fibula tunnel and the looped suture retrieved posteriorly. This then allows the looped end of gracilis graft to be pulled through using this suture (Fig 8). Once pulled through the fibula head, the looped gracilis is then sutured directly on to a Smith & Nephew ENDOBUTTON (The polyester loop of the ENDOBUTTON is removed which allows the whole of the fibular tunnel to be filled with graft), which is then secured over the anterior cortex of the fibula head (Fig 9). Alternatively, an Arthrex variable loop TightRope can be used for the graft fixation in the fibula as shown in the video (Fig 10).

The ITB is split longitudinally midway between its anterior and posterior borders from the lateral epicondyle to Gerdy's tubercle. After going through the

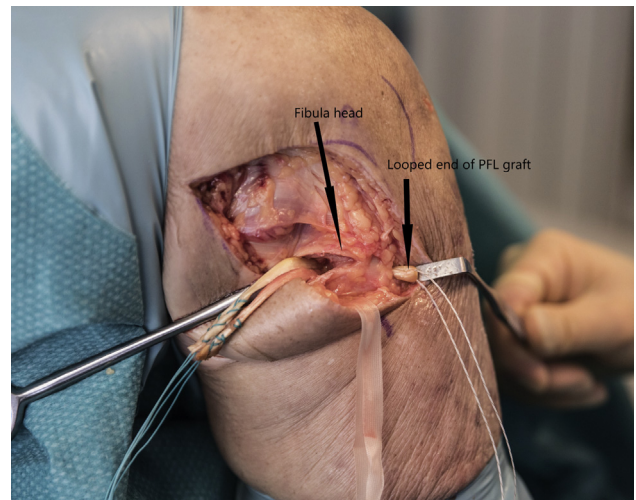


Fig 8. Right knee lateral side in 70° of flexion. Surgical image of passing the looped end of the popliteofibular ligament (PFL) graft through fibula head.

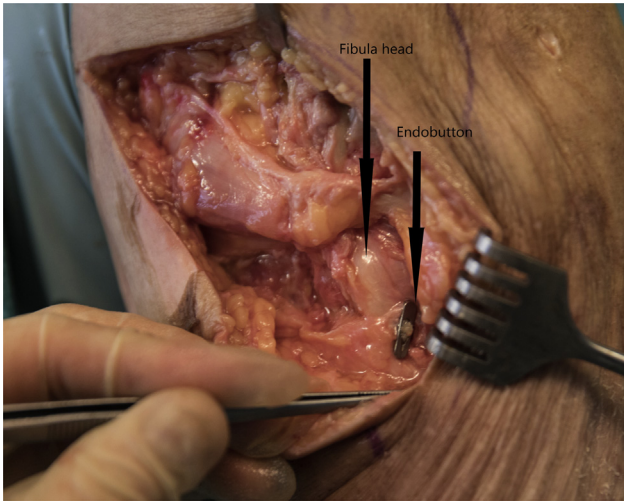


Fig 9. Right knee lateral side in 70° of flexion. Surgical image showing the popliteofibular ligament (PFL) graft anchored over the anterior cortex of fibula with an ENDOBUTTON.

ITB femoral insertion site of the LCL is identified by direct palpation of the remnants of the LCL.

Small capsular incision is then made just above the joint line and the capsule is dissected off from the distal aspect of the femur to locate the proximal femoral insertion of the popliteus tendon.^{6,28,29} This footprint is located in the anterior fifth of the popliteal sulcus, which is a kidney bean-shaped indentation on the lateral aspect of the distal femur (Fig 11).^{6,28,29} A 3.2-mm guide pin (Smith & Nephew) is introduced at this

location and advanced medially heading in a slightly anterior and proximal direction which will avoid both the femoral notch and the ACL tunnel if a concomitant ACL reconstruction has been performed. A 6mm diameter tunnel is drilled (Smith & Nephew drill bit) to a depth of 30 mm to accommodate the free ends of the doubled gracilis (PFL) graft (Fig 11). Soft tissues blocking the tunnel entrance is then cleared using the arthroscopic punch.

The second tunnel is created at the proximal femoral insertion site of the LCL. This location is slightly posterior and proximal (approximately 3.1 mm posterior and 1.4 mm proximal) to the lateral epicondyle and approximately 18.5 mm from the center of the insertion of the popliteus tendon.^{6,28,29} A 3.2-mm guide pin is inserted into the femur at this location, heading in a direction that parallels the previously drilled popliteal socket. A 6-mm wide tunnel is then drilled to a depth of 30 mm to accommodate the free ends of the biceps tendon graft (Fig 11).

From the posteromedial aspect of the fibular head, the 2 free limbs of the doubled gracilis graft (PFL graft) are passed deep to ITB and brought out at the popliteal attachment site (at the previously made socket). The 2 limbs are whip-stitched together to facilitate adequate tensioning and fixation. Only appropriate length should be left behind to avoid the graft bottoming out in the intraosseous tunnel (20-25 mm should be left). The graft is then passed into the tunnel using a suture passer (Figs 12-14).

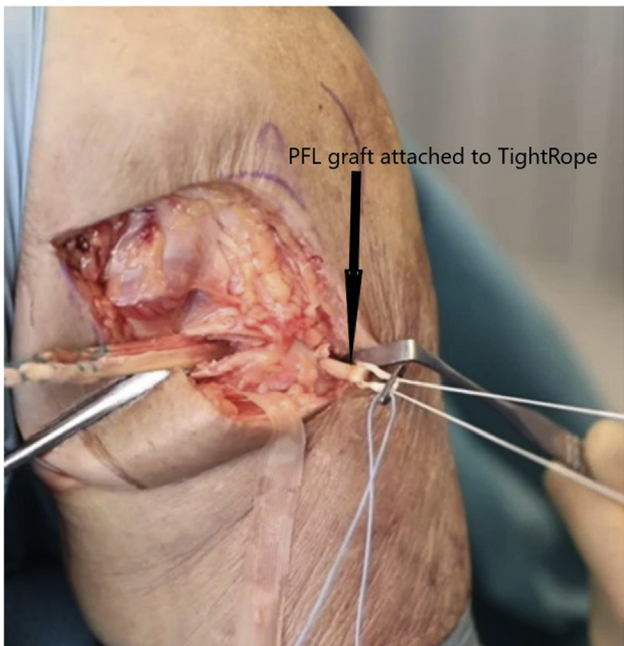


Fig 10. Right knee lateral side in 70° of flexion. Surgical image of passing the popliteofibular ligament (PFL) graft attached to the variable-loop TightRope.

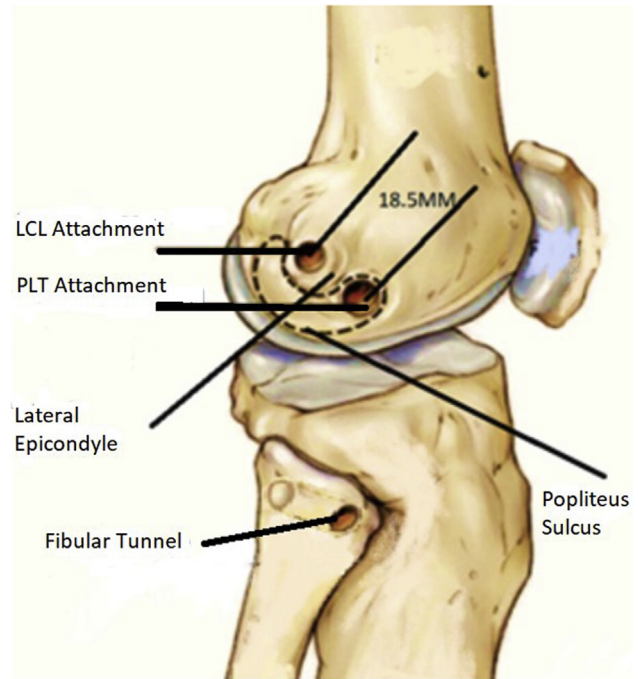


Fig 11. Image of the right knee demonstrating the anatomical landmarks and tunnels. (LCL, lateral collateral ligament; PLT, popliteus tendon.)

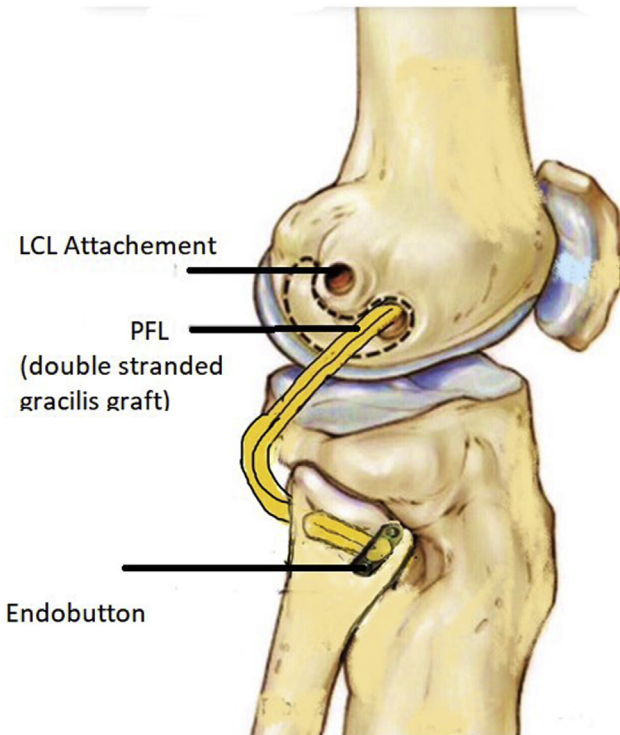


Fig 12. Image of the right knee demonstrating the popliteofibular ligament (PFL) reconstruction. (LCL, lateral collateral ligament.)

The direct and anterior arm of the long head of biceps femoris tendon is identified and isolated (Fig 15). A longitudinal split is made in the long head of the biceps tendon and a 10-mm wide and 70-mm long strip from the anterior half is detached proximally and left attached distally to its anatomical insertion site of the

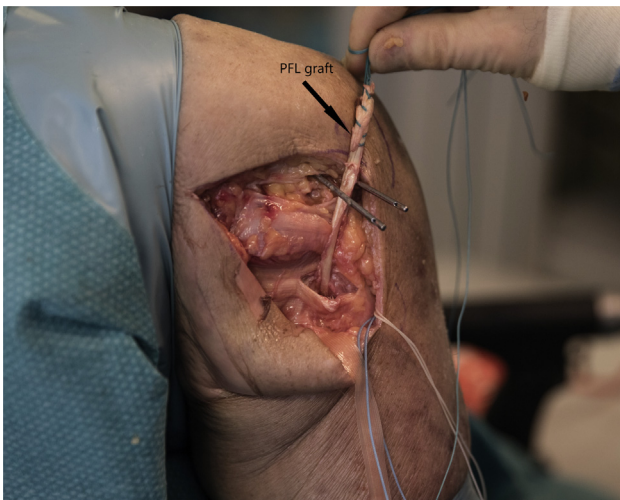

Fig 13. Right knee lateral side in 70° of flexion. Surgical image demonstrating the appropriate length of popliteofibular ligament (PFL) (the graft should be passed deep to the iliotibial band and brought out at the popliteal attachment site).

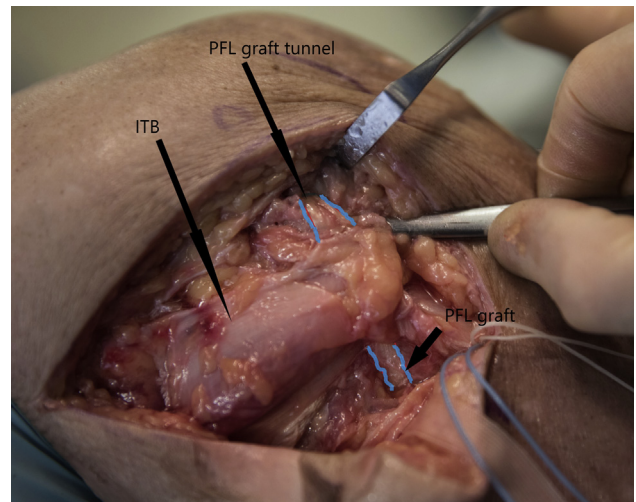


Fig 14. Right knee lateral side in 70° of flexion. Surgical image demonstrating the popliteofibular ligament (PFL) graft has been passed deep to the iliotibial band (ITB) and inserted in to the tunnel (marked in blue).

fibula which partially covers the native LCL attachment of the fibula head (Fig 16).^{6,28} The free end of the graft is whip-stitched and passed deep to the ITB, superficial to the PFL graft and inserted in to the predrilled tunnel at the LCL attachment site after ensuring no excess length is left behind to avoid the graft bottoming out in the intraosseous tunnel (Fig 17).

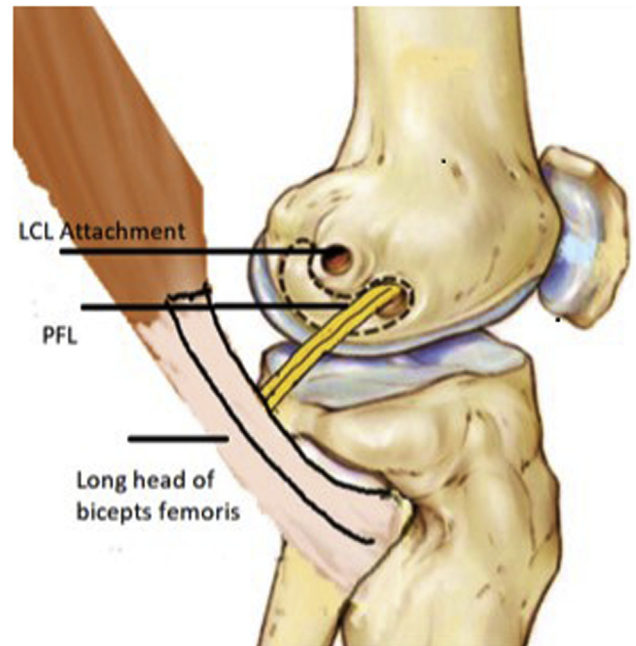


Fig 15. Image of the right knee demonstrating the anatomical attachment of long head of the biceps tendon on to the fibular head. (LCL, lateral collateral ligament; PFL, popliteofibular ligament.)

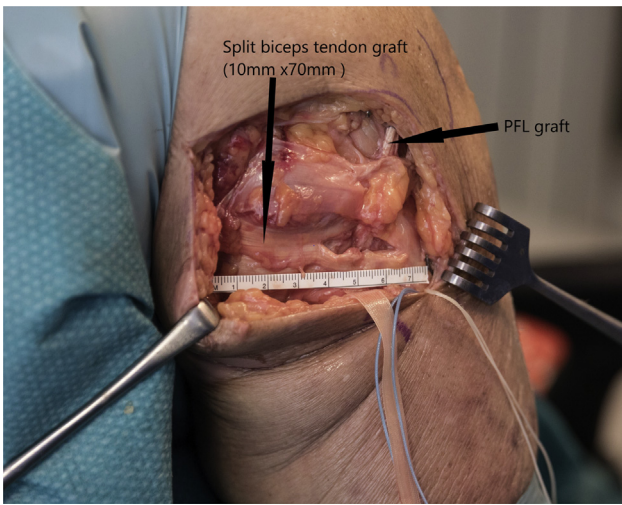


Fig 16. Right knee lateral side in 70° of flexion. Surgical image demonstrating the length of the split biceps tendon graft (anterior half of the biceps tendon 10 mm × 70 mm), which will be left attached distally and detached proximally. (PFL, popliteofibular ligament.)

Both grafts will be secured using 7 × 23-mm interference screws (Mega Fix; Karl Storz Germany, Tuttlingen Germany), with the knee in 30 to 60° of flexion and the foot in neutral rotation, while applying a slight valgus force (Fig 18).

Routine closure of all the fascial intervals, subcutaneous tissue, and skin is then performed. The knee is placed in a hinged knee brace. (Please refer to Table 2 for pearls and pitfalls of the technique and Table 3 for a summary of the surgical plan.)

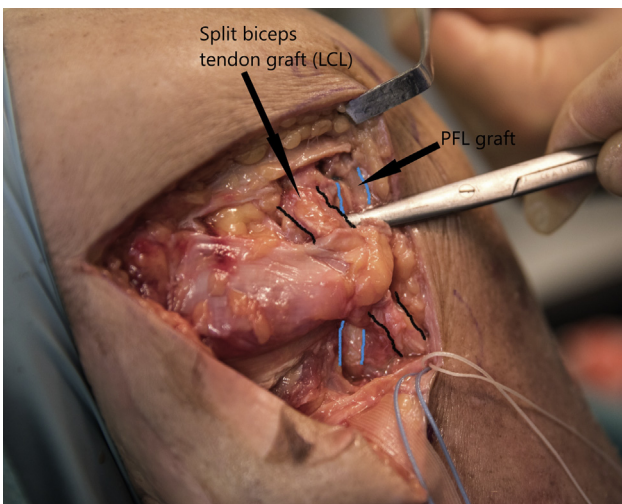


Fig 17. Right knee lateral side in 70° of flexion. Surgical image demonstrating the lateral collateral ligament (LCL) (split biceps tendon) graft passed deep to the iliotibial band and over the popliteofibular ligament (PFL) graft in to its tunnel (marked in black).

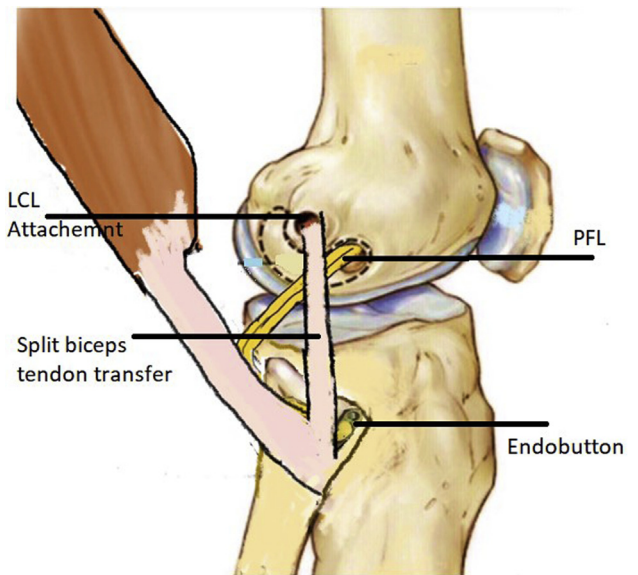


Fig 18. Image of the right knee demonstrating the split biceps tendon transfer. (LCL, lateral collateral ligament; PFL, popliteofibular ligament.)

Postoperative Rehabilitation

This is tailored according to the combination of ligament reconstructions performed. All patients remain touch weight-bearing for the first 6 weeks post-operatively. Following combined ACL and PLC reconstruction, the hinged knee brace is locked in 0 to 30° for 2 weeks,³⁰ 0 to 60° from 2-4 weeks, followed by 0 to 90° until the sixth week following surgery. After 6 weeks, progressive weight-bearing, range-of-motion closed kinetic chain strengthening, and proprioception exercises are started.

Those patients following concomitant PCL and PLC reconstruction will be kept in a posterior tibial support brace locked in full extension for 3 weeks followed by a PCL brace for further 6 weeks while allowing full range of movement and full weight-bearing after the sixth week. Return to sports is related to the type of sports and in general is only allowed after a minimum of 6 months once the patient has gained at least 80% of strength on isokinetic evaluation compared with the uninjured knee.^{6,14}

Discussion

A variety of PLC reconstruction techniques have been reported in the literature.²⁶ These are broadly classified in to anatomical and nonanatomical techniques. Anatomical PLC reconstruction techniques are preferred over nonanatomical techniques due to greater failure rates associated with the latter.⁸ Fibula-based techniques are performed to reconstruct LCL and PFL, whereas tibiofibular-based techniques are used to reconstruct LCL, PFL, and popliteus. Non-anatomical techniques include procedures such as

Table 2. Pearls and Pitfalls

Steps	Pearls	Pitfalls
Clinical assessment, EUA and arthroscopic assessment	Severity of injury is quantified by comparing to uninvolved contralateral knee Drive through sign on arthroscopic assessment	In presence of medial/anteromedial laxity could lead to abnormal external rotation of the tibia giving false-positive results of the dial test Varus malalignment or abnormal slope can contribute to early graft failure Disrupted proximal tibiofibular joint would fail to tension the grafts Inadvertent injury to grafts should be avoided
Graft harvesting	Maximum length of semi-T graft should be obtained	
Skin incision and exposure	Leave adequate subcutaneous tissue in the posterior flap to avoid skin necrosis Common peroneal nerve should be identified and released to avoid injury	
Fibular tunnel	ACL guide should be used while passing the guide pin confirm the tunnel position Tip of the guide pin is held with a Kocher forceps while drilling the tunnel	Be attentive of the risk of iatrogenic fracture
LCL and PFL tunnels	Trajectory of tunnels should direct anteriorly and proximally to avoid tunnel coalition with ACL tunnel Soft tissue from the tunnel entrance should be cleared using arthroscopic nibbler	Tunnel coalition could lead to inadequate graft fixation
Concomitant ACL reconstruction	PLC reconstruction is performed before tightening the ACL	Fixing the ACL graft first will cause abnormal external rotation of the tibia due to lack of posterolateral structures
Concomitant PCL reconstruction	PCL should be tightened and fixed first	Performing the PLC reconstruction first will cause abnormal internal rotation of tibia
Graft fixation	Only appropriate length should be left behind to avoid the graft bottoming out in the intraosseous tunnels (20-25 mm should be left)	Bottoming out in the tunnel will fail to tension the graft thereby failing to restore the stability.

ACL, anterior cruciate ligament; EUA, examination under anesthesia; LCL, lateral collateral ligament; PFL, popliteofibular ligament; PCL, posterior cruciate ligament; PLC, posterolateral corner; semi-T, semitendinosus.

femoral osteotomy, arcuate complex/bone block advancement, extracapsular ITB sling, augmentation techniques, biceps tendon tenodesis,^{11,26,31,32} and Larson's single femoral tunnel PLC reconstruction.³³

A systemic review was carried out by Moulton et al.³⁴ on outcomes of different surgical techniques used in reconstruction for chronic grade III PLC injuries. They reported an overall 90% success rate and 10% failure rate with mean postoperative Lysholm scores ranging from 65.5 to 91.8 and mean postoperative International Knee Documentation Committee scores ranging from 62.6 to 86.0. Surgical techniques reviewed in their study included variations of fibular slings, capsular shifts and 2-tunnel techniques (fibular tunnel and tibial tunnel). A fibular sling reconstruction technique was a commonly used with single or dual femoral attachments to recreate the function of LCL and PFL.³⁴

A systematic review on management of combined ACL-PLC reconstruction injuries by Bonanzinga

et al.¹² concluded that combined ACL-PLC reconstruction was the most effective management; however, indicated the requirement of more research to explore the long-term outcome of the different treatment options.

LaPrade et al. described excellent results with a tibiofibular-based technique.^{10,18,26,35,36} In their technique they attempt to recreate the LCL, PFL, and popliteus based on their native attachment sites.

Several variations of the 2-tailed PLC reconstruction have since been described in the literature.^{20,31,37-40} Wood et al.⁴¹ recently described a modification to the LaPrade anatomic PLC reconstruction with the use of a single semitendinosus tendon and an adjustable-length loop suspensory tibial fixation, which avoids the requirement of allograft to carry out the procedure. Pache et al.⁴² also described a modified LaPrade autograft technique, in which the same tunnel position, graft passage, and fixation are used to reproduce the 3 primary stabilizers of the PLC. Instead of Achilles tendon

Table 3. Summary of Surgical Plan

Surgical Step	Details
Patient setup	Patient positioned supine with the knee flexed to 70° with a lateral thigh support and one foot support
EUA and arthroscopy	The dial test (at 30° and 90° knee flexion) and the varus stress test (at 0° and 30° knee flexion) are performed, respectively, to assess the PLC and LCL. Posterolateral drawer test and external rotation recurvatum tests are performed to confirm popliteal complex injuries and concomitant cruciate ligament involvement. Examination of both cruciate ligaments.
Graft harvest	Ipsilateral gracilis tendon harvested with a minimum length of 16 cm and doubled up to create the PFL graft
Arthroscopy	Arthroscopic evaluation of the joint is performed to detect the increase in lateral compartment opening with application of varus knee stress (“drive-through” sign).
Lateral approach and neurolysis	An incision is made extending from lateral epicondyle to a point just anterior to fibula head. Dissection is carried down to the ITB creating a posterior based vascularized skin flap. The common peroneal nerve is identified, released, held with nerve tape and protected throughout the procedure.
Exposure of fibula head to create the fibula tunnel	A 4-cm horizontal fascial incision is made posterior to the fibular head, just anterior to and in line with the biceps tendon. The fibers of the lateral gastrocnemius muscle are elevated from the fibula exposing the posterior aspect of the fibular head
Creating the fibula tunnel	Fibular tunnel is initially created by passing a 2.4-mm guide pin using the ACL tibial jig (set at 60°), from the anterolateral aspect of proximal fibula over the LCL footprint directed proximally towards the PFL attachment (tubercle located on the posteromedial aspect of the fibular head). Tunnel is reamed up to 6 mm by drilling over the guide pin.
Passing the PFL graft and fixation	ETHIBOND/VICRYL suture loop is passed through the fibula tunnel from posterior to anterior with use of (Smith & Nephew) suture passer or a (Arthrex) fibre stick. Looped end of gracilis/ PFL graft is then pulled through the fibula tunnel from posterior to anterior with help of the suture loop. Graft loop is anchored over the anterior fibula cortex with use of a (Smith & Nephew) ENDOBUTTON or with an (Arthrex) variable-loop TightRope.
ITB split and identification of LCL and popliteal attachments	Longitudinal split of the ITB from lateral epicondyle to Gerdy’s tubercle. Identify LCL attachment site by direct palpation of LCL remnants and popliteal tendon attachment site at anterior fifth of the popliteal sulcus
Drilling the femoral tunnels for LCL and PFL attachments	PFL tunnel followed by the LCL tunnel are created with an 18mm gap between the 2 tunnels. A 3.2-mm guidewire is passed through the PFL popliteus attachment site heading slightly anterior and proximal to avoid tunnel coalition. The tunnel is then reamed up to 6mm of diameter to a depth of 30 mm. Same technique is repeated to create the LCL tunnel being parallel to PFL tunnel trajectory.
LCL graft	A 10-mm wide and 70-mm long strip from the anterior half of the biceps tendon is detached proximally and left attached distally to its anatomical insertion site of the fibula head.
Graft fixations	Free ends of the gracilis/PFL graft is passed under the ITB and inserted in to the PFL/popliteal tunnel Split biceps tendon graft/ LCL graft should be passed under the ITB but over the PFL graft and inserted in to the LCL tunnel. Both grafts are secured using 7 × 23-mm (Mega Fix; Karl Storz) interference screws, with the knee in 30-60° of flexion and the foot in neutral rotation, while applying a slight valgus force.

ACL, anterior cruciate ligament; EUA, examination under anesthesia; ITB, iliotibial band; LCL, lateral collateral ligament; PFL, popliteofibular ligament; PCL, posterior cruciate ligament; PLC, posterolateral corner; semi-T, semitendinosus.

allografts semitendinosus and gracilis autografts are used while tunnel diameters and fixation devices are adapted to them. All-arthroscopic and arthroscopic-assisted minimally invasive techniques to replicate original LaP-rade technique has also been described recently.^{43,44}

Clinical and biomechanical comparison studies have found no additional effect of popliteal tendon reconstruction in anatomic PLC reconstruction on the stability and outcome.^{37,45,46} However this can over constrain the knee.^{38,47,48}

PLC reconstruction using a transfibular tunnel was found equally effective as the dual tibial/fibula tunnels at restoring external rotation and varus stability. This is technically easier to perform with a shorter operation time and less surgical morbidity and also reduces overall volume of tibial tunnels, which especially pertinent in multiligamentous reconstruction of the knee since there may be multiple tibial tunnels for ACL and PCL.^{39,49}

Larson et al.^{25,33,50} reported a fibular sling. It is a fibular-based nonanatomical technique with a single isometric point over the lateral femoral epicondyle that can make the popliteal complex and LCL balanced appropriately. Larson's technique/modified Larson's technique is commonly used and has good outcomes in stabilizing PLC but fails to restore complete normal laxity.^{5,51-53} Other PLC reconstruction techniques are also described in the literature and report satisfactory outcomes in restoring PLC stability on subjective and objective assessments.^{3,24,54,55}

Arciero developed a technique in 2005, which manage to closely replicate the anatomical attachments of LCL and PFL. Reconstruction was performed using a 22- to 24-cm long semi-T autograft or an allograft (tibialis anterior or tibialis posterior) fixed with an interference screw in the anatomical oblique trans fibula tunnel placed accordance to native anatomical attachments of LCL and PFL in the fibula head and dual femoral fixation over their anatomical foot prints.²¹ Rios et al.⁵⁶ reported satisfactory outcomes of restoring varus and rotational instability in concomitant cruciate ligament and PLC reconstruction with the above technique. Based on the principle described by Arciero, few modifications to his technique have been described since in the literature with good outcomes.^{15,57,58} Grimm et al.⁵⁹ recently refined the technique with few modifications and used new innovative fixation devices. Frings et al.⁶⁰ presented the first all-arthroscopic technique for complete PLC reconstruction, based on the open technique described by Arciero.

Biomechanical analysis carried out on different fibula-based PLC reconstruction techniques concluded satisfactory results in anatomical dual femoral fixation and an oblique fibular tunnel best restores lateral-side kinematics.^{61,62} Our Derby technique is designed as an advancement based on the aforementioned principle described by Arciero.

Anatomical and Biomechanical Aspects of the Technique

In our technique, an anatomical LCL and PFL reconstruction can be performed in combination with ACL or PCL reconstruction using hamstring autografts without contralateral graft harvest or allograft. A tripled/quadrupled semi-T can be used as an ACL or PCL graft.

This technique enables us to independently tension the LCL and PFL grafts. We use 2 different types of autologous grafts to reconstruct LCL and PFL with different tensile strengths and viscoelastic properties. We speculate this combination of 2 different graft types with varying structural properties could minimize the risk of failure of the construct if one structure fails and also reduce risk of overconstraining compared with fibula sling technique. This also enables an isolated reconstruction of LCL or PFL when required^{63,64} and can be performed to augment an acute repair.

LCL Reconstruction

The long head of the biceps femoris divides approximately 1 cm proximal to the fibular head into direct and anterior arms, which encloses distal attachment of LCL. The direct arm inserts onto the posterolateral aspect of the fibular head. The anterior arm inserts on the anterolateral aspect of the fibular head adjacent to distal attachment of LCL separated by a small bursa.^{6,28,65} The lateral side of the anterior arm then continues anteriorly and distally terminating as an anterior aponeurosis covering the anterior compartment of the leg. The reflected fascial component (reflected arm) of the anterior arm originates from the tendon just proximal to the fibular head. It ascends anteriorly across the distal portion of the short head of the biceps femoris muscle to insert on the posterior edge of the iliotibial tract and lateral to Gerdy's tubercle.⁶⁵

Because the LCL's native distal bony fibrous enthesis along with its complex attachments of the anterior arm of split biceps tendon graft is preserved, success is only relied upon the graft healing/osseointegration at the graft-tunnel interface at the single fixation point over the femoral LCL footprint compared with other techniques in which graft healing is expected in its both bony fixation sites. This enables the surgeon to anatomically reconstruct and restore the function of LCL with a strong construct with minimal risk of graft failure.

Multiple nonanatomical biceps tendon procedures are reported in the literature for PLC reconstruction.^{20,30,66,67} Most of the described biceps tenodesis/transfer techniques^{68,31,53,69} required harvesting full thickness or almost the entire width of the biceps tendon. These effectively caused secondary destabilization of PLC by removing the dynamic effect of biceps femoris, and they did not replicate or restore the native anatomy and isometry of LCL/PFL as reported in biomechanical analysis.^{25,70}

A split biceps tendon transfer has an advantage over full biceps tendon transfer procedures since it preserves the dynamic stabilizing effect of biceps femoris muscle in providing stability at varus angulation controlling tibial internal rotation and works with the medial hamstrings to prevent excessive tibiofemoral anterior translation.

Fanelli et al.^{11,25,35} described a surgical technique of reconstructing both LCL and PFL using the split biceps tendon transfer to a single isometric point over the lateral femoral epicondyle. Their technique describes harvesting a 12- to 14-cm long strip from the anterior half of the biceps tendon to recreate the function of the PFL and LCL augmented with posterolateral capsular shift. They reported satisfactory outcomes of restoring PLC stability with their technique in combined PCL/PLC reconstruction and combined ACL/PCL/PLC reconstruction; however, they also reported the risk of overcorrection of abnormal external rotation and varus rotation.^{11,71,72} They reported an average postoperative Lysholm score of 91.7.

In our technique, we perform an anatomical reconstruction of LCL by harvesting a shorter strip (7 cm) from the anterior arm of split biceps tendon compared to Fanelli et al.'s technique. Therefore, we speculate our technique has a superior ability in preserving the dynamic functions of biceps femoris. In addition to this, it also helps to restore the native anatomy and isometry of LCL during the early flexion by using a graft running from the anterior aspect of the fibular head to the posterior aspect of the lateral epicondyle while closely replicating its native anatomical attachments.^{25,70}

PFL Reconstruction

Multiple isolated PFL reconstruction techniques have been described.^{25,55,64,71} Cartwright et al.⁵⁵ described a nonanatomical technique of PFL reconstruction using a split biceps tenodesis and reported satisfactory midterm outcomes of combined ACL and PLC reconstruction with their technique.

Fanelli and Larson²⁵ described the principles of PFL reconstruction and developed an isolated PFL reconstruction technique using semi-T graft loop fixed over the anterior cortex of fibula head using 2 parallel fibula tunnels but recommended the femoral tunnel to be placed over the isometric point on the lateral epicondyle. As an advancement of the aforementioned technique, Zhang et al.⁶⁴ developed a technique of isolated anatomical PFL reconstruction based on creating 2 tunnels in the head of fibula with a posterior exit and single blind femoral tunnel over the popliteal tendon attachment. However, the authors reported the risk of fractures when 2 diverging tunnels drilled through the cancellous bone in the fibular head making the technique difficult in smaller knees.⁷³ Since we drill a single fibula tunnel (4.5-6 mm), there is minimal risk of fibula head fracture compared with their technique.

We use a double stranded gracilis autograft to reconstruct the static isometric portion of the popliteus/PFL according to Fanelli et al. and Larson et al.'s description.^{25,47} There is no graft length issue involved in our technique compared with other techniques.

Limitations

This technique cannot be carried out in the presence of an incompetent proximal tibiofibular joint, because the reconstruction is tensioned through the fibula not across the proximal tibiofibular joint. When the biceps muscle tendon complex is compromised owing to the patient's injury, it may not be possible to perform the split biceps femoris tendon transfer for LCL reconstruction.

In conclusion, the Derby technique enables to perform an anatomical reconstruction of the main static PLC stabilizers (PFL and LCL) by using a single gracilis autograft and a split biceps tendon transfer that has not been previously reported.

References

1. LaPrade RF, Wentorf FA, Fritts H, Gundry C, Hightower CD. A prospective magnetic resonance imaging study of the incidence of posterolateral and multiple ligament injuries in acute knee injuries presenting with a haemarthrosis. *Arthroscopy* 2007;23:1341-1347.
2. Geeslin AG, LaPrade RF. Location of bone bruises and other osseous injuries associated with acute grade III isolated and combined posterolateral knee injuries. *Am J Sports Med* 2010;38:2502-2508.
3. Lee SH, Jung YB, Jung HJ, Song KS, Ko YB. Combined reconstruction for posterolateral rotatory instability with anterior cruciate ligament injuries of the knee. *Knee Surg Sports Traumatol Arthrosc* 2010;18:1219-1225.
4. LaPrade RF, Resig S, Wentorf F, Lewis JL. The effects of grade III posterolateral knee complex injuries on anterior cruciate ligament graft force. A biomechanical analysis. *Am J Sports Med* 1999;27:469-475.
5. Khanduja V, Somayaji HS, Harnett P, Utukuri M, Dowd GS. Combined reconstruction of chronic posterior cruciate ligament and posterolateral corner deficiency. A two- to nine-year follow-up study. *J Bone Joint Surg Br* 2006;88:1169-1172.
6. Chahla J, Moatshe G, Dean CS, LaPrade RF. Posterolateral corner of the knee: current concepts. *Arch Bone Joint Surg* 2016;4:97-103.
7. LaPrade RF, Terry GC. Injuries to the posterolateral aspect of the knee. Association of anatomic injury patterns with clinical instability. *Am J Sports Med* 1997;25:433-438.
8. Noyes FR, Barber-Westin SD, Albright JC. An analysis of the causes of failure in 57 consecutive posterolateral operative procedures. *Am J Sports Med* 2006;34:1419-1430.
9. LaPrade RF, Hamilton CD, Engebretsen L. Treatment of acute and chronic combined anterior cruciate ligament and posterolateral knee ligament injuries. *Sports Med Arthrosc* 1997;5:91-99.
10. Geeslin AG, LaPrade RF. Outcomes of treatment of acute grade-III isolated and combined posterolateral knee injuries: A prospective case series and surgical technique. *J Bone Joint Surg Am* 2011;93:1672-1683.
11. Fanelli GC. Surgical treatment of lateral posterolateral instability of the knee using biceps tendon procedures. *Sports Med Arthrosc* 2006;14:37-43.

12. Bonanzinga T, Zaffagnini S, Grassi A, Marcheggiani Muccioli GM, Neri MP, Marcacci M. Management of combined anterior cruciate ligament- posterolateral corner tears: A systematic review. *Am J Sports Med* 2013;42:1496-1503.
13. Ranawat A, Baker C, Henry S, Harner C. Posterolateral corner injury of the knee: evaluation and management. *J Am Acad Orthop Surg* 2008;16:506-518.
14. Serra Cruz R, Mitchell JJ, Dean CS, Chahla J, Moatshe G, LaPrade RF. Anatomic posterolateral corner reconstruction. *Arthrosc Tech* 2016;5:e563-e572.
15. Sanders TL, Johnson NR, Pareek, et al. Satisfactory knee function after single-stage posterolateral corner reconstruction in the multi-ligament injured/dislocated knee using the anatomic single-graft technique. *Knee Surg Sports Traumatol Arthrosc* 2018;26:1258-1265.
16. Black BS, Stannard JP. Repair versus reconstruction in acute posterolateral instability of the knee. *Sports Med Arthrosc* 2015;23:22-26.
17. Levy BA, Dajani KA, Morgan JA, Shah JP, Dahm DL, Stuart MJ. Repair versus reconstruction of the fibular collateral ligament and posterolateral corner in the multiligament-injured knee. *Am J Sports Med* 2010;38:804-809.
18. LaPrade RF, Johansen S, Wentorf FA, Engebretsen L, Esterberg JL, Tso A. An analysis of an anatomical posterolateral knee reconstruction: an in vitro biomechanical study and development of a surgical technique. *Am J Sports Med* 2004;32:1405-1414.
19. Geeslin A, Moulton S, LaPrade R. A systematic review of the outcomes of posterolateral corner knee injuries, part 1: Surgical treatment of acute injuries. *Am J Sports Med* 2016;44:1336-1342.
20. Franciozi CE, Albertoni LJB, Gracitelli GC, et al. Anatomic posterolateral corner reconstruction with autografts. *Arthrosc Tech* 2018;7:e89-e95.
21. Arciero RA. Anatomic posterolateral corner knee reconstruction. *Arthroscopy* 2005;21:1147.
22. Wentorf FA, LaPrade RF, Lewis JL, et al. The influence of the integrity of posterolateral structures on tibiofemoral orientation when an anterior cruciate ligament graft is tensioned. *Am J Sports Med* 2002;0:796-799.
23. Yoo JC, Ahn JH, Sung KS, Wang JH, Lee SH, Bae SW, Ahn YJ. Measurement and comparison of the difference in normal medial and lateral knee joint opening. *Knee Surg Sports Traumatol Arthrosc* 2006;14:1238-1244.
24. Hughston JC, Andrews JR, Cross MJ, Moschi A. Classification of knee ligament instabilities. Part II. The lateral compartment. *J Bone Joint Surg Am* 1976;58:173-179.
25. Fanelli GC, Larson RV. Practical management of posterolateral instability of the knee. *Arthroscopy* 2002;18(2 suppl):1-8.
26. LaPrade RF, Johansen S, Agel J, Risberg MA, Moksnes H, Engebretsen L. Outcomes of an anatomic posterolateral knee reconstruction. *J Bone Joint Surg Am* 2010;92:16-22.
27. LaPrade RF. Arthroscopic evaluation of the lateral compartment of knees with grade 3 posterolateral knee complex injuries. *Am J Sports Med* 1997;25:596-602. <https://doi.org/10.1177/036354659702500502>.
28. LaPrade RF, Ly TV, Wentorf FA, Engebretsen L. The posterolateral attachments of the knee: A qualitative and quantitative morphologic analysis of the fibular collateral ligament, popliteus tendon, popliteofibular ligament, and lateral gastrocnemius tendon. *Am J Sports Med* 2003;31:854-860.
29. Kuzma SA, Chow RM, Engasser WM, Stuart MJ, Levy BA. Reconstruction of the posterolateral corner of the knee with Achilles tendon allograft. *Arthrosc Tech* 2014;3:e393-e398.
30. Fanelli G, Orcutt D, Edson C. The multiple-ligament injured knee: Evaluation, treatment, and results. *Arthroscopy* 2005;21:471-486.
31. Shon O-J, Park J-W, Kim B-J. Current concepts of posterolateral corner injuries of the knee. *Knee Surg Relat Res* 2017;29:256.
32. Clancy WG Jr. Repair and reconstruction of the posterior cruciate ligament. In: Chapman MW, ed. *Operative orthopaedics*. Philadelphia, PA: JB Lippincott, 1998;1651-1665.
33. Larson RV. Isometry of the lateral collateral and popliteofibular ligaments and techniques for reconstruction using a free tendon graft. *Oper Tech Sports Med* 2001;9:84-90.
34. Moulton S, Geeslin A, LaPrade R. A systematic review of the outcomes of posterolateral corner knee injuries, part 2: Surgical treatment of chronic injuries. *Am J Sports Med* 2016;44:1616-1623.
35. LaPrade RF, Griffith CJ, Coobs BR, Geeslin AG, Johansen S, Engebretsen L. Improving outcomes for posterolateral knee injuries. *J Orthop Res* 2014;32:485-491.
36. LaPrade RF, Wentorf F. Diagnosis and treatment of posterolateral knee injuries. *Clin Orthop Relat Res* 2002;(402):110-121.
37. Yoon KH, Lee JH, Bae DK, Song SJ, Chung KY, Park YW. Comparison of clinical results of anatomic posterolateral corner reconstruction for posterolateral rotatory instability of the knee with or without popliteal tendon reconstruction. *Am J Sports Med* 2011;39:2421-2428.
38. Nau T, Chevalier Y, Hagemester N, deGuise JA, Duval N. Comparison of 2 surgical techniques of posterolateral corner reconstruction of the knee. *Am J Sports Med* 2005;33:1838-1845.
39. Rauh PB, Clancy WG Jr, Jasper LE, Curl LA, Belkoff S, Moorman CT III. Biomechanical evaluation of two reconstruction techniques for posterolateral instability of the knee. *J Bone Joint Surg Br* 2010;92:1460-1465.
40. Blackman AJ, Engasser WM, Krych AJ, Stuart MJ, Levy BA. Fibular head and tibial-based (2-tailed) posterolateral corner reconstruction. *Sports Med Arthrosc* 2015;23:44-50.
41. Wood R, Robinson J, Getgood A. anatomic posterolateral corner reconstruction using single graft plus adjustable-loop suspensory fixation device. *Arthrosc Tech* 2019;8:e301-e309. <https://doi.org/10.1016/j.eats.2018.11.011>.
42. Pache S, Sierra M, Larroque D, et al. Anatomic posterolateral corner reconstruction using semitendinosus and gracilis autografts: Surgical technique. *Arthrosc Tech* 2021;10:e487-e497. <https://doi.org/10.1016/j.eats.2020.10.033>.
43. Freychet B, Sonnery-Cottet B, Vieira TD, et al. Arthroscopic identification of the knee posterolateral corner structures and anatomic arthroscopic posterolateral corner reconstruction: Technical Note—Part 2. *Arthrosc Tech* 2020;9:e1985-e1992. [10.1016/j.eats.2020.08.033](https://doi.org/10.1016/j.eats.2020.08.033).

44. Hermanowicz K, Malinowski K, Góralczyk A, Guszczyn T, LaPrade RF. Minimally invasive, arthroscopic-assisted, anatomic posterolateral corner reconstruction. *Arthrosc Tech* 2019;8:e251-e257. <https://doi.org/10.1016/j.eats.2018.10.021>.
45. Treme GP, Ortiz G, Gill GK, et al. A biomechanical comparison of knee stability after posterolateral corner reconstruction: Arciero vs. LaPrade. *Orthop J Sports Med* 2017;5(7 suppl 6). 2325967117S00267.
46. Treme GP, Salas C, Ortiz G, et al. A biomechanical comparison of the Arciero and LaPrade reconstruction for posterolateral corner knee injuries. *Orthop J Sports Med* 2019;7. 2325967119838251.
47. Zhang H, Zhang J, Liu X, et al. In vitro comparison of popliteus tendon and popliteofibular ligament reconstruction in an external rotation injury model of the knee: A cadaveric study evaluated by a navigation system. *Am J Sports Med* 2013;41:2136-2142.
48. Markolf KL, Graves BR, Sigward SM, Jackson SR, McAllister DR. How well do anatomical reconstructions of the posterolateral corner restore varus stability to the posterior cruciate ligament-reconstructed knee? *Am J Sports Med* 2007;35:1117-1122.
49. Jung YB, Jung HJ, Kim SJ, et al. Posterolateral corner reconstruction for posterolateral rotatory instability combined with posterior cruciate ligament injuries: Comparison between fibular tunnel and tibial tunnel techniques. *Knee Surg Sports Traumatol Arthrosc* 2008;16: 239-248.
50. Larsen MW, Moynar AR, Moorman CT 3rd. Posterolateral corner reconstruction: Fibular-based technique. *J Knee Surg* 2005;18:163-166.
51. Zorzi C, Alam M, Iacono V, Madonna V, Rosa D, Maffulli N. Combined PCL and PLC reconstruction in chronic posterolateral instability. *Knee Surg Sports Traumatol Arthrosc* 2013;21:1036-1042.
52. Cooley VJ, Harrington RM, Larson RV. *Effect of lateral ligament reconstruction on intra-articular posterior cruciate ligament graft force and knee motion*. University of Washington research report, 1996;37-41.
53. Apsingi S, Nguyen T, Bull AM, Unwin A, Deehan DJ, Amis AA. A comparison of modified Larson and 'anatomic' posterolateral corner reconstructions in knees with combined PCL and posterolateral corner deficiency. *Knee Surg Sports Traumatol Arthrosc* 2009;17:305-312.
54. Cartwright-Terry M, Yates J, Tan CK, Pengas IP, Banks JV, McNicholas MJ. Medium-term (5-year) comparison of the functional outcomes of combined anterior cruciate ligament and posterolateral corner reconstruction compared with isolated anterior cruciate ligament reconstruction. *Arthroscopy* 2014;30:811-817.
55. Noyes FR, Barber-Westin SD. Long-term assessment of posterolateral ligament femoral-fibular reconstruction in chronic multiligament unstable knees. *Am J Sports Med* 2011;39:497-505.
56. Rios CG, Leger RR, Cote MP, Yang C, Arciero RA. Posterolateral corner reconstruction of the knee: Evaluation of a technique with clinical outcomes and stress radiography. *Am J Sports Med* 2010;38:1564-1574.
57. Schechinger S, Levy B, Dajani K, Shah J, Herrera D, Marx R. Achilles tendon allograft reconstruction of the fibular collateral ligament and posterolateral corner. *Arthroscopy* 2009;25:232-242.
58. Yang B, Bae W, Ha J, Lee D, Jang H, Kim J. Posterolateral corner reconstruction using the single fibular sling method for posterolateral rotatory instability of the knee. *Am J Sports Med* 2013;41:1605-1612.
59. Grimm NL, Levy BJ, Jimenez AE, Bell R, Arciero RA. Open anatomic reconstruction of the posterolateral corner: The Arciero technique. *Arthrosc Tech* 2020;9: e1409-e1414. <https://doi.org/10.1016/j.eats.2020.05.022>.
60. Frings J, Kolb JP, Drenck TC, et al. Anatomic reconstruction of the posterolateral corner: An all-arthroscopic technique. *Arthrosc Tech* 2019;8:e153-e161. <https://doi.org/10.1016/j.eats.2018.10.010>.
61. Feeley BT, Muller MS, Sherman S, Allen AA, Pearle AD. Comparison of posterolateral corner reconstructions using computer-assisted navigation. *Arthroscopy* 2010;26:1088-1095. <https://doi.org/10.1016/j.arthro.2009.12.014>.
62. Ho EP, Lam MH, Chung MM, et al. Comparison of 2 surgical techniques for reconstructing posterolateral corner of the knee: A cadaveric study evaluated by navigation system. *Arthroscopy* 2011;27:89-96.
63. Zhang H, Feng H, Hong L, Wang XS, Zhang J. Popliteofibular ligament reconstruction for posterolateral external rotation instability of the knee. *Knee Surg Sports Traumatol Arthrosc* 2009;17:1070.
64. Moatshe G, Dean CS, Cruz RS, LaPrade RS. Anatomic fibular collateral ligament reconstruction. *Arthrosc Tech* 2016;5:e309-e314.
65. Terry GC, LaPrade RF. The biceps femoris muscle complex at the knee. *Am J Sports Med* 1996;24:1-8.
66. Veltri DM, Warren RF. Operative treatment of posterolateral instability of the knee. *Clin Sports Med* 1994;13:615-627.
67. Djian P. Posterolateral knee reconstruction. *Orthop Traumatol Surg Res* 2015;101:S159-S170.
68. Kim SJ, Shin SJ, Jeong JH. Posterolateral rotatory instability treated by a modified biceps rerouting technique: Technical considerations and results in cases with and without posterior cruciate ligament insufficiency. *Arthroscopy* 2003;19:493-499. <https://doi.org/10.1053/jars.2003.50102>.
69. Zhao J, He Y, Wang J. Anatomical reconstruction of knee posterolateral complex with the tendon of the long head of biceps femoris. *Am J Sports Med* 2006;34:1615-1622.
70. Sidles JA, Larson RV, Garbini JL, et al. Ligament length relationships in the moving knee. *J Orthop Res* 1988;6:593-610.
71. Fanelli GC, Edson CJ. Combined posterior cruciate ligament—posterolateral reconstruction with Achilles tendon allograft and biceps femoris tendon tenodesis: 2-10 year follow-up. *Arthroscopy* 2004;20:339-345.
72. Fanelli G, Edson C. Surgical treatment of combined PCL—ACL medial and lateral side injuries (global laxity): Surgical technique and 2 to 18 year results. *J Knee Surg* 2012;25:307-316.
73. Zhang H, Hong L, Wang XS, et al. Single-bundle posterior cruciate ligament reconstruction and mini-open popliteofibular ligament reconstruction in knees with severe posterior and posterolateral rotation instability: Clinical results of minimum 2-year follow-up. *Arthroscopy* 2010;26:508-514.