

*Nephroquiz*  
(Section Editor: M. G. Zeier)

## An unusual case of familial cystic kidney disease

Seerapani Gopaluni<sup>1</sup>, Matthew Gibson<sup>2</sup> and Mobin Mohteshamzadeh<sup>1</sup>

<sup>1</sup>Renal Unit, Royal Berkshire Hospital, Reading, UK and <sup>2</sup>Department of Radiology, Royal Berkshire Hospital, Reading, UK

Correspondence and offprint requests to: Seerapani Gopaluni; E-mail: pani.gopaluni@yahoo.com

**Keywords:** cystic kidney disease; autosomal polycystic kidney disease; renal lymphangiomas

### Case

A 46-year-old woman with a prior diagnosis of autosomal dominant polycystic kidney disease (ADPKD) was referred to the nephrology clinic with abdominal fullness. She had been diagnosed with ADPKD by ultrasound 10 years previously at a different renal unit and was subsequently lost to follow-up. Her father was diagnosed with polycystic kidney disease at the age of 74 with a normal kidney function. Her sister was also diagnosed with polycystic kidney disease at a different renal unit following this patient's diagnosis.

Her past medical history included severe menorrhagia, iron deficiency anaemia, anxiety, bilateral pleural effusions and polycystic ovaries. She was on perindopril for hypertension though her compliance had been variable. She never suffered from haematuria, back pain or cyst infections. Systemic enquiry did not reveal any significant symptoms. She presented to her general practitioner 2 years prior to this presentation with bilateral swelling of the legs that resolved spontaneously after a month.

On examination she was well. Her blood pressure was 130/92 mmHg. Abdominal examination revealed bilaterally enlarged kidneys. Examination of other systems was unremarkable apart from minimal peripheral oedema. Urine dipstick revealed +protein and no blood. Renal function was normal with a creatinine of 50 µmol/L. She had a normal MRA and MRI of the head which had been requested to rule out berry aneurysms, as there was a family history of death due to 'stroke'.

A repeat ultrasound scan of the abdomen showed bilateral polycystic kidneys. There was a small amount of free fluid within the pelvis and as part of the investigation of this a computed tomography (CT) of the abdomen and pelvis was requested. This showed (Figures 1 and 2) bilateral perinephric fluid collections and a trace of free fluid. The other organs appeared normal. There was no lymphadenopathy.

### Question

What is the condition causing cystic appearance of the kidneys on the ultrasound and CT?

### Answer

The appearances on CT were typical for renal lymphangiomas rather than ADPKD.

### Discussion

Renal lymphangiomas are also referred to as renal lymphangioma, peripelvic lymphangiectasia, renal peripelvic multicystic lymphangiectasia and hygroma renale.

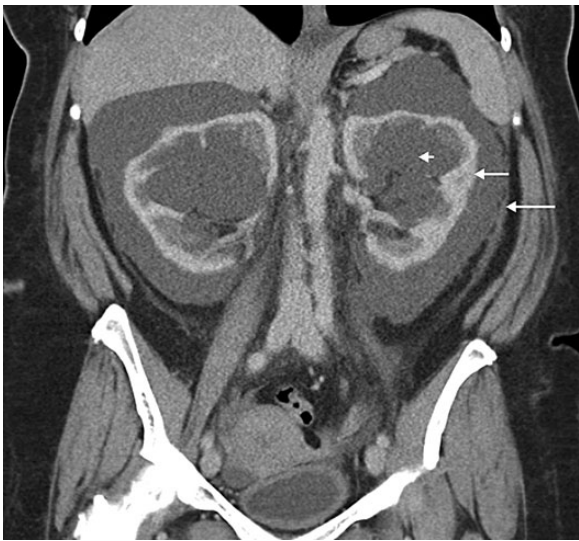It is a rare disease characterized by lymphatic vessel proliferation causing cystic masses in the renal parenchyma, renal sinuses or perinephric spaces [1]. It can be congenital or acquired and is caused by malformation of renal lymphatic drainage to retroperitoneal lymph ducts. It can affect the members of the same family supporting the familial nature of this disease [2].

The patients may be completely asymptomatic and diagnosed incidentally. Flank pain [1, 3], abdominal distension, ascites, haematuria, fatigue, weight loss, hypertension and polycythaemia have been described. It can be a part of the presentation with generalized lymphangiomas. Pregnancy is thought to exacerbate the condition with development of ascites and perinephric haemorrhage [4].

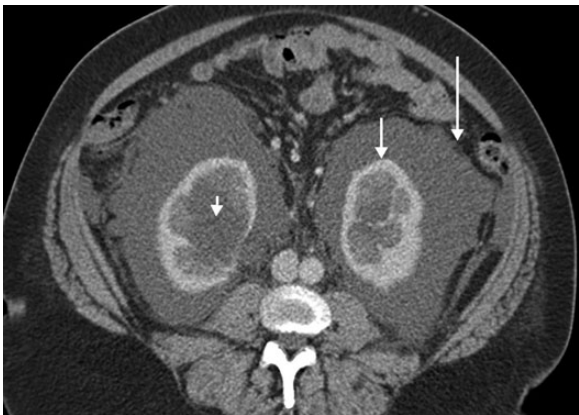
It can sometimes take an unusually long time before a diagnosis is established. A patient presented with lymphoedema in childhood and was treated intermittently for related symptoms before a diagnosis was achieved 36 years later [5].

The condition can be very difficult to differentiate clinically, radiologically and surgically from ADPKD. Patients usually present with normal kidney function and electrolytes. Ultrasound may be reported as ADPKD because of the multiple cysts in both kidneys. However, there may be subtle differences in the appearances as in ADPKD the cysts are parenchymal, whereas those with lymphangiomas are parapelvic with relatively normal renal parenchyma.

Abdominal CT may demonstrate bilateral, multilocular, fluid-filled cystic masses with low attenuation in the perirenal and peripelvic region. The perinephric spaces consist of the subcapsular, perirenal, anterior and posterior



**Fig. 1.** Coronal CT showing perinephric fluid (long arrow) surrounding renal cortex (medium arrow) and parapelvic fluid (short arrow).



**Fig. 2.** Axial CT showing perinephric fluid (long arrow) surrounding renal cortex (medium arrow) and parapelvic fluid (short arrow).

pararenal spaces. Fluid may collect in one or more of these compartments and this can be readily demonstrated by cross-sectional imaging, particularly CT [6]. The cysts do not show contrast enhancement.

MRI demonstrates bilaterally enlarged kidneys with multiple T2 hyperintense and T1 hypointense, non-enhancing cysts in both perirenal spaces and the peripelvic areas [7]. MRI can also demonstrate the extent of the disease, including retroperitoneal lesions.

Lymphoscintigraphy can provide direct evidence of the abnormal lymphatic flows associated with lymphangiomas [5].

Aspiration of the cysts, perinephric fluid or ascites may show sporadic cells, small amounts of fat globules, protein and high renin levels distinguishing it from normal lymph.

The ultrasound appearances can sometimes be mistaken for hydronephrosis [3] due to the position of the cysts in the renal sinus. Other differential diagnoses include perinephric abscess, perirenal urine collection, subcapsular and perirenal haematoma, pancreatic pararenal fluid collections and transudate fluid associated with nephropathies [6].

Asymptomatic patients do not need treatment. When the pressure effects of enlarged kidneys give rise to significant symptoms, percutaneous drainage may be carried out. Percutaneous drainage and repeated sclerotherapy has been reported to be a safe, minimally invasive and effective technique for treating this condition in comparison to surgical techniques. Exacerbations during pregnancy were successfully treated with repeated percutaneous drainage. In severe cases nephrectomy may be needed.

This is a rare condition that can be familial and can simulate ADPKD radiologically. Nephrologists should be aware of the other causes of polycystic kidneys and avoid unnecessary treatments and investigations.

*Conflict of interest statement.* This manuscript has not been published or submitted anywhere else.

## References

1. Vega J, Santamarina M. Unilateral renal lymphangiectasia: report of one case. *Rev Med Chil* 2012; 140: 1312–1325.
2. Antonopoulos P, Charalampopoulos G, Constantinidis F et al. Familial renal retroperitoneal lymphangiomas: personal experience and review of literature. *JBR-BTR* 2010; 93: 258–261
3. Sarikaya B, Akturk Y, Bekar U et al. Bilateral renal lymphangiomas mimicking hydronephrosis: multidetector CT urographic findings. *Abdom Imaging* 2006; 31: 732–734. Epub 2006 Jan 30
4. Meredith WT, Levine E, Ahlstrom NG et al. Exacerbation of familial renal lymphangiomas during pregnancy. *AJR Am J Roentgenol* 1988; 151: 965–966
5. Beveridge N, Allen L, Rogers K. Lymphoscintigraphy in the diagnosis of lymphangiomas. *Clin Nucl Med* 2010; 35: 579–582.
6. Haddad MC, Hawary MM, Khoury NJ et al. Radiology of perinephric fluid collections. *Clin Radiol* 2002; 57: 339–346
7. Bagheri MH, Zare Z, Sefidbakht S et al. Bilateral renal lymphangiomas: sonographic findings. *J Clin Ultrasound* 2009; 37: 115–118.

Received for publication: 27.3.14; Accepted in revised form: 24.6.14