

Clinical studies of alveolar-capillary permeability using technetium-99m DTPA aerosol

Felix X. SUNDRAM

Senior Consultant, Nuclear Medicine Department, Singapore General Hospital

Soluble radioaerosols such as technetium-99m diethylene triamine pentacetate (DTPA) permit simple quantitative studies of alveolar-capillary permeability to be performed, since the submicronic aerosols are deposited mainly at the lung periphery and are cleared across the alveolar-capillary membrane. Regional alterations in permeability can also be noted using this radionuclide technique. We have measured the pulmonary epithelial permeability in normal subjects and the alteration in smokers, in glue-sniffers, in patients with inhalation burns, in chronic obstructive pulmonary disease (COPD) and in patients with lung metastases from thyroid cancer treated with radioiodine ^{131}I . In the normal volunteers, the time taken for 50% of inhaled $^{99\text{m}}\text{Tc}$ DTPA to be cleared from the lungs ($T_{1/2}$) was 66 minutes \pm 1sd of 12 mins. The smokers had a mean $T_{1/2}$ of 20 mins \pm 1sd 4 min. In the hard-core glue-sniffing group, the majority were smokers who had stopped smoking and glue-sniffing for periods varying from 1 day to 42 days, and it was possible to note the changes in clearance times against period of abstinence.

In the patients with inhalation burns, there was change in lung clearance arising from pulmonary epithelial damage; these patients showed increased rate of clearance (short $T_{1/2}$) with mean $T_{1/2}$ of 36 min \pm 1sd of 11 mins, while the retention images revealed regional lung damage in moderately severe inhalation burns. Twenty-four patients with COPD had inhalation scans done with Tc-99m tin colloid radioaerosol, and these images were compared with the perfusion lung scans done with $^{99\text{m}}\text{Tc}$ macroaggregated albumin (MAA); in general the perfusion images matched the defects noted in the inhalation scans. The $^{99\text{m}}\text{Tc}$ DTPA clearance rate in these patients was normal i.e. $T_{1/2} = 78 \pm 14$ mins. In the thyroid cancer patients with lung metastases, who had high doses of radioiodine treatment, the $T_{1/2}$ values were normal or prolonged slightly, mean $T_{1/2} = 76$ min \pm 23.

Key words: alveolar-capillary permeability, inhalation burns, COPD (chronic obstructive pulmonary disease), glue sniffers, thyroid cancer lung metastases

INTRODUCTION

THE ALVEOLAR EPITHELIUM and the capillary endothelium together form the alveolar capillary membrane. Fluid exchange occurs across this membrane, and is dependent on intravascular and interstitial hydrostatic and oncotic pressures, and on permeability of this membrane. Damage to either the alveolar or capillary component can result in a high permeability pulmonary oedema, even though the alveolar epithelium forms an extremely tight mem-

brane which is ten times less permeable than the capillary endothelium.¹ Acute lung injury is defined as "a syndrome of inflammation and increasing permeability that is associated with a constellation of clinical, radiologic, and physiologic abnormalities that cannot be explained by, but may coexist with, left atrial or pulmonary capillary hypertension."² It has been proposed that definition of acute lung injury should relate structural to pathophysiological changes.³ Alteration in capillary membrane integrity (permeability) cannot be quantified by a single parameter and this is relevant when pulmonary vascular permeability is evaluated in the clinical situation.

Nuclear medicine methods can be used to observe changes in integrity of pulmonary capillary endothelium (with first pass dual-indicator dilution technique using successive injections of radiotracer⁴ or by measuring

Based on an invited lecture at the 35th Annual Scientific Meeting of the Japanese Society of Nuclear Medicine, Yokohama, October, 1995.

For reprint contact: Felix X. Sundram, M.D., Nuclear Medicine Department, Singapore General Hospital, Singapore 169608

accumulation of radioactively labelled protein into the lung),⁵ and of alveolar epithelium, and it is important that the damage should be detected before patients develop clinical pulmonary oedema, so that intensive therapy can be instituted early. We have used ^{99m}Tc DTPA radioaerosol to measure alteration in pulmonary epithelial permeability (alveolar-capillary membrane) and to image the distribution of ventilation in normal and some pathological states.

METHODS

Ventilation studies with radioaerosol have been done routinely in Nuclear Medicine Department, Singapore General Hospital since 1986. Clearance measurements of ^{99m}Tc DTPA aerosol across the alveolar capillary membrane were done initially in 30 normal volunteers (army personnel). Subsequently in 1987, all patients with burns who were entered into a study protocol for burns also had the radioaerosol clearance study, and 48 patients with suspicion of inhalation burns have been studied.

We also studied 10 cigarette smokers to confirm the rapid radioaerosol clearance from the lungs in this group. Twenty young hardcore glue sniffers from the Sembawang Detention Centre were studied to note any alveolar-capillary membrane damage from inhalant abuse. Most of these young men were smokers, and since smoking and glue-sniffing was forbidden at the Centre, we were also able to study the effects of cessation for varying periods, on the clearance rate of the radioaerosol from the lungs in glue-sniffing. In 1988 we participated in a programme with the International Atomic Energy Agency (IAEA) to image the ventilation of the lung in chronic obstructive pulmonary disease (COPD) with ^{99m}Tc tin colloid aerosol, and to compare this with perfusion of the lung using ^{99m}Tc macroaggregated albumin (MAA). We took this opportunity to study also the lung clearance of ^{99m}Tc DTPA radioaerosol in 18 of these patients. In these COPD patients we noted the deposition pattern of inhaled radiocolloid aerosol to help differentiate the nature of the obstructive airways disease. X-ray chest was done routinely and all of them had lung function tests done, with only those patients having a FEV₁ of < 70% being entered into the study.

The subjects breathe a submicronic aerosol of ^{99m}Tc DTPA (1 μm mean mass aerodynamic diameter, Ultravent, USA) for 2–3 min after instillation of 20–25 mCi (740–925 MBq) of freshly prepared ^{99m}Tc DTPA into the nebuliser. The radioactive solute was prepared by adding the technetium-99m dose in 2 ml physiological saline into a commercial vial of DTPA (Amersham UK), and the binding of ^{99m}Tc to DTPA was about 95%, using paper chromatography. The nebuliser was connected to the wall oxygen supply and a flow rate of 10 L/min was used. Immediately following the radioaerosol inhalation in a lying position, a dynamic acquisition was started using an

Table 1 Summary of bronchoscopy and ventilation study results (Burns Patients)

	Bronchoscopy			
	Grade 0 + 1	Grade 2	Grade 3	Total
Normal subjects: T _{1/2} = 66 ± 1sd of 12 mins (n = 30)				
No of patients with bronchoscopy and ventilation study = 48 Burns Patients: T _{1/2} = 39 ± 1sd of 12 mins (n = 48)				
Normal T _{1/2} (mean = 60 mins)	n = 22	4	4	30
Abnormal T _{1/2} (mean = 31 mins)	n = 4	2	12	18
Total	26	6	16	48

Elscent Apex 409A or ADAC Vertex gamma camera/computer system with the patient supine and the gamma-camera placed posteriorly over the lungs. Twenty frames at 1 minute per frame were acquired over the 20 minute period using a 64 × 64 spatial resolution. Subsequent reframing was done to produce a single reframed image and regions of interest (ROI'S) were drawn around each lung or parts of the lung. Time-activity curves were then obtained for each region/lung and an exponential fit was performed on the time-activity curves from peak to 7 minutes to obtain a clearance half-time (T_{1/2}) i.e. time for 50% of the radioaerosol to clear from the lung. Retention images were also generated to note any discrepancy in regional lung clearance of ^{99m}Tc DTPA aerosol. No corrections were made for contribution of circulating and tissue radioactivity to the total counts detected over the lung field i.e. non-lung parenchymal radioactivity, as this is usually minimal.

The ventilation study was generally done within 3 days of admission in the burns patients. Serial studies were done in some patients in hospital and as outpatients. Fibreoptic bronchoscopy was usually done within a day of the burns, using an Olympus bronchofibrescope BF Type B2. The severity of damage noted at bronchoscopy was graded as follows:

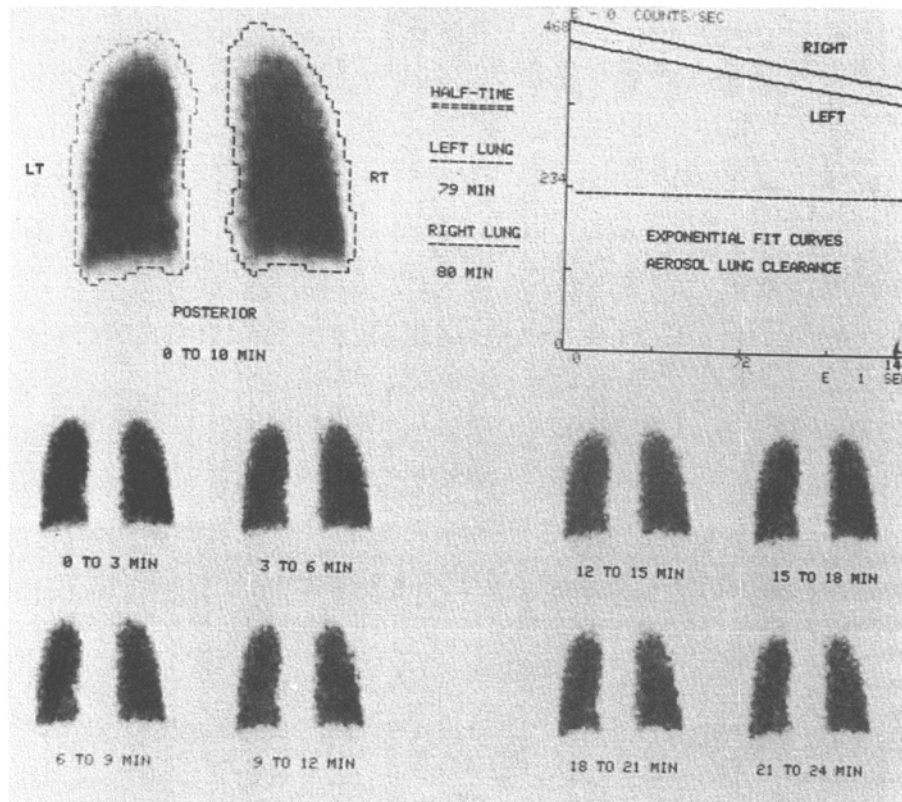
- 0 = normal
- 1 = mild oedema and hyperemia
- 2 = moderate oedema, hyperemia and secretions
- 3 = severe oedema, inflammation, ulceration and slough

Twelve of the burns patients studied were Koreans who were involved in an ammonia tank explosion on board a ship. The remaining 36 were patients from Singapore who were exposed accidentally to kerosine stove fires or gas explosions, or who had attempted suicide.

We treat many patients with differentiated thyroid cancer each year (average 40 per year). Twelve of these patients had lung metastases and had received cumulative radioiodine treatment doses of 500–800 mCi (19–30

Table 2 Change in clearance rates with time (Burns Patients)

Name	Date	Right lung T _{1/2}	Left lung T _{1/2}	X-ray chest
BJU	Day 2	29 mins	24 mins	Normal
	Day 16	33 mins	25 mins	Patchy bilateral opacities
	Day 36	35 mins	35 mins	Patchy bilateral opacities
KMS	Day 1	25 mins	31 mins	Increased markings right lower zone
	Day 18	18 mins	18 mins	Increased markings right lower zone
	Day 20	23 mins	24 mins	Right lower zone effusion and patchy left lower zone
JUB	Day 1	40 mins	34 mins	Normal
	Day 15	70 mins	50 mins	Normal

**Fig. 1** Normal study.

GBq). The aerosol study was done in the morning prior to treatment with radioiodine (off thyroxine for 5 weeks) in the afternoon, the last treatment dose being about six months previously. X-ray chest was done routinely and CT scan of thorax in some of these patients, but pulmonary function tests were not done. None of these patients were smokers. The patients received radioiodine treatment from 8 years previously (6 patients) to 4 years previously (4 patients) and 2 years previously (2 patients). The 12 patients had the aerosol study, to note damage to alveolar-capillary membrane, if any.

RESULTS

1. Normals and Inhalation Burns

In the 30 normal, non-smoking adult volunteers, the T_{1/2} ranged from 47 to 78 minutes with a mean of 66

mins \pm 1sd 12 mins. The volunteers were aged 18–20 years while the patients were in the 30–45 age group. There were no significant differences in clearance between right and left lung.

Table 1 summarizes the findings in the study of normals and in patients with suspected inhalation burns, while Table 2 notes the change in clearance rates over a period of time in three patients with inhalation burns. Figure 1 and Figure 2 show the time-activity clearance curves and the retention images in a normal and abnormal study respectively.

In the group of 65 patients with suspicion of inhalation injury, only 48 had both bronchoscopy and ventilation study; of these 48, 12 were Korean males in their thirties. They were exposed to ammonia from an ammonia tank explosion on board a ship in the South China Sea and they were flown to the Singapore General Hospital the same

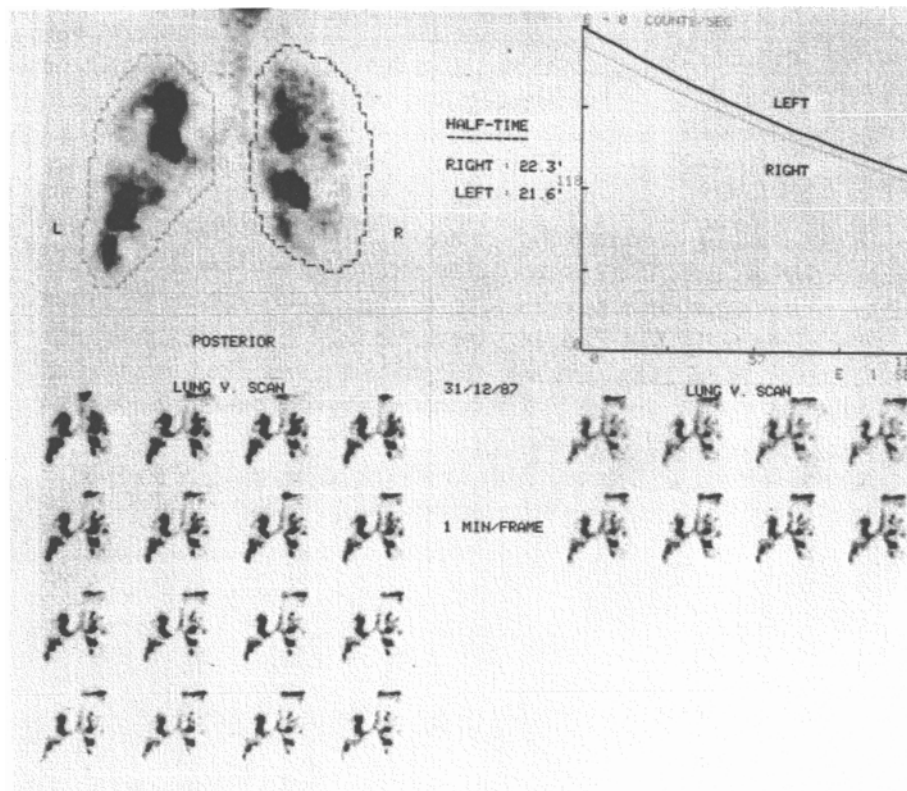


Fig. 2 Abnormal study.

day and managed by the Burns Unit in this hospital. An inhalation injury caused by chemicals was presumed and though 15 were transferred from the ship to hospital only 12 were able to have the aerosol studies done. All these twelve also had bronchoscopy done mostly within a day after admission, though in one of them the delay was 5 days. There were 36 local patients, who had both bronchoscopy and ventilation study done. This group of patients was exposed to thermal injury or products of combustion.

The retention images in normal subjects showed faster clearance of tracer in the apices and edges of the lung fields. Similarly in the patients with abnormal bronchoscopic findings the ventilation images generally showed patchy radioaerosol distribution in both lungs, while the retention images showed obvious increased regional clearance in only a few patients with high likelihood of lung parenchymal damage. Chest X-rays were normal in most of the patients at time of ventilation study, though subsequent films did show evidence of bilateral patchy infiltration (pneumonitis) or oedema, particularly in the basal areas. Pulmonary function measurement was done in only a few patients and no analysis could be done. There was no correlation between the partial pressure of arterial oxygen PaO_2 , and the grading of bronchoscopic findings or the ventilation study $T_{1/2}$ results.

2. Chronic Obstructive Pulmonary Disease (COPD)

Table 3 summarizes the results of aerosol deposition pattern and clearance times in patients with COPD. It is to

be noted that the radioaerosol deposition tends to be central in patients with emphysema, and more peripheral in bronchitic patients, while a fair number of patients will tend to show a mixed pattern. The X-ray chest can be normal in some of these patients. The mean $T_{1/2}$ from Tc-99m DTPA clearance in these patients was 78 ± 14 min. The perfusion images largely matched the ventilation images in these patients with COPD.

Figures 3, 4 and show patterns of aerosol deposition in moderate and severe COPD, together with clearance curves.

3. Smokers and Glue-sniffers

In this group, there were 10 smokers (Volunteers), and 20 glue-sniffers from Sembawang Detention Centre. The smokers had an abnormally rapid mean $T_{1/2}$ clearance time of 20 mins; as can be seen from Figure 5, in the glue-sniffers, the longer the period of abstinence from cigarettes, the larger the $T_{1/2}$ clearance times obtained. In only 1 of the glue-sniffers who was always a non-smoker, and stopped glue-sniffing for 30 days, was the $T_{1/2}$ abnormal i.e. 36 mins, indicating that there is some alveolar-capillary damage in the long-term, in hard-core glue-sniffers. It also appears that the recovery of clearance times to normal on cessation of smoking is prolonged in the glue-sniffers, quite apart from any neurological damage.

4. Thyroid Cancer Lung Metastases

The mean clearance half-time value was 76 ± 23 mins in

Table 3 COPD ventilation perfusion study

Clinical diagnosis	No. of patients	Aerosol deposition pattern	Perfusion scan		X-ray chest
			AN	N	
Emphysema (E)	9	Central (C)	9	0	HIL
Bronchitis (B)	7	Peripheral (P)	5	2	ILM
Mixed	8	C + P	8	0	both

HIL = hyperinflated lung

ILM = increased lung markings

AN = Abnormal

N = Normal

Clearance $T_{1/2}$ in 18 patients (9E, 9B) = 78 ± 1 sd 14 mins.

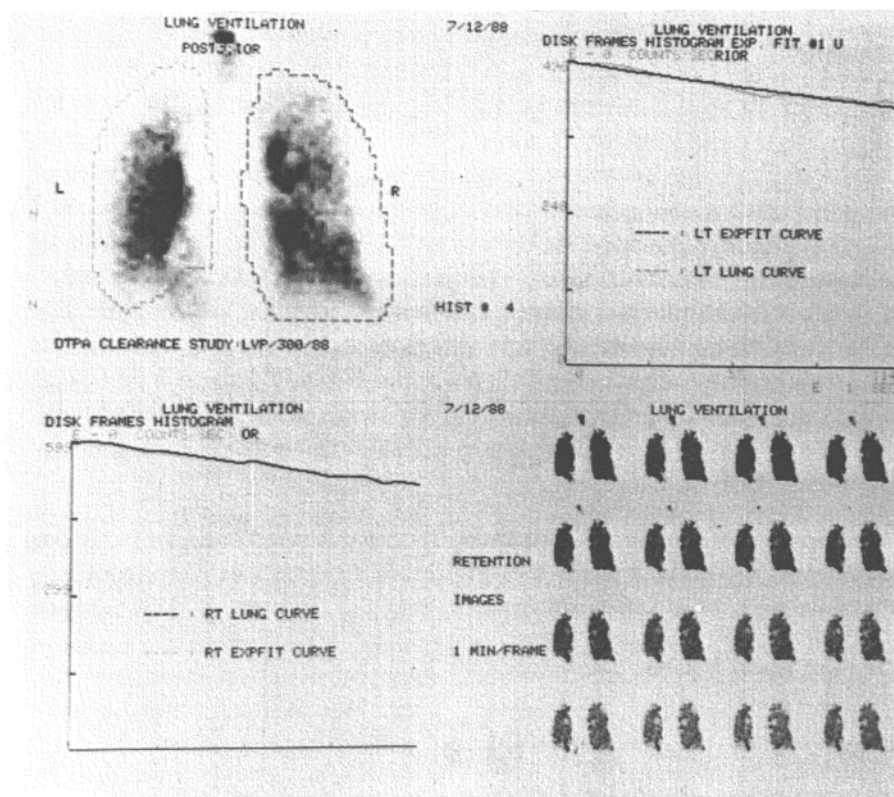


Fig. 3 Clearance study in moderate COPD.

these 12 thyroid cancer patients with lung metastases and who had received radioiodine treatment. Since the numbers are small it is not possible to make meaningful inference between administered radioiodine dose and ^{99m}Tc DTPA clearance $T_{1/2}$ time. However only two patients had low $T_{1/2}$ values (41 min and 49 min) and both these patients had diffuse lung involvement by metastases, compared to the other 10 who had patchy areas of metastatic lung disease. These two patients were given 600 mCi of radioiodine ^{131}I , over a period of 3 years, and are still continuing with the treatment. Though ^{131}I uptake in the lungs was measured (mean uptake = 10% at 72 hours, of administered dose) no calculations were made in terms of radiation dose delivered to the lung.

DISCUSSION

Normals

Our group of 30 normal volunteers was fairly young i.e. mean age = 19. The mean clearance $T_{1/2}$ obtained was 66 mins, and this is slightly lower than that reported from other centres, where older volunteers were studied. A previous study⁶ has shown a variation in clearance $T_{1/2}$ with age, with younger volunteers showing a more rapid clearance; this accounts for our slightly lower normal values.

Smokers and glue-sniffers

Cigarette smoking is known to cause increased ^{99m}Tc

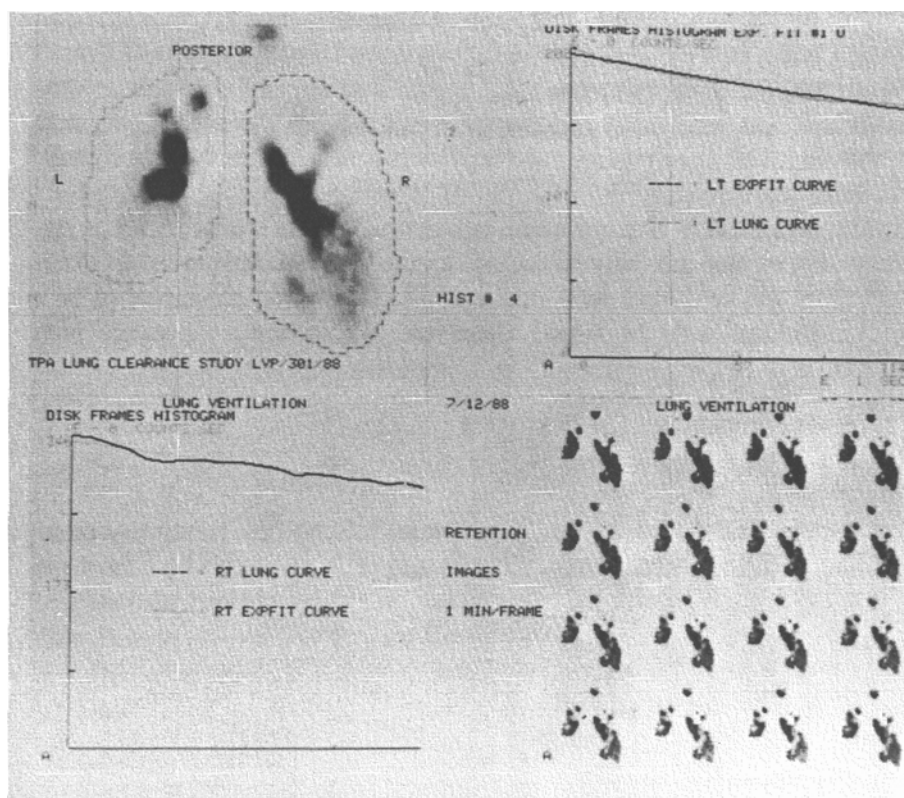


Fig. 4 Clearance study in severe COPD.

DTPA pulmonary clearance,^{7,8} and this has been borne out in our study of 10 smokers where the mean $T_{1/2}$ is considerably reduced to 20 mins. Studies on regular smokers who stopped smoking have shown that the increased clearance rate returned towards normal, with a significant improvement (decreased rate) in $T_{1/2}$ as early as 24 hours.⁹ However in young hard-core glue-sniffers this does not appear to be so. We have studied the pulmonary clearance in these 20 young men from the Sembawang Detention Centre, where they were off cigarettes and glue-sniffing for periods ranging from 1 day to 30 days. Unfortunately, owing to transport and detention logistics, there are not many in each group of days off smoking, but it appears that even up to one week, the clearance-rates are faster than normal. As can be seen from Figure 5, even at four weeks, the clearance-rates are just about approaching the normal range. This indicates that with the superimposition of inhalant abuse on smoking, there is prolonged alteration of the alveolar capillary membrane permeability. Only one out of the 20 men was a regular non-smoker whom we studied at day 30, and he had an abnormal $T_{1/2}$ of 36 mins, suggesting altered alveolar-capillary permeability from inhalant abuse alone. The information in Figure 5 can be utilized in anti-smoking clinics and in rehabilitation of glue-sniffers.

Over the last 3 years there has been a considerable reduction in glue-sniffing in Singapore with very few admissions to the Detention Centre.

Inhalation burns

Inhalation injuries resulting from fires are uncommon in the lower airways and lung parenchyma, unless there is steam exposure. Chemical injuries to the respiratory tract depend on the chemical involved, the concentration of the chemical, its solubility and duration of exposure. Ammonia for example tends to dissolve in the upper respiratory tract and cause injury there but when the concentration is high or the exposure is prolonged, there may be damage to the lower respiratory tract as evidenced by our study of the 12 patients exposed to an ammonia tank explosion, when both the bronchoscopy and ventilation study showed abnormal findings in 9 of 12 patients.

Fibreoptic bronchoscopy, Xenon-133 lung scans and pulmonary functions tests have been useful objective tests in the diagnosis of inhalation burn injury.¹⁰ Bronchoscopy is safe and accurate and it is possible to visualize larynx, trachea, carina and main stem and segmental bronchi. Xenon-133 lung scanning is not available in our part of the world, and is expensive for us to use routinely; hence our decision to use ^{99m}Tc DTPA aerosol. Both the radioaerosol and the Xenon lung scan have the limitation of false positives and false negatives in patients with pre-existing lung disease, and if they are smokers. Our patients were healthy young persons who had no proven lung disease previously, though some of them in the ammonia burns group may have been smokers. The damage caused by the ammonia was probably worse than the effects of smoking

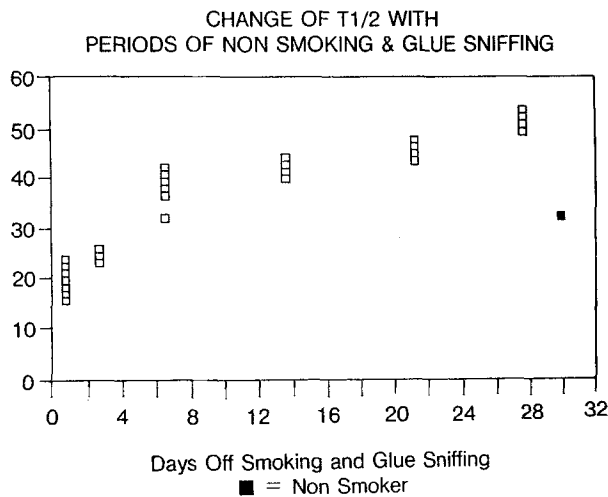


Fig. 5 Clearance study in glue-sniffers.

as proven by the bronchoscopy findings. Pulmonary function tests such as FEV1%, and MEFV (maximum expiratory flow volume) were not done routinely as it would have been difficult for most of these patients to cooperate. A previous study done at this hospital¹⁰ did not show any correlation between severity of bronchoscopic changes and PaO₂ or the severity of the skin burn. The false negative radioaerosol ventilation results are possibly due to this investigation being done one week after the bronchoscopy, while the false positives are either due to effect of smoking, or due to the delayed bronchoscopy being normal 5 days after the ventilation scan.

It would appear that the retention images produced to obtain an index of regional lung ventilation and damage, are not useful in most cases. Serial studies in a few patients with lung parenchymal damage from inhalation burns have shown progressive improvement, deterioration, or no change in regional ventilation and clearance times of the radioaerosol, as shown in Table 2. Most of the Koreans were flown back to Korea soon after the accident and hence it was not possible to get long-term serial studies.

Studies using the plain chest film after smoke inhalation,¹¹ have pointed to bronchial wall thickening and subglottic oedema, as heralding more serious respiratory damage both to the upper airways and to the lung parenchyma. We have not been able to correlate the radioaerosol clearance times with the X-ray chest findings.

An increase in the rate of submicronic aerosol of Tc-99m DTPA clearance from the lungs has been reported in normal persons breathing at high lung volumes,¹² healthy cigarette smokers,⁹ patients with chronic interstitial lung disease¹³ and in patients with adult respiratory distress syndrome¹⁴ and in assessing lung damage in AIDS.¹⁵ Hence there is a belief that measuring altered respiratory epithelial permeability using clearance rate of ^{99m}Tc DTPA radioaerosol is not specific enough for use in the clinical situation.¹⁶ In otherwise healthy, particularly young patients with no pre-existing lung disease and who are non-smokers (as is often the case here), there is a useful role

for simple radioaerosol studies in assessing the lung parenchymal damage from respiratory burns.

Other studies¹⁷ stress the need for early diagnosis of the inhalation burn so that adequate treatment may be instituted early. Our preliminary study¹⁸ indicated that there was a definite role for DTPA clearance study in suspected inhalation burns, and this has been borne out after more patients have been entered into the study.^{19,20}

Chronic obstructive pulmonary disease (COPD)

We used a non-diffusible tracer (^{99m}Tc (tin) colloid) to image the pattern of ventilation of the lungs in COPD, and compared the inhalation images to the perfusion images that were subsequently acquired using i.v. ^{99m}Tc macroaggregated albumin (MAA). In general, the study indicated that in COPD, there were matched ventilation and perfusion abnormalities, confirming that regional ventilation regulates regional perfusion. The deposition patterns of the inhaled aerosol also help in differentiating the nature of the COPD; from the study we noted that the aerosol deposition tended to be central in emphysema, and peripheral in bronchitis, though obviously there will be mixed patterns in some patients. It is possible that abnormal deposition patterns may be noted earlier than changes in X-ray chest.²¹

The ^{99m}Tc DTPA clearance study was done in eight of these patients with COPD; there was no reduction in clearance T_{1/2}. If at all the T_{1/2} was slightly increased, due in part to the central tracer deposition with poor clearance from this site. The mean T_{1/2} was 78 mins which is close to our normal range. Previous studies have also shown that COPD per se does not cause an increase in the rate of ^{99m}Tc DTPA clearance.¹³ Further ^{99m}Tc DTPA aerosol clearance studies are also being done as part of a regional coordinated study on the influence of urban air pollution on altered lung function. The initial findings conclude that in cities with high levels of particulate pollutants (Bombay, Bangkok) people have shorter T_{1/2} times as compared to cities like Sendai and Singapore where atmospheric pollution is low.²²

Thyroid cancer lung metastases

Lung metastases from differentiated cancer are not uncommon and are readily treated with radioiodine and thyroxine. The radiation dose delivered to the lung may be quite high, and results in radiation pneumonitis and fibrosis.²³ The late effects from repeated therapeutic doses of radioiodine could damage normal pulmonary epithelium.²⁴ A recent study²⁵ has shown no significant alteration in the T_{1/2} in 35 patients who had received large cumulative radioiodine dose for lung metastases from thyroid cancer. Our study supports this conclusion, and though pneumonitis and pulmonary fibrosis may occur, there is no permanent damage to alveolar-capillary membrane as measured by the T_{1/2} clearance study. Only in two patients with diffuse lung involvement were there low

$T_{1/2}$ values, but repeat long-term studies have to be done in these 2 patients to note development of radiation induced pulmonary epithelial damage. Other studies have shown interestingly that clearance is accelerated not only in radiation pneumonitic lesions, but also in the contralateral otherwise normal lung.²⁶

In summary the radioaerosols, including technetium-99m DTPA aerosol, can produce inhalation images of the lung and are usefully sensitive, though not specific, in studying pulmonary epithelial permeability in various types of lung diseases.

REFERENCES

- Gorin AB, Stewart PA. Differential permeability of endothelial and epithelial barriers to albumin flux. *J Appl Physiol* 48: 1315–1324, 1979.
- Bernard GR, Artigas A, Brigham KL, et al. The American-European Consensus conference on ARDS: definitions, mechanisms, relevant outcomes, and clinical trial coordination. *Am J Respir Crit Care Med* 149: 818–824, 1994.
- Schuster DP. Measuring pulmonary vascular permeability. *J Nucl Med* 36: 1442–1444, 1995.
- Touya JJ, Rahimian J, Corbus HF, et al. The lung as a metabolic organ. *Sem Nucl Med* 16 (4): 296–305, 1986.
- Drake RE, Laine GA. Pulmonary microvascular permeability to fluid and macromolecules. *J Appl Physiol* 64: 487–501, 1988.
- Pigorini F, Maini CC, Pau T, Giousue S. The influence of age on the pulmonary clearance of Tc-99m-DTPA radioaerosol. *Nucl Med Commun* 9: 965–971, 1988.
- Jones JG, Lawler P, Crawley JCW, Minty BD, Hinlands G, Veall N. Increased alveolar epithelial permeability in cigarette smokers. *Lancet* 1: 66–68, 1980.
- Kennedy SM, Elwood RK, Wiggs BJR, Pare PD, Hogg. Increased airway mucosal permeability of smokers. *Am Rev Respir Dis* 129: 143–148, 1984.
- Minty BD, Jordan C, Jones JG. Rapid improvement in abnormal pulmonary epithelial permeability after stopping cigarettes. *Br Med J* 282: 1183–1185, 1981.
- Tan WC, Lee ST, Lee CN, Wong S. The role of fiberoptic bronchoscopy in the management of respiratory burns. *Ann Acad Med Singapore* 14: 434, 1985.
- Lee MJ, O'Connell DJ. The plain chest radiograph after acute smoke inhalation. *Clinical Radiology* 39: 33–36, 1988.
- Marks JD, Luce JM, Lazar NM, et al. Effect of increases in lung volume on clearance of aerosolised solute from human lungs. *J Appl Physiol* 59: 1242–1245, 1985.
- Rinderknecht J, Shapiro L, Krauthammer M, et al. Accelerated clearance of small solutes from the lungs in interstitial lung disease. *Am Rev Respir Div* 121: 105–109, 1980.
- Mason GR, Uszler IM, Effros RM. Differentiation between hemodynamic and non-hemodynamic pulmonary oedema by a scanning procedure (Abstract). *Am Rev Respir Dis* 123: 238, 1981.
- Rosso J, Guillon JM, Denis M, Akoun G, et al. Technetium-99m DTPA Aerosol and Gallium-67 scanning in pulmonary complication of human immunodeficiency virus infection. *J Nucl Med* 33: 81–87, 1992.
- Huchon GJ, Montgomery AB, Lipavsky A, Hoeffel JM, Murray JP. Respiratory clearance of aerosolised solutes of varying molecular weight. *J Nucl Med* 28: 894, 1987.
- Hendron DN, Barrow RE, Linares HA, et al. Inhalation injury in burned patients: effects and treatment. *Burns* 14 (5): 349–356, 1988.
- Sundram FX, Lee ST. Tc-99m DTPA aerosol studies of the lung in inhalation injuries in burns patients. In Proceedings of International Symposium on Application of Dynamic Functional studies in Nuclear Medicine in Developing Countries, Vienna 1989 IAEA-SM-304/31, Vienna, International Atomic Energy Agency, pp. 319–332, 1989.
- Sundram FX, Lee ST. Radionuclide lung scanning in the management of respiratory burns. *Ann Acad Med Singapore* 21 (5): 630–634, 1992.
- Sundram FX. Clinical application of radioaerosol studies—pulmonary embolism, glue-sniffers, CODP and inhalation burns. In Radioaerosol Imaging of the Lung, Bahk YW, Isawa T (eds.), Korea, Benedict Press, pp. 136–148, 1994.
- Bahk YW, Chung SK. Radioaerosol lung scanning in COPD and related disorders. In Radioaerosol Imaging of the Lung, Bahk YW, Isawa T (eds.), Korea, Benedict Press, pp. 88–135, 1994.
- Nair G, et al. Urban Air pollution and altered lung function—an East, South and South-East Asian regional coordinated study. *N Eng J Med* 1995 (in press).
- Rall JE, Alpers JB, Lewallen GG, et al. Radiation pneumonitis and fibrosis: a complication of radioiodine treatment of pulmonary metastases from cancer of the thyroid. *J Clin Endocrinol Metab* 17: 1263–1276, 1957.
- Frazell EL, Foota FW. Papillary cancer of the thyroid. A review of 25 years of experience. *Cancer* 53: 982–992, 1984.
- Samuel AM, Unnikrishnan TP, Baghel NS, Rajashekharrao B. Effect of radioiodine therapy on pulmonary alveolar-capillary membrane integrity. *J Nucl Med* 36: 783–787, 1995.
- Anazawa Y, Isawa T, Teshima T, Miki M, Motomiya M. Changes in pulmonary epithelial permeability due to thoracic irradiation. *J Jpn Soc Chest Dis* 30: 862–867, 1992.