



Case report

Mucinous cystadenocarcinoma of pancreas mimicking gastrointestinal stromal tumor of stomach: Case report

Arkadeep Dhali^a, Sukanta Ray^{a,*}, Sujan Khamrui^a, Gopal Krishna Dhali^b^a Department of GI Surgery, IPGME&R, School of Digestive & Liver Diseases, Kolkata, India^b Department of Gastroenterology, IPGME&R, School of Digestive & Liver Diseases, Kolkata, India

ARTICLE INFO

Keywords:

Upper gastrointestinal hemorrhage
Mucinous cystadenocarcinoma
Cystic neoplasm
Pancreas
Gastrointestinal stromal tumor

ABSTRACT

Introduction: Pancreatic mucinous cystadenocarcinoma is a rare neoplasm of pancreas which rarely presents as upper gastrointestinal bleed.

Case report: A 45-year-old woman presented with history of repeated episodes of melena and abdominal pain. Upper gastrointestinal endoscopy revealed a growth in the body of the stomach likely to be a gastrointestinal stromal tumor (GIST). Endoscopic biopsy was inconclusive for GIST or malignancy. Computed tomography scan of the abdomen showed a well-defined multiloculated cystic lesion (11.8 × 11.1 × 6.4 cm) in the body and tail of the pancreas with involvement of the stomach. Preoperative diagnosis was a cystic neoplasm of the pancreas with tumor ingrowth into the stomach. The patient underwent en bloc resection of the stomach with distal pancreatectomy and splenectomy. Histopathological examination revealed low grade mucinous cystadenocarcinoma of the pancreas.

Discussion: Upper gastrointestinal bleed as a manifestation of cystic neoplasms of pancreas are rarely reported. Although some cases of hemoperitoneum were reported due to rupture of tumor; luminal gastrointestinal bleed is even rarer. It may be due to involvement of porto-mesenteric axis with portal hypertension, direct invasion of the gastric wall with ulceration of the gastric mucosa, communication between the tumor and the main pancreatic duct, and from the infiltrating tumor.

Conclusion: Our case highlights the fact that mucinous cystadenocarcinoma of pancreas rarely can present with upper gastrointestinal hemorrhage. Moreover, if it is large enough to compress or invade the stomach, endoscopy may misdiagnose it as GIST.

1. Introduction

Pancreatic cystic neoplasms are rare, accounting for 1% of all pancreatic tumors, seen mostly in women aged between 40 and 60 years [1]. Compagno and Oertel classified this subgroup of non-ductal neoplasms into serum producing and mucin producing neoplasms [2]. Herein, we present a novel case of mucinous cystadenocarcinoma of pancreas manifesting with upper gastrointestinal bleed due to tumor infiltration into the stomach wall. During initial investigations, it was misdiagnosed as gastrointestinal stromal tumor of stomach, hence creating a diagnostic dilemma. The case report was realized according to international Surgical Case Report (SCARE) guidelines [3].

2. Case report

A 45-year-old Indian woman presented to our outpatient clinic with a history of repeated episodes of melena and abdominal pain for three months. She was initially admitted in a local hospital. Anemia was confirmed (Hemoglobin- 7.4 g/dL, normal range- 12.1 to 15.1 g/dL). She received two units of packed cell transfusion and her hemoglobin was raised to 10.2 g/dL. She was evaluated with upper gastrointestinal (UGI) endoscopy which revealed a growth in the body of the stomach likely to be a gastrointestinal stromal tumor (GIST). Endoscopic biopsy was inconclusive for GIST or malignancy. She came to our institution for definitive management. In the current presentation, examination revealed significant pallor and a lump in the epigastric region. Her hemoglobin was 7.2 g/dL. Other laboratory parameters including serum CA 19.9 were within normal limits. Computed tomography scan of the

* Corresponding author.

E-mail address: drsukantaray@yahoo.co.in (S. Ray).<https://doi.org/10.1016/j.ijscr.2021.106240>

Received 10 July 2021; Received in revised form 23 July 2021; Accepted 24 July 2021

Available online 26 July 2021

2210-2612/© 2021 The Authors. Published by Elsevier Ltd on behalf of IJS Publishing Group Ltd. This is an open access article under the CC BY-NC-ND license

[\(http://creativecommons.org/licenses/by-nc-nd/4.0/\)](http://creativecommons.org/licenses/by-nc-nd/4.0/).

abdomen (Fig. 1) showed a well-defined multiloculated cystic lesion (11.8 × 11.1 × 6.4 cm) in the body and tail of the pancreas with involvement of the stomach. Preoperative diagnosis was a cystic neoplasm of the pancreas with tumor ingrowth into the stomach. After optimization of general condition including blood transfusion, the patient underwent en bloc resection of the stomach with distal pancreatectomy and splenectomy. Intraoperative finding was a large cystic lesion (13 × 12 × 7 cm) in the body and tail of the pancreas infiltrating into the mid-body of the stomach. The lesion was extending up to the hilum of the spleen. There were features of left sided portal hypertension. There was no significant peripancreatic lymphadenopathy. Operative time was 194 min and blood loss was 200 ml. Histopathological examination (Fig. 2) revealed ovarian type of stroma. Glands were lined by columnar cell with mucin in cytoplasm. Nuclear stratification and hyperchromasia were present. The diagnosis was a low grade mucinous cystadenocarcinoma of the pancreas. There was no lymphovascular or perineural invasion. All the resected margins were free of tumor. The patient had an uneventful recovery and was discharged on 10th post-operative day. The patient received gemcitabine-based adjuvant chemotherapy and was found to be well at 18-month follow-up.

3. Discussion

Pancreatic mucinous cystic neoplasms are rare tumors, accounting for only 2–5% of primary exocrine pancreatic tumors [4]. These are of several types which are mucinous cystadenoma, borderline mucinous cystic neoplasm with moderate dysplasia, and cystadenocarcinoma, noninvasive or invasive. Diagnosis is based on the presence of ovarian type fibrous stroma and no communication with the pancreatic ductal system. These tumors occur predominantly in women between 5th and 6th decades. Malignant lesions usually present about 10 years later than

cystadenoma. Pancreatic mucinous cystadenocarcinoma (MCAC) is extremely rare and majority of them arises from preexisting mucinous cystadenoma. MCAC is generally low grade in nature, localized to the body or tail of the pancreas [5].

Patients with cystic neoplasm of pancreas are mostly asymptomatic or manifests with mild symptoms at advanced stages. Common symptoms include vague abdominal discomfort, pain, anorexia, nausea, vomiting [6]. Upper gastrointestinal (UGI) bleed as a manifestation of them are rarely reported. To the best of our knowledge, fewer than five cases have been reported in English literature [4,7]. Although some cases of hemoperitoneum were reported due to rupture of tumor [8–10]; luminal gastrointestinal bleed is even rarer. UGI bleeding may be due to involvement of porto-mesenteric axis with portal hypertension, direct invasion of the gastric wall with ulceration of the gastric mucosa, communication between the tumor and the main pancreatic duct, and from the infiltrating tumor [4,11]. Grieshop et al. [12] described a case of MCAC-related UGI hemorrhage where the patient underwent cystogastrostomy for a cystic tumor misdiagnosed as an inflammatory pseudocyst. In our case, the presentation and endoscopic appearance were more in favour of a GIST. The diagnosis of cystic neoplasm was made only after CT scan of the abdomen. Endoscopic biopsy was inconclusive in our case. We initially thought that GIST could be missed in endoscopic biopsy due to the submucosal origin of the tumor [13]. But, actually the diagnosis was missed in endoscopic biopsy due to inadequate sampling.

Once the diagnosis of cystic neoplasm of the pancreas is suspected, further evaluation should be made with transabdominal ultrasonography and multislice computed tomography (CT) scanning. Endoscopic ultrasound guided fine needle aspiration, enables cytological sampling and assessment of tumor markers such as carcinoembryonic antigen (CEA) in cyst fluid.

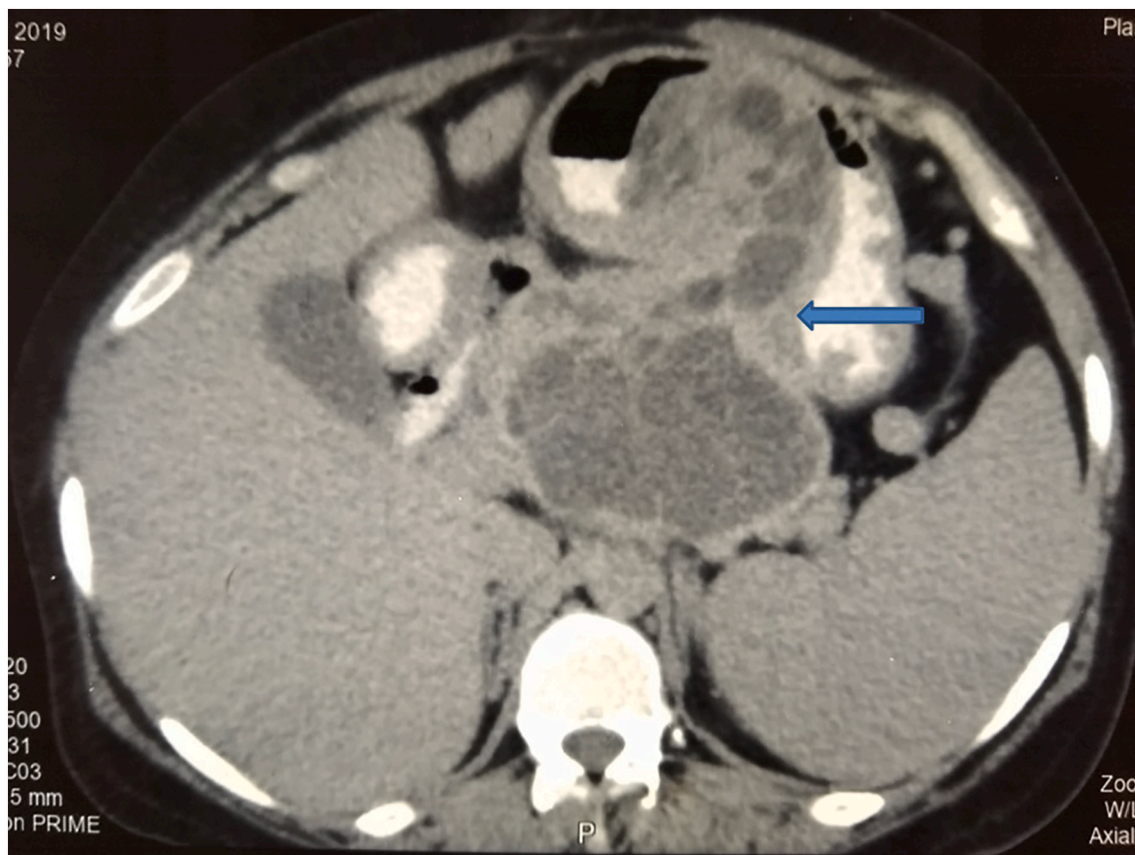


Fig. 1. Computed tomography scan of the abdomen showing a well defined multiloculated cystic lesion (11.8x 11.1x6.4 cm) in the body and tail of the pancreas with involvement of the stomach.

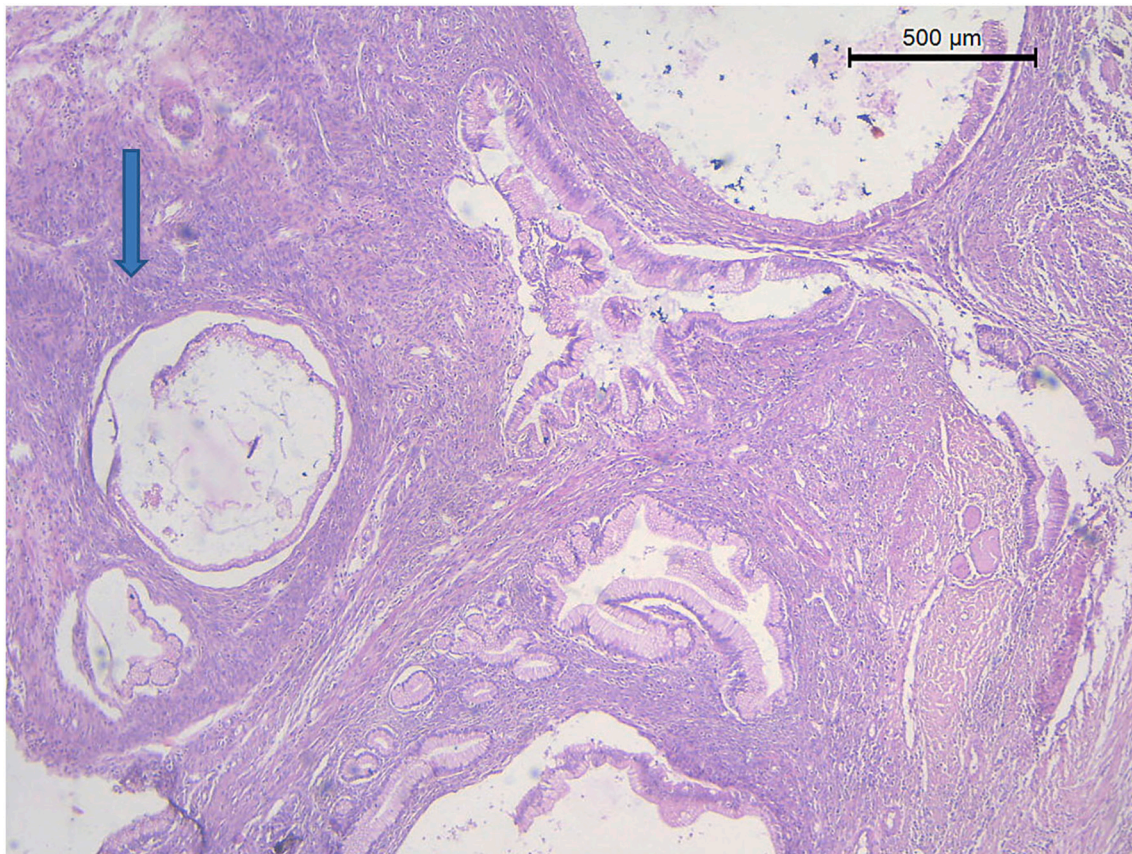


Fig. 2. H&E image (100X) showing ovarian type of stroma (blue arrow). Glands are lined by columnar cell with mucin in cytoplasm. Nuclear stratification and hyperchromasia present suggestive of low grade mucinous cystadenocarcinoma of the pancreas.

Although there are existing case reports on GISTs getting misdiagnosed as pancreatic cystic neoplasms [14] the converse is not yet reported. More confusion adds up when a GIST on cross-sectional imaging shows a cystic degeneration or when an extra-gastrointestinal stromal tumor arises from pancreas. In either way, a pathological histochemical examination is required to achieve a definitive diagnosis. Presence of ovarian stroma on histology is essential for diagnosis of MCAC. This also suggests a possible tumorigenic pathway for both ovarian and pancreatic MCAC.

Complete excision is considered as the treatment of choice. Overall prognosis of MCAC is significantly better than pancreatic adenocarcinoma. The median survival observed was found to be ranging from 4 to 111 months in patients with distant and localized disease respectively. Also, the 1-year disease specific survival for patients with localized disease was 90.1% compared to 18.7% in distant tumor spread cases, which reflects the inefficacy of current treatment modalities in managing advanced stages of the disease [5]. Ages over 50, incomplete surgical excision, evidence of capsular invasion, and nuclear immunohistochemical positivity for p53 are adverse features [4].

4. Conclusion

Our case highlights the fact that mucinous cystadenocarcinoma of pancreas; even though avascular in nature can present with upper gastrointestinal hemorrhage. Moreover, if it is large enough to compress or invade the stomach, endoscopy may misdiagnose it as gastrointestinal stromal tumor. Hence clinicians should be aware of this atypical manifestation and correlate with cross-sectional imaging accordingly.

Financial support

Nil.

Consent

Written informed consent was obtained from the patient for publication of this case report and accompanying images. A copy of the written consent is available for review by the Editor-in-Chief of this journal on request.

Author contribution

Arkadeep Dhali: Conception, design of the study, acquisition of the data, drafting the manuscript, final approval of the version to be submitted.

Sukanta Ray: Conception, design of the study, acquisition of the data, drafting the manuscript, final approval of the version to be submitted.

Sujan Khamrui: Acquisition of the data, final approval of the version to be submitted.

Gopal Krishna Dhali: Acquisition of the data, final approval of the version to be submitted.

Registration of research studies

Not applicable.

Ethical committee approval

Not required in our institution to publish anonymous case reports.

Guarantor

Dr. Sukanta Ray acts as guarantor for the report and accept responsibility for the work.

Provenance and peer review

Not commissioned, externally peer-reviewed.

Declaration of competing interest

None declared.

References

- [1] R. Inceoglu, H. Dosluoglu, N. Okboy, S. Kullu, Mucinous cystadenocarcinoma of the pancreas: an uncommon presentation with anaemia and upper gastrointestinal bleeding, *J. R. Soc. Med.* 84 (3) (Mar 1991) 171–172. PMID: 2013903; PMCID: PMC1293144.
- [2] J. Compagno, J.E. Oertel, Microcystic adenomas of the pancreas (glycogen-rich cystadenomas): a clinicopathologic study of 34 cases, *Am. J. Clin. Pathol.* 69 (3) (1978) 289–298.
- [3] for the SCARE Group, R.A. Agha, T. Franchi, C. Sohrabi, G. Mathew, The SCARE 2020 guideline: updating consensus Surgical CAse REport (SCARE) guidelines, *Int. J. Surg.* 84 (2020) 226–230.
- [4] T.H. Brown, V.S. Menon, D.G. Richards, A.P. Griffiths, Gastrointestinal bleeding in a pregnant woman: mucinous cystic neoplasm of pancreas mimicking gastrointestinal stromal tumor of stomach, *J. Hepato-Biliary-Pancreat. Surg.* 16 (5) (2009) 681–683, <https://doi.org/10.1007/s00534-009-0159-6>.
- [5] I.P. Doulamis, K.S. Mylonas, C.E. Kalfountzos, D. Mou, H. Haj-Ibrahim, D. Nasioudis, Pancreatic mucinous cystadenocarcinoma: epidemiology and outcomes, *Int. J. Surg.* 35 (2016 Nov) 76–82, <https://doi.org/10.1016/j.ijso.2016.09.017>.
- [6] B. Jais, V. Rebours, G. Malleo, R. Salvia, M. Fontana, L. Maggino, et al., Serouscystic neoplasm of the pancreas: a multinational study of 2622 patients under the auspices of the International Association of Pancreatology and European pancreatic Club (European study group on cystic tumors of the pancreas), *Gut* 65 (2) (2016) 305–312.
- [7] J. Compagno, J.E. Oertel, Mucinous cystic neoplasms of the pancreas with overt and latent malignancy (cystadenoma and cystadenocarcinoma) a clinicopathologic study of 41 cases, *Am. J. Clin. Pathol.* 69 (1978) 573–580.
- [8] C.M. Pyke, J.A. van Heerden, T.V. Colby, M.G. Sarr, A.L. Weaver, The spectrum of serous cystadenoma of the pancreas. clinical, pathologic, and surgical aspects, *Ann. Surg.* 215 (2) (1992) 132–139.
- [9] T. Sakaguchi, S. Nakamura, S. Suzuki, H. Konno, K. Fujita, K. Suzuki, et al., Intracystic hemorrhage of pancreatic serous cystadenoma after renal transplantation: report of a case, *Surg. Today* 30 (7) (2000) 667–669.
- [10] H. Ashkzaran, K. Coenegrachts, L. Steyaert, M. Vandelanotte, I. van den Berghe, K. Verstraete, et al., An unusual presentation of pancreatic serouscystadenoma with acute hemorrhage, *JBR-BTR.* 90 (1) (2007) 44–46.
- [11] A. Dhali, E. Pasangha, C. D'Souza, (June 17, et al., Pseudopapillary tumor of the pancreas: a rare cause of extrahepatic portal hypertension, *Cureus* 13 (6) (2021), e15707, <https://doi.org/10.7759/cureus.15707>.
- [12] N.A. Grieshop, E.A. Wiebke, S.S. Kratzer, J.A. Madura, Cystic neoplasms of the pancreas, *Am. Surg.* 60 (1994) 509–515.
- [13] A. Dhali, S. Ray, G.K. Dhali, R. Ghosh, A. Sarkar, Refractory hypoglycaemia in a localised gastrointestinal stromal tumour: case report, *Int. J. Surg. Case Rep.* 83 (May 26 2021), 106023, <https://doi.org/10.1016/j.ijscr.2021.106023>. Epub ahead of print. PMID: 34090190; PMCID: PMC818839.
- [14] V. Shivakumar, V. Rajesh, G. Mathew, et al., Gastrointestinal stromal tumor mimicking a pancreatic cystic lesion: a case report, *JOP. J Pancreas (Online)* 20 (3) (2019 May 30) 98–100.