



# Comparison of the Clinical Outcomes between Angiojet Pharmacomechanical Thrombectomy and Hybrid Surgical Thrombectomy for Thrombotic Occlusion of Hemodialysis Access

Ho Yeong Lee, Cheol Seung Kim, Kyu Dam Han, and Mi Jin Kim

Division of Vascular Surgery, Department of Surgery, Presbyterian Medical Center, Jeonju, Korea

**Purpose:** This retrospective study aimed to compare the clinical outcomes between hybrid surgical thrombectomy (ST) and AngioJet pharmacomechanical thrombectomy (PMT) for thrombotic occlusion of arteriovenous graft.

**Materials and Methods:** This study enrolled patients who underwent either hybrid ST or AngioJet PMT in Presbyterian Medical Center from July 2018 to December 2018. We primarily compared the technical and clinical success rates between the two groups immediately after the procedures. Subsequently, the postprocedure clinical outcomes, including the primary and secondary patency rates and complications, were also compared.

**Results:** The hybrid ST group had a significantly higher bleeding amount than the AngioJet PMT group ( $P=0.02$ ). The technical and clinical success rates were 96.7% and 93.3% in the AngioJet PMT group and 100% and 100% in the hybrid ST group, respectively. There was no significant difference in complications between the groups. The primary and secondary patencies at 12 months were not statistically different between the groups.

**Conclusion:** Comparable clinical outcomes were observed between the AngioJet PMT and hybrid ST groups, highlighting an equivalent efficacy of these two methods. Although the cost is more expensive, AngioJet PMT lowered the bleeding amount. Therefore, it can be considered in selected patients who are at risk of bleeding or reluctant to surgery.

**Key Words:** AngioJet thrombectomy, Hybrid surgical thrombectomy, Thrombotic occlusion, Arteriovenous access, Chronic renal insufficiency

Received July 31, 2020

Revised October 19, 2020

Accepted November 19, 2020

Published online December 17, 2020

**Corresponding author:** Mi Jin Kim

Division of Vascular Surgery, Department of Surgery, Presbyterian Medical Center, 365 Seowon-ro, Wansan-gu, Jeonju 54987, Korea

Tel: 82-63-230-1408

Fax: 82-63-230-1409

E-mail: raw93@paran.com

<https://orcid.org/0000-0002-4257-5086>

Copyright © 2020 The Korean Society for Vascular Surgery

This is an Open Access article distributed under the terms of the Creative Commons Attribution Non-Commercial License (<http://creativecommons.org/licenses/by-nc/4.0>) which permits unrestricted non-commercial use, distribution, and reproduction in any medium, provided the original work is properly cited.

Vasc Specialist Int 2020;36(4):241-247 • <https://doi.org/10.5758/vsi.200052>

## INTRODUCTION

An arteriovenous (AV) access is a lifeline for patients with chronic kidney disease. It is essential to maintain hemodialysis at least once a week to as many as three times a week; thus, it is important to maintain the functionality of the AV access. However, an AV access is associated with

various complications, including infection, hematoma, central vein stenosis, and thrombotic occlusion of the access. Thrombotic occlusion of the AV access is most commonly encountered and is the most common cause of dialysis failure. The leading cause of thrombotic occlusion is venous outflow stenosis, but various other causes such as inflow stenosis, puncture site stenosis, hypercoagulability, hypo-

tension, and over-compression have been reported [1,2].

Despite the varied causes, the treatment strategy for thrombotic occlusion is simple: removing the thrombus and restoring adequate flow for hemodialysis. To date, the treatment of choice is conventional surgical thrombectomy (ST). Recently, however, a variety of treatments have been reported, including ST and endovascular treatments, such as aspiration thrombectomy and pharmacomechanical thrombectomy (PMT) [3]. The PMT apparatus called AngioJet (Boston Scientific Corp., Marlborough, MA, USA) was approved in July 2018 in South Korea, and our clinic started using this device soon after its introduction. Thus, this study aimed to compare the clinical outcomes between hybrid ST and AngioJet PMT for AV graft (AVG) thrombosis.

## MATERIALS AND METHODS

### 1) Patients and methods

We performed a retrospective chart review of patients who visited our institution from July 2018 to December 2018. The patients who were diagnosed with thrombotic occlusion of the AVG for hemodialysis and treated by PMT or hybrid ST were included in this study. The procedure was selected by surgeons' preference and final approval by the patients. Patients with autogenous AV fistula were excluded in the study. Patients receiving other treatments such as thrombectomy with AV access revision or jump graft were excluded. Patients with early access thrombosis (<30 days after the initial access creation for safe cannulation [4]) or those with other complications, such as large aneurysms (>2 cm), overlying ulceration in the skin, and infection, were also excluded. All surgeries were performed by two experienced vascular surgeons.

Demographic data, cardiovascular risk factors, location, type, and age at the time of AV access were recorded for each patient. Information regarding surgical intervention and access outcomes, such as complications, total bleeding amount, operation time, and functional patency, was also recorded.

In both the AngioJet PMT and hybrid ST groups, the procedures were performed under local anesthesia, and oral antibiotics (second-generation cephalosporin) and ciprofloxacin were prescribed for 3 days after the procedure [5] unless contraindicated. The hybrid ST and AngioJet PMT techniques were performed by angiography using C-arm or angiography systems.

### 2) Procedure technique

In hybrid ST, a transverse incision was made, and the

hemodialysis access was exposed and a transverse incision was made on the AVG. A 4-Fr over-the-wire Fogarty balloon catheter (Edwards Lifesciences Corp., Irvine, CA, USA) with a 0.035-inch guidewire was advanced through the AV access into the native venous outflow as centrally as possible. The Fogarty balloon catheter was inflated and withdrawn from the incision site, and multiple passes of the Fogarty catheter were performed to remove the thrombus. Next, venography was performed to verify the any stenosis or residual thrombus. If a stenotic lesion was present, additional procedures, such as balloon angioplasty, stenting, or surgical revision, were performed simultaneously. Similarly, thrombectomy was performed proximally on the arterial anastomotic site. Finally, a fistulogram was obtained to confirm the completion of thrombectomy, and the transverse AV access incision site was closed using a 6-0 Ethilon Nylon Suture (Ethicon Inc., Johnson & Johnson, Somerville, NJ, USA)

In the AngioJet PMT procedure, 6-Fr sheaths were first inserted in both the arterial and venous sides of the AV access, followed by a 0.035-inch guidewire passage. After inserting the AngioJet catheter to the venous side, urokinase (Greencross, Yongin, Korea) was injected into the AV access using a power pulse mode (almost 1 cc/sec). The urokinase was applied in the same manner on the arterial side. After performing pharmacologic thrombolysis for approximately 20 to 30 minutes, mechanical thrombectomy was performed using the AngioJet catheter from the venous side. Next, the fistulogram was checked for the presence of any stenotic lesions. The residual thrombi were treated by an additional procedure of administering 5-U/mL intravenous heparin and 1,000-U/mL power pulse spray urokinase. Mechanical thrombectomy was performed at the most for 240 seconds, considering the possibility of hemolysis in the patient's blood.

### 3) Definitions

Technical success was defined as residual stenosis <30% in the completion fistulogram. Clinical success was defined as the hemodialysis could be completed at least in one session after the procedure. Post-interventional primary patency was defined as the patency during the time interval after the initial thrombectomy procedure until access rethrombosis. Post-interventional secondary patency was defined as the patency during the time interval after the initial thrombectomy procedure until the access was surgically declotted or abandoned.

The complications were classified into major and minor. A major complication was a severe complication affecting the lifespan of the AV access (vessel rupture, access infection, severe bleeding requiring transfusion, hematoma, and

pseudoaneurysm requiring surgery). In contrast, a minor complication was defined as a complication that did not affect the lifespan of the AV access.

4) Statistical analysis

Statistical analyses were performed using IBM SPSS Statistics ver. 20.0 software for Windows (IBM Co., Armonk, NY, USA). The demographic information on patients and AV access was analyzed using the Fisher's exact or  $\chi^2$  test. P-values < 0.05 were considered statistically significant. The outcomes including clinical and technical success rates were determined by frequency. Moreover, a Kaplan–Meier life table analysis was used to calculate the patency curves and survival after the index procedures.

5) Ethical approval

The study was approved by the appropriate Ethical Review Board Committee of Presbyterian Medical Center (IRB no. 2020-02-006) and conducted in accordance with the 2013 Declaration of Helsinki.

**RESULTS**

1) Characteristics of patients and AV access

The data from 62 patients were analyzed in this study, including 29 AngioJet PMT and 33 hybrid ST. There were

no statistically significant differences in the age, sex, diabetes, hypertension, and hyperlipidemia between the two groups. However, the AngioJet PMT group had a significantly higher rate of current smokers than the hybrid ST group. The average age of an AV access in the AngioJet PMT group was 23.8±20.4 months, and that in the hybrid ST group was 34.0±27.5 months, respectively, with no significant difference (P=0.300). In addition, there was no difference in the type of access between the two groups (P=0.143), and the upper arm AVG was the most common graft used in both groups. AVG was mostly created in the non-dominant arm (89.7% in the AngioJet PMT and 97.0% in hybrid ST groups, P=0.259; Table 1).

2) Procedure results

The total procedure time in the AngioJet PMT group was 56.3±13.3 min, and that in the hybrid ST group was 47.0±12.9 min (P=0.017). All patients with stenotic lesions underwent an additional percutaneous transluminal angioplasty (PTA). Regarding intraoperative bleeding, the hybrid ST group had a significantly higher bleeding amount than the AngioJet PMT group (72.5±30.7 vs. 51.7±17.6 mL, P=0.02; Table 2). The technical and clinical success rates were 96.6% and 93.1% in the AngioJet PMT group and 100% and 100% in the hybrid ST group, respectively. There were no statistically significant differences in success rates between the two groups (Table 3).

3) Complications

The complications are presented in Table 3. No mortality was observed. One patient in the AngioJet PMT group developed a major complication of a large hematoma in the forearm area distal to the AVG (brachio-axillary, polytet-

**Table 1.** Characteristics of the study patients and AV access

Characteristic	Hybrid ST (n=33)	AngioJet PMT (n=29)	P-value
<b>Patient</b>			
Age (y)	70.24±12.06	69.28±10.17	0.550
Sex, female	19 (57.6)	18 (62.1)	0.461
<b>Risk factors</b>			
Diabetes mellitus	26 (78.8)	24 (82.8)	0.273
Hypertension	23 (69.7)	20 (69.0)	0.584
Dyslipidemia	13 (39.4)	7 (24.1)	0.156
Smoking	0 (0.0)	7 (24.1)	0.003
<b>AV access</b>			
Access age (mo)	34.0±27.5	23.8±20.4	0.300
Access in non-dominant arm	32 (97.0)	26 (89.7)	0.259
Type			0.143
Upper arm AVG	27 (81.8)	19 (65.5)	
Forearm loop AVG	6 (18.2)	10 (34.5)	

Values are presented as mean±standard deviation or number (%). ST, surgical thrombectomy; PMT, pharmacomechanical thrombectomy; AV, arteriovenous; AVG, AV graft.

**Table 2.** Procedure-related factors

Factor	Hybrid ST (n=33)	AngioJet PMT (n=29)	P-value
Urokinase dosage (unit)	NA	72,900	NA
Heparin dosage (unit)	NA	521.8	NA
Additional procedure	33	29	NA
<b>Procedure time</b>			
Total operation (min)	47.0±12.9	56.3±13.3	0.017
AngioJet working (s)	NA	146.5	NA
Thrombolysis (min)	NA	16.1	NA
Total bleeding amount (mL)	72.5±30.7	51.7±17.6	0.02

Values are presented as number only or mean±standard deviation. ST, surgical thrombectomy; PMT, pharmacomechanical thrombectomy; NA, not applicable.

rafluoroethylene) caused by a wire perforating the distal artery. The hematoma was initially treated with compression; however, re-thrombotic occlusion of the AV access resulted in failed hemodialysis. In addition, two patients in the AngioJet PMT group developed minor complications of nausea.

No patients in the hybrid ST group had any major complications, and only four patients had minor complications. Although these minor complications did not affect AV access, the venogram during the procedure showed short segmental tearing of the intimal hyperplasia in AVG (within 4-cm length). We were able to fix these lesions by balloon angioplasty without stenting.

**Table 3.** Procedure-related success rates and complications

Procedure-related results	Hybrid ST (n=33)	AngioJet PMT (n=29)	P-value
<b>Success rates</b>			
Technical success	33 (100.0)	28 (96.6)	0.468
Clinical success	33 (100.0)	27 (93.1)	0.215
<b>Complication</b>			
Major complication	0 (0.0)	1 (3.4) <sup>b</sup>	0.468
Minor complication	4 (12.1) <sup>a</sup>	2 (6.9) <sup>c</sup>	0.400

Values are presented as number (%).

ST, surgical thrombectomy; PMT, pharmacomechanical thrombectomy.

<sup>a</sup>Procedure-induced AV access dissection during the procedure.

<sup>b</sup>Muscle hematoma. <sup>c</sup>Nausea during the procedure.

#### 4) Procedure patency

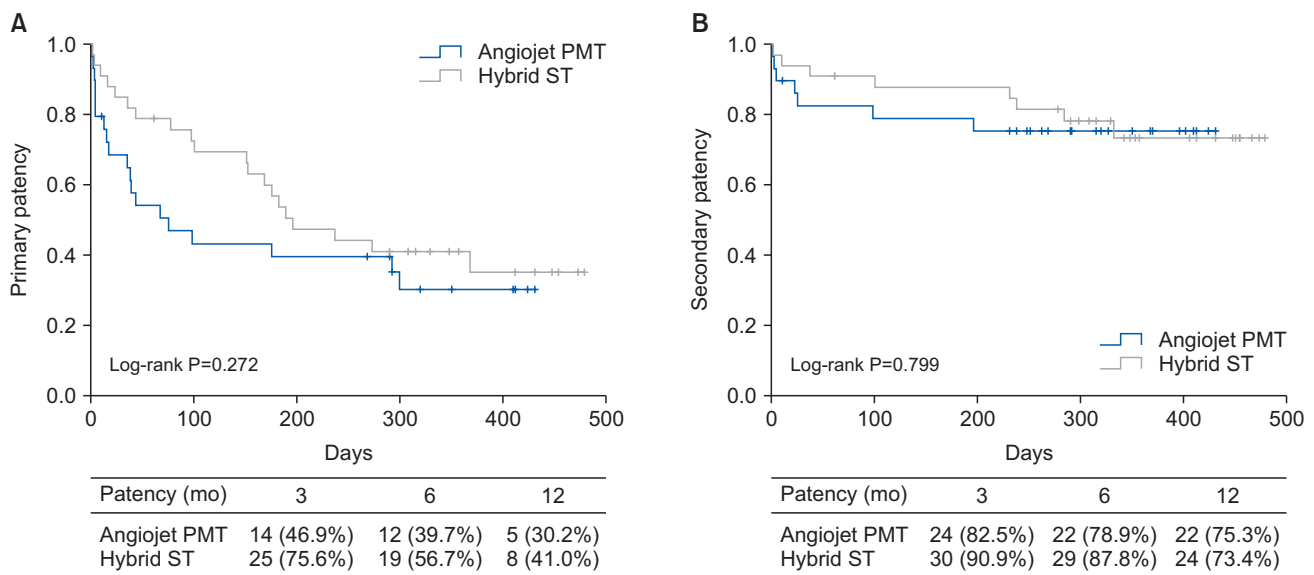
The primary patency rates at 3, 6, and 12 months were 46.9%, 39.7%, and 30.2% in the AngioJet PMT group and 75.6%, 56.7%, and 41.0% in the hybrid ST group, respectively (log-rank test, P=0.272). The secondary patency rates were 82.5%, 78.9%, and 75.3% in the AngioJet PMT group and 90.9%, 87.8%, and 73.4% in the hybrid ST group, respectively (log-rank test, P=0.799; Fig. 1).

## DISCUSSION

With the increase in the aging population, the number of patients with chronic kidney disease is also increasing as well as the need for renal replacement treatment. Given that the number of individuals receiving hemodialysis has been increasing, the interest in managing hemodialysis access has also grown.

The most common complications of the hemodialysis access are juxta-anastomotic stenosis and subsequent thrombosis (approximately 18%) [1]. Approximately 85% of the AV fistula complications may result from thrombosis caused by stenosis due to intimal hyperplasia, especially in the prosthetic grafts. These complications hinder patients from undergoing hemodialysis when needed and may result in hospitalization or temporary catheter insertion, which may be expensive. Thrombotic occlusion of the AV access accounts for 65% to 85% of cases of AV access being surgically declotted or abandoned [2,6].

Therefore, several studies have reported treatment



**Fig. 1.** Kaplan–Meier analysis for the (A) primary and (B) secondary patencies between the hybrid surgical thrombectomy (ST) and AngioJet pharmacomechanical thrombectomy (PMT) groups. Hybrid ST group showed better primary and secondary patencies at 12 months compared with the AngioJet PMT group, without statistically significance.

methods for thrombotic occlusion of an AV access. The treatment methods for thrombotic occlusion of the AV access can be categorized into two types: open ST or endovascular treatment. ST is a method that directly removes the thrombus by making an incision directly to the AV access and then passing the thrombectomy catheter through the incision. Although it is possible to reliably remove the thrombus, regardless of its characteristics, and manage the pathologic lesions surgically during the procedure, there are several associated disadvantages, such as large amounts of bleeding and direct damage to AV access. Other disadvantages of ST include difficulties in detecting additional stenoses during surgery and providing information about the complex vascular anatomy in patients [5].

Endovascular treatment is an attractive alternative, which seems to address the disadvantages of surgical treatment. Various methods such as percutaneous AV access declotting, lyse-and-wait techniques, thromboaspiration, pulse spray-aided pharmacomechanical thrombolysis, and mechanical thrombectomy with Arrow-Treterola device (Teleflex Inc., Wayne, PA, USA) have been reported [7]. The percutaneous AV access declotting method has the advantage of minimal bleeding and the absence of incisions compared with surgery. It is also an enormous advantage that the solution can be resolved simultaneously during the treatment of strictures identified during the procedure. However, there are some drawbacks to endovascular treatment. First, it is technically difficult to perform and has a learning curve effect. Second, the complex anatomy may be technically difficult, which may lead to decreased patency compared with surgical treatment [8].

Various results have been reported for the patency of these two treatment methods. Pharmacologic thrombolysis and mechanical thromboaspiration are the most widely known endovascular treatments, with a reported success rate of >78%, and 1-year patency of 9% to 70%. The initial success rate of surgical treatment was reported to be 70%–94%, and the 1-year patency rate was 51% to 84%. In addition, the technical success rates reported in some studies were 73% to 96% and 66% to 100% for endovascular and surgical treatments, respectively [2,9].

Various studies comparing surgical and endovascular treatments have been published in the past [10–13]. Dougherty et al. [10] reported in 1999 that the endovascular treatment may extend the lifespan of the AV access similar to surgical treatment, but reoperation due to technical failure and the high cost of thrombolysis may pose problems. A systematic review by Chan et al. [11] compared the endovascular and surgical treatments of thrombotic occlusion of an AVG and concluded that the endovascular treatment was inferior to the open surgical treatment in terms of long-

term patency and technical failure rates. Similar to these studies, in our study, the short-term patency was higher in the surgical treatment than in the endovascular treatment, whereas the technical failure rates were higher in the endovascular treatment. However, there was no statistically significant difference in these parameters.

Surgical treatment remains the gold standard for treating thrombotic occlusion of an AV access [4]. However, most of the previous studies did not have standardized procedures, which contributed to the heterogeneity. Besides, as these studies employed different techniques, the comparison of the two treatments may have been limited because of the inconsistencies of each method [10,11].

A previous study in 1999 [14] utilized AngioJet for thrombotic occlusion of an AV access. When the surgical treatment was compared with AngioJet PMT, the technical success rates immediately after the procedure were 73.2% and 78.8% in the AngioJet and surgical treatment groups, respectively ( $P=0.41$ ). The primary patency rates at 1, 2, and 3 months were 32%, 21%, and 15% in the AngioJet PMT group and 41%, 32%, and 26% in the surgical treatment group, respectively. The differences in the results were not statistically significant. However, the surgical treatment group showed better results. Since then, AngioJet devices have undergone several developments and have been reported to be effective and safe for treating AV access complications [15].

In 2009, AngioJet PMT for thrombotic occlusion of the AV access showed an immediate primary patency rate of 91%. The primary patency rates at 1, 3, and 6 months were 71%, 60%, and 37%, respectively, which were found to be better than those in other reports [16]. In 2013, a prospective multicenter randomized trial for AngioJet (PEARL Registry) showed a success rate of 92% immediately after the procedure, with restenosis and rethrombotic occlusion rates of 18% and 29%, respectively, during the 3-month follow-up period. The study suggested that the AngioJet PMT devices could be used for treating thrombotic occlusion of an AV access [17].

In this study, the technical and clinical success rates were 96.6% and 93.1% in the AngioJet PMT group and 100% and 100% in the hybrid ST group, respectively. The primary patency rates at 3, 6, and 12 months were 46.9%, 39.7%, and 30.2% in the AngioJet PMT group and 75.6%, 56.7%, and 41.0% in the hybrid ST group, respectively. The secondary patency rates at 3, 6, and 12 months were 82.5%, 78.9%, and 75.3% in the AngioJet PMT group and 90.9%, 87.8%, and 73.4% in the hybrid ST group, respectively. Compared with other studies, the short-term outcomes within 3 months were slightly poorer in the AngioJet PMT group, but the patency after 6 months was similar in both

groups.

The outcomes of endovascular treatment are likely to be affected by the operator's skill, and the possibility of failure due to the complex anatomy is known as a disadvantage of the procedure. On the other hand, the difficulty in identifying stenoses during the surgical procedure and hence the treatment of the lesions is a key disadvantage of surgical treatment. However, recent advances in endovascular devices have overcome several of these disadvantages by standardizing the operator's skill through automation and quantification of instruments. Also, surgical procedures utilizing hybrid techniques that identify stenoses and treat the lesions during the surgical procedure using C-arm or hybrid angiography machines have overcome the disadvantages of surgical treatments, resulting in better outcomes [18]. In fact, our hospital is performing surgeries using these hybrid techniques to simultaneously fix stenotic lesions during the procedure, and if other methods, such as patch angioplasty or bypass surgery, are required, additional surgeries are also performed.

No previous studies have analyzed the costs of these treatment methods, operation time, and amount of bleeding during the procedure. This study showed that there was statistically significantly less bleeding during AngioJet PMT than during hybrid ST. Moreover, although the costs of all surgical procedures are very low in South Korea, AngioJet PMT costs twice as much as hybrid ST. As such, it may not be cost-effective compared with hybrid ST; however, because the amount of bleeding was significantly less, it can be useful for patients who are at risk of bleeding.

This study has several limitations. First, our study was a retrospective investigation with small number of patients. Second, a bias in case selection may exist. The patients who received AngioJet PMT constituted our initial cases; thus, the case selection procedure was carried out to exclude cases with severe aneurysmal changes or those with previous images showing that the AV access was too damaged. Surgeons may be more familiar with hybrid ST than with AngioJet PMT since it has been performed for several years, and AngioJet PMT has a learning curve effect. Thus, for the initial AngioJet PMT cases, there may have been

a problem with proficiency. In the future, a comparison between AngioJet PMT and conventional thrombectomy other than the endovascular treatments will be necessary with long-term follow-up.

## CONCLUSION

The clinical outcomes of hybrid ST and AngioJet PMT as treatment methods for thrombotic occlusion of the AV access did not differ significantly. However, hybrid ST was superior to AngioJet PMT in terms of the primary and secondary patency rates. The patients in the AngioJet PMT group experienced a lesser amount of blood loss. Therefore, hybrid ST may be considered the gold standard for treating thrombotic occlusion of an AV access. However, AngioJet can certainly be useful for selected patients who are afraid to undergo surgery or at risk of bleeding.

## CONFLICTS OF INTEREST

The authors have nothing to disclose.

## ORCID

Ho Yeong Lee

<https://orcid.org/0000-0003-0027-1196>

Cheol Seung Kim

<https://orcid.org/0000-0003-4983-5941>

Kyu Dam Han

<https://orcid.org/0000-0002-5331-763X>

Mi Jin Kim

<https://orcid.org/0000-0002-4257-5086>

## AUTHOR CONTRIBUTIONS

Concept and design: MJK, CSK. Analysis and interpretation: HYL, MJK. Data collection: HYL. Writing the article: HYL, MJK. Critical revision of the article: MJK, CSK, KDH. Final approval of the article: all authors. Statistical analysis: none. Obtained funding: none. Overall responsibility: MJK.

## REFERENCES

- 1) Johny S, Pawar B. Complications of arteriovenous fistula for haemodialysis access. *Int Surg J* 2018;5:439-444.
- 2) Wan Z, Xiang R, Wang H, Zhong Q, Tu B. Comparative efficacy and safety of local and peripheral venous thrombolytic therapy with urokinase for thrombosed hemodialysis arteriovenous fistulas. *Exp Ther Med* 2019;17:4279-4284.
- 3) Quencer KB, Friedman T. Dec clotting the thrombosed access. *Tech Vasc Interv Radiol* 2017;20:38-47.
- 4) Culp K, Flanigan M, Taylor L, Rothstein M. Vascular access thrombosis

- in new hemodialysis patients. *Am J Kidney Dis* 1995;26:341-346.
- 5) Ishii H, Kumada Y, Toriyama T, Aoyama T, Takahashi H, Yamada S, et al. Cilostazol improves long-term patency after percutaneous transluminal angioplasty in hemodialysis patients with peripheral artery disease. *Clin J Am Soc Nephrol* 2008;3:1034-1040.
  - 6) Smits JH, van der Linden J, Blankestijn PJ, Rabelink TJ. Coagulation and haemodialysis access thrombosis. *Nephrol Dial Transplant* 2000;15:1755-1760.
  - 7) Quencer KB, Oklu R. Hemodialysis access thrombosis. *Cardiovasc Diagn Ther* 2017;7(Suppl 3):S299-S308.
  - 8) Green LD, Lee DS, Kucey DS. A meta-analysis comparing surgical thrombectomy, mechanical thrombectomy, and pharmacomechanical thrombolysis for thrombosed dialysis grafts. *J Vasc Surg* 2002;36:939-945.
  - 9) Tordoir JH, Bode AS, Peppelenbosch N, van der Sande FM, de Haan MW. Surgical or endovascular repair of thrombosed dialysis vascular access: is there any evidence? *J Vasc Surg* 2009;50:953-956.
  - 10) Dougherty MJ, Calligaro KD, Schindler N, Raviola CA, Ntoso A. Endovascular versus surgical treatment for thrombosed hemodialysis grafts: a prospective, randomized study. *J Vasc Surg* 1999;30:1016-1023.
  - 11) Chan N, Wee I, Soong TK, Syn N, Choong AMTL. A systematic review and meta-analysis of surgical versus endovascular thrombectomy of thrombosed arteriovenous grafts in hemodialysis patients. *J Vasc Surg* 2019;69:1976-1988.e7.
  - 12) Kuhan G, Antoniou GA, Nikam M, Mitra S, Farquharson F, Brittenden J, et al. A meta-analysis of randomized trials comparing surgery versus endovascular therapy for thrombosed arteriovenous fistulas and grafts in hemodialysis. *Cardiovasc Intervent Radiol* 2013;36:699-705.
  - 13) Lee HS, Park PJ. Clinical outcome of percutaneous thrombectomy of dialysis access thrombosis by an interventional nephrologist. *Kidney Res Clin Pract* 2014;33:204-209.
  - 14) Vesely TM, Williams D, Weiss M, Hicks M, Stainken B, Matalon T, et al. Comparison of the angiojet rheolytic catheter to surgical thrombectomy for the treatment of thrombosed hemodialysis grafts. *Peripheral AngioJet Clinical Trial. J Vasc Interv Radiol* 1999;10:1195-1205.
  - 15) Chan PG, Goh GS. Safety and efficacy of the AngioJet device in the treatment of thrombosed arteriovenous fistula and grafts: a systematic review. *J Vasc Access* 2018;19:243-251.
  - 16) Littler P, Cullen N, Gould D, Bakran A, Powell S. AngioJet thrombectomy for occluded dialysis fistulae: outcome data. *Cardiovasc Intervent Radiol* 2009;32:265-270.
  - 17) Simoni E, Blitz L, Lookstein R. Outcomes of AngioJet® thrombectomy in hemodialysis vascular access grafts and fistulas: PEARL 1 Registry. *J Vasc Access* 2013;14:72-76.
  - 18) Hyun JH, Lee JH, Park SI. Hybrid surgery versus percutaneous mechanical thrombectomy for the thrombosed hemodialysis autogenous arteriovenous fistulas. *J Korean Surg Soc* 2011;81:43-49.