

[CASE REPORT]

Recurrent Drug-induced Liver Injury Caused by the Incidental Readministration of a Kampo Formula Containing *Scutellariae Radix*

Yutaka Shimada¹, Makoto Fujimoto¹, Tatsuya Nogami¹, Hidetoshi Watari¹, Hideyuki Kitahara¹, Hiroki Misawa¹, Yoshiyuki Kimbara¹ and Kei-ichiro Kita²

Abstract:

A 67-year-old woman experiencing coughing visited a clinic and was prescribed drugs, including *sho-saikoto* extract, for 4 days. She subsequently suffered from liver injury, but her condition improved after the discontinuation of all medications. Approximately 1 year later, she experienced fatigue, consulted another clinic, and received *saikokeishikankyoto* extract for 21 days. She subsequently suffered liver injury again. Both *shosaikoto* and *saikokeishikankyoto* contain *Scutellariae Radix*. This case is thought to be one of recurrent drug-induced liver injury caused by the incidental readministration of a Kampo formula containing *Scutellariae Radix*. An awareness of adverse drug events caused by Kampo formulas, especially those containing *Scutellariae Radix*, is essential.

Key words: drug-induced liver injury, adverse drug event, Kampo medicine, *shosaikoto*, *saikokeishikankyoto*, *Scutellariae Radix*

(Intern Med 57: 1733-1740, 2018)

(DOI: 10.2169/internalmedicine.0275-17)

Introduction

The safety dogma that Kampo medicines are composed of natural drugs with a moderate effect and few side effects may have been formed over a long history. Ethical Kampo extract formulations were first included in Japan's National Health Insurance Drug List in 1967, after which their number and usage increased. However, after a case of interstitial pneumonia induced by *shosaikoto* (SSK; Xiao Chai Hu Tang) was reported in 1989 (1), it was recognized that adverse events may be induced by Kampo medicines. Many of the Kampo formulas that have been reported to induce interstitial pneumonia contain *Scutellariae Radix* (roots of *Scutellaria baicalensis* Georgi; "ogon" in Japanese) as one of the constituent crude drugs (2-4). The causal relationship between *Scutellariae Radix* and interstitial pneumonia has not been completely elucidated, but the involvement of an allergic-immunological mechanism is suspected (5).

Similarly, many adverse events of liver injury induced by Kampo medicines have also been reported. According to an analysis of 1,676 cases of drug-induced liver injuries occurring between 1997 and 2006 conducted by the Japan Society of Hepatology, causal drugs were narrowed down to a single drug in 879 cases, and 7.1% of them were Kampo medicines (6). As with interstitial pneumonia, many Kampo formulas reported to induce liver injury contain *Scutellariae Radix* (7-22).

In the present report, we describe a case of recurrent drug-induced liver injury caused by the incidental readministration of a Kampo formula containing *Scutellariae Radix*.

Case Report

A 67-year-old woman with somatoform disorder and a history of cholecystectomy (due to cholecystolithiasis) and surgery for cervical disc herniation was suffering from headache, neck pain, numbness of the upper limbs, irritability,

¹Department of Japanese Oriental Medicine, Graduate School of Medicine and Pharmaceutical Sciences, University of Toyama, Japan and ²Department of General Medicine, Toyama University Hospital, University of Toyama, Japan

Received: September 25, 2017; Accepted: November 6, 2017; Advance Publication by J-STAGE: February 9, 2018

Correspondence to Dr. Yutaka Shimada, shimada@med.u-toyama.ac.jp

Table 1. Patient's Laboratory Data upon Admission to the Department of Japanese Oriental Medicine in Toyama University Hospital on Day X+2.

TP	6.8 g/dL	TG	101 mg/dL	WBC	93.1×10 ² /μL
Alb	4.3 g/dL	TC	257 mg/dL	Eos	1.1 %
AST	59 U/L	HDL-C	65 mg/dL	Bas	0.3 %
ALT	139 U/L	LDL-C	166 mg/dL	Neu	74.1 %
LD	209 U/L	BS	99 mg/dL	Mon	6.1 %
ALP	362 U/L	HbA1c	5.2 mg/dL	Lym	18.4 %
γGTP	134 U/L	Na	138 mEq/L	RBC	463×10 ⁴ /μL
ChE	373 U/L	K	4.2 mEq/L	Hb	14.7 g/dL
CK	86 U/L	Cl	102 mEq/L	Ht	41.7 %
AMY	62 U/L	Ca	9.4 mg/dL	Plt	24.6×10 ⁴ /μL
T-Bil	1.1 mg/dL	P	4.1 mg/dL		
D-Bil	0.3 mg/dL	CRP	1.23 mg/dL	Urinalysis	
UN	12 mg/dL			Protein (–)	Bilirubin (–)
Cr	0.6 mg/dL	HBsAg (–)		Glucose (–)	Urobilinogen (±)
UA	4.9 mg/dL	HCVAb (–)		Occult blood (–)	

TP: total protein, Alb: albumin, AST: aspartate aminotransferase, ALT: alanine aminotransferase, LD: lactate dehydrogenase, ALP: alkaline phosphatase, γGTP: gamma-glutamyl transpeptidase, ChE: cholinesterase, CK: creatine kinase, AMY: amylase, T-Bil: total bilirubin, D-Bil: direct bilirubin, UN: urea nitrogen, Cr: creatinine, UA: uric acid, TG: triglyceride, TC: total cholesterol, HDL-C: high-density lipoprotein cholesterol, LDL-C: low-density lipoprotein cholesterol, BS: blood sugar, HbA1c: hemoglobin A1c, Na: sodium, K: potassium, Cl: chloride, Ca: calcium, P: phosphate, CRP: C-reactive protein, HBsAg: hepatitis B surface antigen, HCVAb: hepatitis C virus antibody, WBC: white blood cell, Eos: eosinophil, Bas: basophil, Neu: neutrophil, Mon: monocyte, Lym: lymphocyte, RBC: red blood cell, Hb: hemoglobin, Ht: hematocrit, Plt: platelet

depressive mood, and malaise. She denied consuming alcohol or smoking cigarettes. She had previously visited the Department of Orthopedic Surgery, Department of General Medicine, and the Department of Japanese Oriental Medicine (Kampo Internal Medicine) at Toyama University Hospital.

She developed cough and sputum on day X-18, which subsequently worsened. On day X-4, she visited Clinic A where SSK extract (7.5 mg/day; TJ-9, Tsumura & Co., Tokyo, Japan), montelukast sodium (10 mg/day), dextromethorphan hydrobromide hydrate (45 mg/day), and carbocisteine (1,500 mg/day) were prescribed for 4 days. The patient took these medications as prescribed, but her symptoms did not improve. She then visited Hospital B on day X; no obvious abnormalities were noted on chest computed tomography (CT), but blood tests indicated liver injury [aspartate aminotransferase (AST) level, 154 U/L; alanine aminotransferase (ALT) level, 223 U/L]. Levofloxacin hydrate (500 mg/day), carbocisteine (750 mg/day), and tipecidine hiben-zate (30 mg/day) were prescribed, and the patient took these medications for 2 days. On day X+2, her cough was exacerbated, and hoarseness developed, so she visited the Department of Japanese Oriental Medicine at Toyama University Hospital and was hospitalized.

A physical examination revealed a height of 152 cm and a weight of 51 kg. Her body temperature was 36.8°C, pulse was 80 beats/min and regular, and blood pressure was 148/88 mmHg. Her conjunctivas were not pale or icteric, and her tonsils and thyroid were not swollen. Her heart sounds were normal, and no murmur or rale could be heard. The

liver, spleen, and kidneys were not palpable.

The patient's laboratory data at admission are summarized in Table 1. Serum AST (59 U/L), ALT (139 U/L), and gamma-glutamyl transpeptidase (γGTP; 134 U/L) levels were elevated, and liver injury was confirmed. Hepatitis B surface antigens and hepatitis C virus antibodies were absent. Abdominal ultrasonography revealed no abnormalities, other than post-cholecystectomy findings. Chest X-ray and plain CT also revealed no abnormalities. No abnormal bacterial flora were detected in sputum cultures. Serum mycoplasma antibodies were absent, and the cold agglutinin test was negative. The drug lymphocyte stimulation test [DLST; lymphocyte transformation test (LTT)] for SSK extract was positive [stimulation index (SI), 4.16]. A liver biopsy was not performed.

The clinical course of the patient's first episode of liver injury is illustrated in Fig. 1. All medications were discontinued after hospital admission, and her liver function improved and normalized. The clinical test results did not support a diagnosis of bacterial, mycoplasma, or interstitial pneumonia, or of malignancy as the cause of the respiratory symptoms. Regarding the cause of hepatic injury, there was no possibility of hepatitis B or C infection, but that of a general viral upper respiratory or hepatitis A infection could not be excluded. The DLST for SSK extract was positive, but a false positive result was possible; we therefore could not definitively conclude that SSK was the causal drug. We explained to the patient that SSK was the probable cause of her drug-induced liver injury and that she should not receive Kampo medicine prescriptions from any medical institution

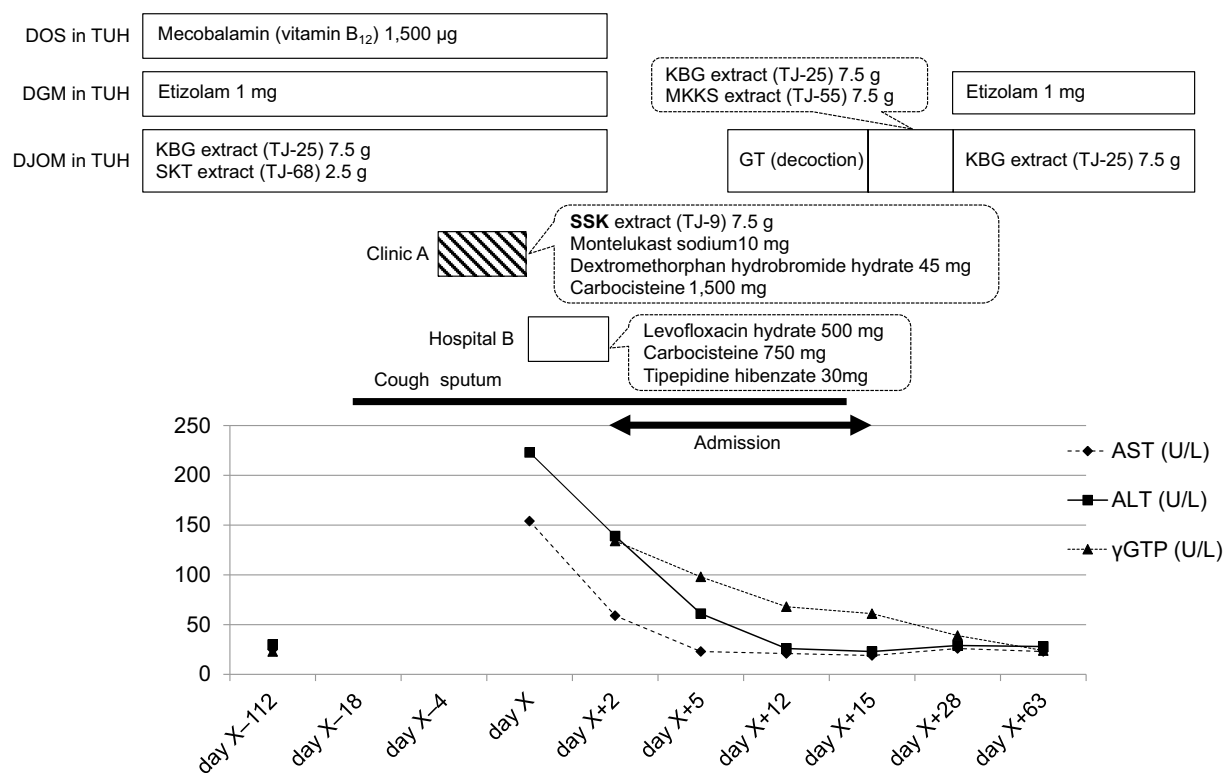


Figure 1. Clinical course of the patient's first episode of liver injury. ALT: alanine aminotransferase, AST: aspartate aminotransferase, DGM: Department of General Medicine, DJOM: Department of Japanese Oriental Medicine, DOS: Department of Orthopedic Surgery, γGTP: gamma-glutamyl transpeptidase, GT: *gokoto*, KBG: *keishibukuryogan*, MKKS: *makyokansekito*, SKT: *shakuyakukankoto*, SSK: *shosaikoto*, TUH: Toyama University Hospital

other than the Department of Japanese Oriental Medicine, nor should she purchase or take any over-the-counter Kampo medicines. The patient was discharged from the hospital on day X+15.

The patient subsequently visited the Department of General Medicine and the Department of Japanese Oriental Medicine at Toyama University Hospital. Approximately 1 year after her previous hospitalization, she visited Hospital B on day Y-35 (day Y was 413 days after day X) because a cutaneous eruption had appeared on her right abdomen. She was diagnosed with herpes zoster and prescribed oral valacyclovir hydrochloride (3,000 mg/day) for 7 days. On day Y-26, she visited Clinic C because she developed fatigue and night sweats. *Saikokeishikankyoto* (SAKK; Chai Hu Gui Zhi Gan Jiang Tang extract (TJ-11, Tsumura & Co.) and *hangekobokuto* (HKT; Ban Xia Hou Po Tang extract (TJ-16, Tsumura & Co.) were prescribed, and she took them for 21 days (until day Y-5).

On day Y-3, the patient developed brown urine, nausea, and anorexia, and the fatigue and night sweats worsened. On day Y, she visited the Department of General Medicine at Toyama University Hospital. The color of her urine had become lighter, but blood tests revealed elevation of AST (412 U/L), ALT (880 U/L), and γGTP (373 U/L) levels, indicating liver injury. The laboratory data from day Y are summarized in Table 2. Abdominal ultrasound revealed no abnormalities other than post-cholecystectomy findings. A liver

biopsy was not performed.

The clinical course of the second episode of liver injury is shown in Fig. 2. All medications were discontinued, and the liver function improved and normalized approximately one month later. On day Y+33, a DLST was performed, and the results were positive for SSK extract (SI, 16.3), SAKK extract (SI, 14.8), and *Scutellariae Radix* (SI, 31.2).

At the time that this report was written, the patient had not taken any Kampo medicines for approximately three years, and there had been no recurrence of liver injury.

Discussion

In recent years, adverse drug events have received much attention from society. In particular, drug-induced liver injury can be fulminant and lead to death. To diagnose drug-induced liver injury, the challenge test provides a definitive etiologic diagnosis. There have been multiple reports of cases in which small doses of a Kampo formula containing *Scutellariae Radix* were challenged as the causal drug and resulted in positive findings (7, 8, 14). However, at present, the challenge test is generally not recommended, as it is accompanied by risk. Cases in which so-called "unintentional challenge tests" were performed incidentally have also been reported. In such cases, the patient took or the physician prescribed a Kampo formula containing *Scutellariae Radix* without realizing that it might result in a challenge

Table 2. Laboratory Data from the Patient's Visit to the Department of General Medicine in Toyama University Hospital on Day Y.

TP	6.9 g/dL	TG	122 mg/dL	WBC	41.7×10 ² /μL
Alb	3.8 g/dL	TC	207 mg/dL	Eos	6.0 %
AST	412 U/L	BS	89 mg/dL	Bas	1.0 %
ALT	880 U/L	HbA1c	5.4 mg/dL	Neu	34.0 %
LD	330 U/L	Na	138 mEq/L	Mon	8.4 %
ALP	691 U/L	K	4.0 mEq/L	Lym	50.6 %
γGTP	373 U/L	Cl	106 mEq/L	RBC	430×10 ⁴ /μL
ChE	304 U/L	Ca	8.5 mg/dL	Hb	13.4 g/dL
CK	40 U/L	P	3.6 mg/dL	Ht	39.7 %
AMY	79 U/L	CRP	0.54 mg/dL	Plt	15.2×10 ⁴ /μL
T-Bil	1.3 mg/dL				
D-Bil	0.7 mg/dL			Urinalysis	
UN	10 mg/dL			Protein (-)	Bilirubin (-)
Cr	0.5 mg/dL			Glucose (-)	Urobilinogen (±)
UA	4.4 mg/dL			Occult blood (-)	

Day Y was 413 days after day X.

TP: total protein, Alb: albumin, AST: aspartate aminotransferase, ALT: alanine aminotransferase, LD: lactate dehydrogenase, ALP: alkaline phosphatase, γGTP: gamma-glutamyl transpeptidase, ChE: cholinesterase, CK: creatine kinase, AMY: amylase, T-Bil: total bilirubin, D-Bil: direct bilirubin, UN: urea nitrogen, Cr: creatinine, UA: uric acid, TG: triglyceride, TC: total cholesterol, BS: blood sugar, HbA1c: hemoglobin A1c, Na: sodium, K: potassium, Cl: chloride, Ca: calcium, P: phosphate, CRP: C-reactive protein, WBC: white blood cell, Eos: eosinophil, Bas: basophil, Neu: neutrophil, Mon: monocyte, Lym: lymphocyte, RBC: red blood cell, Hb: hemoglobin, Ht: hematocrit, Plt: platelet

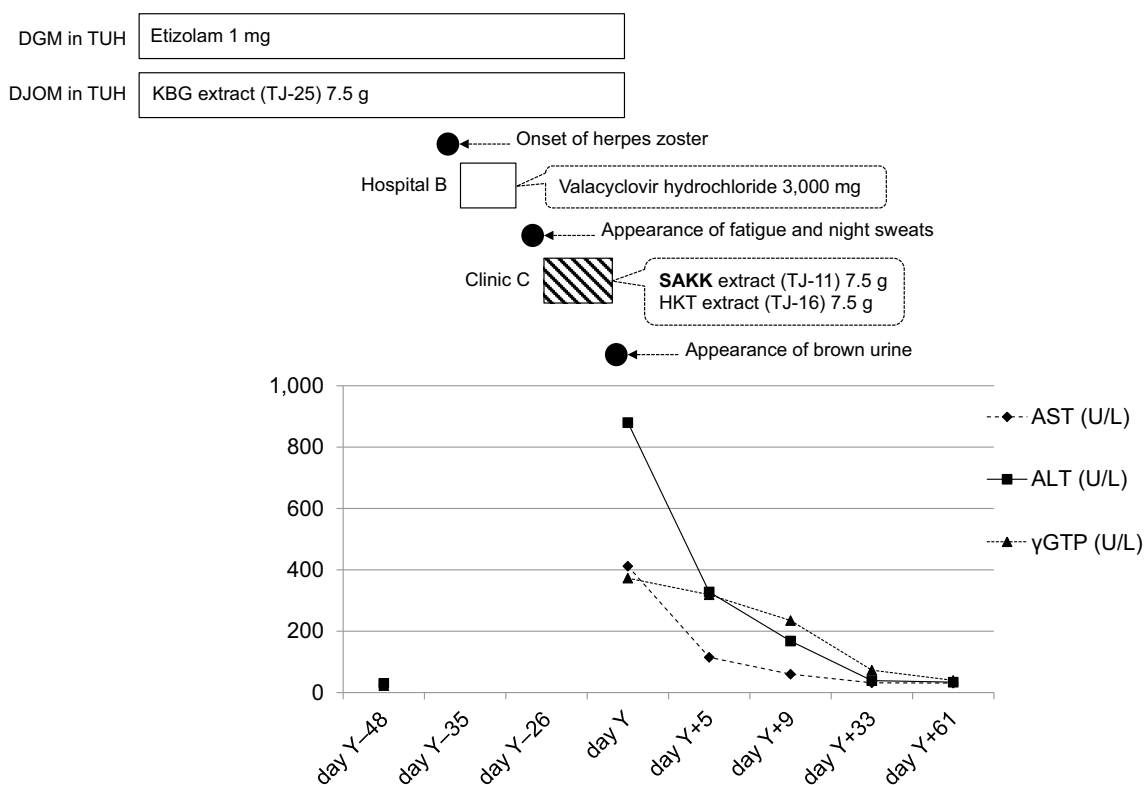


Figure 2. Clinical course of the patient's second episode of liver injury. ALT: alanine aminotransferase, AST: aspartate aminotransferase, DGM: Department of General Medicine, DJOM: Department of Japanese Oriental Medicine, γGTP: gamma-glutamyl transpeptidase, HKT: *hangekobokuto*, KBG: *keishibukuryogan*, SAKK: *saikokeishikankyoto*, TUH: Toyama University Hospital

test (7-10, 15, 16, 20).

When a challenge test is not conducted, determining a possible correlation between drug administration and the

cause liver injury is important. A DLST is performed in some cases, but false positive or negative results are possible; indeed, it has been reported that false positive results are particularly common with Kampo medicines (23, 24).

The proposal made at the workshop during Digestive Disease Week-Japan (DDW-J) 2004 is now used in Japan as a diagnostic criterion for drug-induced liver injury (25). First, based on the ALT and alkaline phosphatase (ALP) levels, liver injury is classified as hepatocellular-type, cholestatic-type, or combined hepatocellular-cholestatic. Second, a total score is calculated from eight items: period until the onset, course, risk factors, presence or absence of a nondrug-related cause, report of past liver injury, eosinophilia, DLST results, and the response in cases of incidental readministration. A diagnosis of drug-induced liver injury is determined to be highly probable if the score is >4 , probable if the score is 3-4, and not probable if it is <3 . Regarding possible nondrug-related causes of liver injury, the diagnostic criteria indicate that Category 1 includes hepatitis A (HAV), hepatitis B (HBV), and hepatitis C viral (HCV) infections, biliary disease, alcoholic liver disease, and ischemic hepatitis (i.e. shock liver), and Category 2 includes cytomegalovirus (CMV) and Epstein-Barr virus (EBV) infections.

In the case described in the present report, hepatic injuries occurred twice within a period of approximately one year. The first injury was believed to have been caused by the SSK extract prescribed by Clinic A for 4 days, and the second injury was believed to have been caused by the SAKK extract prescribed by Clinic C for 21 days. For the first injury, we were able to exclude five (HBV, HCV, biliary disease, alcoholic liver disease, and shock liver) of the six nondrug-related causes from Category 1. Similarly, for the second injury, we were able to exclude three causes from Category 1 (biliary disease, alcoholic liver disease, and shock liver). However, we were unable to exclude CMV and EBV as possible Category 2 causes for both the first and second liver injuries. According to the scoring system for diagnosing drug-induced liver injury proposed during the workshop of the DDW-J 2004, the first liver injury was classified as hepatocellular-type, and the total score was 7 when the causal drug was suspected to be SSK extract; therefore, a diagnosis of drug-induced liver injury was judged to be highly probable. The second liver injury was also classified as hepatocellular-type, and the total score was 5 when the causal drug was suspected to be SAKK extract, and a diagnosis of drug-induced liver injury was again judged to be highly probable. Furthermore, for the second liver injury, when the causal drug was suspected to be HKT extract, a DLST for this drug was not performed, and the total score was two, making a diagnosis of HKT-induced liver injury not probable.

We did not evaluate the patient's serum antinuclear antibody, gamma globulin, or immunoglobulin G levels during both the first and second liver injuries, but autoimmune hepatitis was determined to not be a probable cause because the two injuries improved uneventfully after discontinuation

of the suspected causal drugs without any other specific treatment, including steroid therapy. Serum chemistry tests conducted approximately 6-8 years prior to the first liver injury indicated that the serum antinuclear antibody test was negative, and there was no increase in the patient's gamma globulin level. Furthermore, since there were no episodes of suspected acute circulatory insufficiency, the probability of shock liver was considered low. While we were unable to completely exclude all viral infections (e.g. hepatitis A and herpes zoster infections) as potential causes of the liver injuries, the difference between the peak and normal upper limit ALT values decreased more than 50% within 5 days of discontinuing the suspected causal drugs after both the first and second liver injuries. Therefore, drug-induced liver injury was determined to be highly probable.

There are no useful clinical tests to definitively diagnose drug-induced liver injury, and in situations where a challenge test is not recommended, it is often difficult to identify the causal drug. Generally, Kampo formulas consist of multiple crude drugs. In this case, when SSK was suspected as the causal drug of the first episode of liver injury and SAKK or HKT was suspected for the second episode, the Kampo formulas taken before the first and the second episodes of liver injury contained five crude drugs in common: *Bupleuri Radix* (*saiko*), *Glycyrrhizae Radix* (*kanzo*), *Zingiberis Rhizoma* (*shokyo* or *kankyo*), *Scutellariae Radix*, and *Pinelliae Tuber* (*hange*). Among them, *Bupleuri Radix*, *Glycyrrhizae Radix*, and *Zingiberis Rhizoma* were also included in Kampo formulas that the patient had taken previously for more than four years without developing subsequent liver injury. Furthermore, it was also unlikely that these crude drugs had transformed into compounds that could cause liver injury. Therefore, we believed it highly unlikely that these three crude drugs included in *hochuekkito* (HET) induced these two liver injuries; therefore, only *Scutellariae Radix* and *Pinelliae Tuber* remained as possible causal crude drugs (Table 3).

There are Kampo formulas that contain both *Scutellariae Radix* and *Pinelliae Tuber* as well as formulas that only contain one or the other. As of September 1, 2017, liver injury was listed as a possible adverse drug event in the package inserts of most *Scutellariae Radix*-containing formulas (both with and without concomitant *Pinelliae Tuber*) but was only listed for a few formulas containing *Pinelliae Tuber* without *Scutellariae Radix* also being present (Table 4). A suspected causal drug is included in an individual pharmaceutical safety information report based on the judgment of the health professional involved. In individual cases, it is not always possible to clarify the causal relationship between a specific drug and an adverse event. Thus, multiple suspected causal drugs are often listed in pharmaceutical safety information reports, as the adverse event cannot be specifically attributed to one drug. Furthermore, drugs that are used more commonly are more likely to be designated as suspected causal drugs owing to their frequency of use. Therefore, based on the aforementioned rationale and comprehen-

Table 3. The Kampo Formulas and Their Comprising Crude Drugs That Were Administered to the Patient.

Kampo formula	HET	KSTRJ	TKI	KBG	SKT	SSK	GT	MKKS	SAKK	HKT
Department/Clinic	DJOM	DJOM	DJOM	DJOM	DJOM	CL-A	DJOM	DJOM	CL-C	CL-C
Total days of prescription	1,652	259	105	1,769	266	4	11	35	21	21
Crude drug										
Latin name	Japanese name									
Ginseng Radix	ninjin	n				p				
Astragali Radix	ogi	n	n							
Bupleuri Radix	saiko	n				p			p	
Cimicifugae Rhizoma	shoma	n								
Angelicae Radix	toki	n	n							
Zizyphi Fructus	taiso	n				p				
Atractylodis Lanceae Rhizoma	sojutsu	n*								
Atractylodis Rhizoma	byakujutsu	n#	n							
Aurantii Nobilis Pericarpium	chimpi	n								
Glycyrrhizae Radix	kanzo	n	n	n	n	p	n	n	p	
Zingiberis Rhizoma	shokyo/kankyo	n	n			p			p	p
Cinnamomi Cortex	keihi		n	n					p	
Paeoniae Radix	shakuyaku		n	n	n					
Zizyphi Fructus	taiso		n							
Poria	bukuryo		n	n						p
Processi Aconiti Radix	bushi		n							
Cnidii Rhizoma	senkyu		n							
Rehmanniae Radix	jio		n							
Schizonepetae Spica	keigai		n							
Polygoni Multiflori Radix	kashuu		n							
Tribuli Fructus	sitsurishi		n							
Saposhnikoviae Radix	bofu		n							
Moutan Cortex	botampi			n						
Persicae Semen	tonin			n						
Scutellariae Radix	ogon					p			p	
Pinelliae Tuber	hange					p				p
Ephedrae Herba	mao						n	n		
Armeniacae Semen	kyonin						n	n		
Gypsum Fibrosum	sekko						n	n		
Mori Cortex	sohakuhi						n			
Trichosanthis Radix	karokon								p	
Ostreae Testa	borei								p	
Magnoliae Cortex	koboku									p
Perillae Herba	soyo									p

HET: hochuekkito [extract (TJ-41) or decoction], KSTRJ: keishikaryojutsu [extract (EK-18)], TKI: tokiinshi [extract (TJ-86)], KBG: keishibukuryogan [extract (TJ-25) or ball], SKT: shakuyakukanzoto [extract (TJ-68)], SSK: shosaikoto [extract (TJ-9)], GT: gokoto [extract (TJ-95)], MKKS: makyokansekitto [extract (TJ-55)], SAKK: saikoishikankyo [extract (TJ-11)], HKT: hangekobokuto [extract (TJ-16)], DJOM: the Department of Japanese Oriental Medicine in the Toyama University Hospital, CL-A: Clinic A, CL-C: Clinic C, p: possibility of inducing liver injury, n: does not induce liver injury

*for extracts

#for decoctions

sive evaluations of the clinical course and previous reports, we concluded that, in the present case, Scutellariae Radix was more likely to be the causal crude drug than Pinelliae Tuber.

Adverse drug events induced by Kampo medicines include those caused by overdose, (e.g. pseudoaldosteronism caused by Glycyrrhizae Radix), sympathomimetic effects [caused by Ephedrae Herba (*mao*)], aconitine intoxication [caused by Aconiti Radix (*bushi*)], and diarrhea [caused by Rhei Rhizoma (*daio*)]. In addition, mesenteric phlebosclero-

sis is believed to be caused by the long-term use of Gardeniae Fructus (*sanshishi*) and its accumulation in the body (26). Conversely, Kampo medicine-induced liver injury and interstitial pneumonia are believed to be caused by immunological reactions (i.e. allergies), which are difficult to predict.

Scutellariae Radix is the most common causal crude drug of Kampo medicine-induced liver injury and interstitial pneumonia; therefore, it is necessary to pay close attention when prescribing Kampo formulas containing this drug. Fur-

Table 4. Kampo Formulas That Contain Scutellariae Radix (ogon) and/or Pinelliae Tuber (hange), and the Presence or Absence of Liver Injury Listed as an Adverse Event in the Package Inserts of Ethical Kampo Formulations as of September 1, 2017.

SR (+)/PT (-) [ogon (+)/hange (-)]		SR (+)/PT (+) [ogon (+)/hange (+)]		SR (-)/PT (+) [ogon (-)/hange (+)]	
saikokeishikankyoto	p	shosaikoto	p	bakumondoto	p
bofutsushosan	p	daisaikoto	p	rikkunshito	p
junchoto	p	hangeshashinto	p	shoseiryuto	p
keigairengyoto	p	nijutsuto	p	hangekobokuto	n
nyoshinsan	p	saibokuto	p	bukuryoingohangekobokuto	n
orengedokuto	p	saikokaryukotsuboreito	p	chikujountanto	n
otsujito	p	saikokeishito	p	chotosan	n
ryutanshakanto	p	saireito	p	goshakusan	n
sammotsuogonto	p	shosaikotokakikyosekko	p	hangebyakujutsutemmato	n
san'oshashinto	p	saikanto	n [#]	jinsoin	n
seihaio	p	daisaikotokyodaio	n [§]	nichinto	n
seijobofuto	p			orento	n
seishinrenshiin	p			ryokankyomishingeninto	n
shin'iseihaio	p			shohangekabukuryoto	n
unseiin	p			tokito	n
saikoseikanto	n*			unkeito	n
gorinsan	n			yokukansankachimpihange	n
ogonto	n				

SR: Scutellariae Radix, PT: Pinelliae Tuber

SR (+)/PT (-), [ogon (+)/hange (-)]: Kampo formulas that contain Scutellariae Radix (ogon), but not Pinelliae Tuber (hange).

SR (+)/PT (+), [ogon (+)/hange (+)]: Kampo formulas that contain both Scutellariae Radix and Pinelliae Tuber.

SR (-)/PT (+), [ogon (-)/hange (+)]: Kampo formulas that contain Pinelliae Tuber, but not Scutellariae Radix.

p: presence of liver injury listed as an adverse event in the package insert.

n: liver injury not listed as an adverse event in the package insert.

*saikoseikanto contains all the constituent crude drugs of orengedokuto and unseiin; therefore, liver injury may occur.

[#]saikanto contains all the constituent crude drugs of shosaikoto; therefore, liver injury may occur.

[§]daisaikotokyodaio contains the constituent crude drugs of daisaikoto, excluding Rhei Rhizoma (daio); since there is no possibility that Rhei Rhizoma is a causal drug, liver injury may occur.

thermore, in cases where liver injury (as well as interstitial pneumonia) caused by a Kampo medicine has occurred or was suspected in the past, patient guidance is particularly important.

The authors state that they have no Conflict of Interest (COI).

References

1. Tsukiyama K, Tasaka Y, Nakajima M, et al. A case of pneumonitis due to sho-saiko-to. *Nihon Kyobu Shikkan Gakkai Zasshi* (Japanese Journal of Thoracic Diseases) **27**: 1556-1561, 1989 (in Japanese, Abstract in English).
2. Takeshita K, Saisho Y, Kitamura K, et al. Pneumonitis induced by ou-gon (scullcap). *Intern Med* **40**: 764-768, 2001.
3. Terada M, Kitazawa H, Kawakami J, Adachi I. Pharmacoepidemiology of interstitial pneumonia and liver dysfunction associated with Kampo medicine. *Iryo Yakugaku* (Japanese Journal of Pharmaceutical Health Care and Sciences) **28**: 425-434, 2002 (in Japanese, Abstract in English).
4. Enomoto Y, Nakamura Y, Enomoto N, Fujisawa T, Inui N, Suda T. Japanese herbal medicine-induced pneumonitis: a review of 73 patients. *Respir Investig* **55**: 138-144, 2017.
5. Ishizaki T, Sasaki F, Ameshima S, et al. Pneumonitis during interferon and/or herbal drug therapy in patients with chronic active hepatitis. *Eur Respir J* **9**: 2691-2696, 1996.
6. Takikawa H, Murata Y, Horiike N, Fukui H, Onji M. Drug-induced liver injury in Japan: an analysis of 1676 cases between 1997 and 2006. *Hepatol Res* **39**: 427-431, 2009.
7. Tazawa J, Mae S, Sakai H, Nishimura M, Hasumura Y, Takeuchi J. A case of herb drug-induced liver injury showing the different morphological findings during the disease course of two years. *Kanzo* (*Acta Hepatologica Japonica*) **26**: 1669-1674, 1985 (in Japanese, Abstract in English).
8. Kadota Y, Fujinami S, Fukui Y, et al. A case of drug-induced liver damage caused by Sho-saiko-to. *Kanzo* (*Acta Hepatologica Japonica*) **34**: 36-41, 1993 (in Japanese, Abstract in English).
9. Sakai T, Kuniyoshi M, Nakamura M, Nakano T, Tameda Y, Kosaka Y. A case report of Sho-saiko-to induced hepatic and renal injury. *Kanzo* (*Acta Hepatologica Japonica*) **36**: 712-718, 1995 (in Japanese, Abstract in English).
10. Nakada T, Kawai B, Nagayama K, Tanaka T. A case of hepatic injury induced by Sai-rei-to. *Kanzo* (*Acta Hepatologica Japonica*) **37**: 233-238, 1996 (in Japanese, Abstract in English).
11. Kobayashi F, Nakamura H, Numata M, et al. [A case of drug-induced liver injury caused by Saiko-Keishi-Kankyoto with thrombocytopenia]. *Nippon Shokakibyō Gakkai Zasshi* (Journal of Japa-

- nese Society of Gastroenterology) **94**: 681-686, 1997 (in Japanese).
12. Okada Y, Watanabe K, Suzuki Y, et al. A case of hepatitis and interstitial pneumonitis induced by hangeshashin-to and shosaiko-to. *Nihon Toyo Igaku Zasshi (Japanese Journal of Oriental Medicine)* **50**: 57-65, 1999 (in Japanese, Abstract in English).
 13. Ozawa T, Watanabe H, Okuyama Y, et al. [A case of drug induced liver injury caused by a herbal drug, bofu-tsu-sho-san]. *Nippon Shokakibyō Gakkai Zasshi (Journal of Japanese Society of Gastroenterology)* **98**: 416-420, 2001 (in Japanese).
 14. Mantani N, Kogure T, Tamura J, Shimada Y, Terasawa K. Challenge tests and kampo medicines: case report and review of the literature. *Am J Chin Med* **31**: 643-648, 2003.
 15. Hosonuma K, Yuasa K, Yamada S, Takagi H, Mori M. [A case of reproducible hepatic injury induced by three kinds of herbal medicine]. *Kanzo (Acta Hepatologica Japonica)* **44**: 32-36, 2003 (in Japanese).
 16. Hatanaka N, Yamagishi T, Kamemura H, et al. A case of hepatitis and pneumonitis caused by Bofutsusyo-san herbal medicine. *Nihon Kokyūki Gakkai Zasshi (Journal of the Japanese Respiratory Society)* **44**: 335-339, 2006 (in Japanese, Abstract in English).
 17. Motoyama H, Enomoto M, Yasuda T, et al. Drug-induced liver injury caused by an herbal medicine, bofu-tsu-sho-san. *Nippon Shokakibyō Gakkai Zasshi (Journal of Japanese Society of Gastroenterology)* **105**: 1234-1239, 2008 (in Japanese, Abstract in English).
 18. Itoh T, Sugao M, Chijiwa T, et al. Clinical characteristics of side effects induced by administration of Glycyrrhizae Radix and Scutellaria Radix under the therapy based on Kampo diagnosis in our hospital. *Nihon Toyo Igaku Zasshi (Kampo Medicine)* **61**: 299-307, 2010 (in Japanese, Abstract in English).
 19. Gono Y, Odaguchi H, Hayasaki T, et al. Clinical analysis of cases with drug-induced liver injury for Kampo medicine. *Nihon Toyo Igaku Zasshi (Kampo Medicine)* **61**: 828-833, 2010 (in Japanese, Abstract in English).
 20. Maruyama Y, Yoshizawa K, Tsuruta F, et al. A case of repeated liver injury induced by different herbal medicines containing the same components. *Kanzo (Acta Hepatologica Japonica)* **55**: 214-220, 2014 (in Japanese, Abstract in English).
 21. Dohmen K, Tanaka H, Haruno M, Shimoda S, Aishima S. A case of drug-induced liver injury caused by Keishi-karyukotsu-boreito and Shin-i-seihaito. *Nippon Shokakibyō Gakkai Zasshi (Journal of Japanese Society of Gastroenterology)* **112**: 1054-1059, 2015 (in Japanese, Abstract in English).
 22. Oikawa T, Gono Y, Fukuda T, et al. Three asymptomatic cases of suspected drug-induced liver injury possibly caused by Scutellariae Radix. *Nihon Toyo Igaku Zasshi (Kampo Medicine)* **66**: 212-217, 2015 (in Japanese, Abstract in English).
 23. Mantani N, Kogure T, Sakai S, et al. Incidence and clinical features of liver injury related to Kampo (Japanese herbal) medicine in 2,496 cases between 1979 and 1999: problems of the lymphocyte transformation test as a diagnostic method. *Phytomedicine* **9**: 280-287, 2002.
 24. Mantani N, Kogure T, Tamura J, Shimada Y, Terasawa K. Lymphocyte transformation test for medicinal herbs yields false-positive results for first-visit patients. *Clin Diagn Lab Immunol* **10**: 479-480, 2003.
 25. Takikawa H, Onji M, Takamori Y, et al. [Proposal of diagnostic criteria of drug induced hepatic injury in DDW-J 2004 workshop]. *Kanzo (Acta Hepatologica Japonica)* **46**: 85-90, 2005 (in Japanese).
 26. Nagata Y, Watanabe T, Nagasaka K, et al. Total dosage of gardenia fruit used by patients with mesenteric phlebosclerosis. *BMC Complement Altern Med* **16**: 207, 2016.

The Internal Medicine is an Open Access article distributed under the Creative Commons Attribution-NonCommercial-NoDerivatives 4.0 International License. To view the details of this license, please visit (<https://creativecommons.org/licenses/by-nc-nd/4.0/>).