

Ultrasonographic features of the liver with cystic echinococcosis in sheep

Hussein Awad Hussein,¹ Mohammed Elrashidy²

To cite: Hussein HA, Elrashidy M. Ultrasonographic features of the liver with cystic echinococcosis in sheep. *Vet Rec Open* 2014;1:e000004. doi:10.1136/bmjopen-2013-000004

► Prepublication history and additional material for this paper are available online. To view these files please visit the journal online (<http://dx.doi.org/10.1136/bmjopen-2013-000004>).

Received 10 September 2013
Revised 12 November 2013
Accepted 9 December 2013

This final article is available for use under the terms of the Creative Commons Attribution Non-Commercial 3.0 Licence; see <http://creativecommons.org/licenses/by-nc/3.0/>



CrossMark

¹Department of Animal Medicine, Faculty of Veterinary Medicine, Assiut University, Assiut 71526, Egypt

²Department of Animal Surgery, Faculty of Veterinary Medicine, Sohag University, Sohag 2524, Egypt

Correspondence to Dr Hussein A Hussein; hussein-vet@lycos.com and hhussein@aun.edu.eg

ABSTRACT

Objectives: The present study was designed to gain information about the ultrasonographic features of livers with cystic echinococcosis, as well as to evaluate the use of ultrasonography for diagnosis of such disease in sheep.

Design: This was a retrospective study during the period April 2011 to March 2013.

Participants: A total of 22 Baladi sheep (aged three to six years) were included in this study. Based on clear hepatic ultrasonographic findings, all animals were classified into two groups: those with hepatic cysts (n=9) and without liver cysts (healthy liver, n=13).

Results: Biochemically, serum concentrations of γ -glutamyl transferase, aspartate aminotransferase, total bilirubin and globulins were significantly increased ($P<0.01$), while albumin was lowered ($P<0.01$) in sheep with cystic livers. Ultrasonographic findings of diseased sheep livers revealed the presence of rounded, anechoic and unilocular hydatid cysts with ellipse circumference ranged from 6–10 cm. The borders of cysts were mostly well defined. The interior of cysts contained echogenic particulate materials, septations, or fine echoes. At the 10th intercostal space, the ventral margin, size, thickness and angle of livers were higher ($P<0.01$), while the diameter of portal vein was lower ($P<0.01$) in sheep with liver cysts than control ones. Furthermore, at the 9th intercostal space, the circumference of the gall bladder was decreased in sheep with hepatic cysts ($P<0.01$). The sensitivity, specificity, and positive and negative predictive values of ultrasonography for diagnosis of hepatic hydatid cysts were 80 per cent and 100 per cent, and 100 per cent and 83 per cent, respectively.

Conclusions: Cystic echinococcosis is associated with a number of anatomical alterations in the liver tissues that can be easily recognised by ultrasound. Furthermore, ultrasonography alone or in combination with analysis of biochemical parameters reflecting liver function could be helpful for diagnosis of hepatic hydatid cysts in sheep.

INTRODUCTION

Cystic echinococcosis (CE) is a zoonotic parasitic infection of many mammalian species caused by the larvae of *Echinococcus granulosus*, which is found in the small intestines of dogs

and other carnivores (Kassai 1999). Sheep, cattle and camels are considered as intermediate hosts (Macpherson 1985). Liver and lung cysts of *E granulosus* are a worldwide parasitic disease (Safioles and others 2007), and it is endemic in countries where sheep grazing is carried out with the help of dogs (Khuroo 2002).

The disease also has a wider public health importance. Humans are accidental intermediate hosts (Eckert and others 2001). Sheep and goats appear to be the most important reservoir for human hydatidosis because of the widespread practices of home slaughtering, feeding of diseased offal to the definitive host (the dog; Macpherson and others 1989) and the high percentage of fertile cysts found in small ruminants (Khuroo and others 1991). Sheep as intermediate hosts are infected by ingestion of parasite eggs, which reach the liver via the portal system to form hydatid cysts (Khuroo and others 1991). The liver is involved in up to 75 per cent cases, but no part of the body is spared (Amman and Eckert 1996, Andreas 1997, Lisa 1998).

Cystic liver disease has an economic impact in countries where livestock industry is an important segment of the agricultural sector and where livestock production is based mainly on an extensive grazing system (Berhe 2009). Significant losses are of particular significance in countries with low economic output where sheep production is of particular importance (Torgerson and others 2001), as they include losses of meat and milk production, and fleece values from infected sheep may also be affected (Torgerson 2003, Lahmar and others 2007). CE in farm animals also causes considerable economic problems due to loss of edible livers (Paksoy and others 2003).

With the advent of ultrasonography, many organs and tissues can be scanned and examined for presence of many diseases. There are no reliable methods for the routine diagnosis of liver cysts in living animals, but in rare cases cysts have been identified by ultrasonography alone or in conjunction with serum

antibody detection (Eckert and others 2001). Previous studies (Maxson and others 1996, Sage and others 1998, Lahmar and others 2007) suggested the use of ultrasonography for diagnosis of CE, but they lacked providing detailed information about the ultrasonographic features and alterations of sheep liver with hydatid cysts. Therefore, this study was planned to gain information about the ultrasonographic findings of sheep livers with CE, and also to assess the use of ultrasonography for diagnosis of such disease.

MATERIALS AND METHODS

Animals, history and physical examination

In this study, a total of 22 Baladi sheep (aged three to six years) of both sexes were admitted during the period April 2011 to March 2013 because of weight loss, diarrhoea or pregnancy diagnosis at the Veterinary Teaching Hospital, Assiut University, Egypt. The case histories of infected sheep revealed grazing on pastures near areas known to have stray dogs, or flock control with the help of dogs. This information was obtained from the owners using a questionnaire prepared for this study. Based on clear hepatic ultrasonographic findings, all animals were classified into one of two groups: those with hepatic cysts ($n=9$) and without liver cysts (healthy liver, $n=13$). All animals were subjected to physical examination as described previously (Pugh 2002). This included their general behaviour and condition; auscultation of the heart, lungs, rumen and intestine; and measurement of heart rate, respiratory rate and rectal temperature. Animals with other disease conditions were excluded from the study.

Haematological and biochemical analyses

Two blood samples were collected by puncture of the jugular vein: one with heparin and the other without anticoagulant. Blood gas analysis and a complete blood count including haematocrit, haemoglobin, erythrocyte count and total leucocyte count were carried out on the first sample (Coles 1986). After centrifugation of the second blood sample, serum samples were collected and then frozen at -20°C for one week; subsequently, analysis of biochemical parameters was carried out. With the serum samples, commercial test kits were used to determine the concentrations of total proteins, albumin, blood urea nitrogen, creatinine and total bilirubin. The activities of aspartate aminotransferase (AST) and γ -glutamyl transpeptidase (GGT) were also measured in serum samples. The biochemical analyses of the selected parameters were spectrophotometrically measured according to the standard protocols of the suppliers.

Ultrasonographic examination

Ultrasound examination was carried out while the animals were standing using a real time B-mode scanner with 3.5, 5.0 and 8.0 linear and convex transducers (Veterinary Ultrasound Scanner System, Scanner Aquila

Pro. Vet. Model, Esoate Europe BV, The Netherlands). In preparation for ultrasonography, the right thorax and abdomen were clipped, shaved and a coupling gel was applied. Ultrasonographic examination of the liver was performed on the right side of the abdomen in the 12th to 7th intercostal spaces. In each intercostal space, the dimensions of the liver and, if visible, the location and diameter of the caudal vena cava and portal vein were determined. In addition, the angle of the liver, and location and circumference of the gall bladder were also determined (Braun and Hausammann 1992, Scott and Sargison 2010), and the number, size and location of cysts noted.

Statistical analysis

Data are presented as mean \pm SE and the analysis was conducted using SPSS V.16.0. Haematological, biochemical and blood gas and acid–base data as well as ultrasonographic findings were compared using the Student *t* test. Differences between parameters were tested for significance at probability levels of $P<0.05$, $P<0.01$ and $P<0.001$. A contingency 2×2 table was created to compute the sensitivity, specificity, positive and negative predictive values using ultrasonography as a diagnostic tool for incidence of hepatic CE. The formulas described below were used to calculate the sensitivity, specificity, positive and negative predictive values (Dunn and Clark 2009):

$$\begin{aligned} \text{Sensitivity} &= 100[\text{true positive}/\text{true positive} + \text{false negative}] \\ \text{Specificity} &= 100[\text{true negative}/\text{true negative} + \text{false positive}] \\ \text{Positive predictive value} &= 100[\text{true positive}/\text{test positive}] \\ \text{Negative predictive value} &= 100[\text{true negative}/\text{test negative}] \end{aligned}$$

RESULTS

Clinical, haematological and biochemical findings

Case histories of diseased sheep revealed grazing on pastures near areas with stray dogs or flock control with the help of dogs. This information was obtained from the owners using a questionnaire prepared for this study. Table 1 summarises the main clinical findings in sheep with cystic and healthy livers. Sheep with cystic liver experienced inappetence with frequent diarrhoea and constipation. Two cases had roughness of wool and shaggy appearance.

With regard to the haematological findings, insignificant differences were found in the sheep in the two liver health groups. Biochemically, in comparison with control animals, increased serum levels of globulins ($P<0.01$), total bilirubin ($P<0.01$), AST ($P<0.001$) and GGT ($P<0.01$) were obtained in diseased sheep, while the serum level of albumin and albumin/globulin ratio were lowered in sheep with cystic livers ($P<0.01$). The other serum parameters did not differ significantly between sheep with hepatic cysts and healthy ones (Table 2).

TABLE 1: Clinical findings in sheep in two liver health groups (n=22)

Liver health group	Clinical observations	Temperature, °C	Respiration, breaths/min	Heart rate beats/min	Ruminal contractions
Cystic liver (n=9)	Depression, inappetence, weight loss, poor condition, and frequent diarrhoea and constipation	39.3±0.04	24±0.3	86±2.3	2.0±0.17
Healthy liver (n=13)	Good condition, most ewes were at early stages of pregnancy	39.4±0.06	25±0.5	87±2.1	2.2±0.12

Ultrasonographic findings

The livers of all animals were examined from the 12th to the 7th intercostal spaces (Fig 1). In one healthy sheep, the 12th intercostal space was too narrow; therefore, ultrasonographic examination was not possible in this location. Table 3 shows the ultrasonographic findings from the livers in the two health groups. At the 10th intercostal space, ventral margin, size, thickness and angle of liver were all higher in sheep with liver cysts than healthy ones ($P<0.01$). Out of nine cases with hepatic cysts, three cases showed cysts at the right lobe of liver near the portal vein with increased echogenicity of its wall and narrowing of its diameter (Fig 2), and two cases exhibited cysts near the angle of the liver at the 10th intercostal space (Fig 4).

TABLE 2: Haematological and biochemical findings of sheep in two liver health groups (n=22)

Parameters	Liver health group	
	Cystic liver (n=9)	Healthy liver (n=13)
Haematocrit, %	34±1.0	32±0.6
Haemoglobin, g/L	98±3	100±2
Erythrocytes, T/L	9.2±0.18	9.6±0.24
Leukocyte count, G/L	6.4±0.17	5.9±0.15
γ-Glutamyl transferase, U/L	46±3**	33±2
Aspartate aminotransferase, U/L	104±4***	36±1
Total bilirubin, μmol/L	8.5±0.55**	4.2±0.40
Total proteins, g/L	69±1	70±0.8
Albumin, g/L	22±0.5**	28±0.44
Globulins, g/L	47±1.3**	42±0.8
Albumin/globulin ratio	0.5±0.06**	0.7±0.02
Blood urea nitrogen, mmol/L	3.9±0.16	4.2±0.15
Creatinine, μmol/L	111±2.0	114±1.5
Venous blood gas and acid-base indices:		
pH	7.37±0.02	7.36±0.01
HCO ₃ , mmol/L	22±0.3	23±0.2
tCO ₂ , mmol/L	24±0.5	25±0.4
pO ₂ , mm Hg	34±0.3	35±0.3
pCO ₂ , mm Hg	42±0.6	44±0.5
BE, mmol/L	0.42±0.04	0.40±0.07

Data presented as mean±SE.

** $P<0.01$.

*** $P<0.001$.

The parenchymal pattern of liver in control sheep consisted of numerous weak echoes homogeneously distributed over the entire liver (Figs 3 and 5), whereas in diseased sheep the liver showed heterogeneous hyperechogenic parenchyma (Figs 2 and 6).

In general, liver cysts were rounded, anechoic, unilocular structures with typically hypoechogenic contents (Fig 6). The ellipse circumference of hepatic cysts ranged from 6.7–10.4 cm. The ultrasonographic appearance of liver cysts was homogenous in five animals and heterogeneous in the rest of the animals. The interiors of some cysts contained echogenic particulate materials (Fig 7), septations (Fig 2), or fine echoes (Fig 8). The borders of cysts were either well defined (Fig 8) or ill defined (Fig 2).

The caudal vena cava was located dorsal and medial to the portal vein. It was usually triangular on cross-sectional view (Figs 2 and 3), whereas the portal vein was round or slightly oval (Figs 2–4). In both health groups, the diameter of the caudal vena cava increased cranially, whereas the portal vein diameters decreased cranially ($P<0.05$). The dorsal margin, depth and diameter of the caudal vena cava showed insignificant differences between the two liver health groups ($P>0.05$), whereas at the 10th intercostal space the diameter of the

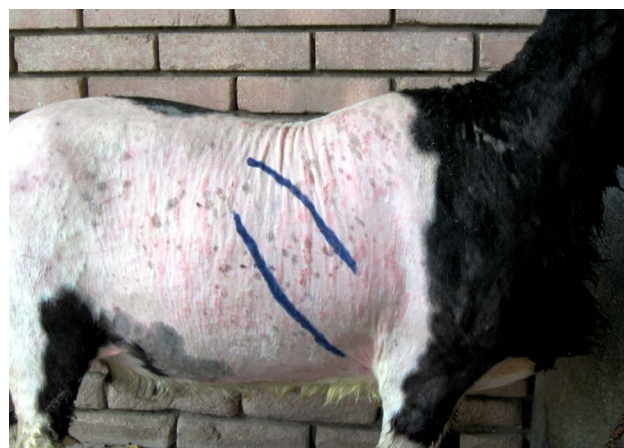

FIG 1: Location of the liver. The lines drawn on the sheep represent the dorsal and ventral limits of the liver from the 7th to the 12th intercostal space. These limits correspond to the mean positions of the dorsal and ventral limits of the liver in 13 healthy sheep

TABLE 3: Ultrasonographic examination of sheep livers (n=22)

Variable	Liver health group	Intercostal space					
		12	11	10	9	8	7
Dorsal margin†	Cystic liver (n=9)	6.1±0.23	8.0±0.17	8.4±0.17	11±0.17	15±0.4	27±0.23
	Healthy liver (n=13)	6.0±0.16	7.6±0.21	8.5±0.14	11±0.20	16±0.4	26±0.24
Ventral margin†	Cystic liver (n=9)	15±0.23	17±0.15	20±0.33**	25±0.4	27±0.5	36±0.24
	Healthy liver (n=13)	16±0.26	17±0.21	18±0.24	24±0.3	27±0.3	36±0.28
Size, cm	Cystic liver (n=9)	8.9±0.33	9±0.29	11.6±0.22**	14±0.4	12±0.4	9±0.15
	Healthy liver (n=13)	10±0.34	9.4±0.26	9.5±0.26	13±0.2	11±0.5	10±0.14
Thickness, cm	Cystic liver (n=9)	NA	7.1±0.28	9.2±0.09*	7.8±0.27	NA	NA
	Healthy liver (n=13)	NA	7.2±0.54	8.3±0.29	8.1±0.21	NA	NA
Angle, °	Cystic liver (n=9)	NA	33±1.3	38±1*	34±0.8	NA	NA
	Healthy liver (n=13)	NA	34±0.7	35±0.9	35±1.1	NA	NA

†Centimeters distal to the midline of the back, values represented as mean±SE.

*P<0.05

**P<0.01

NA, Not applicable

portal vein was smaller in sheep with hepatic cysts than in control ones (P<0.01).

The gall bladder was visualised in all sheep. Generally, the gall bladder was visible at the 9th, 10th or both intercostal spaces. Ultrasonographically, the gall bladder was recognised as a fluid-filled vesicle, which appeared as an oval or pear-shaped dark area with a bright margin (Fig 3). At the 10th and 9th intercostal spaces, the dorsal margins of the gall bladder were greater in sheep with hepatic cysts than healthy ones (P<0.01), whereas at the 9th intercostal space the circumference of the gall bladder was smaller in the diseased group than in control animals (P<0.01) (Table 4).

Postmortem findings

In order to evaluate the reliability of ultrasonography for detection of hepatic cysts, 10 animals were slaughtered after ultrasonographic examination, with the owners' consent. Necropsy examination of two cases showed that all cysts were located in the right (Fig 9) and left lobes of the liver. These cysts were dead as they were caseous. In three cases, cysts were observed near the portal area. Postmortem examination of these cysts revealed the presence of protoscoleces and clear hydatid fluid, indicating viability. Postmortem examination of the rest of the slaughtered sheep (5 cases) revealed no gross hepatic lesions. One positive sheep on

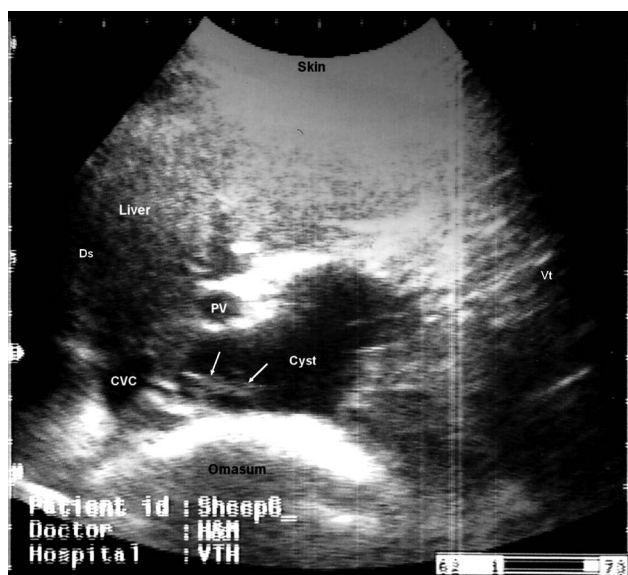


FIG 2: Ultrasonogram of liver of a five-year-old sheep viewed from 9th intercostal space with a 5-MHz convex transducer showing a periportal cyst with ill-defined borders and anechoic content containing echogenic septa (white arrows) (note narrowing with hyperechogenicity of portal vein). CVC, caudal vena cava; PV, portal vein; Ds, dorsal; Vt, ventral

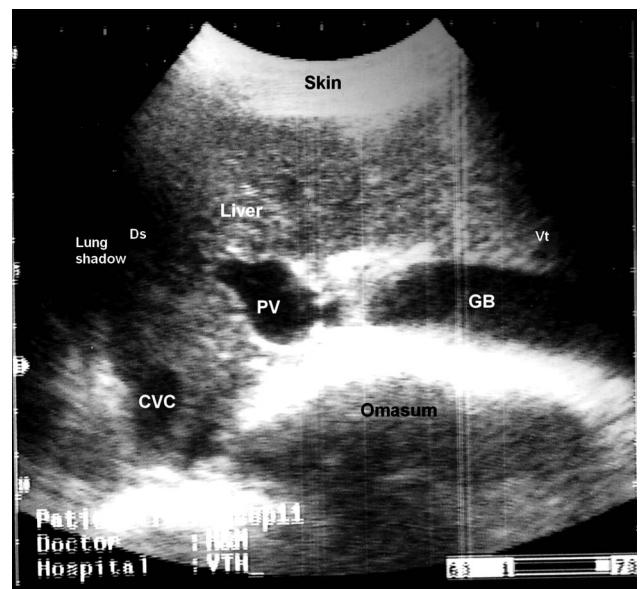


FIG 3: Ultrasonogram of liver of a five-year-old sheep viewed from 9th intercostal space with a 5-MHz convex transducer showing greyish echogenicity of parenchyma in a healthy liver and non-compressed portal vein (compare with Figs 2). CVC, Caudal vena cava; Ds, Dorsal; GB, Gall bladder; PV, Portal vein; Vt, Ventral.

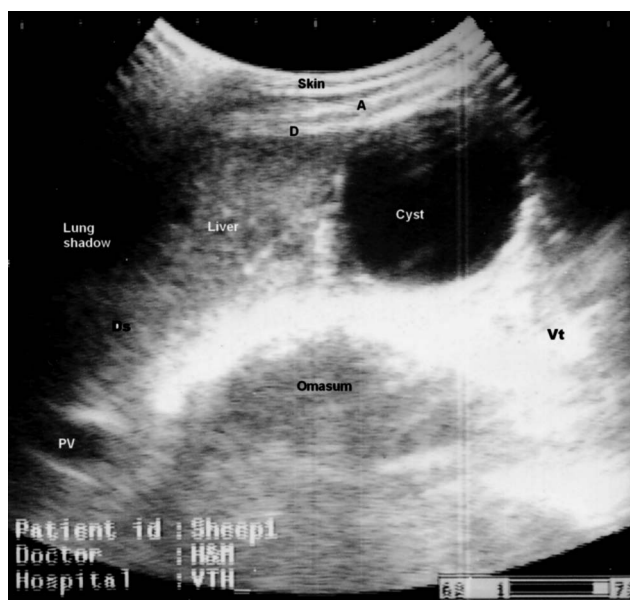


FIG 4: Ultrasonogram of liver of a four-year-old sheep viewed from 10th intercostal space with a 5-MHz convex transducer showing anechoic content of hepatic cyst near the liver angle with increased echogenicity of liver. A, abdominal wall; D, diaphragmatic surface; Ds, dorsal; PV, portal vein; Vt, ventral.

postmortem examination had been falsely identified as negative on ultrasonographic examination. In comparison with postmortem findings, the sensitivity and specificity, positive and negative predictive values of ultrasonography as a diagnostic tool for hepatic hydatid cysts were 80 per cent and 100 per cent, and 100 per cent and 83 per cent, respectively.

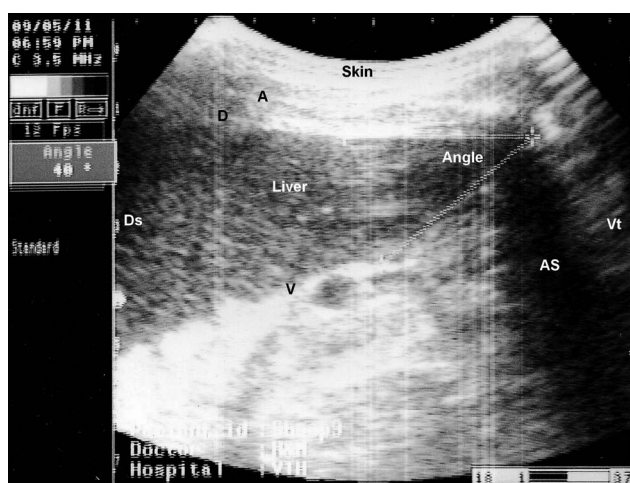


FIG 5: Ultrasonogram of liver of a five-year-old sheep viewed from 10th intercostal space with a 3.5-MHz convex transducer showing the angle of healthy liver (40°), numerous homogenous weak echoes (grey in color). A, abdominal wall; D, diaphragmatic surface of liver; AS, acoustic shadowing; V, visceral surface of liver; Ds, dorsal; Vt, ventral

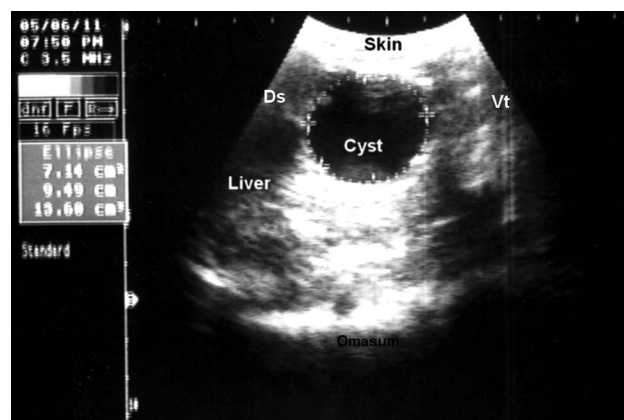


FIG 6: Ultrasonogram of liver of a three-year-old sheep viewed from 9th intercostal space with a 3.5-MHz convex transducer showing anechoic content of liver cyst (ellipse circumference=9.49 cm) and increased echogenicity of liver parenchyma. Ds, dorsal; Vt, ventral

DISCUSSION

Killing infected sheep at a rural breeding site begins the CE transmission cycle that progresses with infection of dogs and finally contamination of the environment where other sheep, and occasionally humans working in contact with them, acquire the disease (WHO Informal Working Group 2003).

Although the importance of sheep in the cycle of CE has been recognised, diagnostic methods that allow in vivo identification of parasitised sheep have been poorly evaluated. Serological tests for the diagnosis of hydatid cysts in sheep have proven unreliable (Lightowlers and others 1984) and of limited use (World Organisation For Animal Health 2008), as these tests does not

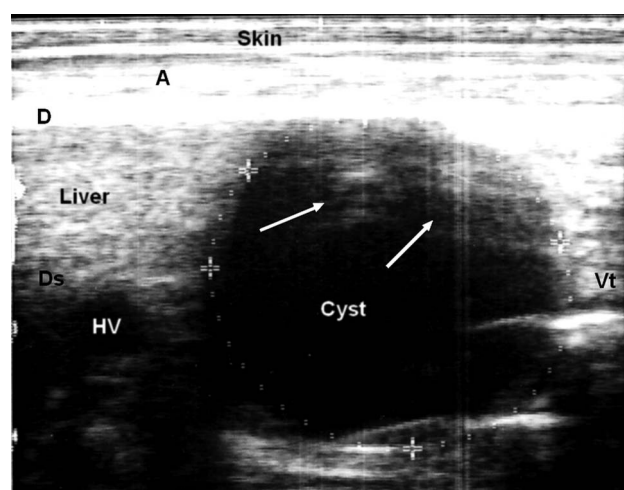


FIG 7: Ultrasonogram of liver of a four-year-old sheep viewed from 9th intercostal space with a 8-MHz linear transducer showing a cyst (ellipse circumference=10.05 cm) with ill-defined borders and echogenic particulate contents (white arrows) A, abdominal wall; D, diaphragmatic surface; HV, hepatic vein; Ds, dorsal; Vt, ventral

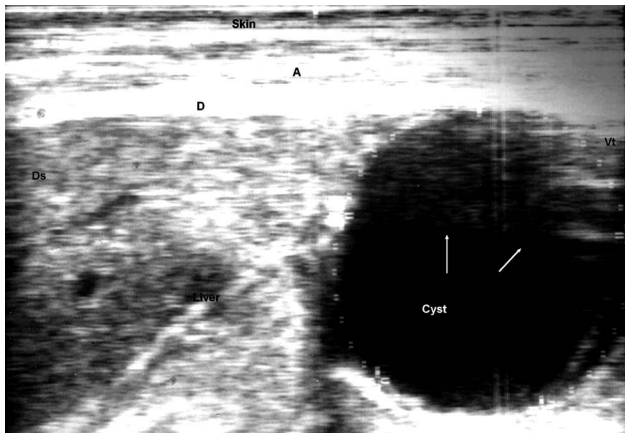


FIG 8: Ultrasonogram of liver of a six-year-old sheep viewed from 10th intercostal space with a 8-MHz linear transducer showing a cyst (ellipse circumference=10.05 cm) with well defined borders and fine echogenic contents representing hydatid sand (white arrows) A, abdominal wall; D, diaphragmatic surface; Ds, dorsal; Vt, ventral

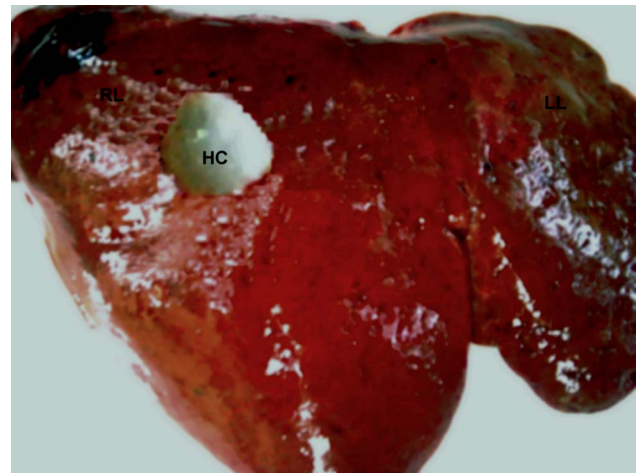


FIG 9: A hydatid cyst located near the right lobe of a sheep liver at postmortem examination. HC, hydatid cyst; LL, left lobe; RL, right lobe

distinguish between current and previous infections as well as the fact crossreactivity between *Echinococcus* and *Taenia* species may occur (World Organisation For Animal Health 2008). Such information is currently obtained at postmortem examination and only at abattoirs during veterinary meat inspections. Thus, the only available data are incomplete and only refer to institutional slaughtering (Guarnera and others 2001). As listed in Table 1, there are no specific signs indicating

infection of sheep with cystic hepatic disease. Additional diagnostic techniques are often helpful for evaluation of liver function through estimation of liver enzymes, total bilirubin, total proteins and albumin (Tennant and Center 2008). In diseased sheep, the significantly increased activities of AST and GGT could be attributed to leakage of these enzymes from hepatocytes as a result of pressure damage caused by hydatid cysts on the liver tissue, whereas increased serum levels of total bilirubin, decreased albumin and lowered albumin globulin ratios

TABLE 4: Ultrasonographic findings of caudal vena cava, portal vein and gall bladder of sheep in two liver health groups (n=22)

Variable	Liver health group	Intercostal space			
		12	11	10	9
Caudal vena cava					
Dorsal margin†	Cystic liver (n=9)	8.6±0.63	11.4±0.63	13.8±0.66	16.0±0.62
	Healthy liver (n=13)	7.6±0.68	10.3±0.56	12.7±0.54	16.2±0.53
Depth, cm	Cystic liver (n=9)	5.1±0.28	5.4±0.17	5.4±0.13	6.1±0.19
	Healthy liver (n=13)	5.2±0.24	5.1±0.27	6.1±0.29	6.6±0.24
Diameter, cm	Cystic liver (n=9)	1.4±0.06	1.5±0.08	1.7±0.10	1.7±0.05
	Healthy liver (n=13)	1.5±0.04	1.6±0.04	1.8±0.03	1.8±0.03
Portal vein					
Dorsal margin†	Cystic liver (n=9)	11±0.8	13.3±0.74	13.7±0.87	16.7±0.51
	Healthy liver (n=13)	12±0.7	12.8±0.65	14.5±0.59	17.2±0.69
Depth, cm	Cystic liver (n=9)	3.7±0.21	3.7±0.15	4.0±0.17	3.8±0.14
	Healthy liver (n=13)	4.5±0.32	4.1±0.13	4.1±0.16	3.9±0.14
Diameter, cm	Cystic liver (n=9)	1.8±0.09	1.8±0.12	1.2±0.06**	1.2±0.05
	Healthy liver (n=13)	1.9±0.04	1.7±0.05	1.5±0.03	1.2±0.02
Gall bladder					
Dorsal margin†	Cystic liver (n=9)	NA	NA	16±0.58**	27±0.35**
	Healthy liver (n=13)	NA	NA	12±0.13	23±0.28
Circumference, cm	Cystic liver (n=9)	NA	NA	12±1.0	11±1.1**
	Healthy liver (n=13)	NA	NA	13±0.9	16±0.3

†Centimeters distal to the midline of the back, values presented as mean±SE.

**P<0.01.

NA, not applicable.

might be due to impaired liver function. Previously, Barnes and others (2011) stated that hydatid cysts grow progressively and increase in size and weight, producing pressure atrophy of the parasitised organ, displacement of adjacent tissues and functional alteration of varying degrees. Furthermore, growing hepatic cysts may interfere with bile flow, causing cholestasis.

In ruminants, liver function tests are not specific for diagnosis of liver diseases. Metabolic disorders lead to diffuse changes in the liver, whereas abscesses, cysts and tumours usually induce focal changes (Pearson 2002). Hepatic function tests are generally unable to distinguish these diseases (Tennant and Center 2008). In contrast to liver function tests, ultrasonography is a quick, non-invasive and well tolerated technique for the diagnosis of cystic hepatic disease in the field (Maxson and others 1996, Sage and others 1998, Lahmar and others 2007).

In the present study, in both healthy and diseased sheep, livers were examined via ultrasonography from the 12th to the 7th intercostal spaces, except in one healthy sheep where the 12th intercostal space was too narrow; therefore, ultrasonographic examination was not possible in this case. In sheep with hepatic cysts, increased echogenicity of liver may be due to changes in the nature of the liver tissue, which may increase the attenuation of the ultrasound beams. This postulation was supported previously by Szebeni and others (2006), who found that the average attenuation of ultrasound beam in bright liver and normal liver as 1.21 ± 0.06 dB/cm/MHz and 0.68 ± 0.03 dB/cm/MHz, respectively. In comparison with control sheep there was a significant increase of the ventral margin of the liver in diseased sheep at the 10th intercostal space (ICS), though it is difficult to conclude or generalise this finding as previously, Braun and Hausammann (1992) tabulated the ventral margin at the 10th ICS of healthy sheep as ranging from 20.7–39.5 cm.

At the 10th ICS, the significant increase of liver size, thickness and angle in sheep with hepatic cysts might be due to hydatid cyst growth. Previous studies (Eckert and Deplazes (2004), Barnes and others (2011), Von Sinner 1997) found increased size and weight of liver as a result of growth of hydatid larvae. Braun and Hausammann (1992) concluded that increased liver size in sheep could be suspected when the liver thickness in one ICS is >8.5 cm. Ultrasonographically, hepatic cysts were rounded or oval with well-defined or ill-defined borders. Generally, the contents of hepatic cysts were anechoic, although the interior of some cysts contained either echogenic particulate materials, which may correspond to hydatidic gallstones fine echoes; this may represent hydatid sand or septations, which may give a daughter cyst. These findings are in agreement with Von Sinner (1997) who described hepatic cysts as completely or partially calcified. Furthermore, Taylor and others (2007) found that growth of hydatid cysts was progressive with arising of septae and budding of numerous daughter cysts.

In the current study, the significant decrease of portal vein diameter at 10th ICS could be attributed to the compression caused by hepatic cysts, as out of nine cases with hepatic cysts three cases showed cysts near the portal vein (Fig 2). In a previous study, Cebra and others (1997) described dilatation and stricture of intrahepatic vessels in cattle with hepatic lipidosis. In diseased sheep, the increased dorsal margin of the gall bladder at the 10th and 9th ICS might be due to displacement of the gall bladder and the pressure caused by liver cysts. In this work, although the circumference of the gall bladder was significantly decreased in sheep with liver cysts at the 9th ICS, it is difficult to conclude the size is lowered; this is because the circumference of the gall bladder changes daily as described previously (Braun and Hausammann 1992). Ultrasonography can be used in the diagnosis of hepatic CE because it allows for identification of the affected organ as well as the topographic relationship of the cysts.

In this study, the presence of one sheep as a false negative caused a lowering of the sensitivity of ultrasound; this could be attributed to the cysts in this sheep being located in the left lobe of the liver, an area not accessible to ultrasound detection (Lahmar and others 2007). The results in the present study showed a higher sensitivity of ultrasound for diagnosis of CE than previous results (sensitivity=57.36 per cent) obtained by Sage and others (1998). Such a difference may be due to variations in the number of animals that were false negatives. In the current study, as a result of owners' disagreement to the slaughtering of the rest of the infected animals (four sheep) for of economic and zootechnic reasons, they were treated with oral oxfendazole (Synthatec, 22.5 per cent solution) at 30 mg/kg/day (Dueger and others 1999). Unfortunately, these animals were discharged from the hospital and we did not have the opportunity to follow them up for evaluation of treatment.

CONCLUSIONS

Previous studies (Maxson and others 1996, Sage and others 1998, Lahmar and others 2007) suggested the use of ultrasonography for diagnosis of cystic echinococcosis, but they lacked detailed information about ultrasonographic features and alterations of sheep liver with hydatid cysts. Therefore, this study was planned to gain information about ultrasonographic findings of sheep livers with cystic echinococcosis, and furthermore, to assess the use of ultrasonography for diagnosis of such disease. In summary, although this study was conducted on a limited number of animals, the data obtained may contain some illuminating results. The findings show that hydatid cysts cause some alterations in liver features that could be easily recognised by ultrasound. In addition, ultrasonography is a sensitive method for diagnosis of hepatic CE; therefore, as an objective non-invasive practical tool, ultrasonography alone or in combination with testing of biochemical parameters reflecting liver

function could be helpful for diagnosis of CE of the liver in sheep.

Acknowledgements The authors gratefully acknowledge Professor Dr R Staufenbiel, deputy manager of the Ruminant Clinic, Free University of Berlin for provision of an ultrasound machine as a gift to carry out this study.

Contributors HAH participated in the design of the study, carried out the clinical assessments and data acquisition, performed data analyses and drafted the manuscript. ME participated in performing the study. Both authors read and approved the final manuscript.

Competing interests None.

Patient consent Obtained.

Provenance and peer review Not commissioned; externally peer reviewed.

REFERENCES

- Amman R., Eckert J. C. (1996) Echinococcus. *Gastrointestinal Endoscopy Clinics of North America* 25, 655–689
- Andreas A. (1997) The liver. In Eds Grainger R.J., Dixon A.K., Allison D.J. *Gainger & Alison's Diagnostic Radiology: A Textbook of Medical Imaging* 3rd edn. Churchill Livingstone, USA: Saunders. pp 1155–1160
- Barnes T., Hinds L., Jenkins D., Bielefeldt-Ohmann H., Lightowers M., Coleman G. (2011) Comparative pathology of pulmonary hydatid cysts in macropods and sheep. *Comparative Clinical Pathology* 144, 113–122
- Berhe G. (2009) Abattoir survey on cattle hydatidosis in Tigray region of Ethiopia. *Tropical Animal Health and Production* 41, 1347–1352
- Braun U., Hausammann K. (1992) Ultrasonographic examination of the liver in sheep. *American Journal of Veterinary Research* 53, 198–202
- Cebra C. K., Garry F. B., Getzy D. M., Fettman M. J. (1997) Hepatic lipidosis in anorectic, lactating Holstein cattle: a retrospective study of serum biochemical abnormalities. *Journal of Veterinary Internal Medicine/American College of Veterinary Internal Medicine* 11, 231–237
- Coles E. H. (1986) *Veterinary Clinical Pathology*. Philadelphia, USA: W.B. Saunders. pp 220–310
- Dueger E., Moro P., Gilman R. (1999) Oxfendazole treatment of sheep with naturally acquired hydatid disease. *Antimicrobial Agents and Chemotherapy* 56, 2263–2267
- Dunn O., Clark V. (2009) *Basic Statistics: A Primer for the Biomedical Sciences*. John Wiley and Sons, Inc. pp 40–165
- Eckert J., Deplazes P. (2004) Biological, epidemiological and clinical aspects of echinococcosis, a zoonosis of increasing concern. *Clinical Microbiology Reviews* 17, 107–135
- Eckert J., Deplazes P., Craig P. S., Gemmell M. S., Gottstein B., Heath D., Jenkins D. J., Kamiya M., Lightowers M. (2001) Echinococcosis in animals: clinical aspects, diagnosis and treatment. In: J. Eckert J., Gemmell, M. A., Meslin F.-X., Pawlowski Z. S. (ed.). *WHO/OIE Manual on echinococcosis in humans and animals: a public health problem of global concern*. Paris: World Organisation for Animal Health. pp 72–99
- Guarnera E. A., Zanzottera E. M., Pereyra H., Franco A. J. (2001) Ultrasonographic diagnosis of ovine cystic echinococcosis. *Veterinary Radiology & Ultrasound: the Official Journal of the American College of Veterinary Radiology and the International Veterinary Radiology Association* 42, 352–354
- Kassai T. (1999) *Veterinary Helminthology*. Oxford, UK: Butterworth-Heinemann/Reed Educational and Professional Publishing. p 260
- Khuroo M. S. (2002) Hydatid disease, current status and recent advances. *Annals of Saudi Medicine* 122, 56–64
- Khuroo M. S., Zargar S. A., Mahajan R. (1991) Echinococcus granulosus cysts in the liver: management with percutaneous drainage. *Radiology* 180, 141–145
- Lahmar S., Ben Chéhida F., Pétavy A. F., Hammou A., Lahmar J., Ghannay A., Gharbi H. A., Sarciron M. E. (2007) Ultrasonographic screening for cystic echinococcosis in sheep in Tunisia. *Veterinary Parasitology* 143, 42–49.
- Lightowers M. W., Rickard M. D., Honey R. D., Obendorf D. L., Mitchell G. F. (1984) Serological diagnosis of Echinococcus granulosus infection in sheep using cyst fluid antigen processed by antibody affinity chromatography. *Australian Veterinary Journal* 61, 101–108
- Lisa M. S. (1998) The liver, biliary system and pancreas. In Eds Juhl J.H., Crummy A.B., Kuhlman J.E. *Paul and Juhl's Essentials of Radiologic Imaging*. 7th edn. USA: Lippincott-Raven. pp 511–515
- Macpherson C. N.L. (1985) Epidemiology of hydatid disease in Kenya: a study of the domestic intermediate hosts in Masailand. *Transactions of the Royal Society of Tropical Medicine and Hygiene* 79, 209–217
- Macpherson C. N. L., Spoerry A., Zeyhle E., Romig T., Gorfe M. (1989) Pastoralists and hydatid disease: an ultrasound scanning prevalence survey of East Africa. *Transactions of the Royal Society of Tropical Medicine and Hygiene* 83, 243–247
- Maxson A. D., Wachira T. M., Zeyhle E. E., Fine A., Mwangi T. W., Smith G. (1996) The use of ultrasound to study the prevalence of hydatid cysts in the right lung and liver of sheep and goats in the Turkana. *International Journal for Parasitology* 26, 1335–1338
- Paksoy Y., Ödev K., Şahin M., Dik B., Ergül R., Arslan A. (2003) Percutaneous Sonographically Guided Treatment of Hydatid Cysts in Sheep: Direct Injection of Mebendazole and Albendazole. *Journal of Ultrasound in Medicine* 22, 797–803
- Pearson E. G. (2002) Diseases of the hepatobiliary system. In *Large Animal Internal Medicine*. 3rd edn. Ed Smith B. P. Missouri, USA: Mosby. pp 790–795
- Pugh D. G. (2002) *Sheep and Goat Medicine*. 1st edn. USA: Saunders. pp 104–250
- Safioles M. C., Misiakos E. P., Kouvaraki M., Stamatakos M., Manti C., Felekouras E. (2007) Hydatid disease of the liver: A continuing surgical problem. *Achieves of Surgery* 142, 690–691
- Sage A. M., Wachira T. M., Zeyhleh E. E., Weber E., Njoroge E., Smith G. (1998) Evaluation of diagnostic ultrasound as a mass screening technique for the detection of hydatid cysts in the liver and lung of sheep and goats. *International Journal of Parasitology* 28, 349–353
- Scott P. R., Sargison N. D. (2010) Ultrasonography as an adjunct to clinical examination in sheep. *Small Ruminant Research* 92, 108–119
- Szebeni A., Tolvaj G., Zalatnai A. (2006) Correlation of ultrasound attenuation and histopathological parameters of the liver in chronic diffuse liver diseases. *European Journal of Gastroenterology & Hepatology* 18, 37–42.
- Taylor M. A., Coop R. L., Wall R. L. (2007) *Veterinary Parasitology*, 3rd edn. UK: Blackwell. p 874.
- Tennant B. C., Center S. A. (2008) Chapter 13: hepatic function. In *Clinical Biochemistry of Domestic Animals*. 6th edn. Eds Kaneko J. J., Harvey J. W., Bruss M. L. New York, USA: Academic press. pp 379–412
- Torgerson P. R. (2003) Economic effects of Echinococcus. *Acta Tropica* 85, 113–118
- Torgerson P. R., Dowling P. M., Abo-Shehaha M. N. (2001) Estimating the economic effects of cystic Echinococcosis. Part 3: Jordan, a developing country with lower-middle income. *Annals of Tropical Medicine and Hygiene* 95, 595–603
- Von Sinner W. N. (1997) Imaging of cystic echinococcosis. *Acta Tropica* 67, 67–89
- WHO informal working group. (2003) International classification of ultrasound images in cystic echinococcosis for application in clinical and field epidemiological settings. *Acta Tropica* 85, 253–261
- World Organisation for Animal Health. (2008) Chapter 2.1.4. Echinococcosis/Hydatidosis. *Terrestrial Manual*, 175–189.