

Available online at www.sciencedirect.com

ScienceDirect

journal homepage: www.elsevier.com/locate/ihj

Research Letter

Atrial and ventricular septal defects device closure in a child in one session



A B S T R A C T

Keywords:

Atrial septal defect
Ventricular septal defect
Device closure

We describe a rare interventional procedure in which an 8-year-old girl underwent a successful device closure of both atrial septal and ventricular septal defects in one session.

© 2016 Cardiological Society of India. Published by Elsevier B.V. This is an open access article under the CC BY-NC-ND license. (<http://creativecommons.org/licenses/by-nc-nd/4.0/>)

1. Introduction

Percutaneous closure of atrial and ventricular septal defects has been well described in literature. However, simultaneously closing both defects in one session has been described only once in an infant¹ and the other is in an adult.²

We present this rare case report to highlight and emphasize that both the defects can be closed in one session. This in turn would save the patient from undergoing a repeat interventional procedure.

2. Case report

An 8-year-old girl child presented to us with incidentally detected murmur during a respiratory illness. Her past history was unremarkable. Clinically, her vital parameters were normal. Cardiovascular examination revealed soft S1, 3/6 pansystolic murmur at left lower sternal border, S2 was wide split, and normal intensity. Her echocardiography revealed 13.5 mm (maximum diameter) ostium secundum atrial septal defect (ASD) and 3.5 mm upper muscular ventricular septal defect (VSD). All the four chambers were dilated. Calculated Qp/Qs was 1.8:1 and pulmonary artery pressure was normal.

She was taken up for percutaneous device closure of both the defects after taking consent. A venous and an arterial access with 5-Fr sheath was secured. Injection heparin was given at 100 U/kg. A LV angiogram was done in left axial

oblique (LAO 60 and cranial 20) view. Angiogram showed a 3.5–4 mm upper muscular VSD filling the RV (Fig. 1). We first crossed the ASD using a 5-Fr multipurpose catheter. Then a 8-Fr Cook sheath (compatible with 15 mm Amplatzer

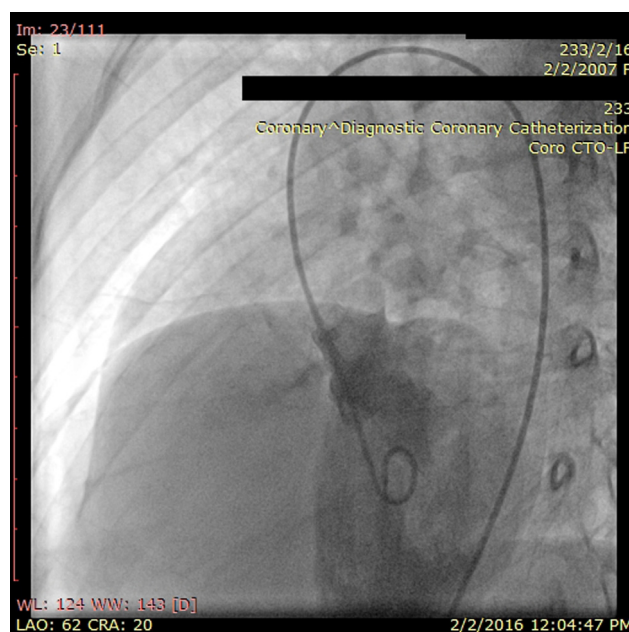


Fig. 1 – LV angiogram showing small upper muscular VSD filling the RV.

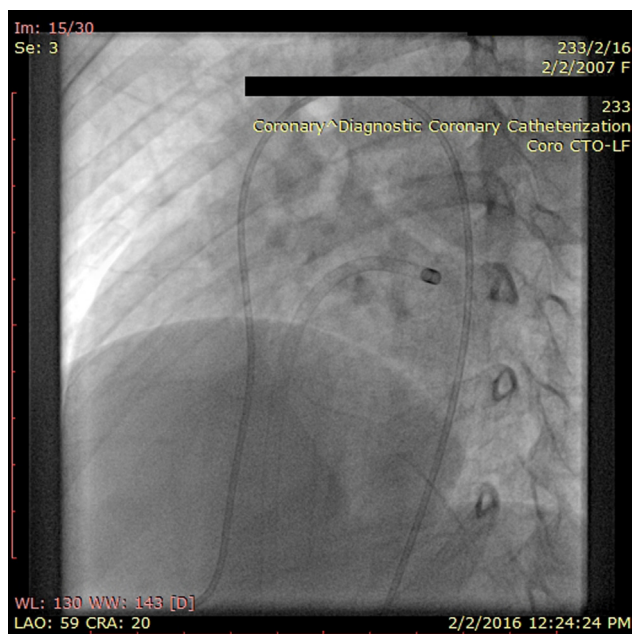


Fig. 2 – VSD crossed with 5-Fr right Judkins-guiding catheter.

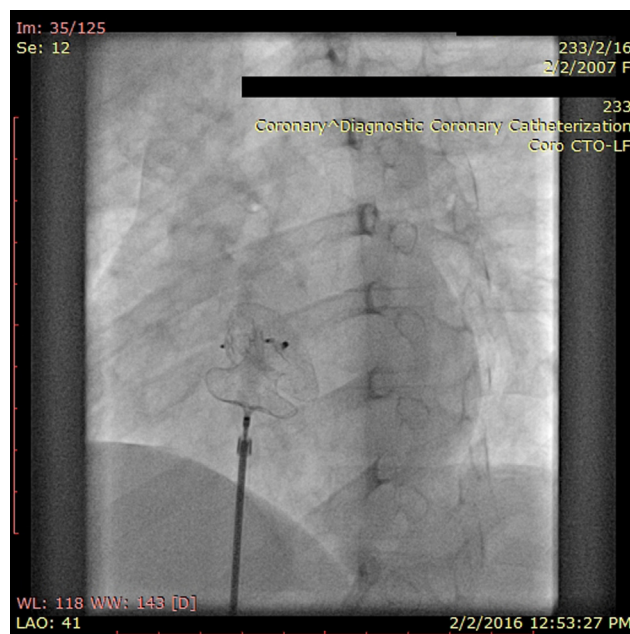


Fig. 4 – ASD device being deployed.

ASD device) was exchanged over 0.035 superstiff Amplatz wire placed in the left upper pulmonary vein. Then the VSD was crossed using a 5-Fr Judkins right guiding catheter over a 0.035 J tip hydrophilic wire (Fig. 2). The Judkins right guiding catheter was exchanged with 5-Fr ADO II delivery sheath. A 5 mm × 6 mm ADO II Amplatzer device was deployed by sheath pull back technique (Fig. 3). Device

placement was confirmed using 2D transthoracic echocardiography. Now a 15 mm Amplatzer ASD device was deployed under fluoroscopic and 2D transthoracic echocardiographic guidance (Fig. 4). The entire procedure was over in 45 min. Activated clotting time was more than 200 throughout the procedure; hence, heparin was not repeated. Postprocedure, the patient was discharged after 24 h of observation.

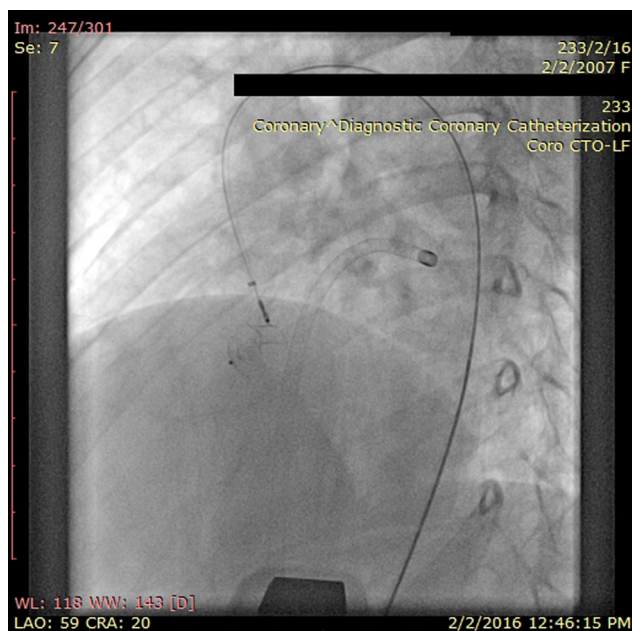


Fig. 3 – VSD device being deployed.

3. Discussion

Percutaneous device closure of ASD and VSD has been well described in literature, and has now become a standard procedure. However, combining both of these procedures in one session has been described only by Narin et al.¹ in a 4-month infant and Iyisoy et al.² in a 23-year-old adult. Former did the VSD device closure first making an arteriovenous loop and then did the ASD closure, while Iyisoy et al. closed the ASD first and then did the VSD closure from the arterial end. We first crossed the ASD, placed the cook sheath in the left upper pulmonary vein, and then closed VSD retrogradely. ASD was closed after the VSD device deployment. We did this as we were skeptical of disturbing the ASD device while parking the wire in pulmonary artery.

Combining the two device closures in one setting in a pediatric patient is difficult. Mostly balloon valvuloplasties have been described with ASD, VSD, and PDA closures.³⁻⁵ Ours is only the third case report of ASD and VSD device closure in one session. This report highlights that this type of combined procedure can be done and would save one interventional procedure for the patient.

Conflicts of interest

The authors have none to declare.

REFERENCES

1. Narin N, Pamukcu O, Baykan A, Sunkak S, Uzum K. Percutaneous ASD and VSD closure of 4-month-old infant in the same session. *Int J Cardiovasc Acad.* 2015;1:59–61.
2. Iyisoy A, Demirkol S, Celik T, Balta S. Percutaneous transcatheter closure of atrial and ventricular septal defect in the same session. *Arch Turk Soc Cardiol.* 2014;42:314.
3. Song ZY, Shu MQ, Hu HY, et al. Clinical efficiency and safety analysis of transcatheter interventional therapy for compound congenital cardiovascular abnormalities. *Clin Cardiol.* 2007;30:518–521.
4. Gupta M, Juneja R, Saxena A. Simultaneous device closure of muscular ventricular septal defect and pulmonary valve balloon dilatation. *Catheter Cardiovasc Interv.* 2003;58:545–547.
5. Ho CL, Fu YC, Jan SL, Lin MC, Chi CS, Hwang B. Combined transcatheter closure of atrial septal defect and patent ductus arteriosus: report of two cases. *Acta Paediatr Taiwan.* 2006;47:197–199.

V. Kumar*
Pediatric Cardiologist, Army Hospital R&R, India

A. Banerjee
Deputy Commandant and Consultant Cardiology, Army Hospital R&R, India

N. Aggarwal
Consultant and HOD Cardiology, Army Hospital R&R, India

S. Garg
A. Swamy
Consultant Cardiology, Army Hospital R&R, India

*Corresponding author
E-mail address: Vk3532@gmail.com (V. Kumar)

Available online 29 March 2016

<http://dx.doi.org/10.1016/j.ihj.2016.03.015>
0019-4832/

© 2016 Cardiological Society of India. Published by Elsevier B.V.
This is an open access article under the CC BY-NC-ND license.
(<http://creativecommons.org/licenses/by-nc-nd/4.0/>)