

Molecular detection of polycystic kidney disease in Persian and Persian-related breeds in Iran

Ali Moazezi Ghavivhelm¹, Shahram Jamshidi¹,
Iraj Ashrafi Tamai² and Mahsa Zangisheh³

Journal of Feline Medicine and Surgery Open Reports
1–4

© The Author(s) 2022

Article reuse guidelines:

sagepub.com/journals-permissions

DOI: 10.1177/20551169211070991

journals.sagepub.com/home/jfmsopenreports

This paper was handled and processed by the European Editorial Office (ISFM) for publication in *JFMS Open Reports*



Abstract

Objectives This study was aimed at detecting feline autosomal dominant polycystic kidney disease in a population of Persian and Persian-related breeds by a molecular method in Iran.

Methods Buccal swab samples were collected from 47 cats and examined with a touchdown PCR method. Additionally, partial sequencing was performed in two cats with bilateral renal cysts.

Results Twenty-two cats (46.8%) were diagnosed as heterozygous for this mutation. Sequence analysis of two cats showed C to A point mutation in the *PKD1* gene, as in previous studies.

Conclusions and relevance Prevalence of this disease is high in Iran, highlighting the need for molecular screening tests before including cats in breeding programmes.

Keywords: Polycystic kidney disease; Persian cats; touchdown PCR; Iran

Accepted: 17 December 2021

Introduction

Autosomal dominant polycystic kidney disease (ADPKD) is one of the most common life-threatening inherited disorders in cats, especially in Persian and Persian-related breeds, with a prevalence of 16–49% worldwide.¹ Homozygous and heterozygous mutations are two forms of expression of feline ADPKD. Fetuses homozygous for the mutation will die before birth, whereas heterozygous cats remain clinically normal until failure of renal function occurs after a number of years (usually after 7 years of age).^{2,3} Affected cats have variable and unpredictable disease progression and severity.⁴

The marked clinical and morphological similarity of feline ADPKD to human disease and its dominant mode of inheritance suggest that this disease represents a very good model for ADPKD in humans.⁵ The point mutation (C to A transversion), at sequence position c.10063 in exon 29 of the *PKD1* gene, results in a premature stop codon at amino acid position 3284 of the polycystin-1 (PC1) protein. The PC1 protein is encoded by the *PKD1* gene and with the early occurrence of this stop codon into the corresponding mRNA transcript,

about 25% of the C-terminus of this protein will not be produced.⁶ PC1 is a transmembrane protein that interacts with other proteins to control tube lumen size through the regulation of a number of cell behaviours; it plays a key role in tubule construction during kidney development and is likely involved in tubular renovation in adult life.⁷ By impairing the function of the PC1 protein, proliferation and apoptosis of renal tubular epithelial cells are enhanced and multiple fluid-filled cysts will form in the cortex and medulla of both

¹Department of Internal Medicine, Faculty of Veterinary Medicine, University of Tehran, Tehran, Iran

²Department of Microbiology, College of Veterinary Medicine, University of Tehran, Tehran, Iran

³Department of Surgery and Radiology, Faculty of Veterinary Medicine, University of Tehran, Tehran, Iran

Corresponding author:

Ali Moazezi Ghavivhelm DVM, DVSc, Department of Internal Medicine, Faculty of Veterinary Medicine, University of Tehran, Qareeb St, Azadi Ave, Tehran, 14155-6453, Iran
Email: ali.moazezi@ut.ac.ir



kidneys and occasionally in the liver, pancreas and uterus at birth.⁸ The chronic progressive nature of the number and size of these cysts causes irreversible damage to the renal parenchyma and can lead to chronic kidney disease (CKD) and renal failure.⁹

Renal imaging was the most prominent diagnostic method until 2004 when Lyons and colleagues discovered the mutation responsible for the feline ADPKD, which was a turning point in the development of diagnostic molecular methods. Unlike humans, who have multiple genes responsible for ADPKD (*PKD1*, *PKD2*, *GANAB* and *DNAJB11*), in cats only a mutation in the *PKD1* gene responsible for ADPKD is recognised.^{10,11} There is no specific treatment for ADPKD; most treatment protocols are supportive and symptomatic and renal transplantation is inevitable.

No information is available on *PKD1* gene sequencing in cats with ADPKD in Iran. This study aimed to investigate the prevalence of ADPKD in Persian and Persian-related breeds for the first time in Iran by a molecular method, the touchdown PCR, which is a low-cost and fast method, and identify, with specific primers, a point mutation that causes this disease.

Materials and methods

Sample collection

Forty-seven clinically healthy Persian and Persian-related cats (aged between 2 months and 7 years old) were randomly selected from the Veterinary Hospital of Small Animals at the University of Tehran. Buccal swab samples were collected for genetic analysis and placed in sterile microtubes containing 1 cc of 0.9% saline and stored at -70°C until DNA extraction.

Two cats with signs of polyuria/polydipsia were examined with ultrasound examination (linear probe 7.5MHz, Philips, Affinity 70).

DNA extraction

DNA for touchdown PCR was extracted using a commercial kit (MBST Iran).

Before testing for the *PKD1* gene of interest, samples were tested with a PCR that detects the glyceraldehyde-3-phosphate dehydrogenase (*GAPDH*) gene, to verify DNA quality by using *GAPDH*-F (CCTTCATTGACCTCAACTACAT) and *GAPDH*-R (CCAAAGTTGTCATGGATGACC) primers¹² producing a 400 base pair (bp) fragment in all samples.

Touchdown PCR

A touchdown PCR was performed to detect the *PKD1* mutant gene (GenBank accession number AY612847) using PKD-F3 (AGAGGCAGACGAGGAGCACT) and PKD-R2 (GCCTCGTGGAGAAGGAGGT) primers.¹³ The end of 3' reverse primer has a single nucleotide that binds

to the mutant sequence template and amplification was performed only in the presence of mutant sequences.

The final mix volume was 25 μl , containing 1 \times PCR buffer, 1 μl of primers, 2 mM of MgCl_2 , 0.25 mM of each deoxyribonucleotide triphosphate (Sinaclone), 1 U of Taq DNA polymerase (Sinaclone) and 5 ng of DNA sample. The initial denaturation step was 5 mins in duration at 94°C , followed by 10 cycles of 1 min at 94°C , 1 min at 67°C (decreasing 1°C per cycle) and 1 min at 72°C , followed by 30 cycles of 1 min at 94°C , 1 min at 59°C and 1 min at 72°C , with a final extension step of 10 mins at 72°C (T100 Thermal Cycler; Bio-Rad). The reaction products were analysed by electrophoresis in 1.5% agarose gels in Tris acetate EDTA buffer, stained by ethidium bromide and visualised under UV light by producing a 277 bp fragment in samples positive for the *PKD1* mutant gene.¹⁴

Partial sequencing

To obtain positive controls, PCR products from DNA from two cats with bilateral renal cysts (about 6 years old) were sequenced in the forward and reverse direction. Bioneer Company performed sequencing reactions and Sanger dideoxy sequencing methods were used to obtain these sequences. The sequences were initially analysed using the NCBI/BLAST/blastn suite (https://blast.ncbi.nlm.nih.gov/Blast.cgi?CMD=Web&PAGE_TYPE=BlastHome). Multiple alignments were performed with the Mega-6 package using the neighbor-joining method with 1000 bootstrap replicates and a cladogram was drawn by likelihood method with the Kimura 2 parameter statistical model.

Results

Touchdown PCR assay

Twenty-two cats (46.8%) were diagnosed as heterozygous for the mutant gene by PCR (Figure 1).

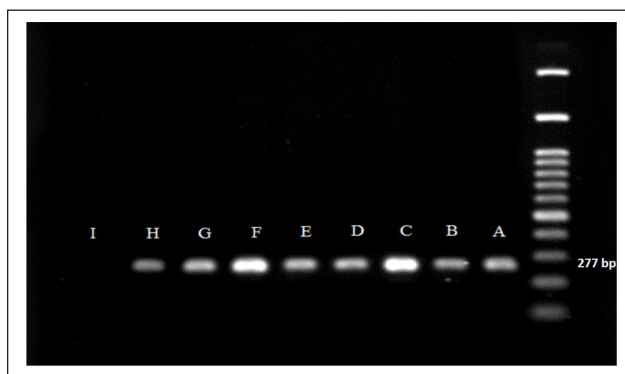

Figure 1 Agarose gel electrophoresis stained by ethidium bromide producing 277 base pair fragments for *PKD1* mutant genes (A and B = positive control; C to H = *PKD1* mutant genes; I = negative control)

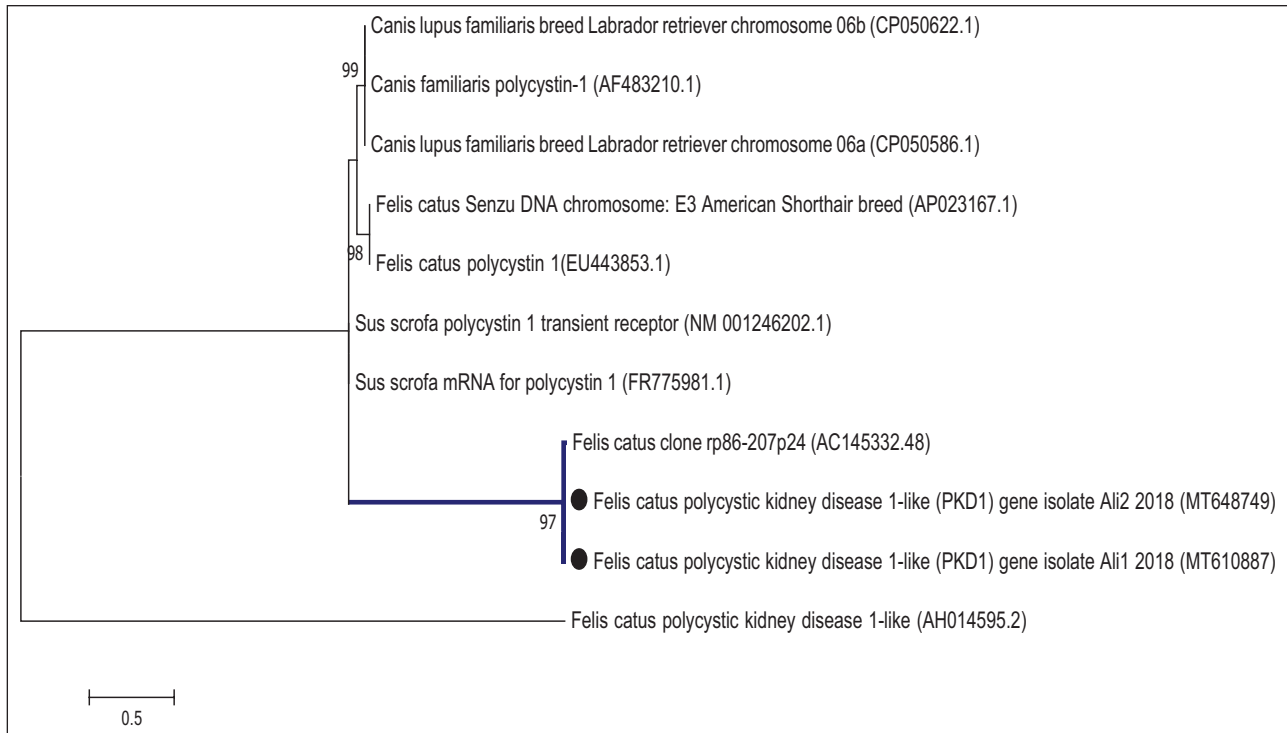


Figure 2 Cladogram of *PKD1* gene drawn by the likelihood method with the Kimura 2 parameter statistical model and bootstrap 1000

Sequencing analysis

The sequences derived were analysed using the BLAST search program (<http://blast.ncbi.nlm.nih.gov/Blast.cgi>). The partial *PKD1* mutant gene sequences derived from this study were submitted to GenBank with accession numbers MT648749 and MT610887.

Phylogenetic analysis of *PKD1* mutant genes

The phylogenetic tree representing the genetic relationships of the *PKD1* mutant gene sequences showed that MT648749 and MT610887 were 100% identical. Based on the phylogenetic analysis of the mutant genes, MT648749 and MT610887 clustered with *Felis catus* clone rp86-207p24 (AC145332.48). We observed 99.83% nucleotide sequence identity (the highest) for the *PKD1* mutant genes between our isolates and *Felis catus* clone rp86-207p24 (AC145332.48) (Figure 2).

Discussion

The prevalence of ADPKD, especially in Persian and Persian-related breeds, has been determined in countries such as the UK (49%), Germany (43%), Australia (43%), France (42%), Slovenia (36%), Italy (41%) and Japan (40%). This study aimed to detect the prevalence of ADPKD in Persian and Persian-related breeds by molecular testing for the first time in Iran. The prevalence of ADPKD in this study was 46.8%, although our sample size was quite small ($n = 47$). This may be due to the lack of regular screening before including a cat in a breeding programme.

Additionally, to obtain positive control samples for PCR and analyse the *PKD1* mutant gene, PCR products of two Persian cats with polycystic kidney disease were partially sequenced for the first time in Iran and the results, as in previous studies, showed a C to A transversion mutation in the *PKD1* gene. The sequencing of the *PKD1* mutant gene of these two cats, which were not siblings, were 100% identical to each other, and they were also 99.38% identical (sharing a single clade) to a sequence registered in the gene bank of the complete genome of a cat of unknown breed from the USA (Figure 2). Using the touchdown PCR method developed by Scaloni et al,¹⁴ we obtained the specific band related to the mutation in these 22 cats (277 bp).

Unlike in humans with ADPKD, in whom numerous mutations in different genes have been documented, in cats only a single casual point mutation in exon 29 at position c.00163 of the *PKD1* gene has been described to date.⁹ In studies conducted by Kappe et al,¹⁵ Bonazzi et al¹⁶ and Lee et al,¹³ some cats that were diagnosed with polycystic kidney disease by ultrasonography did not have the point mutation within exon 29. This indicates that mutation in other genes, like humans, may be responsible for ADPKD in cats. Ultrasound by a skilled ultrasonographer cannot detect polycystic kidney disease until about 3 months of age. Therefore, the molecular assay offers early diagnosis as well as diagnosis in areas where ultrasound is not readily available.

Since Persian cats are currently the best human model for the autosomal dominant form of the disease, it can be

said that humans can also be a good model for this disease in cats. This could pave the way for more detailed genetic studies in cats with polycystic kidneys (especially young cats) and those without the point mutation in the *PKD1* gene to investigate the possibility of other unknown genetic mutations. However, acquired causes of kidney cysts include obstruction owing to nephrolithiasis, lymphoma, chronic kidney disease with interstitial nephritis at older ages and drugs such as diphenylamine.^{4,15,17}

Conclusions

The only way to eradicate or decrease the prevalence of this disease in the future is to exclude these heterozygous animals from breeding programmes. To help achieve this aim, low cost and fast screening tests such as touchdown PCR are needed.

Acknowledgements The authors especially thank Dr Zahra Ziafati Kafi, who kindly contributed to this study.

Conflict of interest The authors declared no potential conflicts of interest with respect to the research, authorship, and/or publication of this article.

Funding The authors disclosed receipt of the following financial support for the research, authorship, and/or publication of this article: this study was funded by the University of Tehran, Faculty of Veterinary Medicine.

Ethical approval The work described in this manuscript involved the use of non-experimental (owned or unowned) animals. Established internationally recognised high standards ('best practice') of veterinary clinical care for the individual patient were always followed and/or this work involved the use of cadavers. Ethical approval from a committee was therefore not specifically required for publication in *JFMS Open Reports*. Although not required, where ethical approval was still obtained, it is stated in the manuscript.

Informed consent Informed consent (verbal or written) was obtained from the owner or legal custodian of all animal(s) described in this work (experimental or non-experimental animals, including cadavers) for all procedure(s) undertaken (prospective or retrospective studies). No animals or people are identifiable within this publication, and therefore additional informed consent for publication was not required.

References

- Guerra JM, Cardoso NC, Daniel AG, et al. **Prevalence of autosomal dominant polycystic kidney disease in Persian and Persian-related cats in Brazil.** *Braz J Biol* 2020; 81: 392–397.
- Young AE, Biller DS, Herrgesell EJ, et al. **Feline polycystic kidney disease is linked to the *PKD1* region.** *Mamm Genome* 2005; 16: 59–65.
- Wills SJ, Barrett EL, Barr FJ, et al. **Evaluation of the repeatability of ultrasound scanning for detection of feline polycystic kidney disease.** *J Feline Med Surg* 2009; 11: 993–996.
- Cannon MJ, Barr FJ, Rudolf H, et al. **Prevalence of polycystic kidney disease in Persian cats in the United Kingdom.** *Vet Rec* 2001; 149: 409–411.
- Eaton KA, Biller DS, DiBartola SP, et al. **Autosomal dominant polycystic kidney disease in Persian and Persian-cross cats.** *Vet Rec* 1997; 34: 117–126.
- Lyons LA, Biller DS, Erdman CA, et al. **Feline polycystic kidney disease mutation identified in *PKD1*.** *J Am Soc Nephrol* 2004; 15: 2548–2555.
- Zhou J. **Polycystins and primary cilia: primers for cell cycle progression.** *Annu Rev Physiol* 2009; 71: 83–113.
- Domanjko Petrič A, Černec D and Cotman M. **Polycystic kidney disease: a review and occurrence in Slovenia with comparison between ultrasound and genetic testing.** *J Feline Med Surg* 2008; 10: 115–119.
- Lyons LA. **Feline genetics: clinical applications and genetic testing.** *Top Companion Anim Med* 2010; 25: 203–212.
- Cornec-Le Gall E, Olson RJ, Besse W, et al. **Monoallelic mutations to *DNAJB11* cause atypical autosomal-dominant polycystic kidney disease.** *Amer J Hum Genet* 2018; 102: 832–844.
- Lu H, Galeano MC, Ott E, et al. **Mutations in *DZIP1L*, which encodes a ciliary-transition-zone protein, cause autosomal recessive polycystic kidney disease.** *Nat Genet* 2017; 49: 1025–1034.
- Birkenheuer AJ, Levy MG and Breitschwerdt EB. **Development and evaluation of a seminested PCR for detection and differentiation of *Babesia gibsoni* (Asian genotype) and *B. canis* DNA in canine blood samples.** *J Clin Microbiol* 2003; 41: 4172–4177.
- Lee YJ, Chen HY, Wong ML, et al. **Molecular detection of autosomal-dominant feline polycystic kidney disease by multiplex amplification refractory mutation system polymerase chain reaction.** *J Vet Diagn Invest* 2010; 22: 424–428.
- Scalon MC, Da Silva TF, Aquino LC, et al. **Touchdown polymerase chain reaction detection of polycystic kidney disease and laboratory findings in different cat populations.** *J Vet Diagn Invest* 2014; 26: 542–546.
- Kappe EC, Hecht W, Gerwing M, et al. **Polycystic kidney disease in the German population of Persian cats. A comparative study of ultrasonographical examination and genetic testing.** *Tierarztl* 2005; 33: 413–418.
- Bonazzi M, Volta A, Gnudi G, et al. **Comparison between ultrasound and genetic testing for the early diagnosis of polycystic kidney disease in Persian and Exotic Shorthair cats.** *J Feline Med Surg* 2009; 11: 430–434.
- Bergmann C. **ARPKD and early manifestations of ADPKD: the original polycystic kidney disease and phenocopies.** *Pediatr Nephrol* 2015; 30: 15–30.