


Dural Follicular Lymphoma: Case Report and Literature Review

Journal of Investigative Medicine High Impact Case Reports
Volume 9: 1–5
© 2021 American Federation for Medical Research
DOI: 10.1177/23247096211056768
journals.sagepub.com/home/hic


Ellery Altshuler, MD¹, Raymond Richhart, MD¹, Umar Iqbal, MD¹, and Joanna Chaffin, MD¹

Abstract

Follicular lymphoma (FL) usually has an indolent course and presents with painless, waxing and waning lymphadenopathy in the absence of systemic symptoms. It is uncommon for FL to present outside of lymph nodes, although it can develop in the gastrointestinal tract, skin, thyroid, and testes. Central nervous system (CNS) involvement in FL is rare. Most CNS lymphomas are diffuse large B-cell lymphoma, although Burkitt lymphoma, lymphoblastic lymphoma, and peripheral T-cell lymphoma are also observed. These tumors usually involve white matter but may also involve gray matter. Lymphomas of the dura are very uncommon and are usually mucosa-associated lymphoid tissue lymphomas. Here, we present a case of FL of the dura arising in a 62-year-old woman that was responsive to chemotherapy. According to a literature review, there have been 15 previously reported cases of FL of the dura. Dural FL has been most frequently treated with radiation and chemotherapy. Patients were still alive in all cases in which follow-up was reported. Although the sample size is small, these data suggest that dural FL, like other forms of FL, is an indolent disease that is associated with prolonged survival despite usually being incurable.

Keywords

central nervous system, dural follicular lymphoma, primary lymphoma

Case Presentation

A 62-year-old woman with a past medical history of coronary artery disease presented to her primary care physician with a 3-month history of worsening scalp pain and an enlarging, mildly tender palpable bump in the parietal area. She reported vision changes described as a darkening of her visual fields and severe, pressure-like headaches that occurred 3 to 4 times a week. She also reported worsening fatigue but denied fevers, chills, or night sweats. Magnetic resonance imaging demonstrated a 2.3 × 1.0 × 2.7 cm dural-based mass in the left frontoparietal region with extension into the gyri of the adjacent brain parenchyma (Figure 1). Notably, there were no abnormalities of the adjacent bone.

A left craniotomy was performed and biopsies were taken of the mass. Flow cytometry analysis detected a population of abnormal CD19(+)/CD20(+) B cells with dim, lambda light chain restriction and homogenous expression of CD10. Microscopic analysis demonstrated a nodular lymphocytic infiltrate consisting of centrocytes with many centroblasts (greater than 15 per high power field), diagnostic of follicular lymphoma (FL), grade IIIA (Figure 2). Immunohistochemical stains showed predominantly CD20(+)/Pax-5(+) B cells that were reactive for both Bcl-2 and Bcl-6 (Figure 3). The Ki-67 proliferation index was as high as 70% in some nodules. Cytogenetic testing

revealed an abnormal female karyotype (46,XX,add(1)(p34.1),t(2;6)(q31;q21),del(6)(q21),t(14;18)(q32.3;q21.3)[10]/46,XX[10]) with fluorescent in situ hybridization confirming the presence of *IGH/BCL2* gene fusion rearrangement. Cells were negative for *MYC* gene locus rearrangement. Next-generation sequencing analysis was notable for loss of function mutations of the *CREBBP* and *KMT2D* genes. Computed tomography (CT) scans of the chest, abdomen, and pelvis were notable for bilateral hilar adenopathy with nodes up to 12 mm in size, suggestive of disease spread.

The patient was treated for grade IV stage IIIA FL with methotrexate, rituximab, cyclophosphamide, doxorubicin, vincristine, and prednisone (MR-CHOP), which was generally well tolerated. The CT scan after cycle 3 showed good disease response with reduced mediastinal lymphadenopathy

¹University of Florida, Gainesville, USA

Received August 30, 2021. Revised September 28, 2021. Accepted October 12, 2021.

Corresponding Author:

Ellery Altshuler, Department of Internal Medicine, College of Medicine, University of Florida, PO Box 100277, 1600 SW Archer Road, Gainesville, FL 32610, USA.
Email: ElleryAltshuler@gmail.com



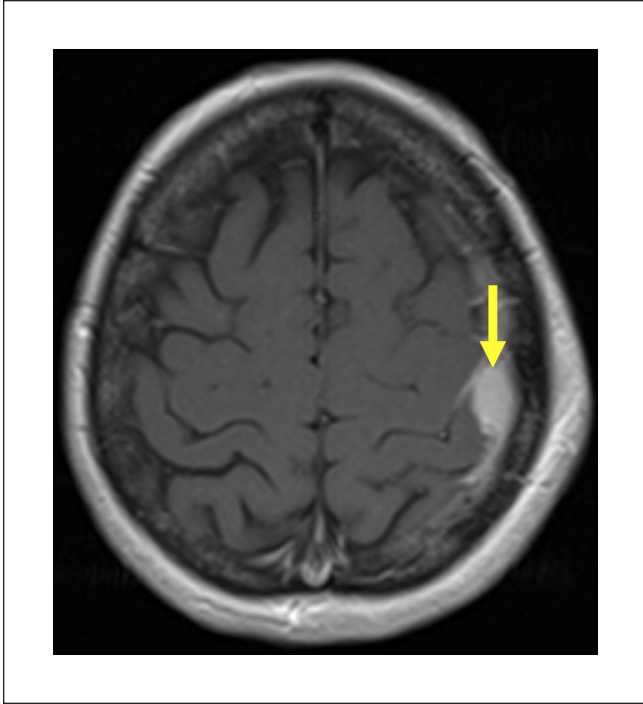


Figure 1. Coronal (left) and axial (right) magnetic resonance images demonstrating a $2.3 \times 1.0 \times 2.7$ cm dural-based mass (yellow arrows) in the left frontoparietal region with associated thickening and enhancement of the adjacent dura. There is an extracranial component to the mass in the adjacent soft tissues without visible abnormalities of the bone. In addition, there are linear extension into the gyri of the adjacent brain parenchyma with an associated focal area of subcortical edema in the lateral aspect of the postcentral gyrus.

and no residual brain lesion. Follow-up scan after cycle 6 showed slightly reduced hilar lymphadenopathy.

Discussion

Follicular lymphoma is the second most common type of non-Hodgkin lymphoma after diffuse large B-cell lymphoma (DLBCL).¹ There are about 15 000 cases of FL in the United States and Europe per year.² Median age of diagnosis is 65 years.³ Pathogenesis normally involves overexpression a translocation between chromosomes 14 and 18. This translocation leads to overexpression of the leukemia/lymphoma 2 (*BCL2*) oncogene.⁴

FL usually presents with painless, waxing and waning lymphadenopathy in the absence of systemic symptoms despite widespread disease; basic labs are often normal, and just a fifth of patients report weight loss or B symptoms.⁵ It is uncommon for FL to present outside of the lymph nodes.⁶ The most common sites of primary extranodal FL are the gastrointestinal tract (often the second portion of the duodenum), skin, thyroid, and testes. Central system involvement (CNS) involvement in FL is rare.⁷ Meanwhile, the vast majority of CNS lymphomas are DLBCL, although Burkitt lymphoma, lymphoblastic lymphoma, and peripheral T-cell lymphoma not otherwise specified are also observed.⁸ These tumors usually involve white matter but may also involve gray matter.⁹ Lymphomas of the dura are very rare and are usually mucosa-associated lymphoid tissue (MALT) lymphomas.¹⁰

Dura mater is a dense layer of irregular connective tissue that serves as the outermost layer of the meninges, sitting

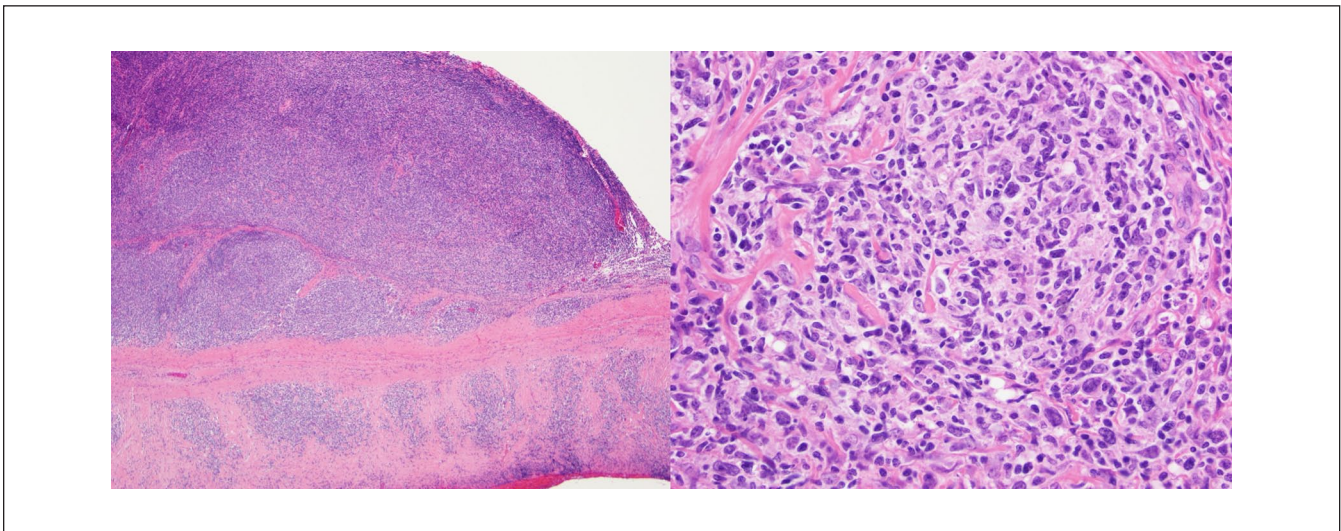


Figure 2. (A) The dura demonstrates infiltration of fibrous tissue by a vaguely nodular lymphocytic infiltrate (hematoxylin and eosin, $40\times$ magnification). (B) Closer inspection of 1 of the nodular areas reveals the infiltrate to consist of a mixture of small lymphocytes with cleaved nuclei (centrocytes) and large lymphocytes with multiple nucleoli (centroblasts) (hematoxylin and eosin, $400\times$ magnification).

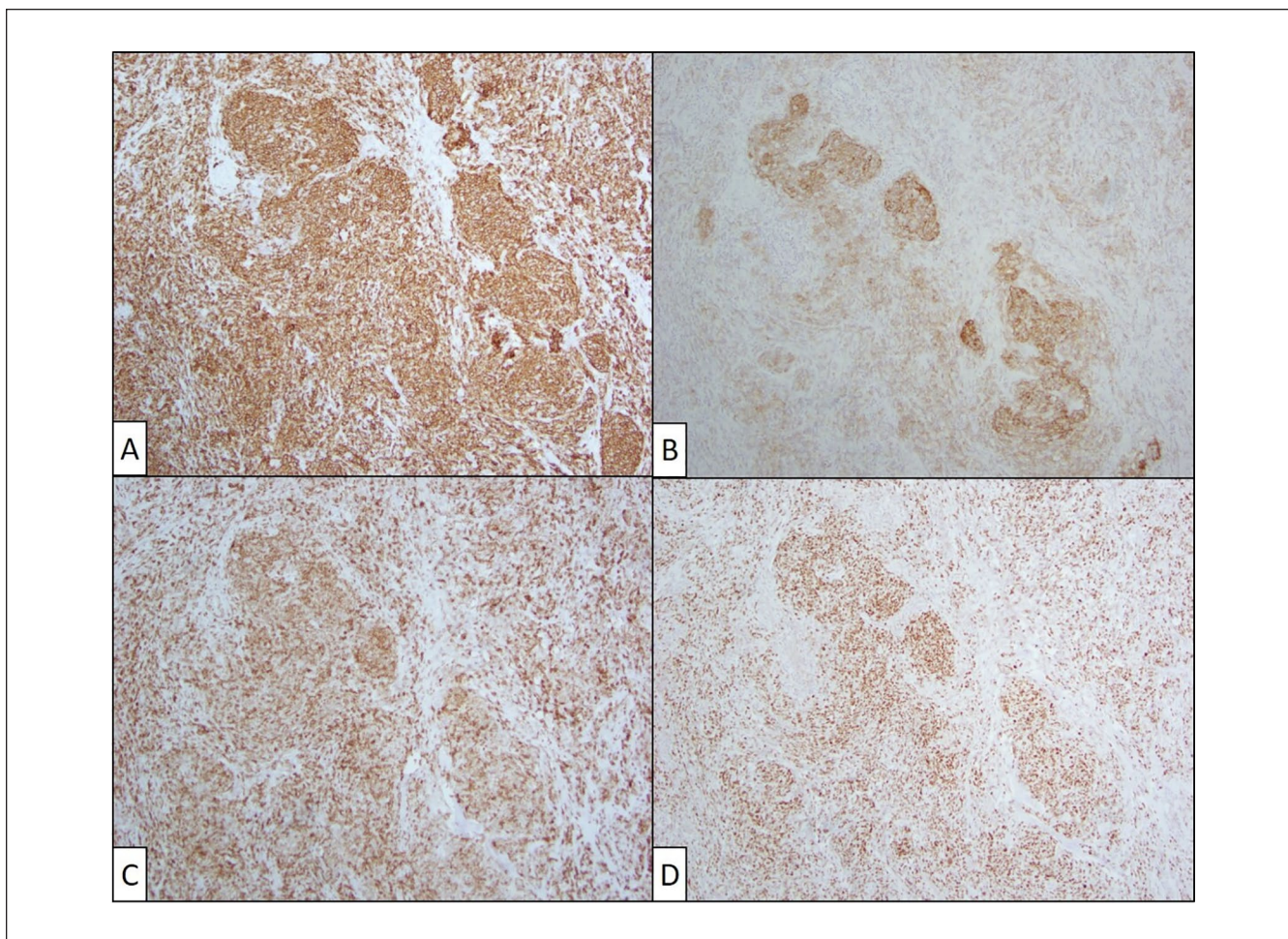


Figure 3. (A) Lymphocytes express CD20, consistent with B cells (CD20 immunohistochemical stain, 200 \times magnification). (B) CD21 highlights retained follicular dendritic cell meshworks (CD21 immunohistochemical stain, 200 \times magnification). B cells show aberrant co-expression of (C) Bcl-2 and (D) Bcl-6 (Bcl-2 and Bcl-6 immunohistochemical stains, 200 \times magnification). The overall morphological and immunophenotypic findings support the diagnosis of follicular lymphoma.

atop arachnoid and pia mater. Meningiomas are by far the most common dural tumor. Other dural tumors include solitary fibrous tumors, sarcomas, and metastases, as well as less common tumors such as Ewing sarcoma, gliosarcomas, and xanthoastrocytomas.¹¹ There have been at least 105 cases of dural MALT lymphoma described in the literature.¹² The FL of the dura is less common still; in our literature review, we identified 15 such cases with convincing pathological date consistent with a diagnosis of dural FL (Table 1).

Conclusion

Median age of patients with dural lymphoma was 56.7, close to the median age of 65 in all patients with FL.²⁵ Common anatomical locations included dura overlying the frontal area

(6) spinal column (4), and cavernous sinus (2). Systemic involvement was reported in 8 cases; these included lymph nodes in 7 cases, bony metastases in 2, and bone marrow in 1. Of the 14 cases (including our patient) in which the grade of the lymphoma was reported, 10 were low grade (I or II), 2 were IIIA, 1 was IIIB, and 1 was IV. Of the 14 cases (including ours) in which treatment was reported, 3 patients received radiation only, 10 received radiation and chemotherapy, and 1 patient received chemotherapy only. Eleven cases reported outcomes at least 6 months after diagnosis and, in all cases, patients were alive. Patients were still alive in all cases in which follow-up was reported. Although the sample size is small, these data suggest that dural FL, like other forms of FL, is an indolent disease that is associated with prolonged survival despite being incurable.

Table 1. Case Reports of Follicular Lymphoma of the Dura With Associated Size, Histology, Treatment, and Outcome.

Age, sex	Location	Systemic involvement	Size	Histology	Treatment	Outcome	Citation
75, F	Left frontal area with extension into skull and subgaleal space	None	Not reported	Low-grade FL	Radiation + Vincristine + CAP	In remission 3 years later	Isla et al ¹³
33, M	Left frontal area and lateral to cavernous sinus	Not reported	Not reported	Not reported	Radiation + CHOP	Not reported	Subramanian et al ¹⁴
57, F	Right sphenoid wing	None	6 × 4 × 6 cm	Not reported	Patient declined treatment	Alive at 6 months	Hodgson et al ¹⁵
67, F	Left cerebellar area	None	Not reported	I	Radiation only	NED at 18 months	Beriwal et al ¹⁶
70, M	Spinal canal	None	Not reported	II	Not reported	Not reported	Alameda et al ¹⁷
41, M	Left posterior frontal area with invasion of temporalis muscle and bone	Pelvic and mesenteric LAD	5.4 × 2.4 × 1.8 cm	I	Radiation + chemotherapy	Alive at 8 months	Hamilton et al ¹⁸
72, F	Right posterior temporal lobe, with parenchymal invasion	Bone marrow	4 × 4 × 2 cm	I	Radiation	NED at 12 months	Low and Allen ⁸
70, F	Midline, with invasion of the subgaleal, falx, and cavernous sinus	Cervical LAD	Not reported	IIIB	Radiation + MR-CHOP	NED at 12 months	Riccioni et al ¹⁹
48, M	Left temporoparietal area	Iliac LAD, bony metastases	1.5 cm	IV	Radiation + R-CHVP, IT aracycline, methylprednisolone, and methotrexate	Asymptomatic at 3 years	Peltier et al ²⁰
72, F	T7-T8	None	Not reported	I-II	Radiation + chemotherapy, unspecified	NED at 12 months	Mneimneh et al ²¹
74, M	T11-T6	None	Not reported	I-II	Radiation + chemotherapy, unspecified	NED at 2 years	Mneimneh et al ²¹
65, F	Cranium, unspecified	None	Not reported	I-II	Radiation	NED at 6 months	Tandon et al ²²
29, M	L5 to S2 level	Bone marrow	5.7 × 2.1 × 1.8 cm	II	R-CHOP + maintenance rituximab	Not reported	Cho et al ²³
31, M	Right frontotemporal area	Cervical LAD	Not reported	IIIA	R-CHOP	NED at 12 months	Yamaguchi et al ⁷
41, F	Right parietal area with invasion of brain parenchyma	Periceliac and para-aortic LAD	Not reported	I-II	Radiation + MR-CHOP, maintenance R for 2 years	NED at 2 years	MacCann et al ²⁴
62, F	Left frontoparietal region with parenchymal invasion	Hilar LAD	2.3 × 1.0 × 2.7	IIIA	Radiation + MR-CHOP	NED in dura, minimal residual hilar lymphadenopathy	Our case

Abbreviations: FL, follicular lymphoma; CAP, cisplatin, adriamycin, prednisone; CHOP, cyclophosphamide, hydroxydaunomycin (doxorubicin), oncovin (vincristine), prednisone; NED, no evidence of disease; LAD, lymphadenitis; MR-CHOP, methotrexate, rituximab, cyclophosphamide, hydroxydaunomycin (doxorubicin), oncovin (vincristine), prednisone; IV, intravenous; R-CHVP, rituximab, cyclophosphamide, adriamycin, vincristine, and prednisone; IT, intrathecal; R-CHOP, rituximab, cyclophosphamide, hydroxydaunomycin (doxorubicin), oncovin (vincristine), prednisone.

Declaration of Conflicting Interests

The author(s) declared no potential conflicts of interest with respect to the research, authorship, and/or publication of this article.

Funding

The author(s) received no financial support for the research, authorship, and/or publication of this article.

Ethics Approval

Our institution does not require ethical approval for reporting individual cases or case series.

Informed Consent

Verbal informed consent was obtained from the patient(s) for their anonymized information to be published in this article.

References

- Chihara D, Nastoupil LJ, Williams JN, Lee P, Koff JL, Flowers CR. New insights into the epidemiology of non-Hodgkin lymphoma and implications for therapy. *Expert Rev Anticancer Ther.* 2015;15(5):531-544. doi:10.1586/14737140.2015.1023712.
- Batlevi CL, Sha F, Alperovich A, et al. Follicular lymphoma in the modern era: survival, treatment outcomes, and identification of high-risk subgroups. *Blood Cancer J.* 2020;10:74.
- Junlén HR, Peterson S, Kimby E, et al. Follicular lymphoma in Sweden: nationwide improved survival in the rituximab era, particularly in elderly women: a Swedish Lymphoma Registry study. *Leukemia.* 2015;29(3):668-676. doi:10.1038/leu.2014.251.
- Raghavan SC, Swanson PC, Wu X, et al. A non-B-DNA structure at the Bcl-2 major breakpoint region is cleaved by the RAG complex. *Nature.* 2004;428(6978):88. doi:10.1038/nature02355.
- Martin AR, Weisenburger DD, Chan WC, et al. Prognostic value of cellular proliferation and histologic grade in follicular lymphoma. *Blood.* 1995;85(12):3671-3678. doi:10.1182/blood.V85.12.3671.
- Fernández de Larrea C, Martínez-Pozo A, Mercadal S, et al. Initial features and outcome of cutaneous and non-cutaneous primary extranodal follicular lymphoma. *Br J Haematol.* 2011;153(3):334-340. doi:10.1111/j.1365-2141.2011.08596.x.
- Yamaguchi J, Kato S, Iwata E, et al. Pediatric-type follicular lymphoma in the dura: a case report and literature review. *World Neurosurg.* 2018;115:176-180. doi:10.1016/j.wneu.2018.04.053.
- Low I, Allen J. Low-grade follicular lymphoma in the dura: rare mimic of meningioma. *Neuropathology.* 2006;26:564-568. doi:10.1111/j.1440-1789.2006.00730.x.
- Sloane HW, Blake JJ, Shah R, et al. CT and MRI findings of intracranial lymphoma. *Am J Roentgenol.* 2004;184:1679-1685.
- Matmati K, Matmati N, Hannun YA, et al. Dural MALT lymphoma with disseminated disease. *Hematol Rep.* 2010;2(1):e10. doi:10.4081/hr.2010.e10.
- Scherer K, Johnston J, Panda M. Dural based mass: malignant or benign. *J Radiol Case Rep.* 2009;3(11):1-12. doi:10.3941/jrcr.v3i11.189.
- Bustoros M, Liechty B, Zagzag D, et al. A rare case of composite dural extranodal marginal zone lymphoma and chronic lymphocytic leukemia/small lymphocytic lymphoma. *Front Neurol.* 2018;9:267. doi:10.3389/fneur.2018.00267.
- Isla A, Alvarez F, Gutiérrez M, et al. Primary cranial vault lymphoma mimicking meningioma. *Neuroradiology.* 1996;38:211-213. doi:10.1007/BF00596530.
- Subramanian S, Bahaceci E, Kanji A. Primary follicular lymphoma of the meninges: a case report. *Proc Ann Meet Am Soc Clin Oncol.* 1995;14:308.
- Hodgson D, David KM, Powell M, Holton JL, Pezzella F. Intracranial extracerebral follicular lymphoma mimicking a sphenoid wing meningioma. *J Neurol Neurosurg Psychiatry.* 1999;67(2):251-252. doi:10.1136/jnnp.67.2.251.
- Berawal S, Hou JS, Miyamoto C, Garcia-Young JA. Primary dural low-grade BCL-2-negative follicular lymphoma: a case report. *J Neurooncol.* 2003;61(1):23-25. doi:10.1023/a:1021244228163.
- Alameda F, Pedro C, Besses C, et al. Primary epidural lymphoma: case report. *J Neurosurg.* 2003;98:215-217. doi:10.3171/spi.2003.98.2.0215.
- Hamilton DK, Bourne TD, Ahmed H, et al. Follicular lymphoma of the dura: case report. *Neurosurgery.* 2006;59:703-704. doi:10.1227/01.NEU.0000229057.50372.06.
- Riccioni L, Morigi F, Cremonini AM. Follicular lymphoma of the dura associated with meningioma: a case report and review of the literature. *Neuropathology.* 2007;27(3):278-283. doi:10.1111/j.1440-1789.2007.00756.x.
- Peltier J, Fichten A, Lefranc M, et al. Lymphome folliculaire méningé. A propos d'un cas [Follicular dural lymphoma. Case report]. *Neurochirurgie.* 2009;55(3):345-349. doi:10.1016/j.neuchi.2008.12.003.
- Mneimneh WS, Ashraf MA, Li L, et al. Primary dural lymphoma: a novel concept of heterogeneous disease. *Pathol Int.* 2013;63(1):68-72. doi:10.1111/pin.12025.
- Tandon R, Mukherjee U, Abrari A. Primary dural follicular lymphoma masquerading as meningioma: a case report. *Br J Neurosurg.* 2012;26(6):905-906. doi:10.3109/02688697.2012.685783.
- Cho HJ, Lee JB, Hur JW, Jin SW, Cho TH, Park JY. A rare case of malignant lymphoma occurred at spinal epidural space: a case report. *Korean J Spine.* 2015;12(3):177-180. doi:10.14245/kjs.2015.12.3.177.
- MacCann R, Gleeson JP, Aird JJ, et al. An unusual presentation of a low grade follicular lymphoma masquerading as a meningioma. *Case Report Ann Hematol Oncol.* 2018;5(6):1211.
- Sorigue M, Sancho JM. Current prognostic and predictive factors in follicular lymphoma. *Ann Hematol.* 2017;97(2):209-227. doi:10.1007/s00277-017-3154-z.