



Successful endoscopic management of adult ileocecal intussusception secondary to a large ileal lipoma

Akira Teramoto, MD,¹ Seiji Hamada, MD,² Takahiro Utsumi, MD,³ Daizen Hirata, MD,¹ Yasushi Sano, MD, PhD¹

CASE PRESENTATION

A 90-year-old man presented to our hospital with abdominal pain, nausea, and loss of appetite that started the day before arrival. Initial CT revealed a target sign with a low-density mass at the center located in the terminal ileum (Fig. 1). Although a severely distended small bowel and ascites were present, physical and serum laboratory findings were not suggestive of peritonitis. From the CT findings, the patient was diagnosed with adult intussusception secondary to a lipoma. Because vital signs were stable and abdominal pain was under control without administration of anesthetics, we attempted endoscopic reduction under fluoroscopic guidance (Video 1, available online at www.VideoGIE.org).

ENDOSCOPIC REDUCTION

A colonoscope (CF-HQ290L/I; Olympus Medical Systems, Tokyo, Japan) and CO₂ gas insufflation were used during the procedure. The patient did not receive a bowel preparation, and 3 mg of midazolam was administered for

conscious sedation. A 20-mm red, smooth, protruding mass formed an intussusception at the ileocecal valve (Fig. 2). The mass was repositioned into the ileum by

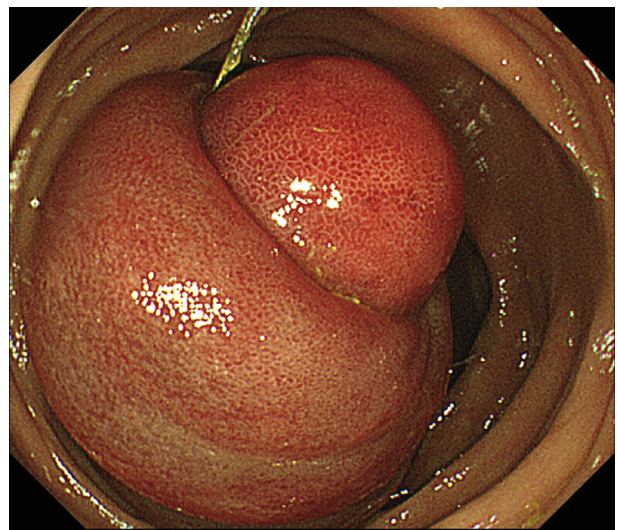


Figure 2. Initial colonoscopy revealed a 25-mm, red, smooth, protruding mass at the ileocecal valve that was causing intussusception.

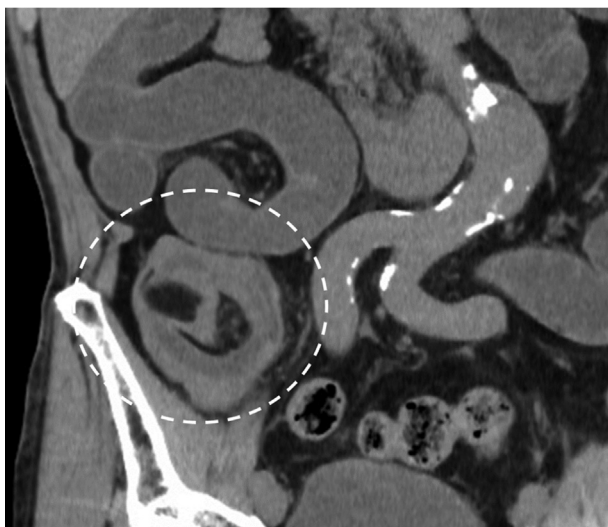


Figure 1. CT scan showed a target sign at the terminal ileum, and the responsible tumor showed a homogeneous low density. The patient was diagnosed with adult intussusception secondary to a lipoma in the ileum.

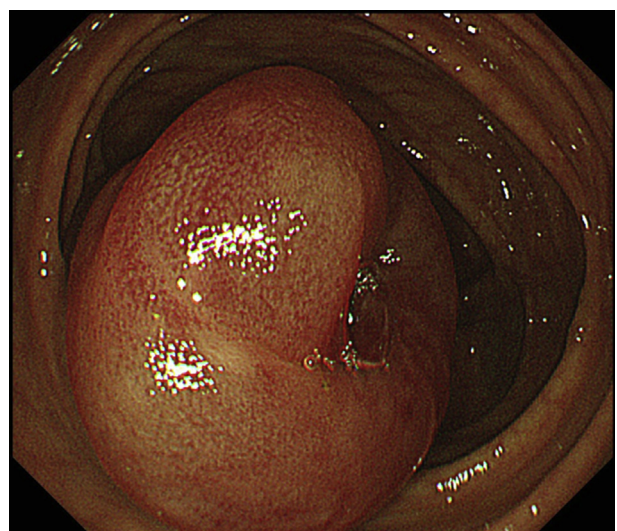


Figure 3. The tumor was repositioned into the ileum by intensive air insufflation. Because the ileocecal valve was edematous, the endoscope could not pass the valve at that time.

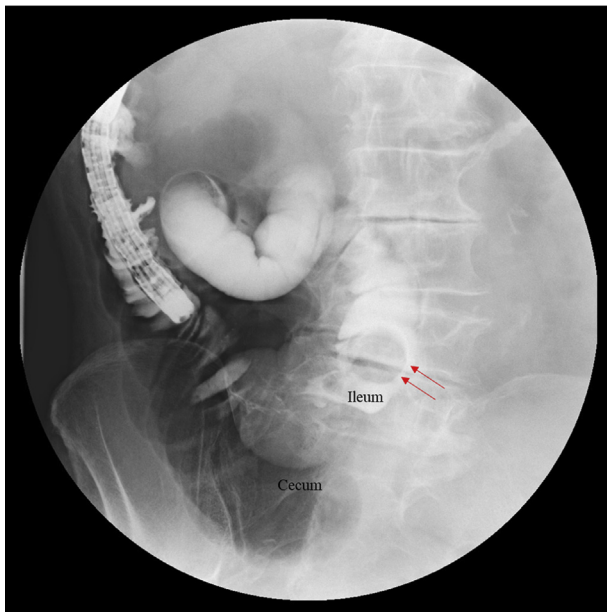


Figure 4. Fluoroscopic contrast showed that the lesion was successfully repositioned in the ileum. There was no leakage of contrast, and the patient recovered from bowel distention immediately after the procedure.

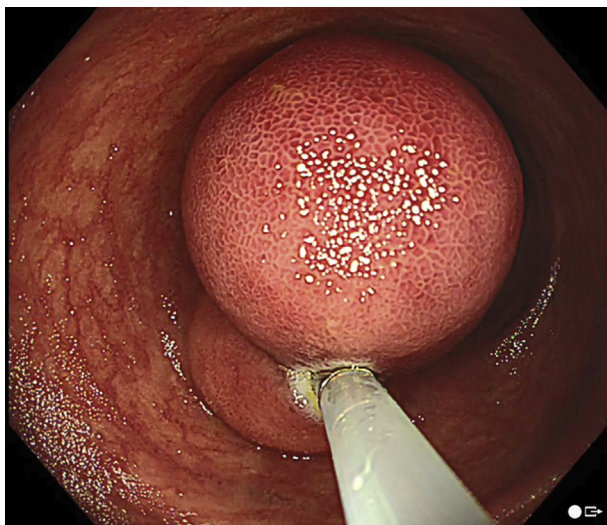


Figure 5. Polypectomy was attempted on day 4 after the patient underwent bowel preparation. Although the tumor was grasped near the bottom, we aimed for an incomplete resection to ensure the safety of the patient.

insufflating air at cecum (Figs. 3 and 4). Immediately after the procedure, the patient recovered from bowel distention by passing a large amount of watery stool.

ENDOSCOPIC RESECTION OF LIPOMA

On day 4, follow-up CT scan revealed dissipation of ileal dilation and ascites. After administering magnesium citrate for bowel preparation, polypectomy was attempted. We assumed that the lesion was a benign lipoma, and given

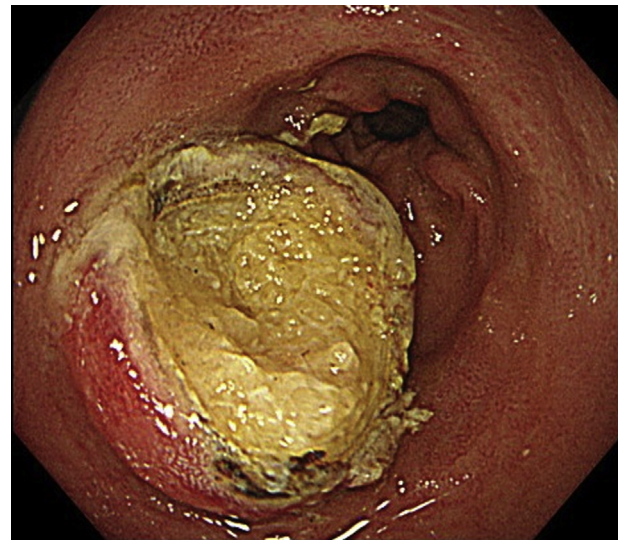


Figure 6. The cut surface of the tumor contained fat-like yellowish tissue, which was confirmed as a lipoma by pathologic analysis.

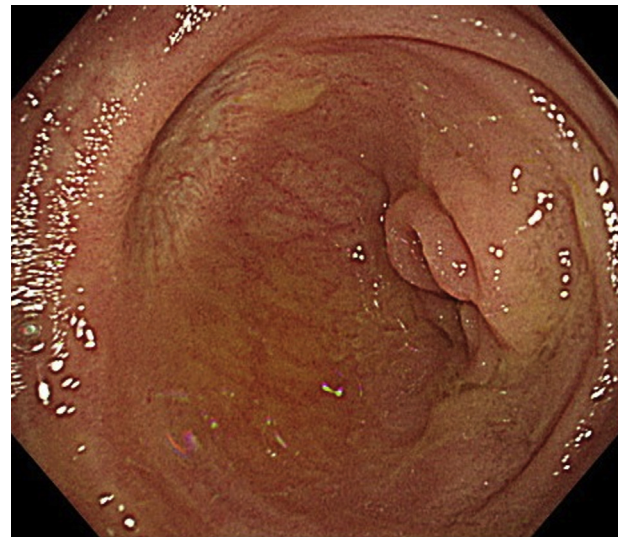


Figure 7. Follow-up colonoscopy after 4 months. There was a clear scar without any signs of recurrence.

that the elderly patient was on multiple anticoagulants because of a history of cerebral infarction, we aimed for an incomplete resection of the submucosal tumor instead of attempting a high-risk complete resection (Fig. 5).

The lesion was grasped toward its bottom using a bipolar snare (26 mm Dragonare BSDH-217, Zeon Medical, Tokyo, Japan), and an electrosurgical unit (VIO 300D; ERBE Elektromedizin, Tübingen, Germany) was used at the following power settings: AUTO CUT effect 4, 30W, FORCED COAG effect 2, 20W. Because the surface of the lesion was severely carbonized with both mode settings, the initial attempt at resection was unsuccessful.

Subsequently, we replaced the snare with a monopolar snare (SnareMaster, Olympus Medical Systems, Tokyo Japan), and the lesion was successfully resected with

ENDOCUT Q effect 3 settings. The cut section of the tumor was yellow, fat-like tissue, which was confirmed to be a lipoma on pathologic analysis (Fig. 6). No adverse events occurred during or after the resection. A clear scar without any signs of recurrence was confirmed on follow-up colonoscopy performed 4 months after the resection (Fig. 7).

DISCUSSION

Adult intussusception accounts for only 1% to 5% of all bowel obstruction, and 75% to 80% are located in the small intestine.¹ In general, a radiologically homogeneous low-density mass can be diagnosed as a lipoma.² Although surgical resection has been the most common approach to treat intussusception, reports regarding endoscopic reduction and resection have increased over the last 2 decades. As a result, several endoscopic methods to remove lipomas have been developed, including standard polypectomy,³ endoloop polypectomy,⁴ endoscopic unroofing,^{5,6} endoscopic mucosal resection,⁷ and endoscopic submucosal dissection.⁸ To date, there is no consensus on treatment methods, and whether to complete resection is necessary remains controversial. However, given that resection of colonic lipomas 2 cm or larger is associated with a higher risk of perforation and bleeding, it is important to consider the risk and benefit for each patient.⁹ Our case demonstrates that it is feasible to reduce an intussusception and resect the responsible lesion endoscopically. Although the lesion was located in the ileum, where care should be taken to avoid perforation, it is important to select a monopolar snare instead of a bipolar snare when a lipoma is suspected. Short-term follow-up suggested that an incomplete resection is acceptable, especially among elderly patients. Endoscopic treatment is less invasive, and long-term adverse events related to surgical treatment can be avoided.

DISCLOSURE

All authors disclosed no financial relationships.

REFERENCES

1. Marsicovetere P, Ivatury SJ, White B, et al. Intestinal intussusception: etiology, diagnosis, and treatment. *Clin Colon Rectal Surg* 2017;30:30-9.
2. Thompson WM. Imaging and findings of lipomas of the gastrointestinal tract. *AJR Am J Roentgenol* 2005;184:1163-71.
3. Kosaka R, Noda T, Tsuboi J, et al. Successful endoscopic removal of a large colonic lipoma causing intussusception. *Endoscopy* 2014;46(Suppl 1 UCTN):E551-2.
4. Raju GS, Gomez G. Endoloop ligation of a large colonic lipoma: a novel technique. *Gastrointest Endosc* 2005;62:988-90.
5. Morimoto T, Fu KI, Konuma H, et al. Peeling a giant ileal lipoma with endoscopic unroofing and submucosal dissection. *World J Gastroenterol* 2010;16:1676-9.
6. Kopacova M, Rejchrt S, Bures J. Unroofing technique as an option for the endoscopic treatment of giant gastrointestinal lipomas. *Acta Medica (Hradec Kralove)* 2015;58:115-8.
7. Lee ES, Lee KN, Choi KS, et al. Endoscopic treatment of a symptomatic ileal lipoma with recurrent ileocolic intussusceptions by using cap-assisted colonoscopy. *Clin Endosc* 2013;46:414-7.
8. Noda H, Ogasawara N, Tamura Y, et al. Successful endoscopic submucosal dissection of a large terminal ileal lipoma. *Case Rep Gastroenterol* 2016;10:506-11.
9. Pfeil SA, Weaver MG, Abdul-Karim FW, et al. Colonic lipomas: outcome of endoscopic removal. *Gastrointest Endosc* 1990;36:435-8.

Gastrointestinal Center, Sano Hospital, Kobe, Japan (1), Gastrointestinal Center, Urasoe General Hospital, Urasoe, Japan (2), Department of Gastroenterology and Hepatology, Kyoto University Graduate School of Medicine, Kyoto, Japan (3).

Copyright © 2021 American Society for Gastrointestinal Endoscopy. Published by Elsevier Inc. This is an open access article under the CC BY-NC-ND license (<http://creativecommons.org/licenses/by-nc-nd/4.0/>).

<https://doi.org/10.1016/j.vgje.2020.12.008>
