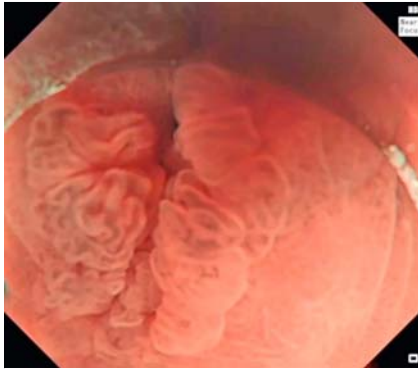
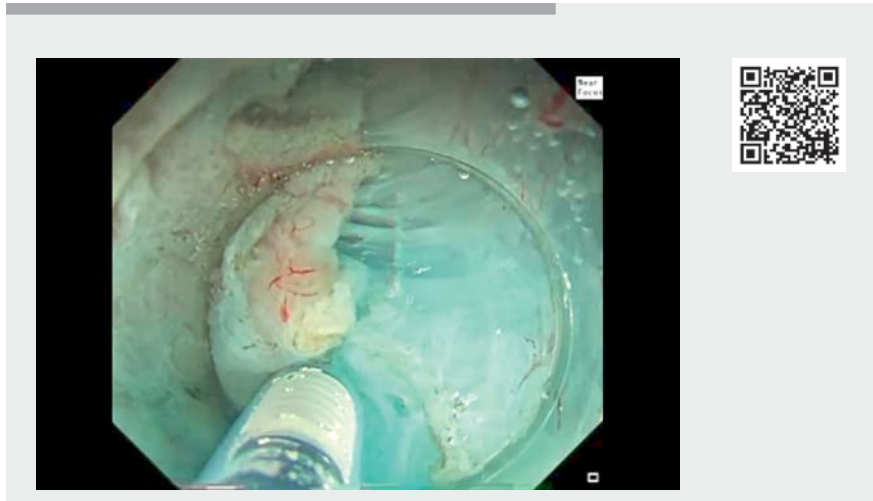

## Saline-immersion therapeutic endoscopy facilitated en bloc endoscopic submucosal-subserosal dissection of a sigmoid diverticulum containing a refractory adenomatous lesion

OPEN  
ACCESS



► **Fig. 1** Refractory sigmoid tubulovillous adenoma arising from and fully occupying a diverticulum.

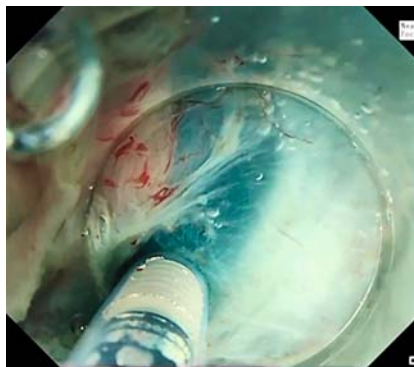


► **Video 1** Saline-immersion therapeutic endoscopy facilitated submucosal-subserosal dissection of a diverticulum with a refractory lesion.

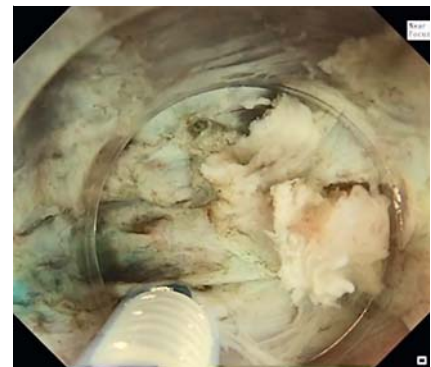
Underwater resection has become a well-recognized alternative approach to standard endoscopic resection techniques [1]. Based on the same principles, saline-immersion therapeutic endoscopy (SITE) was introduced as an “evolution of the underwater technique” with several potential advantages [2]. SITE facilitates endoscopic submucosal dissection (ESD) through maintenance of the submucosal lift, intrinsic buoyancy (obviating the need for traction), enhanced dissection, and improved visibility [2, 3].

A 69-year-old woman without comorbidities was referred to our tertiary center for ESD of a refractory sigmoid tubulovillous adenoma (Paris 0-IIa, JNET 2A) (► **Fig. 1**), arising from and fully occupying a diverticulum within a tight, strictured segment of the sigmoid colon. Endoscopic resection had been attempted three times at other hospitals without success and the patient was referred to us in order to avoid sigmoid colectomy.

Given the tightness of the strictured sigmoid segment, alternative options, including full-thickness resection, were deemed impossible. SITE-facilitated endoscopic submucosal-subserosal dissection (ESSD) was performed under conscious sedation (► **Video 1**). A gas-



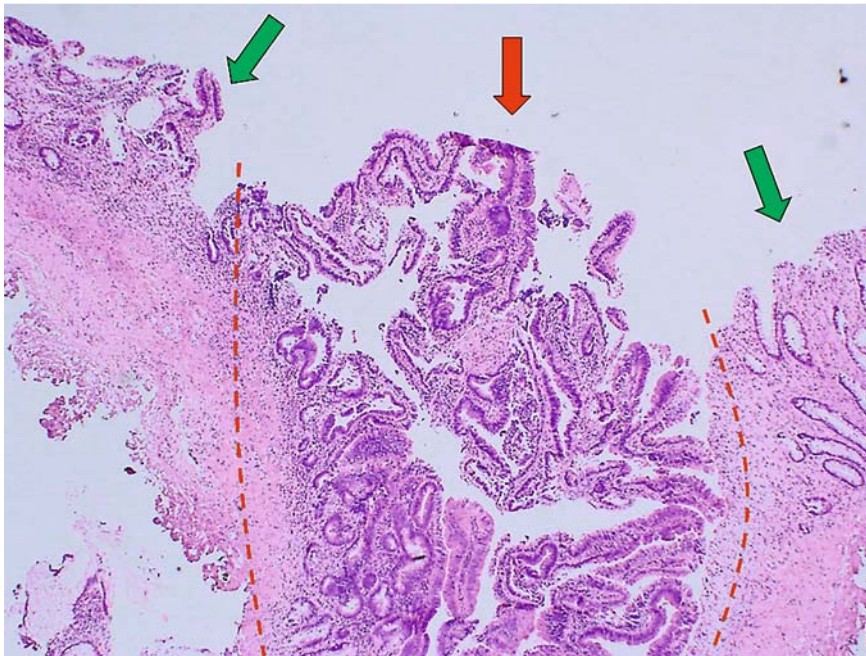
► **Fig. 2** Endoscopic submucosal-subserosal dissection assisted by saline-immersion therapeutic endoscopy.



► **Fig. 3** Procedure performed exclusively using saline immersion with no gaseous insufflation.

troscope incorporating water-jet and NearFocus functions (GIF-H290; Olympus, Tokyo, Japan), a short ST hood (Fujifilm, Tokyo, Japan), and a 1.5-mm FlushKnife-BTs (Fujifilm) were used. No gaseous insufflation was used and the ESSD was performed exclusively using SITE (► **Fig. 2**, ► **Fig. 3**). Saline immersion eliminated any fluid–gas interfaces; its combination with NearFocus also en-

hanced optical clarity for more precise dissection with minimal contact, as well as visualization of submucosal vessels. SITE-ESSD ensured meticulous and safe dissection of the whole diverticulum from the surrounding muscularis propria and subserosal space. En bloc diverticular excision was achieved in 90 minutes. Complete R0 resection of the low grade adenoma was confirmed by histopathol-



► **Fig. 4** Histopathology image showing the adenoma occupying the diverticulum (red arrows) surrounded by healthy mucosa (green arrows).

ogy (► **Fig. 4**). The patient received antibiotics prophylactically and was admitted for 72 hours of observation. No intra- or post-procedural adverse events occurred.

SITE-ESSD is a useful, safe, and effective technique even for challenging cases. In this scenario, with great care, and meticulous dissection with minimal contact, SITE-facilitated expansion of the submucosal and subserosal layers, along with intrinsic buoyancy, obviated the need for traction, and allowed for safe and effective en bloc sigmoid “diverticulectomy” as an alternative to sigmoid colectomy.

Endoscopy\_UCTN\_Code\_TTT\_1AQ\_2AD

### Acknowledgments

We wish to thank our colleague, Dr. Jennifer Watkins, consultant cellular pathologist, for her kind input into this case.

### Competing interests

Dr Despott and Dr Murino have received unrestricted educational grants from Olympus Medical, Fujifilm, Pentax and Medtronic. Dr Despott has received speaker honoraria from Olympus medical, Fujifilm and Norgine, and consultant honoraria from Boston Scientific, Fujifilm and Ambu. Dr Murino has received speaker honoraria from GI supply and consultant honoraria from Boston Scientific and Pentax.

### The authors

**Nikolaos Lazaridis<sup>1</sup>**, **Stavroula Pelitari<sup>1</sup>**, **Alberto Murino<sup>1</sup>**, **Yoshikazu Hayashi<sup>2</sup>**, **Hironori Yamamoto<sup>2</sup>**, **Edward J. Despott<sup>1</sup>**

- 1 Royal Free Unit for Endoscopy, The Royal Free Hospital and University College London (UCL) Institute for Liver and Digestive Health, Hampstead, London, United Kingdom
- 2 Department of Medicine, Division of Gastroenterology, Jichi Medical University, Shimotsuke, Japan

### Corresponding author

**Edward J. Despott, MD**

The Royal Free Hospital and University College London (UCL) Institute for Liver and Digestive Health, Pond Street, Hampstead, London NW3 2QG, United Kingdom  
edespott@doctors.org.uk

### References

- [1] Maida M, Sferrazza S, Murino A et al. Effectiveness and safety of underwater techniques in gastrointestinal endoscopy: a comprehensive review of the literature. *Surg Endosc* 2021; 35: 37–51
- [2] Despott EJ, Murino A. Saline-immersion therapeutic endoscopy (SITE): an evolution of underwater endoscopic lesion resection. *Dig Liver Dis* 2017; 49: 1376
- [3] Despott EJ, Hirayama Y, Lazaridis N et al. Saline immersion therapeutic endoscopy facilitated pocket-creation method for endoscopic submucosal dissection (with video). *Gastrointest Endosc* 2019; 89: 652–653

### Bibliography

*Endoscopy* 2022; 54: E1016–E1017

DOI 10.1055/a-1881-3738

ISSN 0013-726X

published online 24.8.2022

© 2022. The Author(s).

This is an open access article published by Thieme under the terms of the Creative Commons Attribution-NonDerivative-NonCommercial License, permitting copying and reproduction so long as the original work is given appropriate credit. Contents may not be used for commercial purposes, or adapted, remixed, transformed or built upon. (<https://creativecommons.org/licenses/by-nc-nd/4.0/>)

Georg Thieme Verlag KG, Rüdigerstraße 14, 70469 Stuttgart, Germany

