



Contents lists available at [ScienceDirect](https://www.sciencedirect.com)

# AAACE Clinical Case Reports

journal homepage: [www.aaaceclinicalcasereports.com](http://www.aaaceclinicalcasereports.com)



## Case Report

# Rare Diagnosis of Familial Partial Lipodystrophy in a Patient With Life-Threatening Pancreatitis due to Hypertriglyceridemia



Chukwuka Akamnonu, MD <sup>1,\*</sup>, Masako Ueda, MD <sup>2</sup>, Ankit Shah, MD <sup>1</sup>

<sup>1</sup> Division of Endocrinology, Metabolism and Nutrition, Department of Medicine, Robert Wood Johnson Medical School, Rutgers University, New Brunswick, New Jersey

<sup>2</sup> University of Pennsylvania, Philadelphia, Pennsylvania

## ARTICLE INFO

### Article history:

Received 17 February 2021

Received in revised form

3 June 2021

Accepted 8 June 2021

Available online 16 June 2021

### Key words:

lipodystrophy

hypertriglyceridemia

genetic

familial partial lipodystrophy

## ABSTRACT

**Background:** Familial partial lipodystrophy type 2 (FPLD2) is a rare genetic condition characterized by partial lack of subcutaneous tissue and can predispose an individual to complications such as hypertriglyceridemia with pancreatitis, insulin resistance, and diabetes. This report describes a case of FPLD2 identified with judicious history and examination.

**Case Report:** This case describes a 32-year-old patient with recurrent pancreatitis who developed complications requiring multiple surgeries, fistulas, ostomy, and parenteral feeding. The diagnosis of FPLD2 was made after a thorough history, observation, and examination leading to genetic testing. With the underlying etiology and diagnosis being known, appropriate counseling, family testing, and medical follow-ups can be sought.

**Discussion:** Our patient's case highlights the values of judicious physical examination and thoughtful inquiry of medical and family histories in arriving at the diagnosis of FPLD2. A thorough physical examination most of the time is necessary to diagnose this condition as some of the traits associated with the lack of adiposity may be seen as desirable to the general public.

**Conclusion:** It is important that physicians obtain a thorough history and physical examination that may help in the prompt diagnosis of rare diseases like FPLD2, with subsequent multidisciplinary care that includes endocrinology, hepatology, cardiology, and nutrition.

© 2021 AAACE. Published by Elsevier Inc. This is an open access article under the CC BY-NC-ND license (<http://creativecommons.org/licenses/by-nc-nd/4.0/>).

## Introduction

Hypertriglyceridemia (HTG) is an uncommon cause of acute pancreatitis comprising less than 10% of cases.<sup>1</sup> However, it is important to investigate the cause of HTG to prevent recurrent pancreatitis. An obscure condition that should not be forgotten as a cause of HTG is lipodystrophy. Lipodystrophy syndromes are a group of inherited or acquired disorders with a striking feature of either a partial or complete lack of adiposity associated with metabolic and other manifestations.<sup>2–4</sup> The diagnosis of partial lipodystrophy is often overlooked because

patients present with common conditions such as diabetes mellitus, insulin resistance, HTG, and hepatic steatosis but otherwise appear “normal.” An astute observation is necessary to recognize the unique body habitus that is discordant with their exercise and lifestyle history. Family history is also critical in identifying a familial partial lipodystrophy (FPLD) subtype. Since the management of lipodystrophy requires a multidisciplinary approach, identification of individuals with FPLD is crucial. This study aimed to describe a case of familial partial lipodystrophy type 2 (FPLD2) identified with judicious history and physical examination.

## Case Report

The patient is a 32-year-old woman who presented to the endocrinology clinic for the management of HTG after a near-death experience due to the necrotic sequelae of acute pancreatitis. The patient's first episode of pancreatitis was 10 years earlier with triglyceride (TG) level in the “thousands.” Her HTG had been well

**Abbreviations:** FPLD, familial partial lipodystrophy; FPLD2, familial partial lipodystrophy type 2; HTG, hypertriglyceridemia; TG, triglyceride.

\* Address correspondence to Dr Chukwuka Akamnonu, Division of Endocrinology, Metabolism and Nutrition, Department of Medicine, Robert Wood Johnson Medical School, Rutgers University, 125 Paterson St, New Brunswick, NJ 08901-1962.

E-mail address: [akamspc@yahoo.com](mailto:akamspc@yahoo.com) (C. Akamnonu).

<https://doi.org/10.1016/j.aaace.2021.06.005>

2376-0605/© 2021 AAACE. Published by Elsevier Inc. This is an open access article under the CC BY-NC-ND license (<http://creativecommons.org/licenses/by-nc-nd/4.0/>).

managed with a low-fat diet along with fenofibrate, atorvastatin, ezetimibe, and, occasionally,  $\omega$ -3 fatty acids.

She developed severe abdominal pain after attending a series of weddings with loosened dietary discretion, resulting in acute pancreatitis with a TG level of approximately 4000 mg/dL. She required hospitalization and plasmapheresis to lower the TG level to 480 mg/dL. Abdominal imaging revealed pancreatitis with necrotic changes, necessitating abdominal laparotomy and bowel resection. She was finally discharged after 71 days, with a 20-pound weight loss, and subsequently required multiple reconstructive procedures for prolonged ostomy use.

The patient recounted having only 1 alcoholic drink at each wedding event and denied a history of gallstones or any gastrointestinal procedures prior to the pancreatitis episode. Notably, she reported using a combination oral contraceptive pill for several years but denied menstrual irregularities.

Our physical examination was most revealing. She had no apparent subcutaneous fat in her arms and legs, accentuating impressive muscular contours in her extremities (Fig. 1). She described that she has always been muscular without exercising. Her mother, as well as 2 maternal uncles and maternal grandfather, was noted to have similar muscularity and without medical issues, hinting at a familial condition (Fig. 2).

Additional studies showed an elevated homeostatic model assessment for insulin resistance of 4.0 (reference value, <2.0), indicating insulin resistance without notable acanthosis nigricans or hyperglycemia (HbA1c, 5.6% [38 mmol/mol]), and a fatty liver on abdominal ultrasound without obesity (body mass index, 24.52 kg/m<sup>2</sup>). Her total body fat percentage was relatively low at 15.6% (normal, 19%–22%) and was disproportionately low at 9% in her legs. Her electrocardiogram was normal, and transthoracic echocardiogram showed no valvular abnormalities with an ejection fraction of 65% to 70%. Genetic testing, targeting the known 19 lipodystrophy genes, identified a well-known pathogenic mutation (c.1445G>A, p.Arg482Gln) in the lamin A/C gene (*LMNA*) for FPLD2, corroborating our suspicion of FPLD. Interestingly, the mutation was not reported in the Genome Aggregation Database (gnomAD), indicating its rarity in the population.

## Discussion

The prevalence of all lipodystrophies is approximately 1.3 to 4.7 cases/million.<sup>5</sup> FPLD2 or Dunnigan type (OMIM: 151660), commonly due to a specific heterozygous *LMNA* mutation (p.Arg482Trp/Gln/Leu), is an extremely rare but underdiagnosed subtype of inherited lipodystrophy, in which a loss of adiposity in the extremities typically becomes apparent at puberty, whereas an excess of adiposity may be noted in the face and around the neck, often associated with hyperglycemia, hepatic steatosis, and HTG, which may result in pancreatitis as in our patient.<sup>6,7</sup>

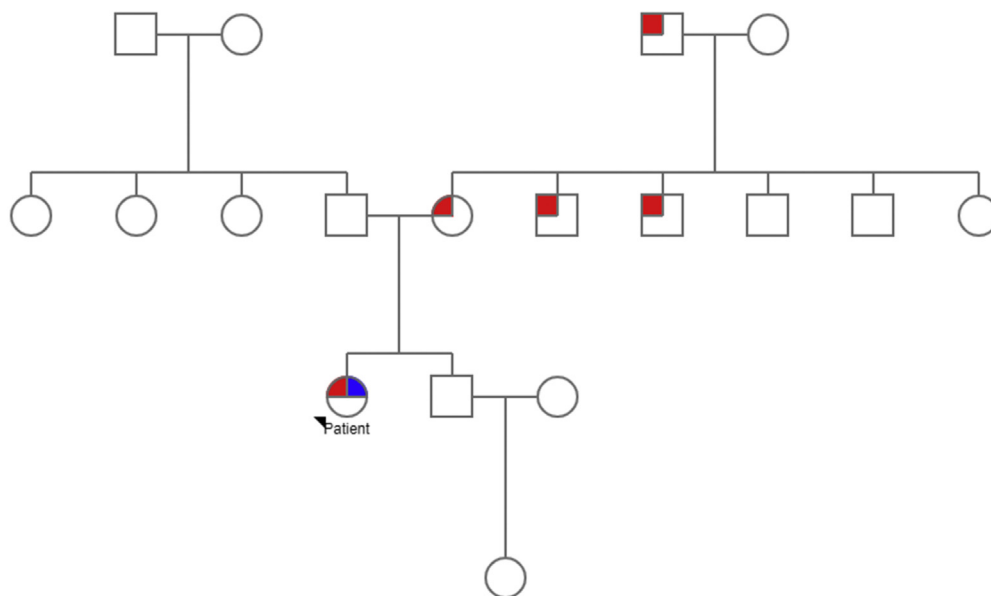
Additional features, not found in our patient, such as menstrual irregularities, hirsutism, cardiac arrhythmias, and hypertrophic cardiomyopathy have been reported in patients with FPLD2.<sup>8</sup> Therefore, there are significant variabilities in the clinical presentation in a patient with FPLD2. There is no specific therapy for FPLD2 in the United States; however, in Europe, volanesorsen, an antisense oligonucleotide against apolipoprotein C-III to lower the TG level, has been approved for FPLD.<sup>9</sup> Metreleptin, only approved for generalized lipodystrophy, has shown some favorable effects in FPLD.<sup>10</sup>

The *LMNA* gene (1q22, OMIM: 150330) encodes nuclear lamin proteins, lamins A and C. They are part of a multigene family and are ubiquitously expressed in most differentiated mammalian cells.<sup>11</sup> Lamins are involved in DNA replication, chromatin organization, nuclear pore arrangement, nuclear growth, and nuclear membrane anchorage.<sup>11</sup> *LMNA* gene mutations exert vastly pleiotropic manifestations affecting multiple organ systems and cause more than 10 distinct, seemingly unrelated, disorders.<sup>12</sup> Other well-known *LMNA* disorders or laminopathies include autosomal dominant dilated cardiomyopathy 1A, autosomal recessive Charcot-Marie-Tooth type 2B1, autosomal dominant and recessive Emery-Dreifuss muscular dystrophies (type 2 and type 3, respectively), autosomal dominant congenital muscular dystrophy, autosomal dominant Hutchinson-Gilford progeria syndrome, autosomal recessive mandibuloacral dysplasia, and restrictive dermopathy.<sup>13</sup>

The *LMNA* gene consists of 12 exons and 5 major domains. The particular mutation in our patient, c.1445G>A, p.Arg482Gln, is located in the exon 8 within the tail domain that contains a nuclear localization signal, immunoglobulin signal, and CAAX box with a

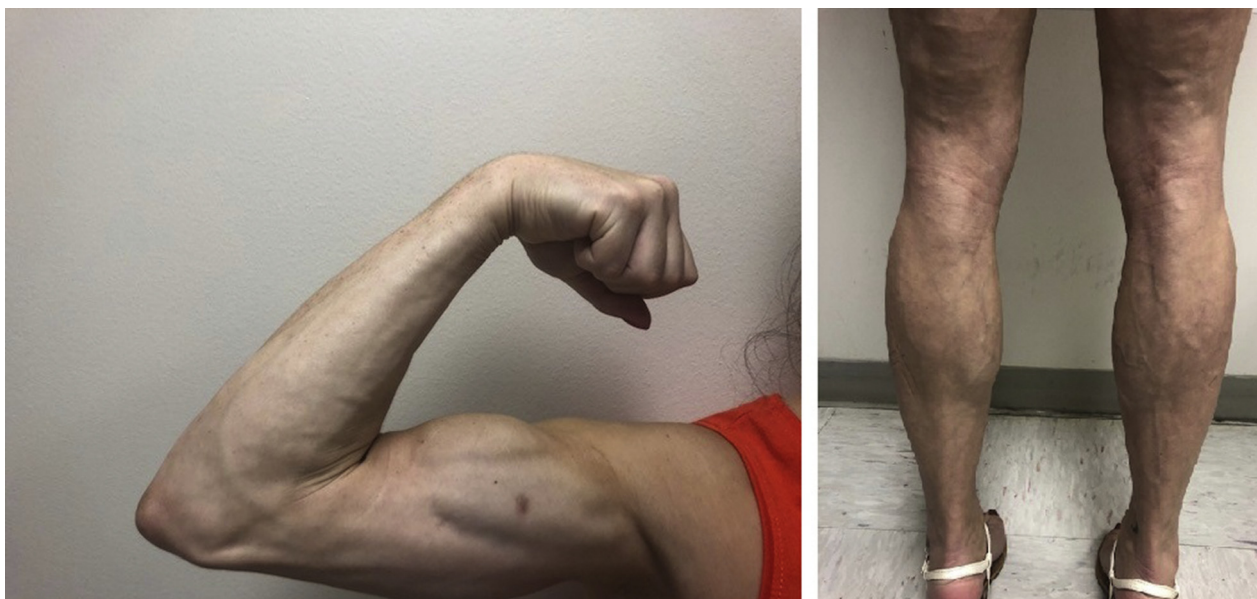

Fig. 1. Upper and lower extremities of the patient demonstrated paucity of subcutaneous tissues and exhibited impressive muscular contours and definitions.



**Fig. 2.** Family pedigree showing multiple members with marked muscular appearance. Interestingly, the patient seems to be the only person who developed hypertriglyceridemia and recurrent pancreatitis.

conserved amino acid sequence at the C-terminal, which undergoes farnesylation. Currently, the underlying mechanisms by which different clinical features manifest with various *LMNA* mutations have not been clearly elucidated. A mutation that manifests in lipodystrophic features has also been identified in the exon 1 of the head region.<sup>14</sup> Therefore, the location of a mutation in the *LMNA* gene does not seem to predict its exact clinical features. Moreover, it remains to be investigated how ubiquitously expressed proteins would cause tissue-specific diseases.

Although there are over 500 reported cases of FPLD2 (Dunnigan type) in literature, the medical burden of delayed diagnosis continues to persist; thus, there is a need to enhance awareness among providers.<sup>15</sup> In addition to a physical feature suggestive of abnormal adipose tissue distribution, the presence of dyslipidemia, diabetes mellitus, and/or hepatic steatosis at a young age and/or with a lean body habitus should raise the suspicion for FPLD2. In a 2013 case-control study, 68.6% of patients with FPLD had dyslipidemia compared with 7.8% in controls.<sup>16</sup> The underlying pathogenic mechanisms and consequences of dyslipidemia in FPLD2 are considered to be the consequence of ineffective adipose tissue biogenesis for TG storing, excess TG accumulation in the plasma, and ectopic fat deposition, eliciting lipotoxicity and inflammation.<sup>17</sup>

Our patient's case clearly highlights the values of judicious physical examination and thoughtful inquiry of medical and family histories in arriving at the diagnosis of FPLD2. It explained the cause of our patient's HTG and the necessity of dietary compliance in lowering the TG level, as well as careful avoidance of HTG-associated agents, including oral contraceptive pills, in preventing recurrent pancreatitis. With the definitive diagnosis, essential follow-up plans for the patient and family members were communicated. Provided with the definitive diagnosis of FPLD2, the patient and her family were able to embrace the importance of specific management plans. It is imperative that patients with

FPLD2 receive multidisciplinary care that includes endocrinology, hepatology, cardiology, and nutrition.

#### Author Contributions

C.A. and A.S. evaluated the patient. M.U. provided inputs on familial partial lipodystrophy type 2 and genetic finding. C.A. wrote the entire manuscript, which was then reviewed and edited by M.U. and A.S.

#### Disclosure

The authors have no multiplicity of interest to disclose.

#### References

- de Pretis N, Amodio A, Frulloni L. Hypertriglyceridemic pancreatitis: epidemiology, pathophysiology and clinical management. *United European Gastroenterol J.* 2018;6(5):649–655.
- Berardinelli W. An undiagnosed endocrinometabolic syndrome: report of 2 cases. *J Clin Endocrinol Metab.* 1954;14(2):193–204.
- Seip M. Lipodystrophy and gigantism with associated endocrine manifestations. A new diencephalic syndrome? *Acta Paediatr.* 1959;48:555–574.
- Falutz J, Allas S, Blot K, et al. Metabolic effects of a growth hormone-releasing factor in patients with HIV. *N Engl J Med.* 2007;357(23):2359–2370.
- Chiquette E, Oral EA, Garg A, Araujo-Vilar D, Dhankhar P. Estimating the prevalence of generalized and partial lipodystrophy: findings and challenges. *Diabetes Metab Syndr Obes.* 2017;10:375–383.
- Garg A, Peshock RM, Fleckenstein JL. Adipose tissue distribution pattern in patients with familial partial lipodystrophy (Dunnigan variety). *J Clin Endocrinol Metab.* 1999;84(1):170–174.
- Simha V, Garg A. Inherited lipodystrophies and hypertriglyceridemia. *Curr Opin Lipidol.* 2009;20(4):300–308.
- Schmidt HH. Consider cardiomyopathy in subjects with familial partial lipodystrophy. *Circulation.* 2002;105(2):E7.
- Paik J, Duggan S. Volanesorsen: first global approval. *Drugs.* 2019;79(12):1349–1354.
- Oral EA, Gorden P, Cochran E, et al. Long-term effectiveness and safety of metreleptin in the treatment of patients with partial lipodystrophy. *Endocrine.* 2019;64(3):500–511.

11. Stuurman N, Heins S, Aebi U. Nuclear lamins: their structure, assembly, and interactions. *J Struct Biol.* 1998;122(1-2):42–66.
12. Carboni N, Mura M, Marrosu G, et al. Muscle imaging analogies in a cohort of patients with different clinical phenotypes caused by LMNA gene mutations. *Muscle Nerve.* 2010;41(4):458–463.
13. Jacob KN, Garg A. Laminopathies: multisystem dystrophy syndromes. *Mol Genet Metab.* 2006;87(4):289–302.
14. Hussain I, Patni N, Ueda M, et al. A novel generalized lipodystrophy-associated progeroid syndrome due to recurrent heterozygous LMNA p.T10I mutation. *J Clin Endocrinol Metab.* 2018;103(3):1005–1014.
15. Bagias C, Xiarchou A, Bargiota A, Tigas S. Familial partial lipodystrophy (FPLD): recent insights. *Diabetes Metab Syndr Obes.* 2020;13:1531–1544.
16. Hegele RA, Kraw ME, Ban MR, Miskie BA, Huff MW, Cao H. Elevated serum C-reactive protein and free fatty acids among nondiabetic carriers of missense mutations in the gene encoding lamin A/C (LMNA) with partial lipodystrophy. *Arterioscler Thromb Vasc Biol.* 2003;23(1):111–116.
17. Hussain I, Patni N, Garg A. Lipodystrophies, dyslipidaemias and atherosclerotic cardiovascular disease. *Pathology.* 2019;51(2):202–212.