



Cite this article as: Inoue Y, Inoue M, Koga M, Koizumi S, Yokawa K, Masada K *et al.* Novel brain computed tomography perfusion for cerebral malperfusion secondary to acute type A aortic dissection. *Interact CardioVasc Thorac Surg* 2022; doi:10.1093/icvts/ivac046.

Novel brain computed tomography perfusion for cerebral malperfusion secondary to acute type A aortic dissection

Yosuke Inoue ^a, Manabu Inoue^b, Masatoshi Koga^b, Shigeki Koizumi^a, Koki Yokawa^a, Kenta Masada^a, Yoshimasa Seike^a, Hiroaki Sasaki^a, Kenji Yoshitani^c, Kenji Minatoya^d and Hitoshi Matsuda ^{a,*}

^a Department of Cardiovascular Surgery, National Cerebral and Cardiovascular Center, Suita, Osaka, Japan

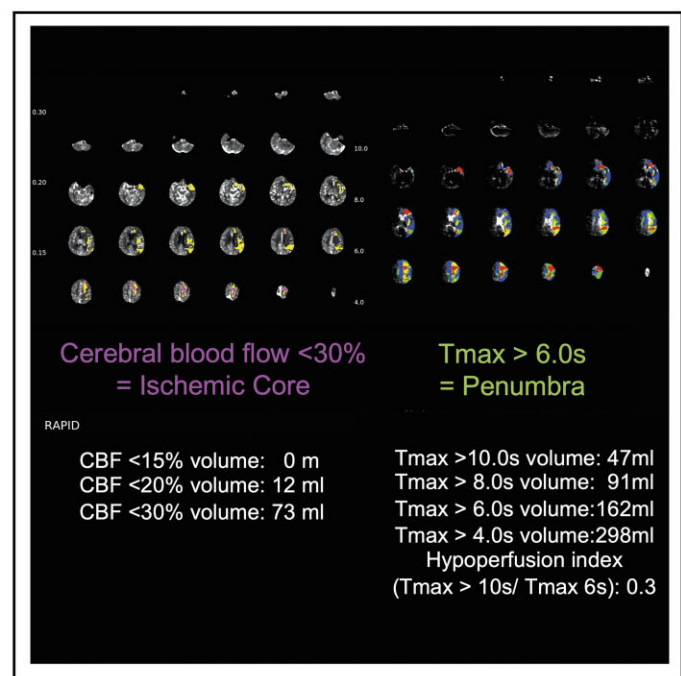
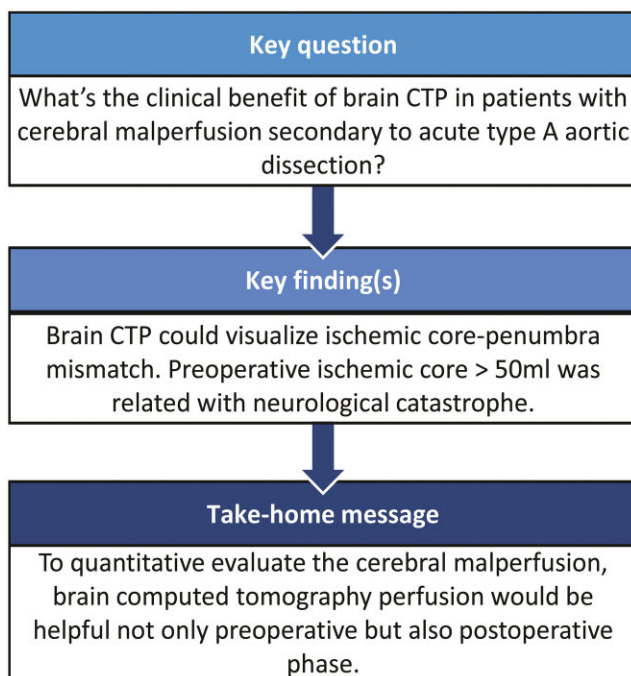
^b Department of Cerebrovascular Medicine, National Cerebral and Cardiovascular Center, Suita, Osaka, Japan

^c Department of Transfusion, Department of Anesthesiology, National Cerebral and Cardiovascular Center, Suita, Osaka, Japan

^d Department of Cardiovascular Surgery, Graduate School of Medicine, Kyoto University, Kyoto, Japan

* Corresponding author. Department of Cardiovascular Surgery, National Cerebral and Cardiovascular Center, 6-1 Kishibe-shimmachi, Suita, Osaka 564-8565, Japan. Tel: +81-6-6170-1070; fax: +81-6-6170-1782; e-mail: hitmat@mist.ocn.ne.jp (H. Matsuda).

Received 13 January 2022; received in revised form 5 February 2022; accepted 6 February 2022



Abstract

OBJECTIVES: The management of acute type A aortic dissection with malperfusion syndrome remains challenging. To evaluate preoperative condition, symptoms might be subjective and objective evaluation of cerebral artery has not yet been established. For quantitative evaluation, this study focused on brain computed tomography perfusion (CTP), which has been recommended by several guidelines of acute ischaemic stroke.

METHODS: In the last 2 years, 147 patients hospitalized due to acute type A aortic dissection were retrospectively reviewed. Among the 23 (16%) patients with cerebral malperfusion, 14 who underwent brain CTP (6 preoperative and 8 postoperative) were enrolled. CTP parameters, including regional blood flow and time to maximum, were automatically computed using RAPID processing of Perfusion and Diffusion software. The median duration from the onset to hospital arrival was 129 (31–659) min.

Presented at the 35th Annual Meeting of the European Association for Cardio-Thoracic Surgery, Barcelona, Spain, 13–16 October 2021.

RESULTS: Among the 6 patients who underwent preoperative CTP, 4 with salvageable ischaemic lesion (penumbra: 8–735 ml) without massive irreversible ischaemic lesion (ischaemic core: 0–31 ml) achieved acceptable neurological outcomes after emergency aortic replacement regardless of preoperative neurological severity. In contrast, 2 patients with an ischaemic core of >50 ml (73, 51 ml) fell into a vegetative state or neurological death due to intracranial haemorrhage. CTP parameters guided postoperative blood pressure augmentation without additional supra-aortic vessel intervention in the 8 patients who underwent postoperative CTP, among whom 6 achieved normal neurological function regardless of common carotid true lumen stenosis severity.

CONCLUSIONS: CTP was able to detect irreversible ischaemic core, guide critical decisions in preoperative patients and aid in determining the blood pressure augmentation for postoperative management focusing on residual brain ischaemia.

Keywords: Acute type A aortic dissection • Cerebral malperfusion • CT perfusion • Quantitative evaluation • Neurological outcome

ABBREVIATIONS

AAAD	Acute type A aortic dissection
AIS	Acute ischaemic stroke
CBF	Cerebral blood flow
CCA	Common carotid artery
CPB	Cardio-pulmonary bypass
CTP	Computed tomography perfusion
FET	Frozen elephant trunk
GCS	Glasgow Coma Scale
MRI	Magnetic resonance imaging
TAR	Total arch replacement
Tmax	Time to maximum

INTRODUCTION

The management of acute type A aortic dissection (AAAD) with malperfusion syndrome, which is certainly a lethal condition, still remains challenging. Unlike other end-organ malperfusions, cerebral malperfusion occurs at a relatively higher frequency, affecting 6–14% of patients with AAAD, and has been reported as an indicator of poor prognosis [1–4]. However, the optimal management of patients with cerebral malperfusion remains unclear. According to several distinct features of cerebral malperfusion, including the time-sensitive nature of the brain injury and concerns regarding reperfusion injury triggered by cardio-pulmonary bypass (CPB) with cerebral perfusion, decisions regarding immediate surgery for difficult clinical scenarios, such as patients with comatose neurological status and simultaneous malperfusion syndrome of the other vital organs, occasionally arise.

Several authors have advocated treatment strategies for patients with cerebral malperfusion stratified according to their preoperative symptoms, which are sometimes subjective and fluctuating depending on their vital condition [5, 6]. Although preoperative objective multimodal evaluation of the common carotid artery and/or intracranial cerebral artery has been attempted in recent years [7–9], its utility has not yet been established. For objective and quantitative evaluation, this study applied brain computed tomography perfusion (CTP), which had been already recommended by acute ischaemic stroke (AIS) guidelines to determine the treatment strategy for AIS. This study sought to determine the clinical impact and applicability of the same concept of CTP for patients with AAAD complicated with cerebral malperfusion.

PATIENTS AND METHODS

Ethics statement

This retrospective observational study was approved by the Institutional Review Board (M30-057) of National Cerebral and Cardiovascular Center, and individual informed consent from each patient was waived given its retrospective nature.

Study design

Figure 1 shows the flowchart of study enrolment between August 2019 and May 2021, during which 147 consecutive patients hospitalized for AAAD were included herein. Among the 23 (16%) patients who presented with cerebral malperfusion, 14 were ultimately enrolled in this study, of whom 6 patients underwent preoperative CTP, 2 underwent both pre- and postoperative CTP and 8 underwent only postoperative CTP. Patients' demographics are summarized in Table 1.

Diagnosis, definition and management

Cerebral malperfusion was defined as AAAD with newly developed neurological symptoms, including coma, disturbance of consciousness, neurological deficit and syncope at the onset of AAAD in the presence of radiographic and/or carotid ultrasonographic evidence of high-grade stenosis or lack of opacification through the unilateral or bilateral common carotid artery (CCA). Impaired CCA was defined as the true lumen decompression of CCA >50% regardless of false lumen patency, according to the largest series published by Kreibich *et al.* [8].

All patients were considered for immediate emergency aortic repair except for those with established cerebral oedema with or without herniation/intracranial haemorrhage. Conservative medical treatment, including withdrawal of care due to futile neurological prognosis, was occasionally selected by their family according to patients' severely deteriorated neurological condition.

Neurological and radiographic evaluation via computed tomography perfusion

Neurological examination was performed on patient arrival by the Cardiovascular Surgery and Neurology Services. The Glasgow Coma Scale (GCS) scores for each patient were obtained to assess symptom severity [10]. Coma was defined as neurological deficits

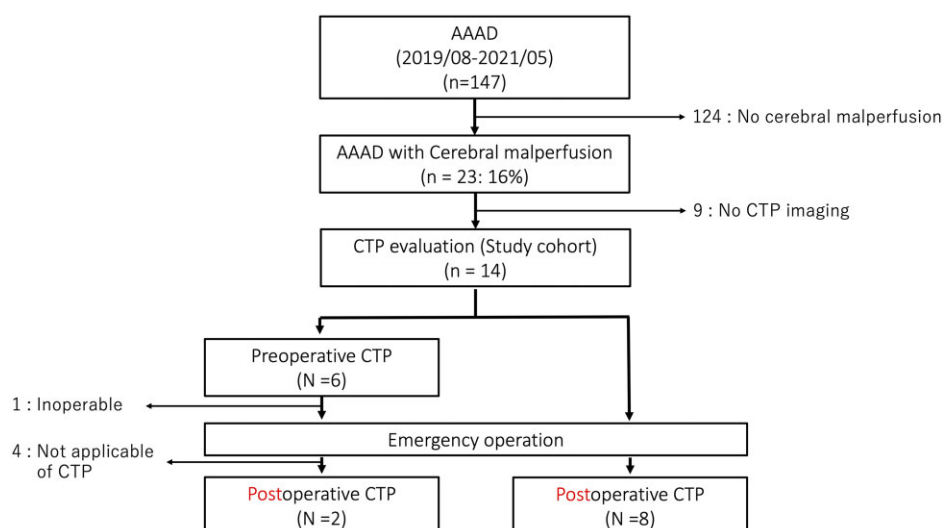


Figure 1: Flowchart of the enrolment of this study. AAAD: acute type A aortic dissection; CTP: computed tomography perfusion.

with a GCS score of <8. Neurological death was defined as a death caused by severe irreversible neurological impairment, including withdrawal of care due to a futile neurological prognosis.

CTP was performed on a 320-slice CT scanner (GE Healthcare, Waukesha, WI; Aquilion ONE; Canon Medical System, Ohtawara, Japan) including a non-contrast CT scan (120 kV, 250 mA, 4-mm axial slices) and volume CTP (z-axis = 160 mm, delay after start of contrast medium injection = 4 s, total imaging duration = 56 s, 80 kV, 120 mA, slice thickness = 5 mm, collimation = 320 mm × 0.5 mm). Even in the emergency setting, CTP can be completed only 1–2 min after the injection of contrast medium. Whole-body CT angiography can also be taken simultaneously on the same CT table and same set-up after CTP examination.

Perfusion parameters [regional cerebral blood flow (CBF) and time to maximum (Tmax)] were automatically computed using RAPID processing of Perfusion and Diffusion software through a delay-independent deconvolution approach [11–14]. Based on recent data suggesting that cerebral blood flow is more accurate than cerebral blood volume for defining ischaemic core, irreversible 'ischaemic core' was prespecified as regional cerebral blood flow <30% of contralateral hemisphere median. In contrast, salvageable 'penumbra' was prespecified as spital area Tmax ≥6 s. Based on the aforementioned parameters, ischaemic core and penumbra mismatch map was visualized to determine the treatment strategy for the brain. Figure 2 provides an example of the mismatch map.

Application of computed tomography perfusion

Preoperative CTP was conducted for preoperative neurologically impaired patients with a haemodynamically stable condition, based on assessment of neurological status by neurologist. Those with shock, evidence of pericardial effusion and any concerns regarding haemodynamics were excluded from preoperative CTP. Moreover, those with mild symptomatic status (GCS >13) after the definitive diagnosis of AAAD were not indicated for additional CTP examinations.

Postoperative CTP was performed for patients with any concerns regarding postoperative stroke within 24 h after emergency surgery. Reasons for CTP application included (i) comparison

with preoperative CTP and (ii) unavailable preoperative CTP due to concerns regarding haemodynamic instability or mild neurological symptom.

In addition, Tmax map also visualized the area Tmax >10 s, which is prespecified as the index of the collateral flow. The greater volume of the area of Tmax >10 s implicated the less collateral network flow inside the brain. According to the Tmax data, hypoperfusion intensity ratio (Tmax >10 s volume/Tmax 6 s) could be calculated as a predictive value of ongoing brain ischaemia [15].

Surgical techniques

In patients eligible for emergency surgery, CPB was immediately established using quick introduction of the double cannulation technique via the distal right axillary artery and common femoral artery based on previous studies [16]. The cannula introduced via the distal axillary artery was utilized as both a systemic perfusion line and a hemi-cerebral perfusion line after brachiocephalic artery clamping (Supplementary Material S1). If the regional tissue oxygen saturation did not improve after the establishment of CPB and initiation of right side hemi-cerebral perfusion, the origin of left CCA was clamped and cut down followed by balloon tip cerebral perfusion catheter insertion inside the true lumen of left CCA as soon as possible. For patients with cerebral malperfusion, our standard protocol involves the total arch replacement with the individual reconstruction of supra-aortic branches. Our standard protocol for surgery has been previously reported [16].

RESULTS

All patient's preoperative demographics are presented in Table 1. The median duration from onset to hospital arrival was 129 (31–659) min. Among the 6 patients (I–VI) who underwent preoperative CTP, 2 also underwent postoperative CTP immediately after the emergency surgery. The remaining 8 patients only underwent postoperative CTP due to haemodynamic instability in 3 and preoperative mild symptoms with remaining postoperatively impaired CCA in 5.

Table 1: Patients' demographics of enrolled patients

Age/ gender	Neurological symptom at onset	Neurological symptom on arrival	GCS	Preoperative shock	Duration from onset to arrival (min)	Diagnostic modality	Status of CCA Right	Left	Preoperative CTP	Postoperat- ive CTP
I 29/F	Lt hemiparesis	Asymptomatic	15	I	230	CTA MRI	Impaired ^a	Not impaired	+	I
II 52/M	Lt hemiparesis	Lt hemiparesis	10	I	345	CTA MRI	Impaired	Impaired	+	+
III 55/M	Lt hemiparesis	Lt hemiparesis	13	I	31	CTA	Impaired	Not impaired	+	+
VI 67/F	Loss of consciousness	Lt hemiparesis	11	I	129	CTA	Occluded	Not impaired	+	I
V 69/F	Dysarthria	Deep coma	3	I	120	CTA	Impaired	Impaired	+	+
VI 81/F	Disturbance of consciousness	Rt hemiparesis coma	6	I	172	CTA	Impaired	Impaired	+	I
VII 74/F	Syncope	Disturbance of consciousness	13	+	55	CT sonography	Impaired	Not impaired	I	+
VIII 83/F	coma	Disturbance of consciousness	6	+	172	CT sonography	Occluded	Impaired	I	+
IX 57/M	Syncope	Disturbance of consciousness	15	I	107	CTA	Occluded	Not impaired	I	+
X 78/F	Syncope	Asymptomatic	15	I	180	CTA	Occluded	Not impaired	I	+
XI 45/M	None	Convulsion	10	+	649	CT sonography	Occluded	Impaired	I	+
XII 46/M	None	Disturbance of consciousness	14	I	138	CTA	Not impaired	Impaired	I	+
XIII 72/F	None	Disturbance of consciousness	13	I	126	CTA	Impaired	Not impaired	I	+
XIV 76/F	None	Disturbance of consciousness	13	I	229	CT sonography	Not impaired	Impaired	I	+

^aImpaired CCA means true lumen decompression >50%.

CCA: common carotid artery; CTA: computed tomographic angiography; F: female; GCS: Glasgow Coma Scale; M: male; MRI: magnetic resonance imaging.

Preoperative computed tomography perfusion

Data for patients who underwent preoperative CTP are summarized in Table 2. All patients were neurologically symptomatic upon hospital arrival, except for 1 patient (patient no. I) who presented syncope at the onset and occlusion of the right distal mid cerebral artery with positive diffusion-weighted magnetic resonance imaging (MRI), which was sufficiently supplied by collateral artery via another collateral pathway of internal carotid artery detected on preoperative CTP.

The characteristics of 3 patients (nos. IV, V and VI) are summarized in Fig. 3 [17]. Patient V presented with dysarthria followed by a loss of consciousness. She had fallen into a deep coma upon hospital arrival 2 h after the onset. CTP revealed massive penumbra (735 ml) without a complete ischaemic core. Total arch replacement (TAR) with frozen elephant trunk (FET) was subsequently performed. The amount of penumbra dramatically improved (10 ml) on postoperative CTP immediately after surgery. The patient recovered consciousness and linguistic ability with monoparesis only in the right arm. Meanwhile, patient IV was found to have collapsed and was transferred with left hemiparesis 2 h after the last known well. The patient's GCS score was 11 (E3, V4 and M4), with CT revealing AAAD with static obstruction of the right CCA. CTP revealed an ischaemic core (57 ml) and a high volume (228 ml) of Tmax >10s, which indicated that the brain area was perfused for >10s with poor brain collaterals and that the hypoperfusion intensity ratio (Tmax >10s/Tmax >6s = 0.6) increased, suggesting rapidly progressing brain ischaemia. Emergency TAR with FET was started 2.5 h after hospital arrival. Massive intracranial bleeding was ultimately diagnosed postoperatively, and her neurological status deteriorated to a vegetative state despite craniotomy. The family of patient VI refused invasive aortic repair and selected the best supportive care due to the evidence of an ischaemic core and advanced patient's age. Unfortunately, patient VI died 1 day after admission due to cerebral haemorrhage and herniation.

Postoperative computed tomography perfusion

The perioperative characteristics of the patients are shown in Table 3. Three patients presented with preoperative shock with pericardial effusion. Among them, 2 were elderly (VII and VIII) and presented postoperative neurological deficits despite systolic blood pressure augmentation >120 mmHg. Moreover, 4 patients without postoperative penumbra achieved normal neurological status. All 4 patients who presented postoperative penumbra on CTP received postoperative systolic blood pressure augmentation >120 mmHg without additional invasive supra-aortic vessel intervention. Among them, 2 patients (VII and VIII) who presented with preoperative shock suffered from hemiparesis. The remaining 2 patients (IX and X) who exhibited transient syncope before surgery achieved postoperative normal neurological status regardless of CCA stenosis severity.

Particularly in patient X, CTP-guided systemic blood pressure augmentation played an important role in terms of postoperative decision-making. She developed syncope at the onset and was transferred 3 h after with a definitive diagnosis of AAAD with right CCA occlusion. Emergency TAR with FET procedure was then performed. After the TAR with neck vessel reconstruction, recanalization of right CCA blood flow was confirmed via direct carotid ultrasonography in the operating room. However, re-

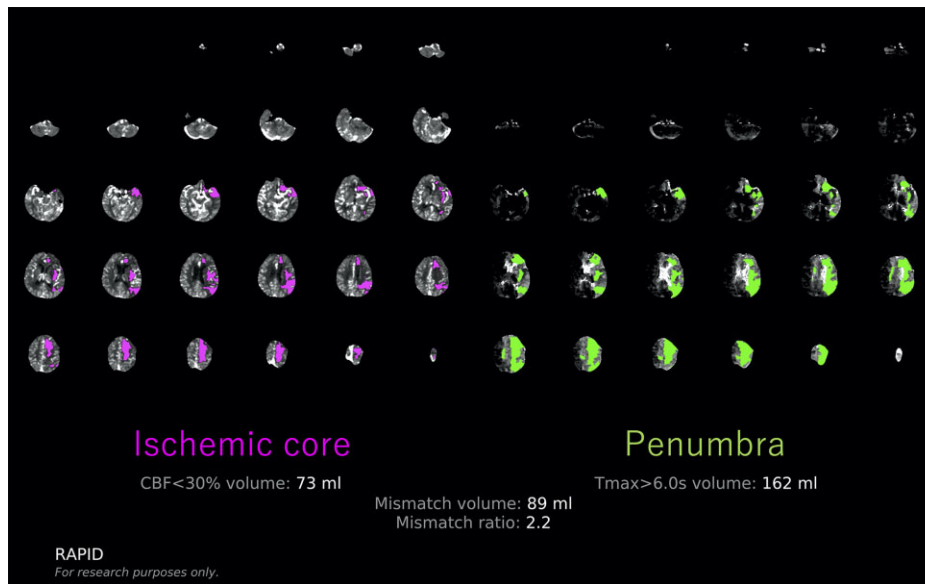


Figure 2: A ischaemic core–penumbra mismatch map automatically computed by RApid processing of Perfusion and Diffusion software using computed tomography perfusion data. Pink area presents the irreversible ischaemia as an ischaemic core. Green mark presents the salvageable ischaemic area as a penumbra.

	Patient IV		Patient V		Patient VI	
Age/gender	67 / F		69 / F		81 / F	
Onset to arrival (min)	129		120		172	
Glasgow coma scale	10		3 (deep coma)		6	
Preop CTP results	Ischemic core	Penumbra	Ischemic core	Penumbra	Ischemic core	Penumbra
Mismatch volume(ml)	296 (353-57)		735 (735-0)		89 (162-73)	
Emergency surgery	TAR + FET		TAR + FET		Inoperable	
Neurologic outcome	Intracranial hemorrhage ↓ Vegetative state		Recovery ↓ Discharge		Complete stroke ↓ Death	

Figure 3: Summary of characteristic of 3 patients with preoperative computed tomography perfusion. FET: frozen elephant trunk; TAR: total arch replacement.

occlusion of the right CCA was detected 2 h after surgery. CTP revealed a minute ischaemic core (12 ml) and penumbra volume (149 ml) and good collateral flow from the left side with a hypoperfusion intensity ratio as low as 0.08. We decided to maintain pressure augmentation (>120 mmHg) without any additional intervention. Recanalization of the right CCA was detected 12 h after initial examination, while complete remodelling was achieved on postoperative day 3. Video 1 presents the chronological series of carotid echocardiogram and intracranial blood flow in patient X. Figure 4 summarizes the pre- and postoperative CT angiography. Patient X was ultimately discharged without any neurological deficits.

DISCUSSION

Surgical outcomes for AAA have been gradually improving over the last 2 decades, with malperfusion syndrome having been

reported as an indicator of poor prognosis [3, 4]. Given the relative frequency of cerebral malperfusion compared to other end-organ malperfusions and its more frequently occurrence in younger patients [1, 2, 18], we occasionally encounter difficult decisions regarding emergency surgery indications in patients with severe neurological symptoms, such as coma.

Recently, cerebral malperfusion has been tried to be stratified by not preoperative patients’ symptom but preoperative radiographic data [5, 6, 8, 9]. However, the utility of these objective evaluations attempted in recent years remains unclear. As such, we have focused on CTP, which has been recommended by several guidelines, to quantitatively evaluate treatment strategies for AIS [19].

The current study has 3 points of discussion: (i) the utility of preoperative CTP, (ii) the utility of postoperative CTP and (iii) the application of preoperative CTP.

In patients with cerebral malperfusion, prompt surgery is not always justified given that the burden of reperfusion against the



Table 2: Perioperative characteristics in patients with preoperative CT

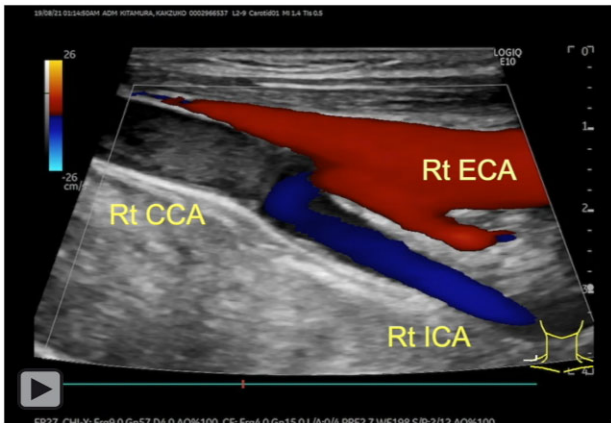
No.	Age/ gender	Preoperative data		Postoperative data				Disposition		
		Preoperative neurological issues	Duration from onset to arrival (min)	Pre-CTP findings Ischaemic core (ml)	Penumbra and HIR	Emergency surgery	Postoperative head CT findings		Post CTP findings Ischaemic core (ml)	Postoperative neurological deficit Penumbra (ml)
I	29/F	Syncope at the onset	230	0	8 (0)	TAR + VSRR	Normal	NA	None	Alive
II	52/M	Lt hemiparesis	345	0	449 (0.5)	TAR	Normal	0	4 ml	Alive
III	55/M	Lt hemiparesis	31	31	308 (0.6)	TAR	Solitary lesion of AIS	NA		Ambulatory hemiparesis
VI	67/F	Lt hemiparesis	129	57	296 (0.6)	TAR	Intracranial Haemorrhage	NA		Vegetative state
V	69/F	Deep coma	120	0	735 (0.1)	TAR	Normal	0	10 ml	Right arm monoparesis
VI	81/F	Disturbance of consciousness	172	73	89 (0.3)	NA	NA	NA	Death	Dead

AIS: acute ischaemic stroke; CTP: computed tomography perfusion; F, female; GCS: Glasgow Coma Scale; HIR: hypoperfusion intensity ratio; M: male; NA: not applicable; TAR: total arch replacement; VSRR: valve-sparing root replacement.

Table 3: Perioperative characteristics in patients with postoperative computed tomography perfusion

No	Age/ gender	Preoperative shock	Preoperative data		Postoperative data				Neurological status at discharge	
			Preoperative issues	Preoperative CCA status	Preoperative CCA status	Postoperative neurological concerns	CTP findings Ischaemic core (ml)	Penumbra (ml) and HIR		SBP augmentation
VII	74/F	+	Disturbance of consciousness Shock	Impaired Rt CCA	Impaired Rt CCA	Preoperative consciousness	4	358 (0)	SBP > 120 mmHg	Ambulatory Lt hemiparesis
VIII	83/F	+	Coma Shock	Rt CCA occlusion	Impaired Rt CCA	Preoperative coma	0	99 (0)	SBP > 120 mmHg	Lt hemiparesis Disuse syndrome
IX	57/M	-	Syncope	Rt CCA occlusion	Impaired Rt CCA	Preoperative Rt CCA occlusion	0	42 (0)	SBP > 120 mmHg	Normal function
X	78/F	-	Syncope	Rt CCA occlusion	Rt CCA occlusion	Postoperative Rt CCA occlusion	12	137 (0.08)	SBP > 120 mmHg	Normal function
XI	45/M	+	1. Convulsion 2. Visceral malperfusion 3. Shock	Rt CCA occlusion Impaired Lt CCA	Impaired bilateral CCA	Preoperative Convulsion	0	0	SBP > 120 mmHg	Normal function
XII	46/M	-	Disturbance of consciousness	Impaired Lt CCA	Impaired Lt CCA	Preoperative consciousness	0	0	Avoid hypotension	Normal function
XIII	72/F	-	Disturbance of consciousness	Impaired Rt CCA	Impaired Rt CCA	Postoperative anisocoria	0	0	Avoid hypotension	Normal function
XIV	76/F	-	Disturbance of consciousness	Impaired Lt CCA	Impaired Lt CCA	Preoperative consciousness	0	0	Avoid hypotension	Normal function

CCA: common carotid artery; CTP: computed tomography perfusion; F, female; HIR: hypoperfusion intensity ratio; M: male; SBP: systolic blood pressure; Rt: right; Lt: left; CT: computed tomography; 3D: 3 dimensional.



Video 1: Video was divided into 4 parts. Part 1 presented right common carotid echogram 2 hours after the emergency operation. Right common carotid artery was occluded and reverse flow of external carotid artery into the internal carotid artery. Part 2 presented real time intracranial cerebral blood flow after detection of re-occlusion of right common carotid artery. Right side brain was well perfused contralateral internal carotid artery. Part 3 presented right common carotid echogram 12 hours after the emergency operation. Recanalization was detected. Part 4 presented right common carotid echogram 3 days after the emergency operation. CCA: Common carotid artery; ICA: Internal carotid artery; ECA: External carotid artery.

brain occasionally evokes catastrophic results, such as intracranial bleeding with herniation. To minimize reperfusion brain injury, determining the severity of AIS is essential, for which MRI has been usually utilized. However, MRI is time-consuming and not suitable for acute-phase AAAD with possible haemodynamic instability. On the other hand, while plain brain CT is an ideally brief and rapid examination, it cannot detect ongoing AIS within 3–6 h [20]. Considering that patients included herein were transferred in the acute phase, a new modality is warranted to appropriately address cerebral malperfusion. Even in the early phase, CTP allowed for the visualization of an area of CBF <30% as an ischaemic core and Tmax lesions >6 s as a penumbra based on the mismatch concept, which has been advocated by a specialist dealing with AIS. Patients with mismatch ratios (Tmax lesion >6 s/lesion

of CBF <30%) >1.8 have been considered good candidates for aggressive intervention, including mechanical thrombectomy or thrombolysis therapy in patients with AIS. Four of our patients (I, II, III and V) who satisfied this criterion achieved acceptable neurological outcomes regardless of preoperative symptom severity. In contrast, an ischaemic core of >53 ml has been reported as an independent risk factor for post-interventional intracranial haemorrhage [12]. In the present study, 2 patients (IV and VI) with an ischaemic core >53 ml developed intracranial bleeding with herniation, suggesting that they were already included in the malignant profile in terms of the AIS. Especially in patient IV, ligation of the carotid artery to minimize the burden of reperfusion should be considered as another option. Although it still remains unclear whether these criteria directly apply to patients with cerebral malperfusion due to AAAD, quantitative evaluation using CTP should be helpful in making critical decisions and anticipating the patients' prognosis.

Historically, our approach for cerebral malperfusion due to AAAD has exclusively been focused on the timelines of surgery, surgical technique for aortic reconstruction and cerebral perfusion strategy based on preoperative symptoms. Okita *et al.* [21] presented the impact of early reperfusion strategy of right CCA established even in the emergency room. However, postoperative management could also alter neurological outcomes. Haphazard additional treatments, including high-blood pressure argumentation, intervention for impaired CCA itself, can sometimes exacerbate postoperative bleeding or thromboembolic stroke [20]. Olivot *et al.* [14] suggested that hypoperfusion intensity ratio >0.5 could predict infarct growth and poor clinical outcomes. Based on these data, we were able to select blood pressure argumentation therapy without invasive intervention of the occluded right CCA in patients VII, VIII, IX and X. In addition, ischaemic core sometimes becomes negative even in potentially positive patients. Plain head CT is also taken to detect intraoperative massive stroke to anticipate the neurological prognosis and manage the systolic pressure depending on the evidence of ischaemic core and penumbra. CTP evaluation was helpful even in the postoperative period to determine the necessity of supra-aortic vessel intervention based on hypoperfusion intensity ratio, from the viewpoint of establishing a rationale for appropriate treatment.

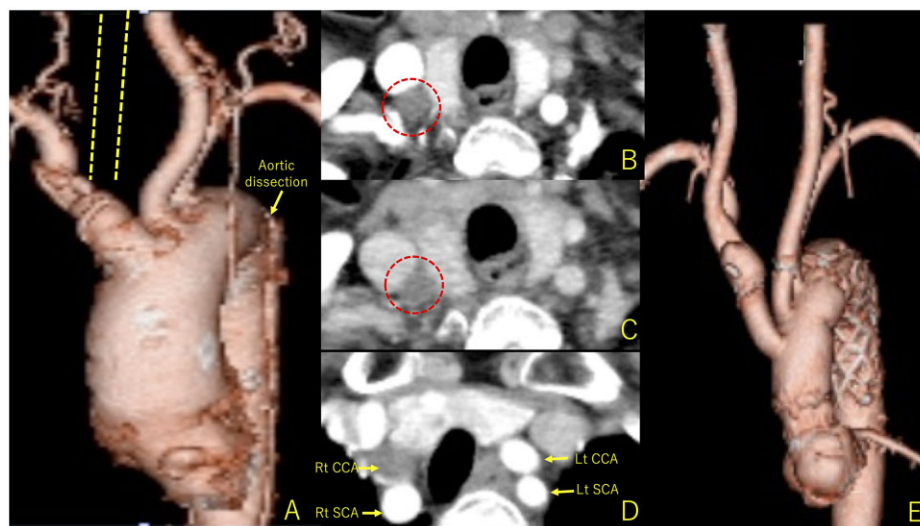


Figure 4: Pre- and postoperative CT angiography in patient number X. (A) Preoperative 3D CT. The yellow dot line implies occluded right common carotid artery and yellow arrow points dissected aorta. (B) Preoperative axial view focusing on bilateral common carotid artery in early phase; red circle emphasizes occluded right common carotid artery. (C) Preoperative axial view focusing on bilateral common carotid artery in delayed phase; red circle emphasizes occluded right common carotid artery. (D) Preoperative axial view focusing on supra-aortic branches. (E) Postoperative 3D CT. CCA: common carotid artery; SCA: subclavian artery

Ultimately, all patients with AAAD with cerebral malperfusion should ideally undergo preoperative CTP. However, from the viewpoint of patient safety, haemodynamically unstable patients should be immediately transferred to the operating room. Indeed, patients included herein who had with any concern regarding haemodynamic instability were excluded from not only CTP but also contrast medium-enhanced CT angiography given that preoperative shock has been reported as the independent risk factors for in-hospital mortality [8]. Based on our protocol, all 6 patients with cerebral malperfusion safely underwent preoperative CTP, which justified our patients' selection in terms of patient's safety. However, as a diagnostic modality, preoperative CTP can be utilized for some patients, including those who have a stable condition, were transferred in the acute phase and have moderate neurological symptoms. These limitations are common problems not only for CTP but also for time-consuming preoperative quantitative modalities. To overcome and completely manage patients with cerebral malperfusion, a multidisciplinary approach, such as intraoperative regional tissue oxygen saturation monitoring for haemodynamically unstable patients without any preoperative objective evaluation and postoperative CTP for patients with any concern regarding intracranial blood flow, would be mandatory. Although cerebral malperfusion still remains challenging, CTP can be a useful guide for making critical decisions regarding challenging clinical circumstances.

Limitations

This study has several inherent limitations worth noting. First, this was a retrospective study with a small sample size, especially in 6 of 24 malperfusion patients indicating preoperative CTP. Furthermore, important clinical variables regarding neurological prognoses, such as patient's age, comorbidities and preoperative frailty, were not incorporated into the analysis. In addition, imaging studies for the evaluation of the CTP were obtained at different time points, including immediately to several hours after neurological symptom occurrence. Further accumulation of patients' volume and investigations involving other institutions using standardized methodology are highly warranted to validate our results.

CONCLUSION

The complete management of patients with AAAD complicated with cerebral malperfusion still remains challenging. Nonetheless, CTP as an approach for quantitative evaluation was useful in detecting irreversible ischaemic core and guiding critical decisions in preoperative patients. Moreover, for postoperative management focusing on residual brain ischaemia, CTP can be helpful in diagnosing the necessity of additional intervention for supra-aortic vessels and predicting neurological prognosis.

SUPPLEMENTARY MATERIAL

[Supplementary material](#) is available at *ICVTS* online.

ACKNOWLEDGEMENT

The authors would like to thank Enago (www.enago.jp) for the English language review.

Funding

This article has no funding relevant to its content.

Conflict of interest: none declared.

Data Availability Statement

The data underlying this article cannot be shared publicly due to relevant data protection regulations. However, the data will be shared on reasonable request to the corresponding author with permission from the ethics committee.

Author contributions

Yosuke Inoue: Data curation; Formal analysis; Investigation; Methodology; Validation; Visualization; Writing—original draft; Writing—review & editing. **Manabu Inoue:** Software; Supervision; Validation; Writing—review & editing. **Masatoshi Koga:** Supervision; Validation; Writing—review & editing. **Shigeki Koizumi:** Supervision; Validation. **Koki Yokawa:** Supervision; Validation. **Kenta Masada:** Supervision; Validation. **Yoshimasa Seike:** Supervision; Validation; Writing—review & editing. **Hiroaki Sasaki:** Supervision; Validation. **Kenji Yoshitani:** Supervision; Validation; Writing—review & editing. **Hitoshi Matsuda:** Conceptualization; Project administration; Supervision; Validation; Writing—review & editing.

Reviewer information

Interactive CardioVascular and Thoracic Surgery thanks Thomas Schachner, Yutaka Okita and the other, anonymous reviewer(s) for their contribution to the peer review process of this article.

REFERENCES

- [1] Berretta P, Trimarchi S, Patel HJ, Gleason TG, Eagle KA, Di Eusanio M. Malperfusion syndromes in type A aortic dissection: what we have learned from IRAD. *J Vis Surg* 2018;4:65.
- [2] Sultan I, Bianco V, Patel HJ, Arnaoutakis GJ, Di Eusanio M, Chen EP *et al.* Surgery for type A aortic dissection in patients with cerebral malperfusion: results from the International Registry of Acute Aortic Dissection. *J Thorac Cardiovasc Surg* 2021;161:1713–1720.e1.
- [3] Yang B, Norton NL, Rosati CM, Wu XL, Kim KM, Khaja MS *et al.* Management patients with acute type A aortic dissection and mesenteric malperfusion syndrome: a 20-year experience. *J Thorac Cardiovasc Surg* 2019;158:675–687. e4.
- [4] Di Eusanio M, Patel HJ, Nienaber CA, Montgomery DM, Korach A, Sundt TM *et al.* Patients with type A acute aortic dissection presenting with major brain injury: should we operate them? *J Thorac Cardiovasc Surg* 2013;145:S213–221.
- [5] Pocar M, Passolunghi D, Moneta A, Mattioli R, Donatelli F. Coma might not preclude emergency operation in acute aortic dissection. *Ann Thorac Surg* 2006;81:1348–51.
- [6] Tsukube T, Hayashi T, Kawahira T, Haraguchi T, Matsukawa R, Kozawa S *et al.* Neurological outcomes after immediate aortic repair for acute type A aortic dissection complicated by coma. *Circulation* 2011;124: S163–7.
- [7] Nagamine H, Ueno Y, Ueda H, Saito D, Tanaka N, Miyazaki M *et al.* A new classification system for branch artery perfusion patterns in acute aortic dissection for examining the effects of central aortic repair. *Eur J Cardiothorac Surg* 2013;44:146–53.
- [8] Kreibich M, Desai ND, Bavaria JE, Szeto WY, Vallabhajosyula P, Beyersdorf F *et al.* Common carotid artery true lumen flow impairment

- in patients with type A aortic dissection. *Eur J Cardiothorac Surg* 2021; 59:490–496.
- [9] Fukuhara S, Norton EL, Chaudhary N, Burris N, Shiomi S, Kim KM *et al.* Type A aortic dissection with cerebral malperfusion: new insight. *Ann Thorac Surg* 2021;112:501–509.
- [10] Teasdale G, Jennett B. Assessment of coma and impaired consciousness. A practical scale. *Lancet* 1974;304:81–4.
- [11] Campbell BC, Weir L, Desmond PM, Tu HT, Hand PJ, Yan B *et al.* CT perfusion improves diagnostic accuracy and confidence in acute ischemic stroke. *J Neurol Neurosurg Psychiatry* 2013;84:613–8.
- [12] Inoue M, Mlynash M, Straka M, Lansberg MG, Zaharchuk G, Bammer R *et al.* Patients with the malignant profile within 3 hours of symptom onset have very poor outcomes after intravenous tissue-type plasminogen activator therapy. *Stroke* 2012;43:2494–2494-6.
- [13] Mokin M, Levy E, Saver JL, Siddiqui AH, Goyal M, Bonafe A *et al.*; SWIFT PRIME Investigators. Predictive value of RAPID assessed perfusion thresholds on final infarct volume in SWIFT PRIME (Solitaire With Intension for Thrombectomy as Primary Endovascular Treatment). *Stroke* 2017;48:932–938.
- [14] Olivot JM, Mlynash M, Inoue M, Marks MP, Wheeler HM, Kemp S *et al.* Hypoperfusion intensity ratio predict infarct progression and functional outcome in the DEFUSE 2 Cohort. *Stroke* 2014;45:1018–1023.
- [15] Ganesh A, Goyal M. Thrombectomy for acute ischemic stroke: recent insights and future directions. *Curr Neurol Neurosci Rep* 2018;18:59.
- [16] Inoue Y, Matsuda H, Omura A, Seike Y, Uehara K, Sasaki H *et al.* What is the optimal surgical strategy for Stanford type A acute aortic dissection in patients with a patent false lumen at the descending aorta? *Eur J Cardiothorac Surg* 2018;54:933–939.
- [17] Inoue Y, Inoue M, Koga M, Matsuda H. Preoperative brain computed tomographic perfusion for quantitative evaluation of cerebral malperfusion caused by acute type A aortic dissection. *JTCVS Tech* 2021;10: 190–195. DOI: 10.1016/j.xjtc.2021.09.031
- [18] Inoue Y, Matsuda H, Uchida K, Komiya T, Koyama T, Yoshino H *et al.* Analysis of acute type A aortic dissection in Japan Registry of Aortic Dissection (JRAD). *Ann Thorac Surg* 2020;110:790–798.
- [19] Powers WJ, Rabinstein AA, Ackerson T, Adeoye OM, Bambakidis NC, Becker K *et al.*; American Heart Association Stroke Council. 2018 Guidelines for the early management of patients with acute ischemic stroke: a guideline for healthcare professionals from the American Heart Association/American Stroke Association. *Stroke* 2018;49:e46–e110.
- [20] Koga M, Iguchi Y, Ohara T, Tahara Y, Fukuda T, Noguchi T *et al.* Acute ischemic stroke as a complication of Stanford type A acute aortic dissection: a review and proposed clinical recommendations for urgent diagnosis. *Gen Thorac Cardiovasc Surg* 2018;66:439–445.
- [21] Okita Y, Matsumori M, Kano H. Direct reperfusion of the right common carotid artery prior to cardiopulmonary bypass in patients with brain malperfusion complicated with acute aortic dissection. *Eur J Cardiothorac Surg* 2016;49:1282–1284.