

Angiomatous meningioma with bizarre nuclei: A case report

YANLING SHEN, XUEQING LIU and WENSHENG YANG

Department of Pathology, Army 73rd Group Military Hospital of PLA and Xiamen University Affiliated Chenggong Hospital, Xiamen, Fujian 361000, P.R. China

Received December 23, 2022; Accepted March 31, 2023

DOI: 10.3892/mco.2023.2642

Abstract. Angiomatous meningioma (AM) is a relatively rare subtype of WHO grade I meningioma. A relatively rare case of AM was recently encountered in a 45-year-old woman. The present case not only observed the typical AM histological pattern but also a large number of cells with bizarre, large, deeply staining and unevenly distributed nuclei. These cells with bizarre nuclei showed a similar pattern of immunoreactivity as meningeal epithelial cells. Although the presence of a large number of cells with bizarre nuclei in this case increased tumour cell atypia, the cells did not differ with regard to proliferative activity and mitotic imaging. Therefore, the patient was ultimately diagnosed as having AM with bizarre nuclei, WHO grade I. This manifestation of nuclear atypia and pleomorphism may be due to 'degenerative changes' in pre-existing, long-established vascular lesions, similar to those seen in degenerative schwannomas and symplastic haemangioma, rather than being considered an indicator of malignancy.

Introduction

Angiomatous meningioma (AM) is a relatively rare subtype of WHO grade I meningioma, constituting 3.24% of grade I meningiomas and 2.1% of all meningiomas (1-2). Angiomatous meningioma (AM) is a relatively rare variant of WHO grade I meningioma, which features a predominance of blood vessels over meningioma cells. The vascular channels may be small- or medium-sized, thin-walled or thick, and most are small with markedly hyalinized walls. AM is usually characterized by the onset of slow progressive symptoms and the main symptoms result from compression of the adjacent structures. Headache and epilepsy are the initial clinical manifestations. AMs are similar to other types of meningiomas in that they are more likely to be caused by radiation than by sex hormone levels in women. The current treatment for this disease is mainly

complete surgical resection supplemented by radiotherapy, and the prognosis is good. We recently encountered a relatively rare case of AM in a 45-year-old woman. In our case, we not only observed the typical AM histological pattern but also a large number of cells with bizarre, large, deep staining and unevenly distributed nuclei. Our report may be the first to describe the presence of bizarre nuclei in AM.

Case reports

A 45-year-old female patient presented to the hospital because of intermittent headache for more than one year. The patient had pain and discomfort on the left side of the head, lasting from a few minutes to 1 h, accompanied by nausea and vomiting in severe cases, which were relieved after rest. There was no dizziness, blurred vision, body convulsions or sensory disorders, language disability, or abnormality during physical examination upon admission. Magnetic resonance imaging (MRI) of the brain detected a soft tissue mass attached to the meninges in the right frontal lobe (Fig. 1), which was subsequently resected. The CT examination of this patient was performed at another hospital, and the patient had already been discharged when the results of the pathological examination appeared, so I did not review these CT images at the time of the patient's diagnosis or treatment. The tumour was excised and submitted for histological examination.

At the macroscopic level, the formalin-fixed surgical specimen of the tumour tissue and dura mater tissue was 2.0x2.0x0.8 cm in size. The tissues were grey-white in colour and smooth. Microscopically, dense small vessels (Fig. 2A) and thick-walled large vessels (Fig. 2B) were interwoven to form a vascular network, most of which were hyalinized, and some tumour cells could be seen within the vascular network. The whirlpool-like structure of meningioma was faintly seen in the focal area (Fig. 2C). In addition to the translucent blood vessels and meningeal cells seen above, a large number of cells with bizarre, large, deeply staining and unevenly distributed nuclei were also seen (Fig. 2D) (10% neutral formalin was fixed for 24 h and H&E staining at room temperature for 10 min, light microscope, slicing thickness of 4 μ m). No mitotic figures were observed in any cells.

Immunohistochemically, the meningeal epithelial cells were strongly positive for Vimentin and SSTR2A (Fig. 2E), and EMA (Fig. 2F) was focally positive. PR was partially positive. CD34 and ERG (Fig. 2G) showed positive staining on vascular endothelial cells and negative staining on tumour cells.

Correspondence to: Mr. Wensheng Yang, Department of Pathology, Army 73rd Group Military Hospital of PLA and Xiamen University Affiliated Chenggong Hospital, 94 Wenyuan Road, Xiamen, Fujian 361000, P.R. China
E-mail: yws_huoyun@126.com

Key words: meningioma, angiomatous meningioma, case report

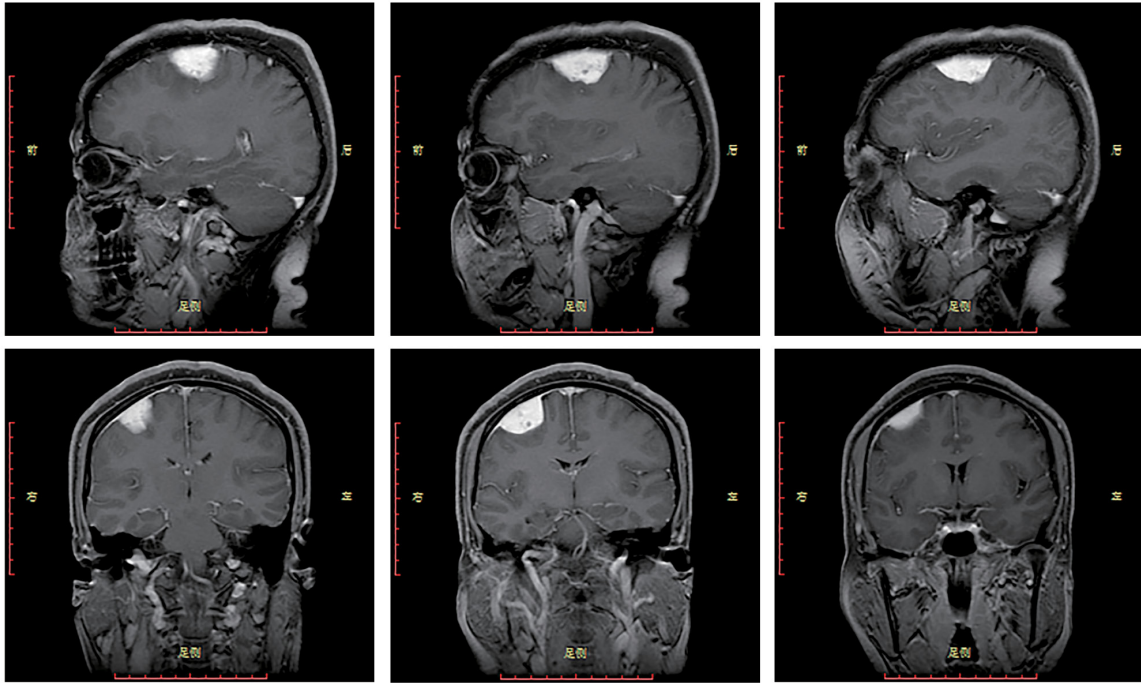


Figure 1. Magnetic resonance imaging showing a soft tissue mass attached to the meninges in the right frontal lobe.

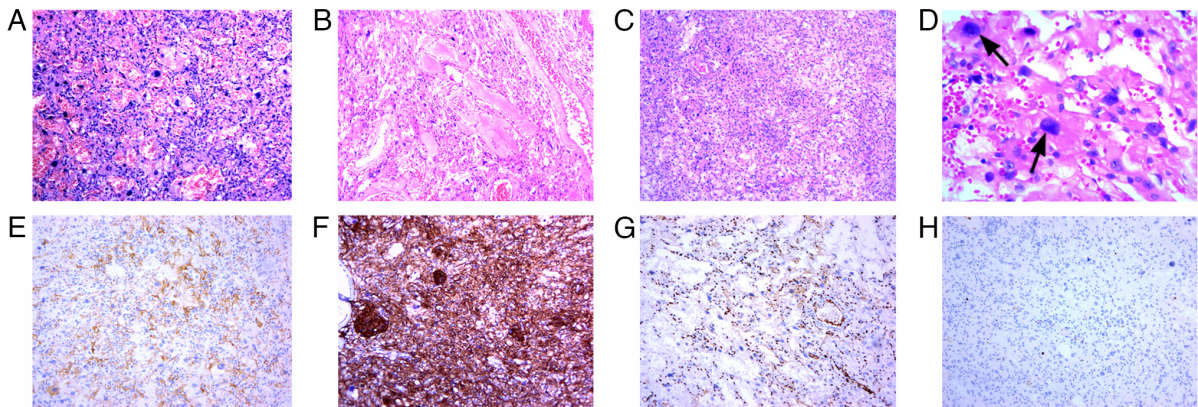


Figure 2. Microscopic findings. Haematoxylin and eosin staining showing (A) dense small vessels or (B) thick-walled large vessels interweaving to form a vascular network (magnification, x100). (C) The whirlpool-like structure of meningioma is faintly seen in the focal area (magnification, x100). (D) A large number of cells with bizarre, large, deep staining and unevenly distributed nuclei were also observed (magnification, x400). Immunohistochemically, meningeal epithelial cells were strongly positive for (E) Vimentin and SSTR2A and (F) EMA was focally positive (magnification, x100). (G) ERG showed positive staining on vascular endothelial cells and negative staining on tumour cells (magnification, x100). (H) The MIB-1 (Ki-67) labelling index was <3% (magnification, x100).

GFAP, Olig-2 and HMB45 were negative. The MIB-1(Ki-67) (Fig. 2H) labelling index was less than 3% (SSTR2A, EMA, ERG and Ki-67 staining at 37°C for 5 min, light microscope, slicing thickness of 4 μ m). The cells with bizarre nuclei had the same immunophenotype as meningeal epithelial cells. This was diagnosed as angiomatous meningioma with bizarre nuclei, WHO grade I.

Discussion

Angiomatous meningioma (AM) is a relatively rare subtype of WHO grade I meningioma, constituting 3.24% of grade I meningiomas and 2.1% of all meningiomas (1). Hasselblatt *et al* defined AM as any meningioma whose vascular component

exceeds 50% of the total tumour area, and AM is divided into two histological subtypes: the macrovascular subtype (diameter of >50% of all vessels larger than 30 μ m) and the microvascular subtype (diameter of >50% of all vessels smaller than 30 μ m) (2). In our case, we not only observed the typical AM histological pattern but also a large number of cells with bizarre, large, deeply staining and unevenly distributed nuclei. These cells with bizarre nuclei showed a similar pattern of immunoreactivity as meningeal epithelial cells, including SSTR2A (somatostatin receptor 2A) positivity, which is a prominent immunomarker of meningioma (3). Although the presence of a large number of cells with bizarre nuclei in this case increases tumour cell atypia, the cells did not differ with regard to proliferative activity and mitotic imaging. Therefore, according to

the published revised WHO 2016 guidelines (4), our case did not meet grade II meningioma and even grade III meningioma criteria. Therefore, we ultimately diagnosed the patients as having 'AM with bizarre nuclei, WHO grade I' by exclusion of the other types.

AM with bizarre nuclei has been very rarely reported. We performed a systematic search of Medline and PubMed and found few reported cases of AM and even fewer reports of angiomatous meningioma with bizarre nuclei. In 2004, Hasselblatt *et al* systematically analysed the clinicopathological characteristics of 38 consecutive AM patients (2). In 2013, Liu *et al* (5) retrospectively studied the clinical presentation, neuroimaging results, and treatment follow-up of 27 AM patients, and in 2016, Ben Nsir *et al* conducted the largest multicentre long-term follow-up study of 58 AM patients (6). AM with bizarre nuclei is not mentioned in the above literature. Therefore, our report may be the first to describe the presence of bizarre nuclei in AM. The presence of cells with bizarre nuclei in AM does not bear clinical consequences; that is, they are not a feature associated with grade II or grade III meningiomas. This manifestation of nuclear atypia and pleomorphism may be due to 'degenerative changes' in pre-existing, long-established vascular lesions, similar to those seen in degenerative schwannomas and symplastic haemangioma, rather than being considered an indicator of malignancy. Differential diagnoses of AM include the following: 1) vaso-genic tumour, especially angiosarcoma; 2) hemangioblastoma; and 3) others, such as solitary fibrous tumours (SFTs) and malignant melanoma. These tumours can be well identified by immunophenotype.

The most common aberration in grade I meningiomas is monosomy of chromosome 22, with resultant loss of the neurofibromatosis 2 (NF2) gene on chromosome 22q (7). This aberration is frequently the only copy number change in WHO grade I meningiomas (8). However, Abedalthagafi *et al* demonstrated that AM is distinct from other meningiomas, bearing numerous chromosomal polysomies and lacking mutations characteristic of other meningioma subtypes. In addition, chromosomal alterations usually involve chromosome 5 (9).

There are no established screening guidelines for meningioma. Gross total resection is still the treatment of choice, including dural attachment and infiltrated bone (10). The patient was followed up for more than 2 years, and no recurrence was found.

In conclusion, to the best of our knowledge, the present report is the first to describe the presence of bizarre nuclei in AM. This manifestation of nuclear atypia and pleomorphism was related to degenerative changes and a long clinical history. Nevertheless, knowledge of such histological changes certainly may aid in the diagnosis of AM.

Acknowledgements

Not applicable.

Funding

No funding was received.

Availability of data and materials

The datasets used and/or analysed during the current study are available from the corresponding author on reasonable request.

Authors' contributions

YS and WY participated in the study design. YS wrote the manuscript. XL provided all clinical data of the patient and performed the histologically stained of the specimens. YS and WY confirm the authenticity of all the raw data. WY and XL revised the manuscript. All authors read and approved the final manuscript.

Ethics approval and consent to participate

Not applicable.

Patient consent for publication

Not applicable.

Competing interests

The authors declare that they have no competing interests.

References

- Mehdorn HM: Intracranial meningiomas: A 30-year experience and literature review. *Adv Tech Stand Neurosurg*: 139-184, 2016.
- Hasselblatt M, Nolte KW and Paulus W: Angiomatous meningioma: A clinicopathologic study of 38 cases. *Am J Surg Pathol* 28: 390-393, 2004.
- Menke JR, Raleigh DR, Gown AM, Thomas S, Perry A and Tihan T: Somatostatin receptor 2a is a more sensitive diagnostic marker of meningioma than epithelial membrane antigen. *Acta Neuropathol* 130: 441-443, 2015.
- Louis DN, Perry A, Reifenberger G, von Deimling A, Figarella-Branger D, Cavenee WK, Ohgaki H, Wiestler OD, Kleihues P and Ellison DW: The 2016 World Health Organization Classification of Tumors of the Central Nervous System: A summary. *Acta Neuropathol* 131: 803-820, 2016.
- Liu Z, Wang C, Wang H, Wang Y, Li JY and Liu Y: Clinical characteristics and treatment of angiomatous meningiomas: A report of 27 cases. *Int J Clin Exp Pathol* 6: 695-702, 2013.
- Ben Nsir A, Chabaane M, Krifa H, Jeme H and Hattab N: Intracranial angiomatous meningiomas: A 15-year, multicenter study. *Clin Neurol Neurosurg* 149: 111-117, 2016.
- Goutagny S and Kalamarides M: Meningiomas and neurofibromatosis. *J Neurooncol* 99: 341-347, 2010.
- Choy W, Kim W, Nagasawa D, Stramotas S, Yew A, Gopen Q, Parsa AT and Yang I: The molecular genetics and tumor pathogenesis of meningiomas and the future directions of meningioma treatments. *Neurosurg Focus* 30: E6, 2011.
- Abedalthagafi MS, Merrill PH, Bi WL, Jones RT, Listewnik ML, Ramkissoon SH, Thorner AR, Dunn IF, Beroukheim R, Alexander BM, *et al*: Angiomatous meningiomas have a distinct genetic profile with multiple chromosomal polysomies including polysomy of chromosome 5. *Oncotarget* 5: 10596-10606, 2014.
- Proctor DT, Ramachandran S, Lama S and Sutherland GR: Towards molecular classification of meningioma: Evolving treatment and diagnostic paradigms. *World Neurosurg* 119: 366-373, 2018.



This work is licensed under a Creative Commons Attribution-NonCommercial-NoDerivatives 4.0 International (CC BY-NC-ND 4.0) License.