

Trauma and reconstruction

## The value of pre-operative MRI in management of penile fractures

Sankara Varun Bhoopathy<sup>a,\*</sup>, Lawrence H. Kim<sup>a,b</sup><sup>a</sup> Urology Department, Westmead Hospital, Westmead, NSW, 2145, Australia<sup>b</sup> Discipline of Surgery, Sydney Medical School, The University of Sydney, Sydney, Australia

## ARTICLE INFO

## Keywords:

Penile fracture  
mri penis  
Magnetic resonance imaging  
Penis  
Rupture

## ABSTRACT

Penile fracture is a urological emergency which requires urgent assessment and surgical intervention to avoid long term complications. In this report, we describe a case in which penile MRI was used for initial assessment and surgical planning. This allowed exact localisation of the tunical tear and allowed direct incision over the tear for repair. In this case, the man avoided circumcision, which would be often required with the conventional degloving approach.

## Introduction

Penile fracture is defined as the disruption of the tunica albuginea with a corporeal tear induced by blunt trauma to the erect penis. In the western world the most common cause is traumatic coitus.<sup>1</sup> Penile fracture is generally a clinical diagnosis without the need for imaging, however several imaging modalities are available to confirm diagnosis. These include fluoroscopic guided cavernosography, ultrasonography, and magnetic resonance imaging (MRI).<sup>2</sup> High sensitivity of MRIs in penile fractures have been described previously,<sup>3</sup> however the primary benefit of MRIs is the ability to localise the site of the tunical tear.

Penile fractures are a urological emergency that requires prompt repair of the tunica albuginea to avoid long-term complications such as penile deformity, erectile dysfunction and urinary dysfunction.<sup>1</sup> Various surgical approaches can be undertaken to evacuate the haematoma, identify the tunical injury and repair the defect. The most used approach and the most invasive is the circumferential de-gloving incision. Other approaches include an incision over the haematoma, penoscrotal, and perineal incisions.

We describe of a case of a penile fracture in an uncircumcised man who had a direct incision over the fracture site guided by the pre-operative MRI. He avoided circumcision which otherwise could have been inevitable with the de-gloving incision approach.

## Case presentation

A 42yr old man presented with penile pain of one hour duration after hearing a popping sound and sudden detumescence whilst having

reverse cow-girl sexual intercourse with his wife. However, he reported achieving multiple erections post the initial injury. On examination there was significant penile swelling and bruising (Fig. 1) – but no areas of tenderness or haematoma was palpable, we were not able to distinguish if a fracture was present proximally, distally or on which side. There was no haematuria. Normally the clinical examination alone would have warranted a penile exploration, possibly through a degloving incision. Given the unclear history of recurrent erections, an urgent MRI was performed within 30minutes of presentation. The patient was in supine position, and his penis taped to the abdomen. Triplanar T2 sequences with and without fat saturation, axial and coronal T1, and sagittal STIR sequences targeted to the previous sequences were obtained. The MRI identified a disruption of the tunica albuginea of the mid shaft of the right corpus cavernosum measuring 11mm wide, with associated 2cm haematoma (Fig. 2).

The patient proceeded to a surgical exploration where a direct 1cm incision was made at the fracture site identified using cognitive guidance in comparison to the MRI images. The incision was further extended due to the large haematoma (Fig. 3). A 1 cm defect in the tunica was identified which repaired with 3/0 ticon mattress sutures. At 3-month review post operatively the patient was achieving erections sufficient for intercourse without medications.

## Discussion

MRIs are well known to have high sensitivity and negative predictive value in identifying tunical ruptures in penile fractures, with a recent study reporting a 100% sensitivity and 87.5% specificity within a

\* Corresponding author. Tel.: +61 2 8890 5555; fax: +61 2 5633 1010.

E-mail address: [mail@vaboo.org](mailto:mail@vaboo.org) (S.V. Bhoopathy).

<https://doi.org/10.1016/j.eucr.2020.101185>

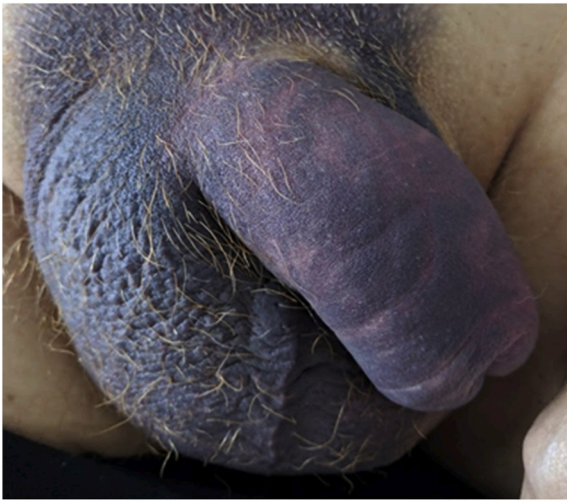Received 21 March 2020; Accepted 27 March 2020

Available online 6 April 2020

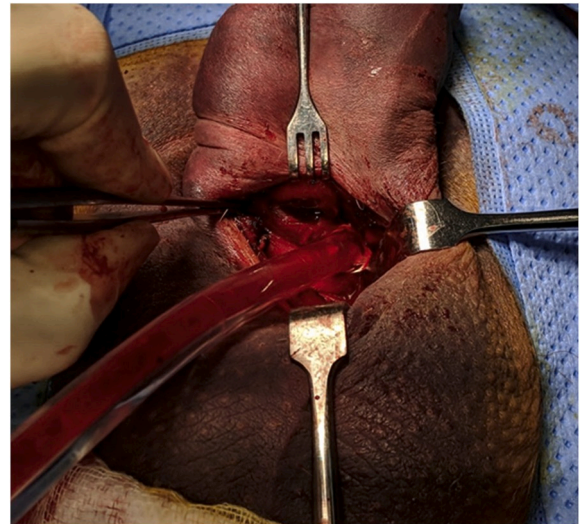
2214-4420/© 2020 The Authors. Published by Elsevier Inc.

This is an open access article under the CC BY-NC-ND license

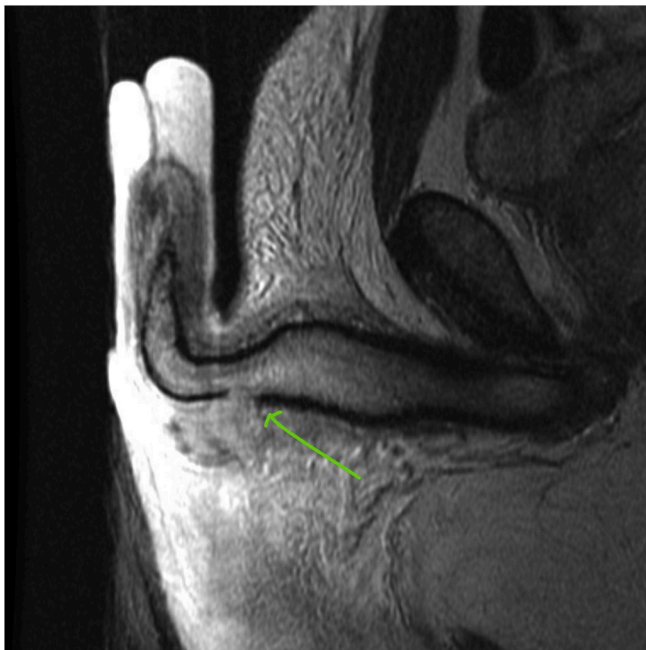
(<http://creativecommons.org/licenses/by-nc-nd/4.0/>).



**Fig. 1.** Patient with extensive bruising. Unable to identify the site of the fracture on clinical examination alone.



**Fig. 3.** A 3cm lateral incision directly over the defect.



**Fig. 2.** T2 weighted axial slice showcasing a focal defect in the tunica overlying the right corpus cavernosum.

sample size of 31 patients.<sup>3</sup> We wanted to highlight by reporting on this case, some of the unforeseen utilities of performing pre-operative MRIs in patients with suspected penile fracture.

Firstly, the classical surgical degloving of the penis with a circumferential incision can cause significant morbidity through diffuse swelling of the dartos fascia. A pre-operative MRI can help surgical planning by localising the defect in the tunica albuginea which can allow a direct incision. Furthermore, there is a potential to improve cosmetic outcomes by avoiding circumcision in those who are uncircumcised. Some men may also refuse circumcision. In future, perhaps there is a role of placing skin fiducial markers prior to the MRI which can further help isolate the fracture.<sup>4</sup>

Secondly, in cases where clinical history and physical examination may not be adequate in making a clinical decision, an urgent MRI can play a pivotal role in diagnosis. While surgical exploration remains a viable option for diagnosis and management, pre-operative MRI can

avoid unnecessary exploration and morbidity. Conversely, an expedited MRI which shows a fracture in these cases can lead to urgent surgical repair to avoid complications and optimise outcomes.

There are however some pitfalls that should be considered. MRIs have a reported lower accuracy, sensitivity of 60%, in identifying concomitant urethral injuries in patients with penile fracture.<sup>5</sup> In suspected penile fracture patients with haematuria, further investigation through cystoscopy should be considered. In an emergent setting, not only can the physical access to an MRI facility be limited, but also there could be a lack of radiological expertise in reporting penile MRIs as it is a rare presentation. Additionally, confidence in interpreting penile fractures on MRI may be low in inexperienced Urologists.<sup>5</sup> And of course, the cost of performing an urgent MRI is always a consideration.

## Conclusion

In health facilities that have easy access to MRI scanners, and in men with suspected penile fracture, an urgent pre-operative MRI could be considered as part of their assessment and management. This could potentially reduce morbidity, particularly in uncircumcised men.

## Consent

The patient has given informed consent to the usage of clinical history, anonymised photographs and medical imaging for this report.

## Declaration of competing interest

None.

## CRediT authorship contribution statement

**Sankara Varun Bhoopathy:** Conceptualization, Data curation, Writing - original draft, Writing - review & editing. **Lawrence H. Kim:** Conceptualization, Data curation, Writing - original draft.

## References

- Bozzini G, Albersen M, Otero JR, et al. Delaying surgical treatment of penile fracture results in poor functional outcomes: results from a large retrospective multicenter European study. *European urology focus*. 2018;4(1):106–110.
- Guler I, Ödev K, Kalkan H, Simsek C, Keskin S, Kiliç M. The value of magnetic resonance imaging in the diagnosis of penile fracture. *Int Braz J Urol*. 2015;41(2): 325–328.

3. Saglam E, Tarhan F, Hamarat MB, et al. Efficacy of magnetic resonance imaging for diagnosis of penile fracture: a controlled study. *Invest Clin Urol*. 2017;58(4):255–260.
4. Eccles C, Whitaker J, Nyland J, Roberts C, Carlson J, Zamora R. Skin fiducial markers enable accurate computerized navigation resection of simulated soft tissue tumors: a static cadaveric model pilot study. *J Surg Oncol*. 2018;118(3):510–517.
5. Sokolakis I, Schubert T, Oelschlaeger M, et al. The role of magnetic resonance imaging in the diagnosis of penile fracture in real-life emergency settings: comparative analysis with intraoperative findings. *J Urol*. 2019;202(3):552–557.