



Contents lists available at ScienceDirect

International Journal of Surgery Case Reports

journal homepage: www.casereports.com

Metal on metal total hip arthroplasty and a large groin mass: Not always adverse reaction to metallic debris



Harry Krishnan^a, Alex Magnussen^{b,*}, Aadhar Sharma^b, John Skinner^c

^a *Spr Trauma and Orthopaedics, Northwick Park Hospital, UK*

^b *Spr Trauma and Orthopaedics, Royal National Orthopaedic Hospital, UK*

^c *Consultant Truma and Orthopaedics, Royal National Orthopaedic Hospital, UK*

ARTICLE INFO

Article history:

Received 29 May 2014

Accepted 7 October 2014

Available online 8 December 2014

Keywords:

Metal-on-metal

Pseudotumour

Adverse reaction to metallic debris

Revision arthroplasty

ABSTRACT

Due to their improved wear rates, Metal-on-metal bearings have been increasingly used in the past decade by orthopaedic surgeons carrying out total hip arthroplasty. However there is increasing evidence that there are significant complications associated with such implants. One well documented complication is that of metallic debris leading to pseudotumour formation, however there is less known about associations with other tumours within the pelvis. We present two cases where an intra-pelvic mass in patients with metal-on-metal implants were diagnosed as being of a different aetiology. This highlights the need for careful assessment of such patients in order to guide appropriate management.

© 2014 The Authors. Published by Elsevier Ltd. on behalf of Surgical Associates Ltd. This is an open access article under the CC BY-NC-ND license (<http://creativecommons.org/licenses/by-nc-nd/3.0/>).

1. Introduction

Metal-on-metal (MoM) bearings have been used with increasing frequency by orthopaedic surgeons over the past decade due to potential improvements in wear rates compared to more conventional implants, especially in younger patients.¹ Recently published research has however revealed a number of significant complications associated with MoM bearings^{2–4} culminating in national UK guidelines for follow-up and investigation in symptomatic patients.⁵ There is release of metallic debris which is thought to cause adverse local and distant problems.⁶ Pseudotumours are inflammatory soft tissue lesions well known to be found surrounding failing MoM implants.⁷ Histological analysis of these masses have found them to be sterile and consisting mostly of macrophages aggregating around metal particles.⁸

The relationship between MoM bearings and the development of other tumours is less well documented. A recent study published on behalf of the National Joint Registry of England and Wales retrospectively analyzed the post-operative outcomes and cancer risk of patients with MoM hip implants compared to the general population.⁹ Although no link between MoM implants and cancer was found, further conclusive studies were recommended on the effect of metal debris exposure. To date there is no current literature suggesting or proving any association between MoM bearings

and benign peri-prosthetic soft tissue lesions apart from pseudotumour.

We present 2 cases, one male and one female, of post operative MoM patients presenting with groin masses. These were both fully investigated with a high index of suspicion for pseudotumour. However following histological and radiological analysis, they were diagnosed as a benign lipoma and ovarian cysts respectively. They were both found to be unrelated to the implants. To the best of our knowledge, there have been no previous reports of example of either lesion in a patient with MoM THA.

2. Case report 1

A 65-year-old man was referred to our tertiary centre with an 18-month history of worsening severe right hip pain and an audible grinding. The pain woke him most nights and he had difficulty walking. The patient had previously undergone uncomplicated bilateral MoM THAs (Corail/Pinnacle Ultramet, DePuy, Warsaw, Indiana, USA) for osteoarthritis in 2005 (right) and 2006 (left) at a local hospital. Both total hip replacement's had a 36 mm femoral head component with articular surfaces consisting of cobalt-chromium-molybdenum (CoCrMo).

In addition to the pain, he complained of a large ipsilateral soft tissue groin mass which was enlarging, particularly over the past 6 months. The patient was otherwise well with no history of other masses, weight loss or night sweats. He had no significant past medical history.

Examination revealed normal vital signs and an antalgic gait with a well healed posterolateral surgical scar over the right hip. There was a large compressible lobular soft tissue mass in the right

* Corresponding author. Tel.: +44 7764603313.

E-mail addresses: harry.krishnan02@imperial.ac.uk (H. Krishnan), Apm0044@gmail.com (A. Magnussen).

<http://dx.doi.org/10.1016/j.ijscr.2014.10.017>

2210-2612/© 2014 The Authors. Published by Elsevier Ltd. on behalf of Surgical Associates Ltd. This is an open access article under the CC BY-NC-ND license (<http://creativecommons.org/licenses/by-nc-nd/3.0/>).

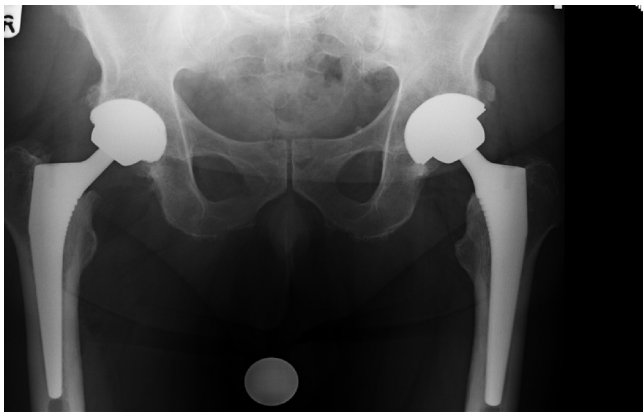


Fig. 1. Pre operative AP pelvic radiograph demonstrates bilateral metal on metal total hip replacements.

groin distal to the femoral pulse. This was non-tender and tethered to subcutaneous tissues with no local lymphadenopathy. Right hip range of movement was significantly limited due to pain throughout and irritability on passive rotation. There was no abnormality on spinal, neurological and knee examination.

Plain radiographs of the pelvis and hip showed a right MoM THA in a satisfactory position with no features of loosening, osteolysis or wear (Fig. 1). The white cell count was $8.4 \times 10^9/L$, erythrocyte sedimentation rate 7 mm/h and C reactive protein <1 mg/L. Serum metal ion levels were elevated: chromium (Cr) 10 ppb (normal range 0–0.5 ppb) and cobalt (Co) 12 ppb (normal range 0–0.4 ppb). Metal artifact reduction sequence (MARS) magnetic resonance imaging (MRI) identified a 23 cm \times 13 cm \times 5.7 cm purely fatty mass extending from the pelvis lying lateral to the distal psoas muscle to the iliopsoas tendon insertion in the proximal thigh (Fig. 2). It surrounded the femoral vessels in the proximal thigh region and also extended between the lesser trochanter and the ischium. The appearances were consistent with an atypical lipomatous tumour.

Based on the investigations the decision to revise the failing MoM THA with excision biopsy of the mass was made. The operative procedure was performed under general anaesthesia via two separate incisions: anterior longitudinal groin (supine position) for the soft tissue mass and posterolateral hip (lateral position) for the revision THA. A large fatty mass approximately 23 cm \times 13 cm \times 6 cm in size was found directly over the femoral neurovascular bundle. This was protected and preserved throughout excision (with a small capsular breach) with subsequent histological analysis. The revision THA was performed via a standard posterior approach with aspiration of joint fluid sent for microbiological analysis prior to prophylactic antibiotics and capsulectomy. There was evidence of mild metallosis and with no significant local soft tissue reaction or muscle damage. The capsule samples were sent for histological analysis. The hip was dislocated and the CoCrMo head removed showing evidence of wear on the trunnion and taper. The femoral and acetabular components were well fixed with no obvious signs of infection or osteolysis. The femoral component was found to be in 10° of anteversion and the neck shaft angle was 135° . The decision was made to retain the femoral component. The acetabular component was in 25° anteversion and 45° inclination, however it was removed using an explant (Zimmer, Warsaw, Indiana, USA) without significant residual bone loss. A Pinnacle 52 mm uncemented press-fit porous coated cup with a Marathon 52/32 mm 10° lipped polyethylene liner (DePuy, Warsaw, Indiana, USA) were inserted. A BioBall Taper adapter (WG Healthcare, Lechworth, Hertfordshire, UK) was applied to the trunnion of the retained femoral stem with a 32 mm Biolox Delta

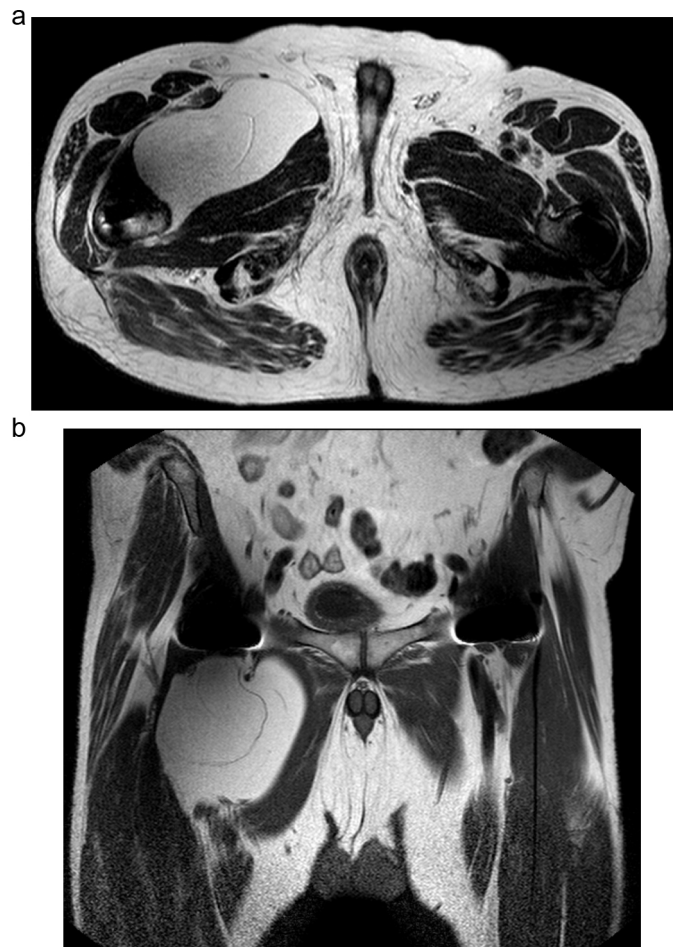


Fig. 2. T1 weighted Magnetic Resonance Image (a) axial and (b) coronal view. The very large soft tissue mass is seen between alongside the right iliopsoas tendon.

ceramic head (Zimmer, Warsaw, Indiana, USA) A stable reduction was achieved.

The post-operative course was uncomplicated and the patient was discharged after 5 days of inpatient stay. He was reviewed in clinic 8 weeks post operatively with only mild hip discomfort and mobilising the aid of one crutch. The surgical wounds had healed well without evidence of local recurrence and hip motion was reasonable. Radiographs obtained post operatively were satisfactory with no adverse features (Fig. 3). His WOMAC hip score improved from 29.7 preoperatively to 50 post-operatively. He also showed an improvement in his UCLA activity score which improved from 3 to 6.

Peri-prosthetic tissues and the soft tissue mass were fixed in 10% buffered formalin and processed into paraffin wax using routine histological methods. Haematoxylin and Eosin (H&E) – stained sections were examined using a light microscope. The large mass was identified as a lipomatous tumour composed of lobules of well-differentiated adipose tissue separated by fibrous septa (Fig. 4). There were scattered cells with hyperchromatic nuclei. These features were most consistent with a benign lipoma with no evidence of metallosis. On the contrary, the peri-prosthetic tissue was composed of fibrous tissue with a pseudosynovial membrane and diffuse collections of finely pigmented macrophages containing wear debris (Fig. 5). This suggests a diagnosis of metallosis. Of note microbiological analysis revealed no evidence of an infective process.

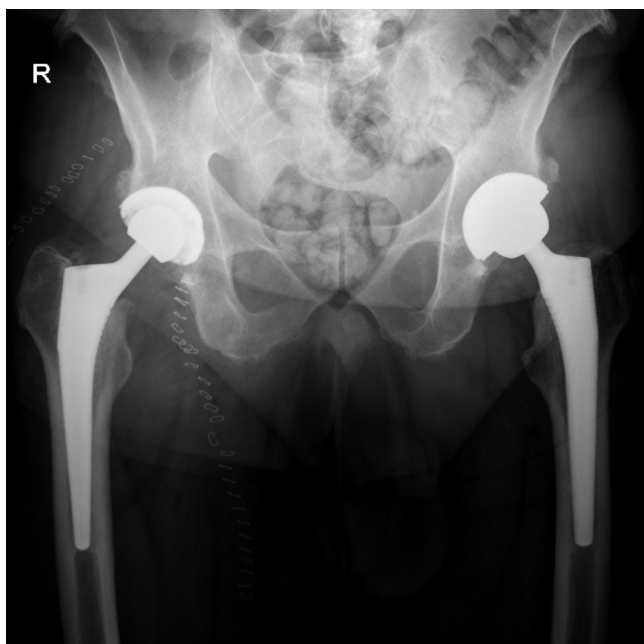


Fig. 3. Postoperative AP pelvic radiograph showing revised head and acetabular component.

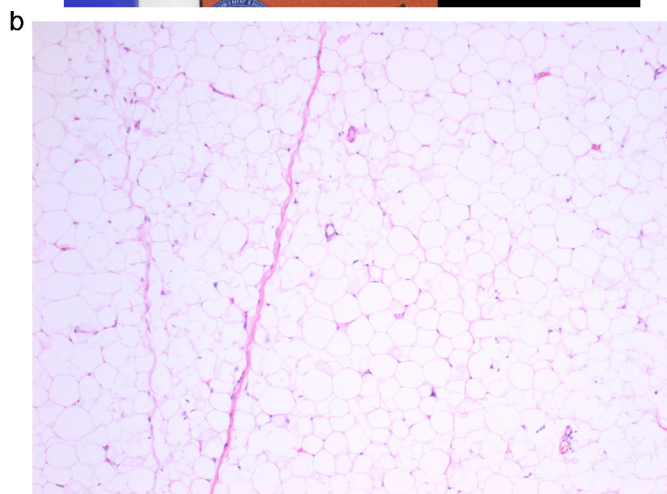


Fig. 5. (a) Macroscopic specimen of the joint capsule (b) microscopic image showing finely pigmented macrophages containing wear debris.

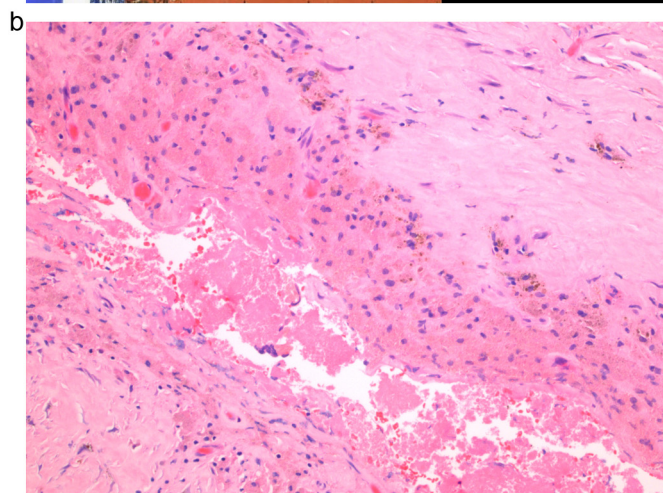
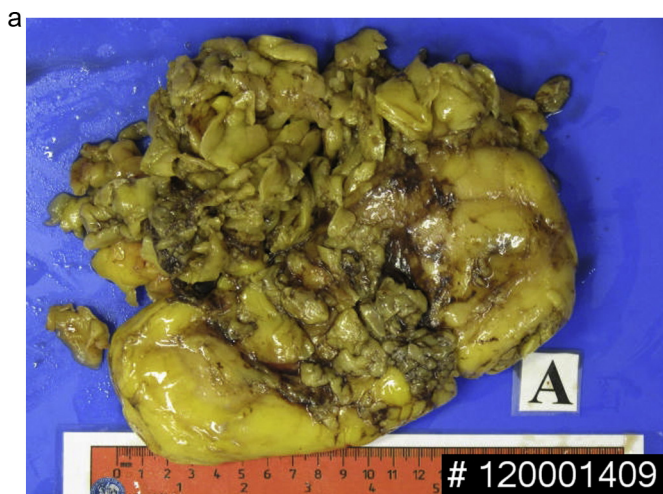


Fig. 4. (a) Macroscopic specimen showing very large lipomatous mass (b) microscopic image showing mature adipocytes with hyperchromatic nuclei.

3. Case report 2

A 57-year-old lady presented back to our tertiary care centre with new onset right groin pain exacerbated by routine exercise. This patient had undergone an uncomplicated right-sided Birmingham hip resurfacing operation on our unit 5 years previously.

In addition to moderate pain in the right groin crease she also reported intermittent “electric shocks” radiating around to her flank and a worsening bloating sensation in her abdomen. Comprehensive clinical examination of her hip, spine, knee and peripheral nerves was unremarkable. There was no palpable mass on abdominal examination.

Plain radiographs confirmed the prosthesis was still in a satisfactory position with no features of loosening, osteolysis or wear (Fig. 6). Inflammatory markers were within normal limits. Serum metal ions were elevated: serum chromium (Cr) 79.5 ppb (normal range 0–0.5 ppb) and cobalt (Co) 103.6 ppb (normal range 0–0.4 ppb). Due to clinical suspicion of a pseudotumour the team requested a MARS MRI which revealed a large, well defined lobular cystic mass in the recto-uterine pouch within the pelvis measuring 10 cm × 8.5 cm × 6.8 cm (Fig. 7). The cystic nature of the lesion combined with calcification present in the inferior wall was consistent with a diagnosis of an ovarian cyst. The imaging also demonstrated evidence of a small fluid collection at the medial and superior aspect of the acetabular component measuring 3.7 cm by 2.8 cm. These findings were consistent with development of a pseudotumour.

In light of these results the patient was referred to her local gynaecology service who confirmed the diagnosis of ovarian cyst and removed it along with both ovaries and fallopian tubes

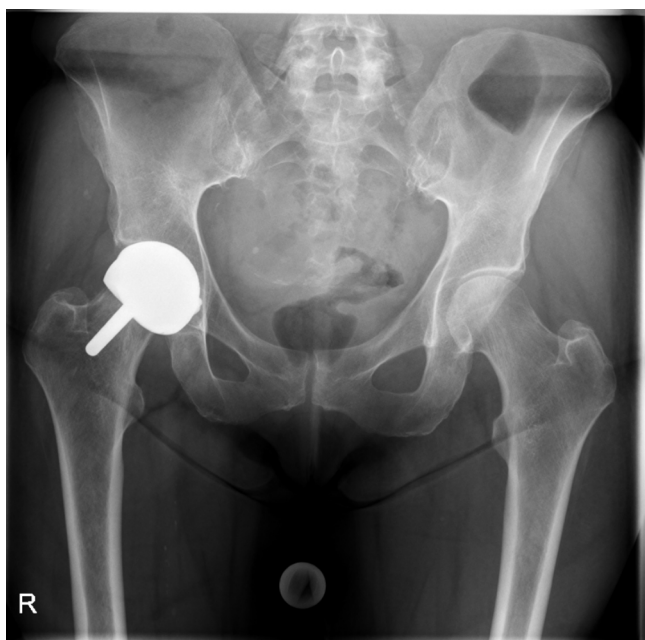

Fig. 6. AP pelvic radiograph demonstrating right-sided Birmingham resurfacing prosthesis.

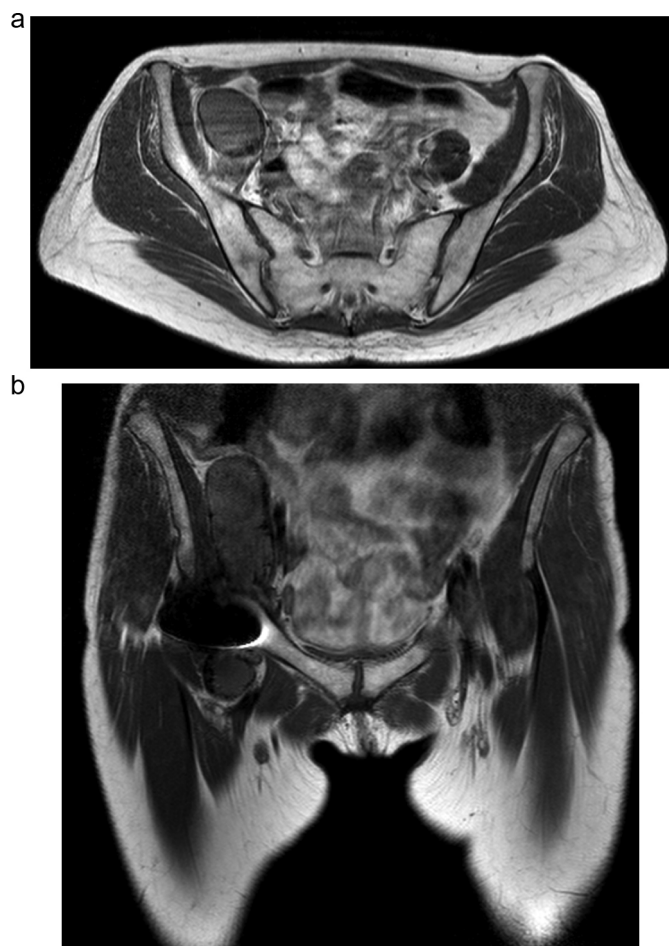


Fig. 7. T1 weighted Magnetic Resonance Image (a) axial and (b) coronal demonstrating large intra-pelvic mass.

within 6 months of initial incidental diagnosis. Frozen sections of tissue samples were taken intraoperatively. Histological analysis demonstrated a hemorrhagic endometriotic ovarian cyst with haemosiderin laden macrophages and focal calcification. No evidence of atypia or malignancy was seen.

On her next attendance to our orthopaedic outpatients department she reported a significant improvement in her symptoms following gynaecological surgery.

4. Discussion

There are a large number of differential diagnoses for a painful mass following THA. These include and abscess, haematoma, enlarged lymph node and a hip dislocation. Rarer causes have been seen in the literature such as synovial cysts, synovial sarcoma, osteosarcoma and malignant fibrous histiocytoma.^{10–12}

The increased use of MoM hip bearings became popular due to the advantage of reduced wear compared to metal on polyethylene (MoP) bearings.¹³ However MoM bearings can generate up to 500 times more nano-meter sized particles compared to MoP bearings. There are various adverse tissue reactions to metal wear debris which include lymphocytosis, vasculitis, and necrosis and pseudotumour formation.^{14,15} Pseudotumours are sterile inflammatory masses found in the soft tissues surrounding MoM implants. They are often associated with elevated chromium and cobalt levels.¹⁶ Bosker et al. performed a prospective cohort study evaluating pseudotumour formation following MoM THA¹⁷ and patients with a serum cobalt level $> 5 \mu\text{g/l}$ had a four fold increased risk of developing a pseudotumour.

In the UK, the Medicines and Healthcare Regulatory Agency (MHRA) has suggested all patients with MoM hip arthroplasty should have cross sectional imaging such as MARS MRI to detect pseudotumours,⁵ which can be described radiologically as solid, cystic or a combination of both. MRI studies of pseudotumours demonstrate a 'characteristic' signal intensity when the solid component of the mass or thickened cystic wall returns a low signal on fluid-sensitive sequences relative to muscle. This is thought to be due to the metallic content of the lesions.¹⁸

MRI is helpful in determining the nature of soft tissue masses around MoM bearings however the diagnosis of a pseudotumour can only be made on a histological examination. Willert et al. examined pseudotumour histology following failed MoM hip articulations²⁰ and found diffuse perivascular infiltrates of T-/B-lymphocytes, plasma cells with high endothelial venules, massive fibrin exudation and accumulations of macrophages/eosinophils. Lipomas typically show well-differentiated adipocytes with an absence of inflammatory cells.²¹ Histological analysis of the hip capsule revealed pigmented macrophages suggestive of metallosis. However the large mass had no features suggestive of a pseudotumour. The finding of well differentiated adipocytes confirmed the diagnosis of a very large lipoma.

To our knowledge, the finding of a very large peri-prosthetic lipoma in a patient with MoM THA has never been reported. Marghertini et al. have reported an intra-articular lipoma of the hip. They suggested that the occurrence was secondary to a subsynovial layer of supporting tissue consisting of fibroareolar tissue.²² Wettstein et al. reported on a painful total hip replacement due to sciatic nerve entrapment in scar tissue and lipoma.²³ The prosthesis that was revised did not have a MoM articulation and the size of the lipoma was considerably smaller (maximum diameter 4 cm).

The presence of a soft tissue mass near a MoM THA with elevated metal ion levels usually suggests a peri-prosthetic pseudotumour. A failing MoM THA generates metal debris however little is known about the risk of developing cancer. Omega et al. performed a meta-analysis comparing the incidence of 28 cancers between those

receiving hip or knee arthroplasties and found an increased incidence in prostate cancer and malignant melanoma.²⁴ A recent review of data from the National Joint Registry of England and Wales did not find a link between MoM THA and an increased incidence of cancer diagnoses.⁹ Nevertheless, imaging characteristics of benign and malignant soft tissue masses can overlap.¹⁹ Hence, identification and excision of a peri-prosthetic mass following MoM bearings is important for diagnosis and specifically exclusion of infection or malignancy. We therefore recommend that these cases are promptly managed at tertiary referral centres with appropriate expertise and possibly the availability of tumour surgeons.

This case demonstrates the importance of considering the large number of differential diagnoses when assessing a patient with a painful groin mass following a MoM resurfacing. Imaging these lesions early and reviewing the cases in a specialist multidisciplinary team meeting is essential so that an appropriate management can be undertaken.

Conflict of interest

None declared.

Funding

None declared.

Ethical approval

We had obtained written and signed consent to publish the case report from the patient.

Authors' contribution

Harry Krishnan conceptualized the study and wrote the manuscript. Alex Magnussen also was involved in the writing of the manuscript. Data collection was done by Alex Magnussen, Nirav Patel and Aadhar Sharma. John Skinner is a senior author and he supervised the study.

References

- Schmalzried TP, Shephard EF, Dorey FJ, Jackson WO, de la Rosa M, Fa'vae F, McKellop HA, McClung CD, Martell J, Moreland JR, Amstutz HC. The John Charnley Award. Wear is a function of use, not time. *Clin Orthop Relat Res* 2000;**381**:36–46.
- Fabi D, Levine B, Papprosky W, Della Valle C, Sporer S, Klein G, Levine H, Hartzband M. Metal-on-metal total hip arthroplasty: causes and high incidence of early failure. *Orthopedics* 2012;**35**(July (7)):e1009–16, <http://dx.doi.org/10.3928/01477447-20120621-12>.
- Hart AJ, Matthies A, Henckel J, Ilo K, Skinner J, Noble PC. Understanding why metal-on-metal hip arthroplasties fail: a comparison between patients with well-functioning and revised Birmingham hip resurfacing arthroplasties. AAOS exhibit selection. *J Bone Joint Surg Am* 2012;**94**(February (4)):e22.
- Matthies AK, Henckel J, Skinner JA, Hart AJ. A retrieval analysis of explanted Durum metal-on-metal hip arthroplasties. *Hip Int* 2011;**21**(November–December (6)):724–31, <http://dx.doi.org/10.5301/HIP.2011.8885>.
- MHRA. *Medical Device Alert Ref: MDA/2012/036*; 2012. <http://www.mhra.gov.uk/> (accessed 25.07.12).
- Natu S, Sidaginamale RP, Gandhi J, Langton DJ, Nargol AV. Adverse reactions to metal debris: histopathological features of periprosthetic soft tissue reactions seen in association with failed metal on metal hip arthroplasties. *J Clin Pathol* 2012;**65**(May (5)):409–18.
- Campbell P, Ebraamzadeh E, Nelson S, Takamura K, De Smet K, Amstutz HC. Histological features of pseudotumour-like tissues from metal-on-metal hips. *Clin Orthop Relat Res* 2010;**468**:2321–7.
- Matthies AK, Skinner JA, Osmani H, Henckel J, Hart AJ. Pseudotumors are common in well-positioned low-wearing metal-on-metal hips. *Clin Orthop Relat Res* 2012;**470**:1895–906.
- Smith AJ, Dieppe P, Porter M, Blom AW. Risk of cancer in first seven years after metal-on-metal hip replacement compared with other bearings and general population: linkage study between the National Joint Registry of England and Wales and hospital episode statistics. *Br Med J* 2012;**344**.
- Tan EJ, Thualet S, Caja L, Carletti T, Heldin CH, Moustakas A. Regulation of transcription factor Twist expression by the DNA architectural protein high mobility group A2 during epithelial-to-mesenchymal transition. *J Biol Chem* 2012;**287**(March (10)):7134–45.
- Martin A, Bauer TW, Manley MT, Marks KE. Osteosarcoma at the site of total hip replacement. A case report. *J Bone Joint Surg Am* 1988;**70**(December (10)):1561–7.
- Troop JK, Mallory TH, Fisher DA, Vaughn BK. Malignant fibrous histiocytoma after total hip arthroplasty. A case report. *Clin Orthop Relat Res* 1990;**253**:297–300.
- Sieber HP, Rieker CB, Köttig P. Analysis of 118 second-generation metal-on-metal retrieved hip implants. *J Bone Joint Surg Br* 1999;**81**(January (1)):46–50.
- Davies AP, Willert HG, Campbell PA, Learmonth ID, Case CP. An unusual lymphocytic perivascular infiltration in tissues around contemporary metal-on-metal joint replacements. *J Bone Joint Surg Am* 2005;**87**(January (1)):18–27.
- Toms AP, Marshall TJ, Cahir J, Darrah C, Nolan J, Donnell ST, Barker T, Tucker JK. MRI of early symptomatic metal-on-metal total hip arthroplasty: a retrospective review of radiological findings in 20 hips. *Clin Radiol* 2008;**63**(January (1)):49–58.
- Pandit H, Glyn-Jones S, McLardy-Smith P, Gundle R, Whitwell D, Gibbons CL, Ostlere S, Athanasou N, Gill HS, Murray DW. Pseudotumours associated with metal-on-metal hip resurfacings. *J Bone Joint Surg Br* 2008;**90**(July (7)):847–51.
- Bosker BH, Ettema HB, Boomsma MF, Kollen BJ, Maas M, Verheyen CC. High incidence of pseudotumour formation after large-diameter metal-on-metal total hip replacement: a prospective cohort study. *J Bone Joint Surg Br* 2012;**94**(June (6)):755–61.
- Hauptfleisch J, Pandit H, Grammatopoulos G, Gill HS, Murray DW, Ostlere S. A MRI classification of periprosthetic soft tissue masses (pseudotumours) associated with metal-on-metal resurfacing hip arthroplasty. *Skelet Radiol* 2012;**41**(February (2)):149–55.
- Galant J, Marti-Bonmati L, Saez F, Soler R, Alcalá-Santaella R, Navarro M. The value of fat-suppressed T2 or STIR sequences in distinguishing lipoma from well-differentiated liposarcoma. *Eur Radiol* 2003;**13**:337–43.
- Willert HG, Buchhorn GH, Fayyazi A, Flury R, Windler M, Köster G, Lohmann CH. Metal-on-metal bearings and hypersensitivity in patients with artificial hip joints. A clinical and histomorphological study. *J Bone Joint Surg Am* 2005;**87**(January (1)):28–36.
- Weiss SW, Goldblum JR, Enzinger FM. *Enzinger and Weiss's soft tissue tumors*. Fourth ed. St. Louis: Mosby; 2001.
- Margheritini F, Villar RN, Rees D. Intra-articular lipoma of the hip. A case report. *Int Orthop* 1998;**22**(5):328–9.
- Wettstein M, Garofalo R, Mouhsine E. Painful total hip replacement due to sciatic nerve entrapment in scar tissue and lipoma. *Musculoskelet Surg* 2010;**94**(November (2)):77–80.
- Onega T, Baron J, MacKenzie T. Cancer after total joint arthroplasty: a meta-analysis. *Cancer Epidemiol Biomark Prev* 2006;**15**(August (8)):1532–7.

Open Access

This article is published Open Access at sciendo.com. It is distributed under the [IJSCR Supplemental terms and conditions](#), which permits unrestricted non commercial use, distribution, and reproduction in any medium, provided the original authors and source are credited.