

## Synthesis of evidence for the treatment of intersection syndrome

Konstantine Balakatounis, Antonios G Angoules, Nikolaos A Angoules, Kalomoira Panagiotopoulou

Konstantine Balakatounis, Neurology Institute of Athens, 10676 Athens, Greece

Antonios G Angoules, Department of Medical Laboratories, Technological Educational Institute of Athens, 12243 Athens, Greece

Nikolaos A Angoules, School of Physiotherapy, AMC Metropolitan College, 15125 Athens, Greece

Kalomoira Panagiotopoulou, School of Medicine, University of Ioannina, 45110 Ioannina, Greece

**Author contributions:** All authors equally contributed to this paper with conception and design of the study; Balakatounis K wrote the draft; Balakatounis K, Angoules AG, Angoules NA and Panagiotopoulou K contributed to the literature review and analysis; Angoules AG provided expert review; all authors approved the final version of the article.

**Conflict-of-interest statement:** The authors of this manuscript declare that they have no conflict of interests.

**Open-Access:** This article is an open-access article which was selected by an in-house editor and fully peer-reviewed by external reviewers. It is distributed in accordance with the Creative Commons Attribution Non Commercial (CC BY-NC 4.0) license, which permits others to distribute, remix, adapt, build upon this work non-commercially, and license their derivative works on different terms, provided the original work is properly cited and the use is non-commercial. See: <http://creativecommons.org/licenses/by-nc/4.0/>

**Manuscript source:** Invited manuscript

**Correspondence to:** Antonios G Angoules, MD, PhD, Department of Medical Laboratories, Technological Educational Institute of Athens, 28 Agiou Spiridonos St, 12243 Athens, Greece. [angoules@teiath.gr](mailto:angoules@teiath.gr)  
Telephone: +30-6-977011617

Received: March 20, 2017

Peer-review started: March 23, 2017

First decision: June 12, 2017

Revised: July 17, 2017

Accepted: July 21, 2017

Article in press: July 22, 2017

Published online: August 18, 2017

### Abstract

Intersection syndrome is a rare sports overuse injury occurring through friction at the intersection of the first and second compartment of the forearm. Differential diagnosis must be carefully made, especially from De Quervain tendonsynovitis. Clinical examination provides with the necessary information for diagnosis, still magnetic resonance imaging scans and ultrasonography may assist in diagnosis. Treatment consists mainly of rest, use of a thumb spica splint, analgetic and oral nonsteroidal anti-inflammatory drugs and after 2-3 wk progressive stretching and muscle strengthening. Should symptoms persist beyond this time, corticosteroid injections adjacent to the site of injury may be useful. In refractory cases, surgical intervention is warranted.

**Key words:** Intersection syndrome; Overuse injury; Wrist pain; Differential diagnosis; Treatment

© The Author(s) 2017. Published by Baishideng Publishing Group Inc. All rights reserved.

**Core tip:** In this review, current aspects of clinical and imaging diagnosis, as well as therapeutic approach of intersection syndrome, are outlined. This overuse syndrome which may provokes significant wrist pain and disability, is associated with repetitive wrist flexion and extension and compressive forces applied to the wrist and is common in sports such as rowing, canoeing, skiing, weight lifting and racket sports. Conservative treatment is generally an efficient therapeutic approach and includes means such as rest, cryotherapy, immobilization through splinting, medication with non-steroid anti-inflammatory and corticoid drugs as well as individualized rehabilitation program incorporating progressive stretching and muscle

strengthening exercises. Future research is proposed to select larger samples if possible and utilize the frank value of imaging studies such as magnetic resonance imaging scans or ultrasonography as well as optimal therapeutic strategies for every individual suffering from this syndrome.

Balakatounis K, Angoules AG, Angoules NA, Panagiotopoulou K. Synthesis of evidence for the treatment of intersection syndrome. *World J Orthop* 2017; 8(8): 619-623 Available from: URL: <http://www.wjgnet.com/2218-5836/full/v8/i8/619.htm> DOI: <http://dx.doi.org/10.5312/wjo.v8.i8.619>

## INTRODUCTION

Although the first report of the IS took place by Velpeau in 1841, Dobyns in 1978 was the first who introduced this term<sup>[1,2]</sup>. Intersection syndrome (IS) which has been alternatively named peritendinitis crepitans, crossover syndrome, adventitial bursitis, subcutaneous perimyositis with abductor pollicis longus syndrome and bugaboo forearm<sup>[3-5]</sup> is a rare inflammatory condition, usually reported as an overuse injury resulting from friction between two compartments each wrapped in its own sheath. The dorsal or first musculotendinous unit/compartment contains the abductor pollicis longus and the extensor pollicis brevis while the second compartment includes the extensor carpi radialis longus and extensor carpi radialis brevis<sup>[6]</sup>. These two compartments intercept at an angle of 60 degrees<sup>[7]</sup>. Montechiarello *et al*<sup>[1]</sup>, specifically report that friction occurs between the muscle bellies of the first compartment and the tendon sheaths of the second compartment. Intersection syndrome has been also reported to result from stenosis and entrapment of the second compartment, although it has been supported that it is not clear which is the etiology of this pathology<sup>[5]</sup>.

Draghi and Bortolotto<sup>[8]</sup> report that there is also an intersection more distally where the extensor pollicis longus intersects with the second compartment. Friction may occur at that site as well, resulting in intersection syndrome<sup>[9-11]</sup>. Furthermore, the second compartment may also be not in a single sheath but each tendon may be in its own sheath<sup>[4,12]</sup>. The flexor retinaculum has also been attributed a possibly important role in the pathogenesis of IS<sup>[13]</sup>.

Overall incidence ranges from 0.2% to 0.37% in various studies<sup>[14]</sup>. IS occurs through repetitive wrist flexion and extension and compressive forces applied to the wrist<sup>[15]</sup>, affects mainly the dominant hand, and onset has been pinpointed specifically when beginning a new sport<sup>[15]</sup>. This nosologic entity is reported in sports such as rowing, canoeing, horseback riding, skiing, weight training or racket sports, activities associated with repetitive wrist extension<sup>[16,17]</sup>. In a study including 42 skiers, prevalence was estimated as high as 11.9%

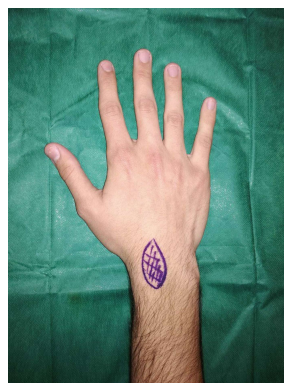


Figure 1 Area of pain and tenderness to palpation in intersection syndrome.

in the first two days<sup>[18]</sup>. In another study, incidence reached 2% in tennis players<sup>[11]</sup> whilst in a study of 8000 patients with arm or hand pain, occurrence was found to reach only 0.37%<sup>[19]</sup>.

In this review current aspects of clinical and imaging diagnosis as well as the therapeutic approach of IS are outlined.

## CLINICAL EXAMINATION

Clinical examination reveals usually pain 4-8 cm proximally to radial styloid and swelling in the radial aspect of the wrist and forearm<sup>[20]</sup> (Figure 1). Localized redness and tenderness to palpation over the site of swelling are two other typical clinical signs<sup>[20]</sup>. Pain in movement is observed specifically in ulnar deviation and wrist extension. Crepitus in palpation during flexion and extension of the wrist may also be present<sup>[1,17]</sup>.

## DIFFERENTIAL DIAGNOSIS

Differential diagnosis from similar pathologies is of paramount importance, due to its different strategy in treatment (Table 1). Differential diagnosis should mainly be made from De Quervain Syndrome (DQS)<sup>[3]</sup>. Other pathologies such as scaphoid fractures, osteoarthritis of the first metacarpal joint, ganglion cysts, Wartenderg syndrome wrist ligament sprains, and muscle strains maybe also confused with IS and should be early diagnosed and properly treated<sup>[1,6]</sup>. In DQS pain is localized distally to the dorsal interphalangeal joint of the thumb, in the first dorsal compartment that consists of the abductor pollicis longus and the extensor pollicis brevis. Finkelstein test in this case is considered pathognomonic<sup>[21]</sup>. In IS, on the contrary, pain is identified 4-8 cm proximally to the radial styloid. The method of application of the test is important since it is a pathognomonic test guiding diagnosis. It is described as grasping the thumb within the fingers forming a fist and deviating the wrist in an ulnar direction. Still, the original description by Finkelstein reports that the patient's thumb is grasped with abduction of the wrist taking place in an ulnar direction, resulting in

**Table 1** Differential diagnosis of radial wrist pain<sup>[1,3,6]</sup>

Intersection syndrome
Tendonitis De Quervain
Scaphoid fractures
Osteoarthritis of the first metacarpal joint
Ganglion cysts
Wartenberg syndrome
Wrist ligament sprains
Muscle strains
Soft tissue neoplasms

intense pain over the styloid<sup>[21]</sup>. Differentiating DQS from intersection syndrome is significant since in DQS earlier surgical intervention is recommended by some experts<sup>[22]</sup>.

## IMAGING STUDIES

Although clinical diagnosis is usually sufficient, imaging studies offer a more certain diagnosis and clarify complicated injuries<sup>[11]</sup>.

Ultrasound imaging provides reliable and “first-line” diagnosis in the study of IS, while magnetic resonance imaging (MRI) studies are retrospective studies<sup>[1]</sup>. It is important to note that the utility of the ultrasound in diagnosing IS is of value and even more important in research studies. Through ultrasound imaging, details in the anatomy of the region may be observed, that may explain symptoms or guide treatment. In the study by Draghi and Bortolotto<sup>[8]</sup>, valuable information was derived. The study can be considered of significant value since it took place over 5 years and included 1131 patients with hand and wrist pathology. It was reported that tendons may be coated in one sheath or individual sheaths and a second location of an intersection was underlined. This information may be beneficial in both research and clinical level. For instance, a more detailed anatomy or pathologic anatomy may elucidate the mechanics of injury and healing. It may also result in improved effectiveness in injection therapy, by targeting the intended site.

Clinical examination may be accompanied by axial MRI<sup>[3]</sup>. de Lima *et al.*<sup>[4]</sup>, studied through MRI scans the anatomy of the forearm around the intersection area, before and after tenography. The authors of this study concluded that MRI may be a useful noninvasive method for the evaluation of wrist pain. In T2 weighted fat suppressed fast spin echo axial MRI, peritendinous and subcutaneous edema concentrically both proximally and distally of the intersection site) or even synovial effusion are depicted in the presence of intersection syndrome pathology<sup>[6,7]</sup> Lee *et al.*<sup>[9]</sup>, in a review of intersection injury studied through MRI, identified also tendinosis and subcutaneous and muscle edema as abnormalities related to this overuse syndrome.

Of note, although imaging studies may be useful in identifying and confirming IS, is reported that 70% of cases can be found through appropriate history

taking<sup>[23]</sup>.

## TREATMENT

It is common ground that the fundamental element for the recuperation of an overuse injury is informing the patient of the steps he or she may follow to assist in healing. Patient education thus is important in IS and understanding of the mechanism of injury will aid in conceiving how to protect and progressively rehabilitate the wrist back to its normal daily activities<sup>[24]</sup>.

In the first phase, the proposed main line of action consists of rest, use of oral nonsteroidal anti-inflammatory medication, cryotherapy, elevation, and compression. Although inflammation is necessary for the proper cascade of healing of the site of injury, reduction to some extent of inflammation to result in the reduction of pain is necessary in order to eliminate disabling symptoms as soon as possible<sup>[3]</sup>. The second phase of rehabilitation consists of the gradual restoration of function of the upper extremity to former daily activities. This phase lasts 4-6 wk and consists of progressive stretching and mobilization of relevant joints that is the wrist, elbow joint, metacarpophalangeal and phalangophalangeal joints and other structures such as musculature, tendons, and fascia. Strength training should be initiated carefully to avoid relapse of symptoms. The performance of daily life activities is a part of training, in order to reach full functional rehabilitation. The general rule of increasing parameters such as intensity, repetition, or distance per week, has been shown to be a beneficial rule of thumb for runners<sup>[20]</sup>.

Immobilization through splinting is proposed in the literature<sup>[20]</sup>. Immobilization of the wrist as well as the thumb has been proposed, with a thumb spica splint, strapping or use of a cock up wire-splint<sup>[3]</sup>. The anatomical position of immobilization is 20 degrees of extension of the wrist. The duration of immobilization in research studies extends from 2-3 wk<sup>[20,23]</sup>.

Persistence of symptoms after 2-3 wk, leads to the consideration of a second line of available treatment procedures available<sup>[21]</sup>. A percentage of 60% has been reported to heal solely through conservative management<sup>[18]</sup>. Corticosteroid injections may alleviate pain and reduce inflammation<sup>[25]</sup>. Injections may be administered adjacent to the maximally tender areas solely, providing relief after 10 d<sup>[3]</sup>.

Resolving to surgical intervention is very effective but is offered only to patients not responding to conservative treatment. Operative management consists of Abductor Pollicis Longus (APL) and Extensor Pollicis Brevis (EPB) tenosynovectomy and fasciotomy, and debridement of the bursa so as to result in release compression at the crossover site<sup>[17,18]</sup> while post-operatively immobility using plaster forearm splint is recommended for ten days. Return to full activity is permitted from at least 12 wk<sup>[26]</sup>.

Williams *et al.*<sup>[27]</sup>, described the decompression of the

muscle belly of the swollen by overuse muscles. They performed an incision at the site of maximum swelling, aiming at decompression of the extensors beneath. This incision is performed 3-4 cm proximal to the incision for De Quervain tenosynovitis. It may take place by local anesthesia, by bypassing superficial layers to reach the tendon and fascia of the APL and EPB. In 11 patients, mostly rowing athletes presenting with overuse syndrome of the extensors of the wrist, this technique was performed. Return to light training was achieved from the first day post-surgery and return to training 10 d later. No return of symptoms was reported even 4 mo following operation<sup>[27]</sup>.

Another therapeutic approach was proposed by Grundberg and Reagan<sup>[5]</sup>. According to the authors pathology relates mainly to Extensor Carpi Radialis Brevis (ECRB) and Extensor Carpi Radialis Longus (ECRL) who are responsible for the more proximal than the De Quervain localization of pain. This decompression of the second extensor compartment is thought to resolve symptoms of the syndrome. This technique was performed to 13 patients with IS of a duration from 4 mo to 5 years, where conservative treatment had failed. In two patients a surgical approach was implemented more proximally to the tendon of the carpal extensors which rendered unsatisfactory results. In line incision of the carpal extensors was performed with a direction centrally towards the area of the marked edema. Release of ECRL and ECRB within the second dorsal compartment after dissecting the deep fascia achieved reduction of symptoms in all patients ten months on average, postoperatively. All patients returned to their former employment<sup>[5]</sup>.

## DISCUSSION

Up to this day, there is a debate whether IS is a tendinosis, thus a chronic tendon degeneration with the absence of inflammation or a peritenosynovitis, involving an inflammatory process across the tendon sheaths<sup>[28,29]</sup>. Furthermore, as reported above the site of injury in IS is also debatable, since it may occur at two different intersections of the second compartment with the abductor extensor longus and extensor pollicis brevis or more distally with the extensor pollicis longus alone.

The establishment of diagnosis of this pathology is based mainly on thorough clinical examination and should be achieved early in order to avoid functional impairment of the affected hand and devastating consequences for patients and especially these interfering with athletic activity. Differential diagnosis includes several nosologic entities which provoke wrist pain and mainly De Quervain Syndrome<sup>[1,3,26]</sup>.

Treatment includes mainly conservative therapeutic strategies such as rest, immobilization with a thumb spica splint, analgetic and non-steroid anti-inflammatory drugs (NSAIDS) and after 2-3 wk progressive stretching and muscle strengthening. Injection therapy using

drugs such as using 2 mL of 1% of lidocaine with betamethasone, is another conservative therapeutic option which is proposed when symptoms persist more than few weeks of immobilization<sup>[25]</sup>. Still, major adverse events that may take place and represent a percentage of 5,8%, have to be discussed with the patient. These range from a simple ecchymosis which may occur to as much as a devastating tendon rupture<sup>[25]</sup>.

As conservative treatment is generally an efficient therapeutic approach for IS, surgical management is warranted only for refractory cases and is followed with good results<sup>[5,17,18,27]</sup>.

## CONCLUSION

Intersection syndrome is not a clearly understudied syndrome. The etiology, site of injury, histologic underlying changes are still debatable. Moreover, the extent of the utility of imaging studies in diagnosis is still not entirely clear. Adding to the necessity of further elucidating all aspects of the syndrome, every possible way of studying the syndrome is proposed. The utility of imaging in research as a means of studying histology and anatomy is supported as well as the need to conduct studies with larger samples in order to study the injury in depth.

## REFERENCES

- 1 **Montechiarello S**, Miozzi F, D'Ambrosio I, Giovagnorio F. The intersection syndrome: Ultrasound findings and their diagnostic value. *J Ultrasound* 2010; **13**: 70-73 [PMID: 23396515 DOI: 10.1016/j.jus.2010.07.009]
- 2 **Dobyns JH**, Sim FH, Linscheid RL. Sports stress syndromes of the hand and wrist. *Am J Sports Med* 1978; **6**: 236-254 [PMID: 707683 DOI: 10.1177/036354657800600505]
- 3 **Hanlon DP**, Luellen JR. Intersection syndrome: a case report and review of the literature. *J Emerg Med* 1999; **17**: 969-971 [PMID: 10595881]
- 4 **de Lima JE**, Kim HJ, Albertotti F, Resnick D. Intersection syndrome: MR imaging with anatomic comparison of the distal forearm. *Skeletal Radiol* 2004; **33**: 627-631 [PMID: 15365785 DOI: 10.1007/s00256-004-0832-4]
- 5 **Grundberg AB**, Reagan DS. Pathologic anatomy of the forearm: intersection syndrome. *J Hand Surg Am* 1985; **10**: 299-302 [PMID: 3980951 DOI: 10.1016/S0363-5023(85)80129-5]
- 6 **Browne J**, Helms CA. Intersection syndrome of the forearm. *Arthritis Rheum* 2006; **54**: 2038 [PMID: 16736508 DOI: 10.1002/art.21825]
- 7 **Costa CR**, Morrison WB, Carrino JA. MRI features of intersection syndrome of the forearm. *AJR Am J Roentgenol* 2003; **181**: 1245-1249 [PMID: 14573413 DOI: 10.2214/ajr.181.5.1811245]
- 8 **Draghi F**, Bortolotto C. Intersection syndrome: ultrasound imaging. *Skeletal Radiol* 2014; **43**: 283-287 [PMID: 24337446 DOI: 10.1007/s00256-013-1786-1]
- 9 **Lee RP**, Hatem SF, Recht MP. Extended MRI findings of intersection syndrome. *Skeletal Radiol* 2009; **38**: 157-163 [PMID: 18810435 DOI: 10.1007/s00256-008-0587-4]
- 10 **De Maeseneer M**, Marcelis S, Jager T, Girard C, Gest T, Jamadar D. Spectrum of normal and pathologic findings in the region of the first extensor compartment of the wrist: sonographic findings and correlations with dissections. *J Ultrasound Med* 2009; **28**: 779-786 [PMID: 19470818 DOI: 10.7863/jum.2009.28.6.779]
- 11 **Tagliafico AS**, Ameri P, Michaud J, Derchi LE, Sormani MP, Martinoli C. Wrist injuries in nonprofessional tennis players: relationships with different grips. *Am J Sports Med* 2009; **37**: 760-767 [PMID: 19270188]



- DOI: 10.1177/0363546508328112]
- 12 **Cvitanic OA**, Henzie GM, Adham M. Communicating foramen between the tendon sheaths of the extensor carpi radialis brevis and extensor pollicis longus muscles: imaging of cadavers and patients. *AJR Am J Roentgenol* 2007; **189**: 1190-1197 [PMID: 17954660 DOI: 10.2214/AJR.07.2281]
  - 13 **Draghi F**. Ultrasonography of the upper extremity: hand and wrist. Berlin: Thieme & Froberg, 2013: 47-52
  - 14 **Descatha A**, Leproust H, Roure P, Ronan, Colette, Roquelaure Y. Is the intersection syndrome is an occupational disease? *Joint Bone Spine* 2008; **75**: 329-331 [DOI: 10.1016/j.jbspin.2007.05.013]
  - 15 **Palmer DH**, Lane-Larsen CL. Helicopter skiing wrist injuries. A case report of "bugaboo forearm". *Am J Sports Med* 1994; **22**: 148-149 [PMID: 8129100 DOI: 10.1177/036354659402200124]
  - 16 **Servi JT**. Wrist pain from overuse: detecting and relieving intersection syndrome. *Phys Sportsmed* 1997; **25**: 41-44 [PMID: 20086879 DOI: 10.3810/psm.1997.12.1401]
  - 17 **Rettig AC**. Athletic injuries of the wrist and hand: part II: overuse injuries of the wrist and traumatic injuries to the hand. *Am J Sports Med* 2004; **32**: 262-273 [PMID: 14754754 DOI: 10.1177/0363546503261422]
  - 18 **Stern PJ**. Tendinitis, overuse syndromes, and tendon injuries. *Hand Clin* 1990; **6**: 467-476 [PMID: 2211857]
  - 19 **Pantukosit S**, Petchkrua W, Stiens SA. Intersection syndrome in Buriram Hospital: a 4-yr prospective study. *Am J Phys Med Rehabil* 2001; **80**: 656-661 [PMID: 11523968 DOI: 10.1097/00002060-200109000-00005]
  - 20 **Jean Yonnet G**. Intersection syndrome in a handcyclist: case report and literature review. *Top Spinal Cord Inj Rehabil* 2013; **19**: 236-243 [PMID: 23960708 DOI: 10.1310/sci1903-236]
  - 21 **Posner M**. Differential diagnosis of wrist pain: tendinitis, ganglia, and other syndromes. In: Peimer C, ed, *Surgery of the hand and upper extremity*. New York: McGraw-Hill, 1996: 838-841
  - 22 **Topper S**, Wood M, Cooney W. Athletic injuries of the wrist. In: Cooney W, Linschied R, Dobyns J, eds. *The wrist: diagnosis and operative treatment*. Philadelphia: Mosby, 1998: 1031-1074
  - 23 **Fulcher SM**, Kiefhaber TR, Stern PJ. Upper-extremity tendinitis and overuse syndromes in the athlete. *Clin Sports Med* 1998; **17**: 433-448 [PMID: 9700413 DOI: 10.1016/S0278-5919(05)70095-8]
  - 24 **Higgs PE**, Mackinnon SE. Repetitive motion injuries. *Annu Rev Med* 1995; **46**: 1-16 [PMID: 7598446 DOI: 10.1146/annurev.med.46.1.1]
  - 25 **Brinks A**, Koes BW, Volkers AC, Verhaar JA, Bierma-Zeinstra SM. Adverse effects of extra-articular corticosteroid injections: a systematic review. *BMC Musculoskelet Disord* 2010; **11**: 206 [PMID: 20836867 DOI: 10.1186/1471-2474-11-206]
  - 26 **Elder G**, Harvey E. Hand and Wrist Tendinopathies. In: Maffulli NRP, Wayne B, editors. *Tendon injuries: basic science and clinical medicine*. London: Springer, 2005: 137-149 [DOI: 10.1007/1-84628-050-8\_15]
  - 27 **Williams JG**. Surgical management of traumatic non-infective tenosynovitis of the wrist extensors. *J Bone Joint Surg Br* 1977; **59-B**: 408-410 [PMID: 925050]
  - 28 **Khan KM**, Cook JL, Kannus P, Maffulli N, Bonar SF. Time to abandon the "tendinitis" myth. *BMJ* 2002; **324**: 626-627 [PMID: 11895810 DOI: 10.1136/bmj.324.7338.626]
  - 29 **Maffulli N**, Khan KM, Puddu G. Overuse tendon conditions: time to change a confusing terminology. *Arthroscopy* 1998; **14**: 840-843 [PMID: 9848596 DOI: 10.1016/S0749-8063(98)70021-0]

**P- Reviewer:** Kamineni S   **S- Editor:** Kong JX   **L- Editor:** A  
**E- Editor:** Lu YJ





Published by **Baishideng Publishing Group Inc**  
7901 Stoneridge Drive, Suite 501, Pleasanton, CA 94588, USA  
Telephone: +1-925-223-8242  
Fax: +1-925-223-8243  
E-mail: [bpgoffice@wjgnet.com](mailto:bpgoffice@wjgnet.com)  
Help Desk: <http://www.f6publishing.com/helpdesk>  
<http://www.wjgnet.com>

