




# Concomitant Occurrence of the Ossified Posterior Longitudinal Ligament with a Posterior C2 Defect

Manikandan Thandapani<sup>1</sup> Sudheer Kumar Pothu<sup>1</sup>  Ramachandran Govindasamy<sup>1</sup> Satish Rudrappa<sup>1</sup>  
Balaji Vaithialingam<sup>2</sup>

<sup>1</sup>Institute of Neurosciences, Sakra World Hospital, Bengaluru, Karnataka, India

<sup>2</sup>Department of Anaesthesiology, Sakra World Hospital, Bengaluru, Karnataka, India

Address for correspondence Manikandan Thandapani, MS, FNB, Institute of Neurosciences, Sakra World Hospital, Bengaluru, Karnataka 560103, India (e-mail: drmani7@gmail.com).

Asian J Neurosurg 2023;18:688–689.

Cervical myelopathy secondary to congenital anomalies involving the posterior elements of the axis (C2) is extremely rare.<sup>1</sup> We present a case of deeply invaginated unfused C2 laminae into the spinal canal with associated ossified posterior longitudinal ligament (OPLL) at the C2-C3 level presenting with myelopathy symptoms.

A 34-year-old man presented with a 2-year history of neck pain and recent-onset radiating pain in the left upper limb associated with a tingling sensation. Trauma and other medical comorbidities were ruled out. A neurological examination revealed normal power, intact sensation, and brisk reflexes in all four extremities, with bilateral extensor plantar response. A plain radiograph revealed an abnormality in the C2 posterior elements with a normal atlantodens interval. Magnetic resonance imaging (MRI) revealed circumferential cord compression with canal stenosis caused by the disc osteophyte complex anteriorly and the ligamentum flavum posteriorly at the C2-C3 level with features of myelomalacia (► **Fig. 1A**). Dynamic MRI revealed no worsening or additional level of compression. Computed tomographic scan revealed segmental OPLL at C2-C3 (► **Fig. 1B**), which was initially thought to be a disc osteophyte complex in MRI and unfused bilaterally invaginated lamina of C2 (► **Fig. 1C**). Pseudoarthrosis of the lamina with remaining C2 posterolaterally was also observed. The C1 posterior arch and C1-C2 joint were both normal. A surgical laminectomy of C2 and C2-C3 instrumented fusion (C2-pars and C3-lateral mass) were performed. Intraoperatively, the C2 arch was underde-

veloped, with hypermobile C2 lamina. Following an uneventful course, the patient was discharged with a hard cervical orthosis for 6 weeks. At the 3-year follow-up, there was a significant improvement in clinical symptoms and adequate decompression with solid fusion was noted in the imaging.

Congenital C2 anomalies usually involve the odontoid process, such as the ossiculum terminale, os odontoideum, or dens hypoplasia. The fusion of two halves of the posterior arch is visible by 2 to 3 years of age (failure to fuse results in the bifid arch), and the fusion of the posterior neural arch to the anterior vertebral body occurs by 7 years of age (failure to fuse results in spondylolysis).<sup>2</sup> Failure of the above two embryological events results in the floating lamina. In our case, C2 was not associated with a bifid arch but was unfused posterolaterally, indicating failure of fusion of the posterior arch with the rest of the body.

Posterior element defect of C2 with myelopathy is extremely rare, with only a few cases reported in the literature. Passias et al classified congenital C2 defects into four categories: hypoplasia of the posterior arch with invagination, aplasia of the C2 lamina, and hypertrophy of the C2 arch with an associated upper cervical stenosis.<sup>3</sup> In most cases, myelopathy is caused by compression from the posterior aspect, either due to hypertrophy or invagination of the hypoplastic lamina/spinous process. Aplasia of the C2 posterior elements causes progressive instability, resulting in C2-C3 anterolisthesis and dynamic compression.<sup>4</sup> Circumferential compression was caused in our case by concomitant

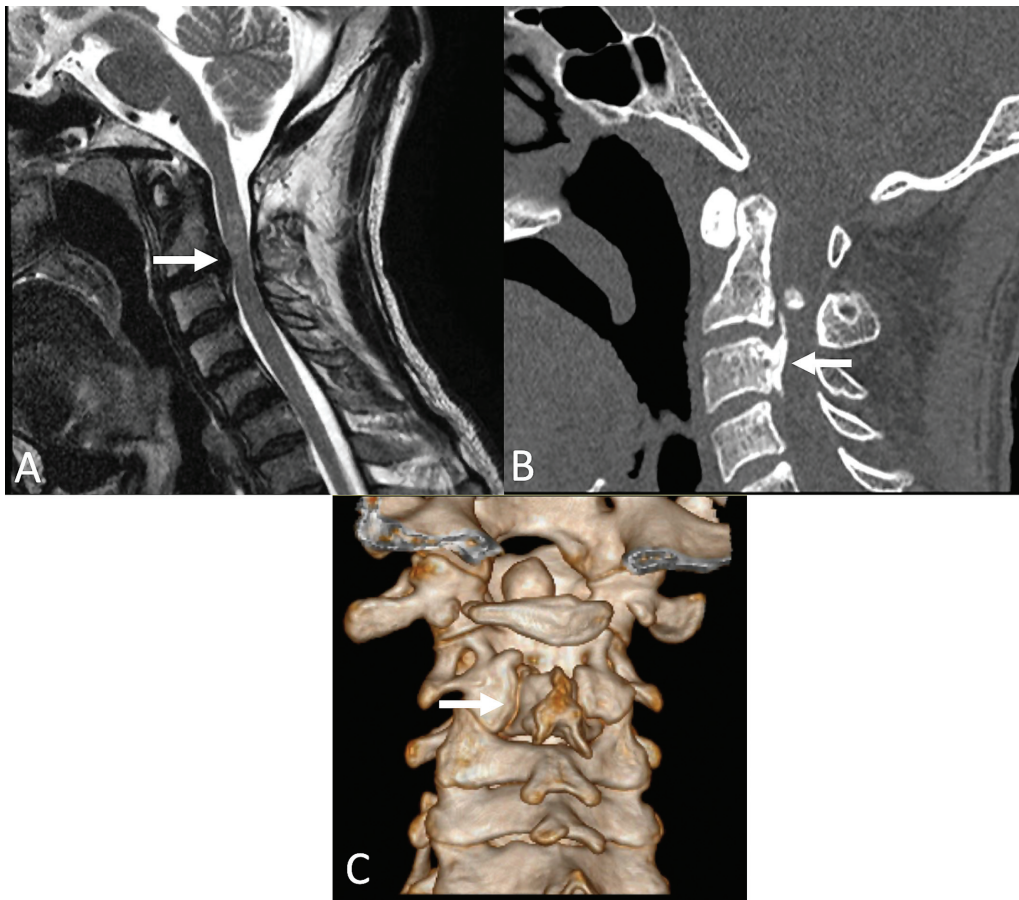
article published online  
September 22, 2023

DOI <https://doi.org/10.1055/s-0043-1771321>.  
ISSN 2248-9614.

© 2023. Asian Congress of Neurological Surgeons. All rights reserved.

This is an open access article published by Thieme under the terms of the Creative Commons Attribution-NonDerivative-NonCommercial-License, permitting copying and reproduction so long as the original work is given appropriate credit. Contents may not be used for commercial purposes, or adapted, remixed, transformed or built upon. (<https://creativecommons.org/licenses/by-nc-nd/4.0/>)

Thieme Medical and Scientific Publishers Pvt. Ltd., A-12, 2nd Floor, Sector 2, Noida-201301 UP, India



**Fig. 1** (A) Magnetic resonance imaging (MRI) revealed circumferential cord compression with canal stenosis with features of myelomalacia (arrow). (B) Computed tomography (CT) showing ossified posterior longitudinal ligament (OPLL) at the level of (arrow). (C) Three-dimensional (3D) view showing unfused C2 lamina (arrow).

OPLL and invaginated C2 lamina. The etiology of OPLL is poorly understood and spinal instability, on the other hand, may play a role in the development and progression of OPLL.<sup>5</sup> Our patient was a manual laborer who had to carry heavy weights over his head for an extended period. This could have increased the mechanical load on the most mobile anterior element (C2-C3 discs), resulting in the development of OPLL due to a preexisting deficient posterior element. Considering OPLL as a sign of segmental instability, we performed posterior decompression (C2 laminectomy) in conjunction with C2-C3 fusion.

To conclude, in the absence of instability, as in hypoplastic or hypertrophic lamina/spinous process cases, optimal posterior decompression of abnormal structure is sufficient for a favorable outcome. However, in aplastic posterior elements causing C2-C3 anterolisthesis can require anterior decompression with or without fusion, followed by posterior fusion.

#### Informed Consent

The authors certify that they have obtained all appropriate patient consent forms. In the form, the patient(s) has/have given his/her/their consent for his/her/their images and other clinical information to be reported in the journal. The

patients understand that their names and initials will not be published, and due efforts will be made to conceal their identity, but anonymity cannot be guaranteed. The authors declare that written and informed consents have been taken from the patient/ guardian for publication.

#### Conflict of Interest

None declared.

#### References

- Morizono Y, Sakou T, Maehara T. Congenital defect of posterior elements of the axis. *Clin Orthop Relat Res* 1987;(216):120-123
- Vangilder JC, Menezes AH. Craniovertebral junction abnormalities. *Clin Neurosurg* 1983;30:514-530
- Passias PG, Wang S, Wang S. Combined ossification of the posterior longitudinal ligament at C2-3 and invagination of the posterior axis resulting in myelopathy. *Eur Spine J* 2013;22(Suppl 3): S478-S486
- Muzumdar DP, Goel A. C2 over C3 spondyloptosis in a case with absent posterior elements. Report of an unusual case and analysis of treatment options. *J Clin Neurosci* 2004;11(06): 675-677
- Goel A. Ossification of the posterior longitudinal ligament: analysis of the role of craniovertebral and spinal instability. *Acta Neurochir Suppl (Wien)* 2019;125:63-70