



Comparison of the Effectiveness of Different Techniques for Supportive Removal of Root Canal Filling Material

 Taha ÖZYÜREK,  Ebru ÖZSEZER DEMİRYÜREK

ABSTRACT

Objective: To compare the cleanliness of oval cross-sectioned root canals after using different supportive techniques for removal of root canal filling material as part of retreatment process.

Methods: One hundred mandibular canine teeth with flat oval cross-sectioned canals were instrumented up to #40.06 and obturated using the warm vertical compaction technique. Removal of the gutta-percha and sealer was performed using the D-RaCe nickel-titanium retreatment instruments. The roots were randomly divided into four groups of 25 teeth, and the activation processes were applied: XP-endo Finisher (XP), EndoActivator (EA) and IrriSafe (IS). Conventional needle irrigation (CI) was used as the control group. The teeth were sectioned, and digital images were captured. The photographs were analysed using AutoCAD software regarding the area of residual root filling. Kruskal–Wallis and post hoc Dunn’s tests were performed for statistical analysis.

Results: There was significantly less gutta-percha and sealer remnant in the XP group than in the other groups ($P<0.05$). The CI group contained significantly more gutta-percha and sealer remnant than the other groups ($P<0.05$). The apical third of the CI group had significantly more residual gutta-percha and sealer when compared to that of the other groups ($P<0.05$).

Conclusion: Within the limitations of this study, the amount of gutta-percha and sealer in the XP group was lower than that in the EA, IS, and CI groups.

Keywords: EndoActivator, endodontics, IrriSafe, oval canals, XP-endo finisher

INTRODUCTION

During nonsurgical retreatment, all existing root canal filling materials should be removed because they might contain microorganisms that can interfere with the effective distribution of irrigants and prevent adaptation of new root canal filling materials. Nickel-titanium (NiTi) rotary instruments have been shown to be more resistant to fracture for the removal of root canal filling materials (1, 2) and faster than using hand instruments (3). NiTi rotary instruments also reduce operator-related complications (4).

There are several NiTi retreatment rotary systems available in the market. One of these systems is the D-RaCe retreatment system (FKG Dentaire, La-Chaux-de Fonds, Switzerland), which consists of two NiTi instruments. The DR1 instrument, which has a file size of 30.10 has an active tip to penetrate the gutta-percha mass and is used for removing the gutta-percha from the coronal part of the root canal. The DR2 instrument, which is size 25.04, is used for removing the gutta-percha and sealer from the middle and apical parts of the root canal (5).

Before the retreatment, the root canal anatomy should be carefully evaluated. Previous studies reported that retreatment procedure affected by cross-sectional root canal shape (6, 7). Removal of root canal filling materials from a round cross-section canal might be easy using NiTi rotary instruments Page: 1 (7), but an oval cross-section canal may require additional removal procedures (6, 7). It is well established that the latter could only be cleaned with mechanical instrumentation during the retreatment process (8, 9). In such cases, additional enlargement of the apical diameter could be done to decrease the amount of residual gutta-percha and sealer, but this might lead to perforation or canal transportation (10). Other methods, for example, sonics, ultrasonics and laser devices, have been reported to develop the removal of residual root canal filling materials (11, 12).

Recently, a novel NiTi rotary system has been launched called XP-endo Finisher (FKG Dentaire). According to the manufacturer, it is made of a proprietary MaxWire alloy, which gives the instru-

Please cite this article as: Özyürek T, Özsezer Demiryürek E. Comparison of the Effectiveness of Different Techniques for Supportive Removal of Root Canal Filling Material. Eur Endod J (2016) 1:6.

From the Department of Endodontics (T.Ö. ✉ tahaozyurek@hotmail.com, E.Ö.D.) Ondokuz Mayıs University, Faculty of Dentistry, Samsun, Turkey.

Received 24 May 2016, revision requested 12 July 2016, last revision received 11 October 2016, accepted 4 November 2016.

Published online: 26 December 2016
DOI: 10.5152/eej.2016.16002

This work is licensed under a Creative Commons Attribution-NonCommercial 4.0 International License.





Figure 1. Expanded shape of XP-endo Finisher (austenitic phase)

ment unparalleled flexibility and ability to remove debris from the root canal system complexity. The XP-endo Finisher has an ISO 25 in diameter and zero taper (25/.00) at 20°C and below (martensitic phase) (13). The manufacturer claims that the reach of the instrument could be expanded to 6 mm in diameter or 100-fold of an equivalent sized file at 35°C and above (austenitic phase) (13) (Figure 1).

A literature review revealed no previous studies on the use of the XP-endo Finisher for residual root canal filling material removal in root canals with an oval cross-section. Therefore, the aim of this study was to compare the effectiveness of different additional techniques (EndoActivator, IrriSafe and XP-endo Finisher) in removing residual root canal filling material. The null hypothesis was that there would be no significant differences between the different additional techniques in removing residual root canal filling material.

MATERIALS AND METHODS

Selection of the samples

After receiving approval from the local ethics committee (Ondokuz Mayıs University Clinical Research Ethics Committee; no. B.30.2.ODM.0.20.08/1561), 100 mandibular canine teeth with flat oval canals that were extracted for periodontal reasons were selected for this study. Soft- and hard-tissue residues around the teeth were removed mechanically. The crowns of the teeth, the root length of which were 16 mm, were removed from the cement–enamel junction under water-cooling. Mesiodistal and buccal–lingual radiographs of the teeth were taken to determine the diameter of the canals. The teeth represented the ratio of the long diameter to the short diameter of the canal: >2 at 5 mm from the root apex and >3 at 8 mm from the apex were classified as oval (14). Teeth with calcified canals, prior root canal treatment, internal and/or external resorption, and crack and/or immature roots were excluded from the study. The selected teeth were kept in distilled water at 4°C until the experiment stage.

Root canal preparation

A #10 K-file (Dentsply Maillefer) was inserted into the root canals and moved until the tip of the file could be seen from

the apical foramen. The working length (WL) was established by subtracting 1 mm from this measurement. Subsequently, the apical diameters of the canals were prepared with manual files in a way to be #20 for glide path preparation. Samples with an apical diameter larger than #20 were not included in the study. Root canal preparation was performed at 300 rpm and 300 g cm⁻¹ torque, in accordance with the instructions of the manufacturer. During canal preparation, X1 (17.04), X2 (25.06), X3 (30.07) and X4 (40.06) files were operated using a torque-controlled endodontic motor (X-Smart; Dentsply Maillefer) with a ProTaper Next (Dentsply Maillefer) rotary system. The canals were irrigated with 2 ml of 5.25% NaOCl solution after each file. In the last irrigation process of the canals, 2 ml of 17% EDTA and 2 ml of 5.25% NaOCl solution were used to remove the smear layer.

Root canal obturation

Root canals were dried with paper points and obturated using the warm vertical compaction technique and the Calamus 3D Obturation System (Dentsply Maillefer). The quality of the root canal obturation was confirmed on mesiodistal and buccal–lingual radiographs. Samples with inadequate and/or nonhomogeneous root canal obturation were replaced with new ones. The samples were restored with a temporary obturation material (Cavit-G; 3M Espe, Seefeld, Germany) and kept in a 100% humid environment at 37°C for 14 days for the maximum setting of the root canal sealer (AH Plus; De Trey, Dentsply, Konstanz, Germany).

Retreatment technique

All samples were embedded separately in a silicone impression material (Elite HD; Zhermack, Badia Polesine, Italy) for retreatment procedures. To imitate the clinical setting, the samples were placed in a water bath at 37°C. No chemical solvent was utilised during the removal of root canal filling material.

In accordance with the instructions of the manufacturer, the DR1 (30.10) file, operating at 1000 rpm and 150 g cm⁻¹ torque with a torque-controlled endodontic motor (X-Smart), was used to remove the obturation materials from the coronal section of the canal. The DR2 (25.04) file, operating at 600 rpm and 70 g cm⁻¹ torque, was used to remove the obturation material from the middle and apical thirds. After each file instrumentation, the canals were irrigated with 2 ml of 5.25% NaOCl. For the final irrigation, 2 ml of 17% EDTA and 2 ml of 5.25% NaOCl, respectively, were used. While each DR1 file was used to remove canal filling material from the root canals of three samples, the DR2 file was used in one sample. A single operator performed all the retreatment processes. The roots were randomly divided into four groups (25 teeth each) according to the additional system used for removal of root canal filling material as follows:

Group 1: Conventional needle irrigation (CI)

In this group, an additional irrigation was performed with a syringe and a 30-G closed-end tip and side-port opening needle (Canal Clean, Biodent, South Korea). The irrigation needle was placed 1 mm short of the WL, and 5.25 % NaOCl was delivered into root canal at a constant flow rate of 6 ml/min.

Group 2: XP-endo finisher (XP)

The XP-endo Finisher NiTi file was used to activate the additional irrigation. Following insertion of 3 ml of 5.25% NaOCl solution into the root canal, the XP-endo Finisher was used with a torque-controlled endodontic motor at 800 rpm and 10 g cm⁻¹ according to the manufacturer’s instructions. The XP-endo Finisher was applied for 30 s, using slow and gentle 7–8 mm lengthwise movements to contact the full length of the canal. The canals were then flushed with 3 ml of 5.25% NaOCl, and the XP-endo Finisher was applied again for 30 s, using the same method. A total of 6 ml of 5.25% NaOCl was used, and the total activation time was 1 min.

Group 3: EndoActivator (EA)

In this group, 3 ml of 5.25% NaOCl was flushed into the canal and activated with the red EndoActivator (25.04) tip at 10,000 cycles/min. The tip was placed inside the canal at 1 mm short of the WL and operated using an up-and-down motion for 30 s. The canals were then flushed with 3 ml of 5.25% NaOCl and activated using the same method for 30 s. A total of 6 ml of 5.25% NaOCl was used, and the total activation time was 1 min.

Group 4: IrriSafe (IS)

The additional irrigation was activated using an ultrasonic tip; 3 ml of 5.25% NaOCl was flushed into the canal and ultrasonically agitated with the IrriSafe tip #25/25 which was placed inside the canal mm short of the WL and operated using an up-and-down motion for 30 s. The canals were then flushed with 3 ml of 5.25% NaOCl and activated using the same method for 30 s. The ultrasonic tip was placed into the canal 1 mm short of the WL, without touching the walls, enabling it to vibrate freely. A total of 6 ml of 5.25% NaOCl was used, and the total activation time was 1 min.

Evaluation of residual Gutta-percha and sealer

The teeth were grooved buccolingually using a stainless steel disc and then split into halves using a chisel and mallet. Digital images at 8x magnification were obtained from both halves under a stereomicroscope (Olympus BX43, Olympus Co., Tokyo, Japan) attached to a digital camera. The photographs were analysed using AutoCAD (Autodesk, San Rafael, CA, USA) software to measure the areas of residual gutta-percha and sealer (Figure 2).

Statistical analysis

According to the Kolmogorov–Smirnov test, the residual gutta-percha and sealer data were not normally distributed. Therefore, a nonparametric Kruskal–Wallis and post hoc Dunn’s tests were used, at P=0.05 to compare the mean area

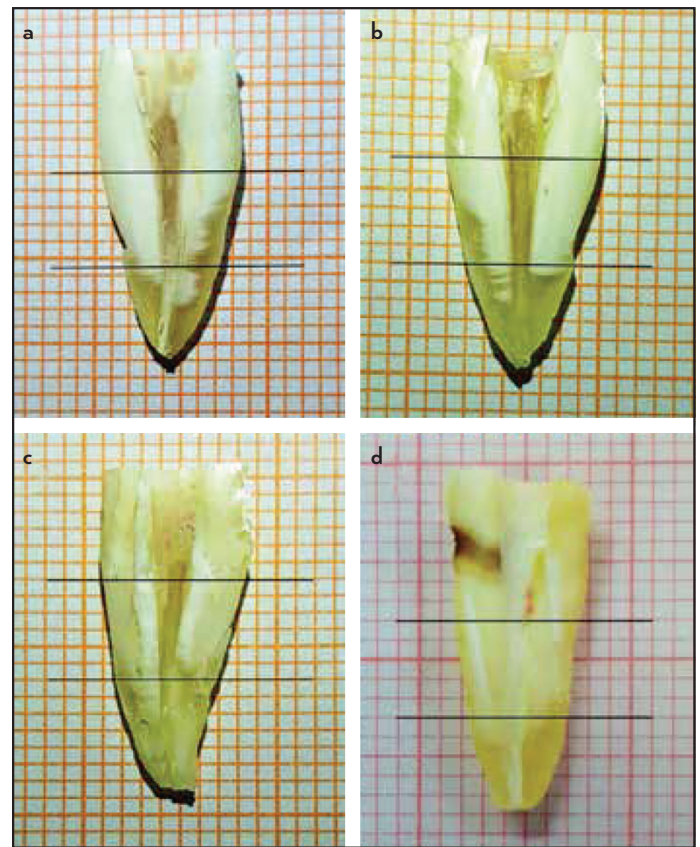


Figure 2. a–d. Measurement of residual gutta-percha and sealer via AutoCAD software (a) Conventional Irrigation (b) XP-endo Finisher (c) IrriSafe (d) EndoActivator

of residual gutta-percha and sealer. All the statistical analysis were performed with SPSS 21.0 (IBM Corp., Armonk, NY, USA) software.

RESULTS

The results for the mean area of residual gutta-percha and sealer are shown in Table 1. There was a significant difference regarding the total residual gutta-percha and sealer among groups (P<0.001). The mean area of the gutta-percha and sealer remnant in the XP group (0.80±0.25) was significantly lower than that in the other groups (P<0.001). The mean area of gutta-percha and sealer remnant in the CI group (1.84±0.50) was significantly greater than that in the other groups (P<0.001).

When comparing the root canal regions, the apical third of the CI group had significantly more residual gutta-percha and sealer when compared to that of the other groups (P<0.001).

TABLE 1. Mean and Standard Deviations of Residual Gutta-percha and Sealer on Canal Walls (mm²)

Group	Apical	Middle	Coronal	P value	Total
XP-endo Finisher	0.80±0.25 ^{x a}	0.80±0.32 ^{x a}	0.79±0.18 ^{x a}	>0.05	0.80±0.25 ^x
EndoActivator	0.93±0.28 ^{x a}	1.21±0.25 ^{yz bc}	1.20±0.36 ^{y ac}	<0.05	1.11±0.32 ^y
IrriSafe	0.82±0.33 ^{x a}	1.07±0.47 ^{z ac}	1.25±0.37 ^{y bc}	<0.05	1.05±0.43 ^y
Conventional Irrigation	2.05±0.49 ^{y a}	1.50±0.40 ^{y b}	1.97±0.42 ^{z a}	<0.001	1.84±0.50 ^z
P value	<0.001	<0.001	<0.001		<0.001

*Different superscript letters indicate a significant difference between groups (abc; for rows and xyz; for columns)

In the middle third, the amount of residual gutta-percha and sealer was lower in the XP and IS groups than in the other groups ($P>0.05$). In the coronal third, the amount of residual gutta-percha and sealer in the XP group was significantly lower than in the other groups ($P<0.001$).

None of the DR1 files were fractured. However, two DR2 files fractured (1 in the EA group and 1 in the IS group) during the gutta-percha removal procedures. These samples were changed with new ones.

DISCUSSION

Previous studies have reported that in the oval cross-section root canals, residual root canal filling materials remains in the buccal and lingual walls of root canals after retreatment with NiTi files (15). Therefore, additional activation processes are needed when using NiTi files to ensure complete cleaning of the root canal. The aim of the present study was to evaluate the efficiency of various activation methods applied after removing gutta-percha and sealer in the oval canals.

Various methods, such as micro-tomography (16), longitudinal sectioning (17) and radiological assessment (18), have been used to evaluate root canal residual gutta-percha and sealer. Micro-tomography could provide 3D information and accurate quantification data (volume) of the remaining filling materials (19). In the present study, the longitudinal sectioning method was preferred because it enables a direct examination of the samples. Thus, it is easier to determine root canal obturation materials using the sectioning method than using radiographic techniques; also, it is less costly (20). The radiological method provides 2D images of the 3D structure; magnification and distortions are likely to occur in the image, potentially increasing the possibility of inaccurate results (21). When using the cross-sectioning method, extreme care must be taken to prevent the displacement of remaining gutta-percha from the samples. In the present study, 13 samples (XP group, $n=2$; EA group, $n=3$; IS group, $n=3$ and CI group, $n=5$) had to be replaced due to damage during the cross sectioning.

In the current study, mandibular canine teeth with oval cross-section canal were selected based on previous studies (22, 23). To ensure standardisation of the samples, the crowns of the teeth, all of which had a root size of 16 mm, were removed at the cemento-enamel junction. Obturation of the root canals using the vertical compaction technique was reported to provide a more homogeneous canal obturation than the single-cone and lateral compaction technique (23). Thus, in the present study, the canals were obturated using the vertical compaction technique.

The gutta-percha removal processes were performed in a water bath at 37°C, with an intention to imitate the normal body temperature and allow the XP-endo Finisher to proceed the austenitic phase in the presence of heat.

Previous research has shown that using larger files during the preparation of the apical diameter of the root canal reduces the amount of obturation material remaining after the gutta-percha removal process (24). However, excessive

enlargement of root canals might reduce the amount of dentin remaining and reduce the resistance of the root canal, leading to the formation of vertical root fracture (25). For this reason, the apical diameter of the canals was not enlarged in the present study. Solvent was not used with the NiTi rotary instruments in the present study. Along with friction, solvent softens gutta-percha and allows the files to easily reach the WL. However, as shown in a previous study, gutta-percha that is softened by solvent can easily reach to canal system complexities (26); in this case, cleaning of the canals becomes difficult.

The repeated use of NiTi files can cause various problems, such as abrasion, distortion and microcracks in the surface of the file. As shown in previous studies (27, 28), cutting activities are reduced, and the instruments are more vulnerable to breakage. Thus, in the present study, the DR1 file was used in three samples and DR2 was used in one sample and then discarded, in accordance with the manufacturer's recommendations (29).

According to the results of the present study, the amount of gutta-percha and sealer residue was lowest in the XP group and highest in the CI group ($P<0.001$). There was no significant difference in the amount of gutta-percha and sealer residue in the EA and IS groups ($P>0.05$). Thus, the null hypothesis of our study was rejected. We attribute the findings to the different efficiencies of the activation processes.

In the current study, none of the methods applied in the groups were capable of removing the entire gutta-percha and sealer from the root canals. This finding is similar to the results of previous studies, which used different systems, instruments and/or methodology (30, 31). As noted above, in the present study, the amount of gutta-percha and sealer residue in the root canal walls was significantly lowest in the XP group. A detailed literature review showed that there were no retreatment studies conducted with the XP-endo Finisher NiTi file in oval root canals. Thus, it is not possible to compare the findings obtained in the XP group with those reported in earlier studies. In a recent study, Alves et al. (32) reported that the usage of XP-endo Finisher significantly improved filling material removal in retreatment process in mandibular molar's mesial roots. Also, a recent study that evaluated the efficacy of four final irrigation protocols on the reduction of hard-tissue debris accumulated within the mesial root canal system of mandibular first molars (33). The authors reported that XP-endo Finisher and passive ultrasonic irrigation was statistically more effective than CI and Self-adjusting File (ReDent-Nova, Ra'anana, Israel). The lower amount of gutta-percha and sealer residue in the XP group compared to that of the other groups might stem from the fact that after the file passes from the martensitic to the austenitic phase at temperatures over 35°C, the file can expand to 100 times of its diameter and contact all of the canal wall (13).

A few studies have examined the effect of sonic or ultrasonic activation applied after gutta-percha removal on root canal wall cleaning (34). In the present study, a greater amount of gutta-percha and sealer were removed in the EA and IS

groups than in the CI group ($P < 0.001$). A study of the cleaning efficiency of the EA versus that of ultrasonic activation with an ultrasonic tip and laser after a retreatment process reported that the ultrasonic was more efficient (34). In the present study, although there was no significant difference in the amount of gutta-percha and sealer residue in the IS and EA groups ($P > 0.05$), the canals were cleaner in the IS group. In accordance with the findings of the present study, a previous retreatment study reported that ultrasonic activation removed significantly more residual gutta-percha than conventional syringe irrigation (11). Ultrasonic cleaning of root canals containing residual filling materials during the retreatment process is based on the transfer of acoustic energy to the ultrasonic tip and then to the irrigation solution. In contrast, with the Endo-Activator, sonic energy is transferred directly to the irrigation solution. As reported earlier, high energy greatly increases the fluidity of irrigation solution in the canal (35). The aforementioned explains the greater amount of gutta-percha and sealer removal in the EA and IS groups compared to the CI group. There are some limitations to the present study. The results of the present study cannot be compared with studies that focus on teeth with curved root canals. Root canal curvature might affect the efficacy of gutta-percha removal. During longitudinal sectioning, gutta-percha and sealer remnants could be damaged. Therefore, the conclusion of the present study cannot be directly applied to clinical conditions. Further *in vivo* studies are needed to confirm the results of the present study.

CONCLUSION

Within the limitations of this study, the XP-endo Finisher file was the most effective activation method in additional removal of old root canal filling material during retreatment procedures.

Disclosures

Ethical Approval: Ethics committee approval was received for this study from the local ethics committee.

Informed Consent: N/A

Peer-review: Externally peer-reviewed.

Authorship contributions: Concept - T.Ö.; Design - T.Ö.; Supervision - T.Ö.; Funding - T.Ö.; Materials - T.Ö.; Data Collection and/or Processing - T.Ö.; Analysis and/or Interpretation - T.Ö.; Literature Review - T.Ö.; Writer - T.Ö., E.Ö.D.; Critical Review - T.Ö., E.Ö.D.

Conflict of interest: No conflict of interest was declared by the authors.

Financial Disclosure: The authors declared that this study has received no financial support.

REFERENCES

- Topçuoğlu HS, Topçuoğlu G, Akti A. Comparative evaluation of cyclic fatigue resistance of D-RaCe and ProTaper retreatment instruments in curved artificial canals. *Int Endod J* 2015; 49:604-9.
- Inan U, Aydın C. Comparison of cyclic fatigue resistance of three different rotary nickel-titanium instruments designed for retreatment. *J Endod* 2012; 38:108-11.
- Saad AY, Al-Hadlaq SM, Al-Katheeri NH. Efficacy of two rotary NiTi instruments in the removal of gutta-percha during root canal retreatment. *J Endod* 2007; 33:38-41.
- Giuliani V, Cocchetti R, Pagavino G. Efficacy of ProTaper universal retreatment files in removing filling materials during root canal retreatment. *J Endod* 2008; 34:1381-4.
- Rödiger T, Hausdörfer T, Konietschke F, et al. Efficacy of D-RaCe and ProTaper Universal Retreatment NiTi instruments and hand files in removing gutta-percha from curved root canals—a micro-computed tomography study. *Int Endod J* 2012; 45:580-9.
- Rechenberg DK, Paqué F. Impact of cross-sectional root canal shape on filled canal volume and remaining root filling material after retreatment. *Int Endod J* 2013; 46:547-55.
- Simsek N, Keles A, Ahmetoglu F, et al. Comparison of different retreatment techniques and root canal sealers: a scanning electron microscopic study. *Braz Oral Res* 2014; 28:1-7.
- Paqué F, Peters OA. Micro-computed Tomography Evaluation of the Preparation of Long Oval Root Canals in Mandibular Molars with the Self-adjusting File. *J Endod* 2011; 37:517-21.
- Versiani MA, Pécora JD, de Sousa-Neto MD. Flat-oval root canal preparation with self-adjusting file instrument: a micro-computed tomography study. *J Endod* 2011; 37:1002-7.
- Kunert GG, Camargo Fontanella VR, de Moura AA, Barletta FB. Analysis of apical root transportation associated with ProTaper Universal F3 and F4 instruments by using digital subtraction radiography. *J Endod* 2010; 36:1052-5.
- Cavenago B, Ordinola-Zapata R, Duarte M, et al. Efficacy of xylene and passive ultrasonic irrigation on remaining root filling material during retreatment of anatomically complex teeth. *Int Endod J* 2014; 47:1078-83.
- Tachinami H, Katsuumi I. Removal of root canal filling materials using Er:YAG laser irradiation. *Dent Mater J* 2010; 29:246-52.
- FKG. The XP-endo Finisher Brochure. Available at: <http://www.fkg.ch/products/root-canal-preparation-and-retreatment/xp-endo-finisher>. Accessed March 15, 2016.
- Jou Y-T, Karabucak B, Levin J, Liu D. Endodontic working width: current concepts and techniques. *Dent Clin* 2004; 48:323-35.
- Wu M, Sluis L, Wesselink P. The capability of two hand instrumentation techniques to remove the inner layer of dentine in oval canals. *Int Endod J* 2003; 36:218-24.
- Keleş A, Arslan H, Kamalak A, et al. Removal of Filling Materials from Oval-shaped Canals Using Laser Irradiation: A Micro-computed Tomographic Study. *J Endod* 2015; 41:219-24.
- Chou K, George R, Walsh LJ. Effectiveness of different intracanal irrigation techniques in removing intracanal paste medicaments. *Aust Endod J* 2014; 40:21-5.
- Özyürek T, Demiryürek EÖ. Efficacy of Different Nickel-titanium Instruments in Removing Gutta-percha during Root Canal Retreatment. *J Endod* 2016; 42:646-9.
- de Carvalho Maciel A, Zaccaro Scelza M. Efficacy of automated versus hand instrumentation during root canal retreatment: an ex vivo study. *Int Endod J* 2006; 39:779-84.
- Asheibi F, Qualtrough AJ, Mellor A, Withers PJ, Lowe T. Micro-CT evaluation of the effectiveness of the combined use of rotary and hand instrumentation in removal of Resilon. *Dent Mater J* 2014; 33:1-6.
- Gergi R, Sabbagh C. Effectiveness of two nickel-titanium rotary instruments and a hand file for removing gutta-percha in severely curved root canals during retreatment: an ex vivo study. *Int Endod J* 2007; 40:532-7.
- Keles A, Kamalak A, Keskin C, Akçay M, and Uzun İ. (2016), The efficacy of laser, ultrasound and self-adjustable file in removing smear layer debris from oval root canals following retreatment: A scanning electron microscopy study. *Aust Endod J*, 42: 104-111. doi:10.1111/aej.12145
- Ma J, Al-Ashaw AJ, Shen Y, et al. Efficacy of ProTaper Universal Rotary Retreatment System for Gutta-percha Removal from Oval Root Canals: A Micro-Computed Tomography Study. *J Endod* 2012; 38:1516-20.
- Schäfer E, Schrenker C, Zupanc J, Bürklein S. Percentage of Gutta-percha Filled Areas in Canals Obturated with Cross-linked Gutta-percha Core-carrier Systems, Single-Cone and Lateral Compaction Technique. *J Endod* 2015; 42:294-8.
- Hassanloo A, Watson P, Finer Y, Friedman S. Retreatment efficacy of the Epiphany soft resin obturation system. *Int Endod J* 2007; 40:633-43.
- Hülsmann M, Drebenstedt S, Holscher C. Shaping and filling root canals during root canal re-treatment. *Endod Top* 2008; 19:74-124.
- Kfir A, Tsesis I, Yakirevich E, et al. The efficacy of five techniques for removing root filling material: microscopic versus radiographic evaluation. *Int Endod J* 2012; 45:35-41.
- Sağlam BC, Görgül G. Evaluation of surface alterations in different retreatment nickel-titanium files: AFM and SEM study. *Micro Res Technol* 2015; 78:356-62.

29. Arantes WB, da Silva CM, Lage-Marques JL, et al. JMF. SEM analysis of defects and wear on Ni-Ti rotary instruments. *Scanning*. 2014; 36:411-8.
30. FKG. The D-Race Brochure. Available at: <http://www.fkg.ch/products/root-canal-preparation-and-retreatment/d-race>. Accessed March 15, 2016.
31. Zuolo A, Mello J, Cunha R, et al. Efficacy of reciprocating and rotary techniques for removing filling material during root canal retreatment *Int Endod J* 2013; 46:947-53.
32. Alves FRF, Marceliano-Alves MF, Sousa JCN, Silveira SB, et al. Removal of Root Canal Fillings in Curved Canals Using Either Reciprocating Single-or Rotary Multi-instrument Systems and a Supplementary Step with the XP-Endo Finisher. *J Endod* 2016; 43:1114-9.
33. de Azevêdo Rios M, Villela AM, Cunha RS, et al. Efficacy of 2 reciprocating systems compared with a rotary retreatment system for gutta-percha removal. *J Endod* 2014; 40:543-6.
34. Leoni GB, Versiani MA, Silva-Sousa YT, Bruniera JFB, Pécora JD, Sousa-Neto MD. Ex vivo evaluation of four final irrigation protocols on the removal of hard-tissue debris from the mesial root canal system of mandibular first molars. *International Endodontic Journal*.
35. Jiang S, Zou T, Li D, et al. Effectiveness of Sonic, Ultrasonic, and Photon-Induced Photoacoustic Streaming Activation of NaOCl on Filling Material Removal Following Retreatment in Oval Canal Anatomy. *Photomed Laser Surg* 2016; 34:3-10.