

# Microscopic examination of normal nail clippings

Betina Werner<sup>1</sup>, Andre Antunes<sup>2</sup>

<sup>1</sup> Dermatopathologist, Department of Pathology, Universidade Federal do Paraná, Curitiba, Brazil

<sup>2</sup> Graduate student, Universidade Tuiuti do Paraná, Curitiba, Brazil

**Key words:** nails, normality, nail clipping, microscopy, histotechnology

**Citation:** Werner B, Antunes A. Microscopic examination of normal nail clippings. *Dermatol Pract Conc.* 2013;3(3):4. <http://dx.doi.org/10.5826/dpc.0303a04>.

**Received:** May 1, 2013; **Accepted:** June 1, 2013; **Published:** July 31, 2013

**Copyright:** ©2013 Werner et al. This is an open-access article distributed under the terms of the Creative Commons Attribution License, which permits unrestricted use, distribution, and reproduction in any medium, provided the original author and source are credited.

**Funding:** None.

**Competing interests:** The authors have no conflicts of interest to disclose.

Dr. Betina Werner and Mr. Andre Antunes had full access to all of the data in the study and take responsibility for the integrity of the data and the accuracy of the data analysis.

All authors have contributed significantly to this publication.

**Corresponding author:** Betina Werner, M.D., Ph.D., Rua Dr. Nelson de Souza Pinto, 759. CEP 82200-060, Curitiba, PR, Brazil. Tel. (41) 9116 0525. E-mail: [betina.werner@gmail.com](mailto:betina.werner@gmail.com).

**ABSTRACT** **Background:** Nail clipping analysis for diagnosing causes of onychodystrophy other than onychomycosis is investigated to a very small extent. In order to achieve acceptance as a diagnostic method for any kind of nail abnormalities, normal microscopic parameters have to be established first. In most reported cases, nail plates were fixed in formalin with processing of the specimens with routine automated histotechnique.

**Methodology:** Fifteen pairs of normal nails were studied. One nail fragment was placed in a container with formalin, and the other was kept dry in a proper receptacle. Fixed specimens were submitted to standard automated tissue processing (formalin group) and dry specimens were directly embedded in paraffin (dry group). Several microscopic parameters were analyzed.

**Results:** Nail plate thickness ranged from 0.25 to 0.50 mm (mean 0.36 mm) and subungual region from 0 to 0.31 mm (mean 0.11 mm). Forty-one percent of cases presented onychokaryosis, and hyper eosinophilic nuclear shadows were detected in 63%, statistically more frequent in the dry group ( $p=0.002$ ). Parakeratosis was present in 86% of nails varying from 1 to 13 layers (mean 5.6). None of the nails presented fungi, neutrophils, and blood or serum collections. Bacteria were seen in 60% of specimens. Both groups yielded adequate microscopic preparations for analysis with no statistical difference in the dryness or hardness of specimens or difficulty in cutting the paraffin blocks ( $p=1$ ).

**Conclusion:** These microscopic findings of a normal population can be used as parameters for evaluating any cause of onychodystrophy. The dry method is faster and cheaper and yields adequate slide preparations for microscopic analysis of nail clippings.

## Introduction

Nail plate microscopic analysis in PAS stained slides, also known simply as nail clipping, is an established test used in the diagnosis of onychomycosis [1-7], and in one study it

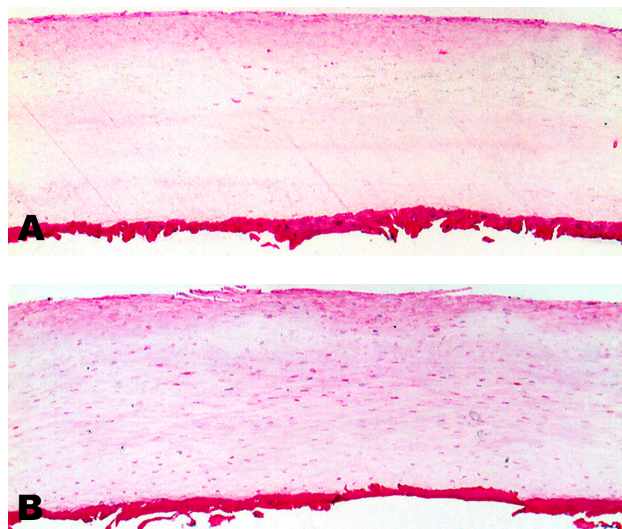
proved to have a role in discovering clinically unapparent nail fungal infection [8]. Its application in evaluating causes of onychodystrophy other than fungal infection is reported to a very small extent, though [2,9,10]. Because we believe microscopic evaluation of nail clippings may be a potential

tool in investigation of nail dystrophies of any cause, not only mycotic but also inflammatory and traumatic, we considered necessary to establish normal microscopic parameters first.

Furthermore, in order to make the diagnostic test of nail clippings easier and quicker, we propose a method of microscopic preparation without fixation with formalin and automated tissue processing. We will compare that method with an alternative one, in which nail fragments are placed directly in paraffin, without fixation and automated microscopic tissue processing.

## Materials and methods

Volunteers were asked to donate nail clippings from two fingers. Inclusion criteria: healthy adults with no visible nail abnormality and without any local or systemic disease that could interfere with nail growth. Exclusion criteria: manicure or nail biting habits. The subjects were oriented in such a way so as to obtain a full-thickness nail sample with nail clippers or scissors (as far proximally as possible without discomfort) from the distal part of both annular fingers nail plates. Randomly, one nail fragment was placed in a container with 10% formalin, and the other was put in a dry sealed receptacle. The samples were coded to allow blinded paraffin block sectioning, slide preparation/staining and microscopic interpretation. Cassettes with formalin-fixed specimens were submitted to standard automated tissue processing, and cassettes with dry specimens were directly immersed in melted paraffin (68° C) for 50 minutes. For paraffin embedment, in all specimens, the long axis of the nail fragment was oriented in a way that would allow microtomy to be achieved at a right angle to the microtome blade. Once all paraffin blocks were ready for sectioning, each block was trimmed with caution to only expose the nail down to a level where a representative section could be obtained. The cut faces of the blocks were kept facing an icy cold surface (approximately 1° C) with 10% ammonium hydroxide solution for 30 minutes, prior to microtomy. Paraffin sections were cut at 2 microns and placed on Meyer albumin coated slides. Two slides from each block were obtained, one subjected to staining with hematoxylin and eosin (H&E) and the other with PAS with digestion (PAS). The H&E-stained slides were evaluated for the following microscopic features: nail plate and subungual region thickness (measured using a microscopic ruler), and the presence or absence of neutrophils, bacteria, parakeratosis, onychokaryosis (name given for the retention of nuclei in the nail plate) and hypereosinophilic nuclear shadows (name given for the apparent staining of the "nuclei ghosts" of onychocytes). The PAS-stained slides were evaluated for fungi. Both H&E and PAS-stained sections were examined using the light microscope by the dermatopathologist (BW) blinded to the processing method used.



**Figure 1.** (A) Nail from the formalin group and (B) nail from the dry group. Two regions are readily discernable: nail plate (above) and subungual region (below). H&E x100 (original magnification). [Copyright: ©2013 Werner et al.]

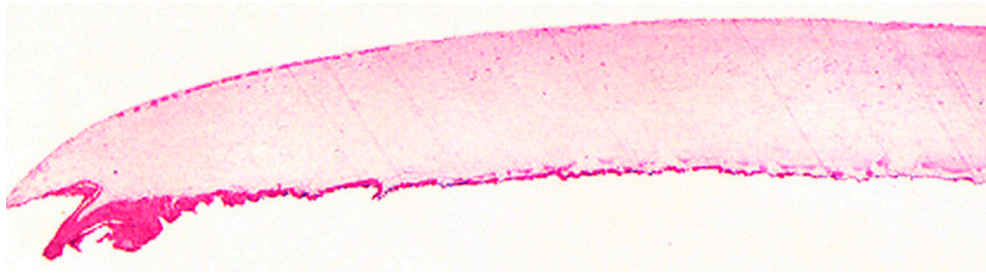
The statistical analysis of quantitative variables was performed with descriptive statistics, such as the mean, median, standard deviation, minimum and maximum. In order to compare the two microscopic processing methods used, non-parametric Wilcoxon test for quantitative variables, non-parametric McNemar test for dichotomous categorical variables, and Sign test for ordinal categorical variables were applied. P values < 0.05 were considered statistically significant.

## Results

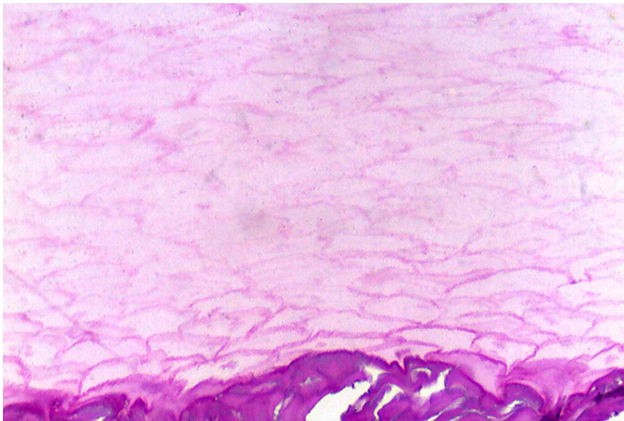
There were 13 male and two female subjects enrolled in the study yielding 15 pairs of nails. Ages varied from 20 to 62 years (mean 36, median 33, SD +/-11.4 years). Because one fragment of each individual was randomly selected for one of the methods tested, we examined 15 formalin-fixed specimens and submitted to standard automated tissue processing (formalin group), and 15 specimens kept dry and directly embedded in paraffin (dry group). Nail specimens measured from 9 to 14 mm in length (mean 10.7, median 10, SD +/-1.3 mm) and from 1 to 3 mm in width (mean 1.8, median 2, SD +/-0.65 mm). Formalin and dry groups were statistically similar regarding length and width of nail fragments (p=0.62 and 0.27, respectively).

All microscopic preparations were done by one of the authors (AA), on the same day. There was no statistical difference in the feeling of dryness or in difficulty in cutting of the specimens among the groups (p=1 in both variables).

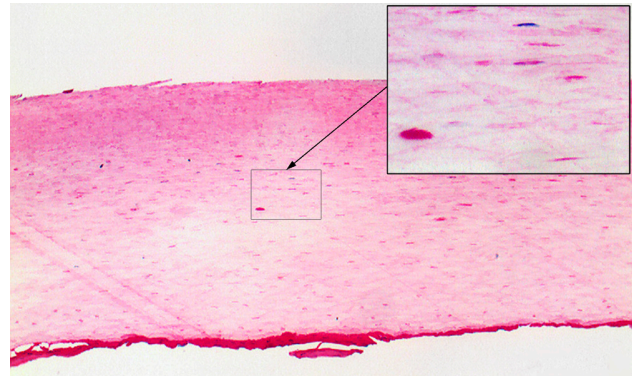
Both PAS and H&E in the formalin and dry groups were adequate for analysis and showed two readily discernable areas: plate (external) and subungual region (internal) (Figure 1A and 1B). The corners or extremities of nails had a wavy configuration in the subungual region in contrast with



**Figure 2.** Panoramic view of nail from the formalin group. In several instances the corners or extremities of nails had a wavy configuration in the subungual region. H&E x40 (original magnification). [Copyright: ©2013 Werner et al.]



**Figure 3.** Nail from the formalin group. Onychocytes borders are better seen in the PAS staining. PAS x400 (original magnification). [Copyright: ©2013 Werner et al.]



**Figure 4.** Nail from the dry group showing several hyper eosinophilic nuclear shadows and onychokaryosis. Insert: one fusiform basophilic nucleus (upper half) and several hyper eosinophilic "stains" in the center of onychocytes. H&E x100 and x400 (original magnification). [Copyright: ©2013 Werner et al.]

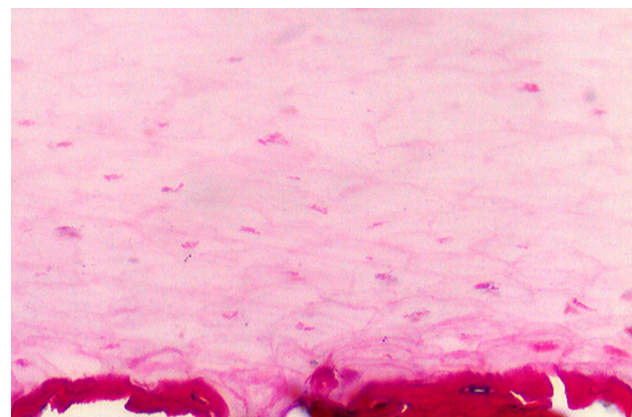
a smoother surface in the center of the fragment (Figure 2). Nail plate thickness ranged from 0.25 to 0.50 mm (mean 0.36, median 0.37, SD +/-0.06 mm) and subungual region thickness from 0 to 0.31 mm (mean 0.11, median 0.08, SD +/-0.07 mm); those measures were not statistically different among the groups tested ( $p=0.59$  e  $0.91$ , respectively).

The contours of cells from nail plate (onychocytes) were better seen with PAS staining; cells increased in size closer to the subungual region (Figure 3). In 12 instances (41% of cases) nail plates presented few basophilic fusiform nuclei (onychokaryosis), usually in the outer aspect of the plate, and that finding was much more evident in the dry group (Figure 4). The presence of hyper eosinophilic nuclear shadows was a common finding, detected in 63% of specimens, also more prominent in the dry group (Figure 4). In half of cases that finding was observed in the inferior/internal aspect of the plate (Figure 5), statistically more frequent in the dry group ( $p=0.002$ ).

Nuclei in the subungual region (parakeratosis) were present in 86% of nails, and thickness varied from 1 to 13 layers of nuclei thick (mean 5.6, median 4, SD +/-3.5 layers) (Figure 6). None of the nails examined presented fungi, neutrophils, and blood or serum collections. Bacteria were seen in 60% of specimens in foci of the subungual region, usually in the corners, and in small amounts (Figure 7).

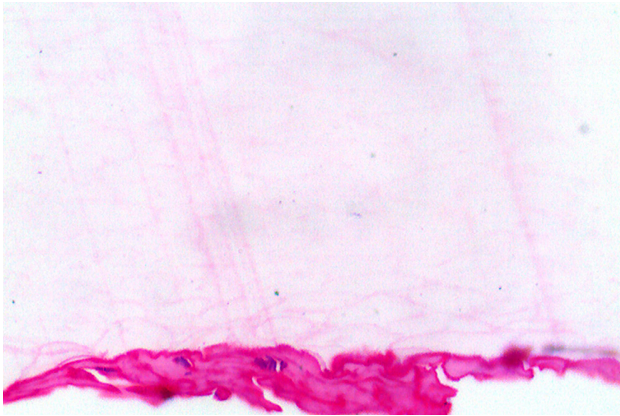
## Discussion

Microscopic examination of nail clippings immediately involves two discernable regions: the nail plate itself and the subungual region. Nail plate and subungual region analysis reflects nail matrix and nail bed status, respectively [11-13]. Although the nail plate shows a subtle and subjective difference in the superior and inferior parts (superior onychocytes are smaller than inferior onychocytes), we were not able to separate those two regions with confidence. Nonetheless, an

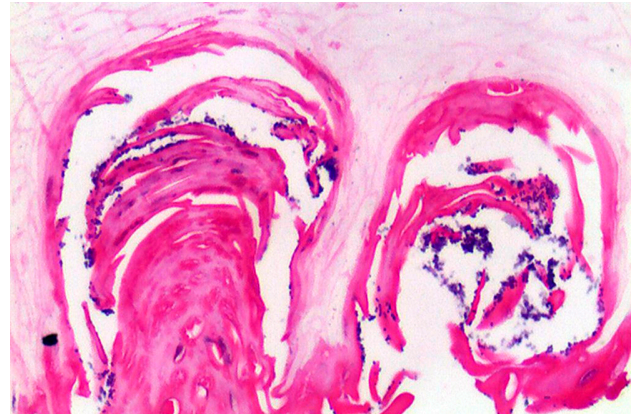


**Figure 5.** Nail of the dry group showing prominent hyper eosinophilic nuclear shadows in the inferior/internal aspect of the plate. H&E x400 (original magnification). [Copyright: ©2013 Werner et al.]





**Figure 6.** Nuclei in the subungual region (parakeratosis) in a nail of the formalin group. H&E x400 (original magnification). [Copyright: ©2013 Werner et al.]



**Figure 7.** Bacteria in subungual region in a nail of the formalin group. H&E x400 (original magnification). [Copyright: ©2013 Werner et al.]

ultrastructural study of normal nails permitted the definition of three regions of nail apparatus: upper and lower parts of the plate, and what is called hyponychium (subungual region) [14]. The border between the two parts of the nail plate were not easily discernable, however, cells at the upper part of the nail plate were more flattened when compared to ones at the lower part [14]. So, they also demonstrated progressive thickening of the plate cells from the nail surface to the subungual region limit. Furthermore, the authors found that onychocytes of the upper part of nail plates were joined laterally by sparse and deep digitations, in contrast to onychocytes from the lower part of the plate which had membranes showing a different pattern: the digitations were regular and numerous, but shallow [14]. Similar to the present microscopic study, the ultrastructural investigation of Parent and colleagues [14] showed that the limit between the plate and the subungual region was clearly discernible because different sizes, morphology, and staining affinities of the cells in the two regions existed. Therefore, the microscopic separation of the nail in three regions, namely, superior part of nail plate, inferior part of nail plate and subungual region, has the potential of taking the nail clipping analysis to a higher level. The dorsal aspect of nail plate (superior half) yields information about the proximal nail matrix, the ventral aspect of nail plate, immediately above the subungual region (inferior half), reveals facts concerning the distal nail matrix, and the subungual region reflects what is going on the nail bed. That approach could be very useful if nail-clipping examination is used to investigate nail diseases that affect one or other part of nail apparatus, in particular. Or, to the contrary, microscopic examination of nail clippings could indicate where in the nail apparatus disease is more prominent.

One has to keep in mind that microscopic examination of nail plates can be compared to looking at the starry sky at night: one is observing the past, because the distal part of the nail that is clipped off was formed around six months previously [11,15]. Therefore, microscopic findings seen in

the nail tell of standing disease (and also either topical or systemic treatment influences) that the patient had several months before the time clipping was performed.

As mentioned before, in the literature, nail clipping has an established role only for the diagnosis of onychomycosis [1-8]. Apart from that, nail-clipping microscopy was superficially studied in psoriasis [2], but in comparison to fungal infection; alopecia areata [9], a light and electron microscopic study in only nine patients; and in onychomatricoma [10], a case report. As far as we are concerned, the study of Laporte and co-workers [9] in alopecia areata was the first publication that used the microscopic examination of nail clipping as an investigation tool for a disease, in 1988 [9]. They analyzed nails from nine patients with alopecia areata and found architectural disorder of the corneocyte arrangement, parakeratosis of variable intensity, disintegration and little depressions in the upper part of the plate, and noted that the subungual keratin was spared. Neither those authors showed frequency or intensity in their microscopic findings, nor did they compare to normal controls.

On the other hand, Mahler and colleagues, in 1998 [2], sought for microscopic differences in nail clippings between dystrophic changes due to psoriasis and onychomycosis, compared to normal controls. They examined four cases of onychomycosis, 14 cases of psoriasis and five normal controls. In nails with psoriasis they concluded: “the psoriatic nails were dystrophic with foci of parakeratosis and frequently scattered neutrophils in the residual nail bed”, without giving a full account of those findings. And about the nails without dystrophy they commented: “the normal nail cases were uniform and demonstrated only compact hyperkeratosis”, without any further details.

In the present normal population that we studied, we found that nail plates and subungual regions measured around 0.37 and 0.08 mm in thickness, respectively, and nuclei in the subungual region (parakeratosis) was a common finding (86%), the numbers of layers varying from 1

to 13 layers of nuclei thick (mean 5.6). The external surface of all specimens was smooth, and no depressions were observed. Those parameters can be easily used for comparison with dystrophic nails. What we called onychokaryosis (nuclei in nail plate) was seen in 12 nails examined (41%), particularly in the superior part of nail. What we named hypereosinophilic nuclear shadow was a common finding (63% of nails examined), and was observed in the inferior/internal part of the plate statistically more frequent in the dry group ( $p=0.002$ ). Both onychokaryosis and hypereosinophilic nuclear shadow were more easily perceived in the specimens pertaining to the dry group, in general. That feature gave the dry group a “busier” look when compared to the formalin group. The meaning of these two findings and why they are sometimes present in normal nails, though, remains to be investigated further. It would be very interesting to evaluate these two parameters in dystrophic nails, to see whether nuclear retention (onychokaryosis) or some sort of cell maturation (hypereosinophilic nuclear shadow) would be increased or decreased.

Fungi, neutrophils, and blood or serum collections were not seen in any case examined, and the presence of those features may indicate nail disease. On the contrary, as expected, bacteria were seen in the subungual region (60% of nails analyzed), but usually in the corners of nails and in small amounts. For that reason, the presence of bacteria should not be taken as an abnormal finding itself, although variations in the amount and localization of those organisms could have a meaning in nail abnormality investigation.

Although nail fragments are easily obtainable specimens, a nail plate specimen is very difficult to cut for microscopic preparations, due to its hardness. Probably that is one of the reasons why microscopic analysis of nail clippings is not a widespread technique in onychodystrophy investigations. A good microscopic slide is usually time consuming to make and is totally dependent upon an experienced histotechnologist. The techniques described in the literature for nail processing vary, though. The majority of nail clipping studies fix the specimens in formalin [1-8, 10,17], some apply substances for softening of the nail plate, like chitin-softening solution [1,10] and Tween solution [5]. Several articles mentioned using traditional routine histologic examination for nail processing [1,2,3,7,10], few studies applied what seemed to be a diverse microscopic processing only with a series of ethanol [4,6], and a few did not use any microscopic processing at all after fixing with formalin and before paraffin embedding [5,8]. One study obtained good histologic preparations without using a fixative and immersed nail fragments in a solution of liquid hand soap and distilled water followed by a process in a routine overnight cycle [16], and in only two reports the samples examined were immediately wrapped in paraffin without using a fixative liquid [9,17].

In the present study we tried to compare the more conventional method of microscopic slides preparations for nails, i.e., fixing nail fragments in formalin and processing the specimens as done in routine histotechnology, with the less widespread procedure in which nail clippings are placed directly in paraffin without fixation and automated microscopic tissue preparation. Both techniques yielded adequate microscopic preparations and no difference was detected either in cutting the paraffin block or in preparing and staining the slide. It seems that the main vantage of not using formalin fixation followed by standard histotechnology with overnight processing, is that the dry specimens allow a faster microscopic slide preparation of the nail clippings and is a less expensive technique. However, the microscopic aspect of the slides on H&E and PAS differ between the methods. The dry specimens delivered more “busy” sections, where nuclei and hypereosinophilic stains were more often seen in nail plates, when compared to the formalin-fixed ones. That microscopic difference between techniques must be kept in mind when dystrophic nails are analyzed using one or the other method of slide preparation.

In conclusion, we believe nail clippings are a valuable source of information when considering inflammatory and traumatic onychodystrophy. We here delineate microscopic findings of a normal population used as basis for evaluating any cause of nail abnormalities under the microscope. The alternative method of not using formalin fixation and overnight automated processing is faster and less expensive and yields adequate slide preparations stained with H&E and PAS for microscopic analysis of nail clippings.

## References

1. Suarez SM, Silvers DN, Scher RK, Pearlstein HH, Auerbach R. Histologic evaluation of nail clippings for diagnosing onychomycosis. *Arch Dermatol.* 1991;127(10):1517-9.
2. Machler BC, Kirsner RS, Elgart GW. Routine histologic examination for the diagnosis of onychomycosis: an evaluation of sensitivity and specificity. *Cutis.* 1998;61(4):217-9.
3. Lawry MA, Haneke E, Strobeck K, et al. Methods for diagnosing onychomycosis: a comparative study and review of the literature. *Arch Dermatol.* 2000;136(9):1112-6.
4. Gianni C, Morelli V, Cerri A, et al. Usefulness of histological examination for the diagnosis of onychomycosis. *Dermatology.* 2001;202(4):283-8.
5. Barak O, Asarch A, Horn T. PAS is optimal for diagnosing onychomycosis. *J Cutan Pathol.* 2010;37(10):1038-40.
6. Wilsmann-Theis D, Sareika F, Bieber T, Schmid-Wendtner MH, Wenzel J. New reasons for histopathological nail-clipping examination in the diagnosis of onychomycosis. *J Eur Acad Dermatol Venereol.* 2011;25(2):235-7.
7. Mayer E, Izhak OB, Bergman R. Histopathological periodic acid-schiff stains of nail clippings as a second-line diagnostic tool in onychomycosis. *Am J Dermatopathol.* 2012;34(3):270-3.
8. Walling HW. Subclinical onychomycosis is associated with tinea pedis. *Br J Dermatol.* 2009;161(4):746-9.

9. Laporte M, André J, Stouffs-Vanhoof F, Achten G. Nail changes in alopecia areata: light and electron microscopy. *Arch Dermatol Res.* 1988;280 Suppl:S85-9.
10. Miteva M, de Farias DC, Zaiac M, Romanelli P, Tosti A. Nail clipping diagnosis of onychomatricoma. *Arch Dermatol.* 2011;147(9):1117-8.
11. Ackerman AB, Böer A, Bennin B, Gottlieb GJ. Embryologic, histologic, and anatomic aspects of the nail. In: *Histologic Diagnosis of Inflammatory Skin Diseases. An Algorithmic Method Based on Pattern Analysis.* 3rd ed. New York: Ardor Scribendi, Ltd., 2005. Available at: <http://www.derm101.com>.
12. Baran R. The nail in the elderly. *Clin Dermatol.* 2011;29(1):54-60.
13. Magalhães MG, Succi ICB, Sousa MAJ. Subsídios para estudo histopatológico das lesões ungueais. *An Bras Dermatol.* 2003;78:49-61.
14. Parent D, Achten G, Stouffs-Vanhoof F. Ultrastructure of the normal human nail. *Am J Dermatopathol.* 1985;7(6):529-35.
15. Yaemsiri S, Hou N, Slining MM, He K. Growth rate of human fingernails and toenails in healthy American young adults. *J Eur Acad Dermatol Venereol.* 2010;24(4):420-3.
16. Mondragon G. Histotechnologist to histopathologist: a method for processing specimens of nails. *Dermatopathology: Practical Conceptual.* 1996;2:41-2.
17. Fillus Neto J, Tchornobay AM. How the nail clipping helps the dermatologist. *An Bras Dermatol.* 2009;84(2):173-6.