

# Percutaneous antegrade nailing with reductor-T tape pin is effective and well tolerated in patients with ipsilateral multisegmental femoral shaft fractures

Wei Wang, Jianning Liu, Zhiyong Li, Guohui Xu, Rongling Wei, Xu Li and Xiangbei Qi 

## Abstract

**Objective:** This study was performed to investigate the efficacy and safety of percutaneous antegrade nailing with a reductor-T tape pin in the treatment of ipsilateral multisegmental femoral shaft fractures (IMFSFs).

**Methods:** Nineteen patients with IMFSFs underwent antegrade nailing with a reductor-T tape pin by percutaneous techniques. The operation time, reduction time, fluoroscopy time, blood loss, fracture union time, and complications were recorded.

**Results:** All 19 patients (100%) achieved technical success. The mean and median operation time were  $62.42 \pm 16.27$  and 60 (range, 40–105) minutes, respectively; the mean and median reduction time were  $11.47 \pm 3.78$  and 10 (range, 8–22) minutes, respectively; the mean and median fluoroscopy time were  $16.63 \pm 6.10$  and 15 (range, 10–35) s, respectively; and the mean and median blood loss were  $185.26 \pm 62.75$  and 180 (range, 110–350) mL, respectively. Additionally, all 19 patients (100%) achieved fracture union within a mean and median time of  $3.95 \pm 1.75$  and 3 (range, 3–9) months, respectively; most patients [ $n=14$  (73.7%)] achieved fracture union within 3 months. No obvious complications occurred during the study.

**Conclusion:** Antegrade nailing with a reductor-T tape pin by a percutaneous technique is effective and well tolerated in patients with IMFSFs.

---

Department of Orthopedics, Xiangjiang Area of The Third Hospital of Hebei Medical University, Shijiazhuang, China

---

## Corresponding author:

Xiangbei Qi, Department of Orthopedics, Xiangjiang Area of The Third Hospital of Hebei Medical University, 68 Xiangjiang Road, Shijiazhuang 050000, China.  
Email: qixiangbei@163.com



## Keywords

Ipsilateral multisegmental femoral shaft fracture, closed reduction, reductor-T tape pin, intramedullary nail, antegrade nailing, percutaneous technique

Date received: 20 February 2019; accepted: 28 May 2019

## Introduction

Treatment of ipsilateral multisegmental femoral shaft fractures (IMFSFs) is a great challenge despite advancements in modern medical care. IMFSFs are rare complex fractures accounting for approximately 0.31% of all fractures in adults.<sup>1</sup> Closed reduction and intramedullary nailing are considered the most common treatments for adult femoral shaft fractures. However, some patients do not achieve anatomical reduction with closed treatment, and the treatment effectiveness is sometimes unsustainable during subsequent implanting procedures, even with the assistance of a traction table; this is especially true for patients with IMFSFs.<sup>2-6</sup> Thus, the exploration of novel treatment options to resolve this critical issue is of great importance.

Complex femoral shaft fractures, including IMFSFs, are often characterized by difficulties in inserting the guide wire into the distal medullary cavity from the proximal medullary cavity passing the fracture site. Open reduction is recommended to overcome this issue; however, open reduction is associated with a lower union rate and higher infection rate in some cases.<sup>7-9</sup> Therefore, to address this problem and achieve closed reduction, we designed the reductor-T tape pin, an intramedullary reduction device that facilitates relatively easy and appropriate insertion of guide wires. The present study was performed to investigate the efficacy and safety of antegrade nailing with the assistance of this

novel intramedullary reduction device by a percutaneous technique in patients with IMFSFs.

## Methods

### *Patients*

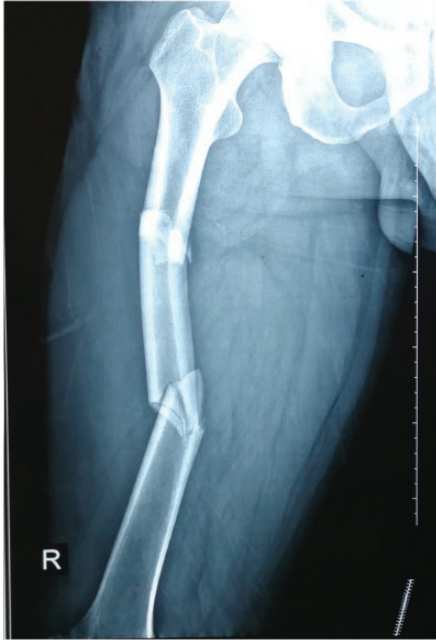This study involved consecutive patients with IMFSFs who underwent antegrade nailing with our novel intramedullary reduction device (reductor-T tape pin) by percutaneous techniques from January 2013 to December 2015 at our hospital. The inclusion criteria were a diagnosis of IMFSF by imaging examination (Figure 1 shows a representative image of a patient with IMFSF), age of >18 years, and performance of antegrade nailing with the reductor-T tape pin by a percutaneous technique. The exclusion criteria were open fractures, pathological fractures of the femoral shaft, and an inability to be regularly followed up.

### *Ethics approval*

This study was approved by the ethics committee of our hospital and conducted under the guidelines of the Declaration of Helsinki. All patients or their family members provided written informed consent.

### *Description of reductor-T tape pin*

The reductor-T tape pin is primarily composed of a screw head, connecting rod, and T tape handle (Figure 2). The diameter of



**Figure 1.** Representative image of IMFSFs. This image was obtained from a 36-year-old man with IMFSFs caused by a traffic accident. IMFSFs, ipsilateral multisegmental femoral shaft fractures.



**Figure 2.** Image of reductor-T tape pin.

the screw head gradually increases from 4.5 mm at the beginning to 6.0 mm at the end with a 3.0-cm length. The screw head can be fixed to the unilateral cortical bone of the femoral shaft, and the surgeon can grasp the connecting rod and T tape handle to control the fracture site by the “joystick technique.”

### *Surgical procedures*

All operations were performed 2 to 5 days after the initial injury, and the IMFSFs were treated by antegrade nailing with the assistance of the reductor-T tape pin by a percutaneous technique as follows. The patient was first placed on the traction table in the supine position under epidural anesthesia, and the relative shift of both fracture ends was observed under C-arm fluoroscopy. The skin was then prepared and sterilized, and the tip of the greater trochanter was selected as the entry point of the intramedullary nail. The skin was incised to expose the entry point of the nail, and a guide pin was inserted to the tip of the trochanter. A sleeve was then passed down to the starting point along the guide pin, and the proximal femur was opened with an opening reamer. The fractures were initially reduced by traction on the traction table, and several 0.5-cm stab incisions were then made laterally in the thigh about 3 to 5 cm from both sides of the fractures. A soft tissue separator (Figure 3) was inserted from the small stab incision to the bone, and the unilateral cortex of the femoral shaft was drilled through the sleeve using a drill with a diameter of 4.2 mm. The reductor-T tape pin was subsequently screwed to the unilateral cortical bone of the femoral shaft, and the residual displacement was aligned by the reductor-T tape pin with double “joystick technique.” While the fracture reduction was maintained, the guide wire was inserted from the proximal to distal femoral



**Figure 3.** Image of soft tissue separator.

medullary canal (Figure 4), and a series of flexible reamers was used to increase the diameter of the femoral medullary canal while the reductor-T tape pin controlled the intermediate fracture fragment. Finally, the intramedullary nail was inserted along the guide wire to fix the displaced femoral shaft fractures (Figure 5) (the selected nail was 1 mm smaller in diameter than the last reamer). Fluoroscopy was conducted during the operation to monitor the procedure.

### ***Postoperative management and follow-up***

Isometric quadriceps exercises were performed on day 1 postoperatively, crutch-assisted walking without weight-bearing was conducted from day 2 to week 6, and crutch-assisted walking with partial weight-bearing was conducted from week 6 until fracture union; walking with full weight-bearing was allowed thereafter. Fracture union was defined as callus bridging of the fracture site as shown on serial radiographs. Patients were regularly followed up once

per month during the first 3 months, once every 3 months during the following 6 months, and once every 6 months thereafter. A radiological and clinical evaluation was performed at each visit. The median follow-up duration was 24 months (range, 18–30 months), and the last follow-up date was 31 December 2017.

### ***Data collection***

Age, sex, causes of IMFSFs, operation time, reduction time, fluoroscopy time, blood loss, fracture union time, and complications were recorded in this study.

### ***Statistics***

The statistical analysis was mainly conducted using SPSS 22.0 software (IBM Corp., Armonk, NY, USA). Data are mainly presented as mean  $\pm$  standard deviation, median (range), or count (percentage). Descriptive data analysis was mainly applied in this study.

## **Results**

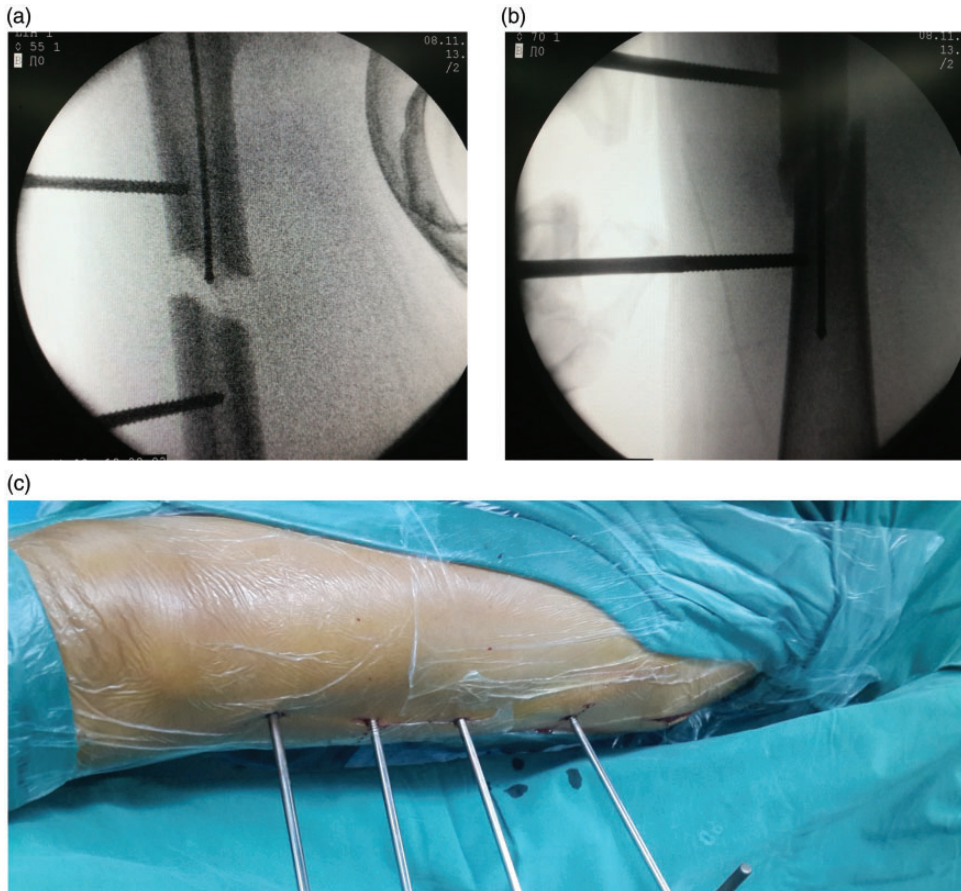
### ***Baseline characteristics***

Nineteen patients with IMFSFs were included in this study. The mean age of the patients was  $37.37 \pm 16.93$  years, and they comprised 16 (84.2%) males and 3 (15.8%) females (Table 1). According to the AO/OTA classification, all fracture patterns were type 32-C2 (100.0%). Twelve (63.2%) patients' fractures were caused by a traffic accident, while seven (36.8%) were caused by falling from a height. The detailed characteristics of each patient are shown in Table 2.

### ***Operative indexes and treatment outcomes***

All patients (100%) achieved technical success by antegrade nailing with the assistance





**Figure 4.** Fracture reduction by reductor-T tape pin. IMFSFs were reduced using the reductor-T tape pin by traction via a fracture table. (a) Image of a proximal displacement fracture. (b) Image of a distal displacement fracture. (c) Image of operation. IMFSFs, ipsilateral multisegmental femoral shaft fractures.

of the reductor-T tape pin via a percutaneous technique. Table 3 shows the mean and median operation time, reduction time, fluoroscopy time, and blood loss. All 19 patients (100%) achieved fracture union within a mean and median time of  $3.95 \pm 1.75$  and 3 (range, 3–9) months, respectively; most patients [14 (73.7%)] achieved fracture union within 3 months.

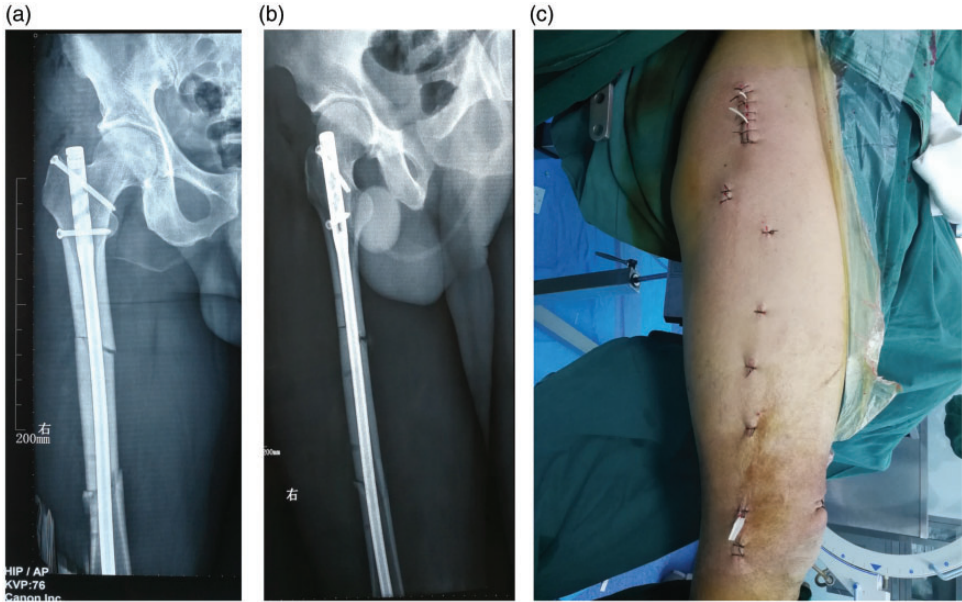
### Complications

No wound infection, limitation of knee or hip function, or nail loosening or breakage

was observed during the study. Additionally, no patients had obvious valgus or varus deformity, leg length discrepancy of  $>1$  cm, or anterior superior iliac spine–patellar midpoint–second metatarsal malalignment.

### Discussion

In the present study, we designed a reductor-T tape pin as an intramedullary reduction device and observed that antegrade nailing with the assistance of the reductor-T tape pin by a percutaneous



**Figure 5.** Successful fixation by antegrade nailing using reductor-T tape pin. (a) Anteroposterior view of successful fixation. (b) Lateral view of successful fixation. (c) Intraoperative skin incision.

**Table 1.** Characteristics of patients with ipsilateral multisegmental femoral shaft fractures

Parameters	Patients (n = 19)
Age (years)	37.37 ± 16.93
Sex	
Male	16 (84.2)
Female	3 (15.8)
AO/OTA type	
32-C2	19 (100.0)
Cause of fractures	
Traffic accident	12 (63.2)
Falling from height	7 (36.8)

Data are presented as mean ± standard deviation or n (%).

technique was effective and well tolerated in patients with IMFSFs with a 100% technical success rate and 100% fracture union rate.

IMFSFs are often caused by high-velocity or high-energy trauma and are a rare type of femoral shaft fracture that occur in patients in severe clinical condition. Increasing numbers of studies are revealing

that closed reduction with intramedullary nailing fixation is effective in the treatment of adult femoral shaft fractures.<sup>4-6,10</sup> However, several problems or difficulties are encountered in the treatment of some complex femoral shaft fractures, especially IMFSFs. First, the guide wire must be inserted into the distal medullary cavity from the proximal cavity and must pass the fracture site before the intramedullary nail is implanted; however, the powerful deforming and shortening forces of the quadriceps with traction provided by a traction table are difficult to overcome.<sup>11</sup> Additionally, heavy traction can lead to nerve and skin injury, including stretch wound of the foot, pudendal nerve trauma, perineal ulcers, peroneal nerve palsy, and compartment syndrome.<sup>12-18</sup> Although some surgeons propose that open reduction may eliminate these concerns, such treatment is often correlate with relatively low fracture union efficacy and a high infection rate.<sup>7-9</sup> Second, reaming, which is applied to enlarge the

**Table 2.** Detailed information of patients with ipsilateral multisegmental femoral shaft fractures

Patient No.	Sex	Age (years)	Cause of fractures	Operation time (minutes)	Reduction time (minutes)	Fluoroscopy time (s)	Blood loss (mL)	Fracture union time (months)
1	Male	21	Traffic accident	105	22	35	350	6
2	Male	47	Traffic accident	90	18	29	300	3
3	Male	23	Fall from height	80	15	21	260	3
4	Male	52	Traffic accident	72	12	15	200	3
5	Female	55	Fall from height	65	10	13	180	6
6	Male	26	Traffic accident	58	9	14	150	3
7	Male	26	Traffic accident	55	8	13	130	3
8	Male	22	Traffic accident	50	10	14	110	3
9	Male	35	Fall from height	46	8	12	150	3
10	Male	65	Fall from height	45	9	13	130	6
11	Male	36	Traffic accident	40	8	10	110	3
12	Male	51	Fall from height	46	10	13	140	3
13	Male	29	Traffic accident	56	12	18	200	9
14	Female	67	Traffic accident	65	15	16	200	3
15	Male	20	Traffic accident	71	13	17	150	3
16	Male	65	Fall from height	54	10	12	180	6
17	Male	21	Traffic accident	60	8	16	170	3
18	Male	24	Traffic accident	62	9	17	200	3
19	Female	25	Fall from height	66	12	18	210	3

**Table 3.** Operative data and outcomes

Parameters	Mean value	Median value
Operation time (minutes)	62.42 ± 16.27	60 (40–105)
Reduction time (minutes)	11.47 ± 3.78	10 (8–22)
Fluoroscopy time (s)	16.63 ± 6.10	15 (10–35)
Blood loss (mL)	185.26 ± 62.75	180 (110–350)
Fracture union time (months)	3.95 ± 1.75	3 (3–9)

Data are presented as mean ± standard deviation or median (range).

diameter of the femoral shaft before implanting the intramedullary nail, can result in floating intermediate fragments that might cause soft tissue injury and blood vessel lesions.<sup>19–21</sup>

We have also observed the abovementioned problems in treating patients with IMFSFs in our clinical practice. Therefore, to attenuate or even resolve these issues, we designed the reductor-T tape pin as a novel intramedullary

reduction device and explored the efficacy and safety of antegrade nailing with this device via a percutaneous technique in patients with IMFSFs. In this study, we used the reductor-T tape pin to percutaneously reduce the residual displacement after traction using a traction table with double “joystick technique” and facilitated insertion of the guide wire into the femoral medullary cavity, which was the key procedure of the intramedullary nailing technique.

All patients achieved technical success, and the reductor-T tape pin produced rapid, close fracture reduction with a mean and median reduction time of  $11.47 \pm 3.78$  and 10 (range, 8–22) minutes, respectively, as shown on the anteroposterior and lateral fluoroscopic views using the C-arm. Additionally, the application of small stab incisions during the operation avoided the need to open the fracture site and strip the soft tissue envelope, which protected the soft tissue envelope and blood supply of the fracture site and decreased the operation time and exposure to X-rays. Moreover, the screw head of the reductor-T tape pin also improved the control of floating intermediate fragments during reaming, which attenuated the soft tissue and blood vessel injuries. These advantages of the reductor-T tape pin led to a technical success rate of 100% and a mean and median fracture union time of  $3.95 \pm 1.75$  and 3 (range, 3–9) months, respectively. Because percutaneous antegrade nailing with the reductor-T tape pin is a novel method of treating IMFSFs, the indications for the procedure were restricted in our study, and some patients were excluded (such as those with no origin of force to hold the reductor-T tape pin). Thus, the procedure had high technical success.

Several complications might occur during antegrade nailing with the assistance of the reductor-T tape pin by a percutaneous technique, such as infection, heterotopic ossification, obvious valgus or varus deformity, new iatrogenic fracture and fibrosis, quadriceps contracture, or obvious leg length discrepancy. Notably, none of these complications occurred in the present study, indicating that the reductor-T tape pin was well tolerated.

This study had several limitations. First, this was a pilot study with a relatively small sample; thus, the efficacy and safety of percutaneous antegrade nailing with the reductor-T tape pin in treating IMFSFs

requires further validation in a randomized controlled study with a larger sample. Second, this was a single-arm study, and a further study including more centers is needed. Third, the long-term recovery outcomes need to be further validated in the future.

In conclusion, antegrade nailing with the reductor-T tape pin by a percutaneous technique is effective and well tolerated in patients with IMFSFs.

### Disclosure of conflict of interest

The authors declare that there is no conflict of interest.

### Funding

This research received no specific grant from any funding agency in the public, commercial, or not-for-profit sectors.

### ORCID iD

Xiangbei Qi  <https://orcid.org/0000-0002-3537-303X>

### References

1. Zhang Y. *Clinical epidemiology of orthopaedic trauma*. 2nd ed. New York: Thieme, 2012.
2. Bohler J. Closed intramedullary nailing of the femur. *Clin Orthop Relat Res* 1968; 60: 51–67.
3. Kempf I, Grosse A and Beck G. Closed locked intramedullary nailing. Its application to comminuted fractures of the femur. *J Bone Joint Surg Am* 1985; 67: 709–720.
4. Yang KH, Han DY, Jahng JS, et al. Prevention of malrotation deformity in femoral shaft fracture. *J Orthop Trauma* 1998; 12: 558–562.
5. Bonneville P, Laques D, Fabre G, et al. [Femoral shaft fractures in the elderly treated by intramedullary nailing]. *Rev Chir Orthop Reparatrice Appar Mot* 2002; 88: 41–50.



6. Pfister U. [Reamed intramedullary nailing]. *Orthopade* 2010; 39: 171–181. DOI: 10.1007/s00132-009-1522-7.
7. Chapman MW. The role of intramedullary fixation in open fractures. *Clin Orthop Relat Res* 1986; (212): 26–34.
8. Whittaker RP, Heppenstall B, Menkowitz E, et al. Comparison of open vs. closed rodding of femurs utilizing a Sampson rod. *J Trauma* 1982; 22: 461–468.
9. Whittle AP. Fractures of the lower extremity. In: Canale ST (ed.) *Campbell's operative orthopaedics*. 9th ed. St Louis: Mosby-Year Book, 1998, p.2143.
10. Taitsman LA, Lynch JR, Agel J, et al. Risk factors for femoral nonunion after femoral shaft fracture. *J Trauma* 2009; 67: 1389–1392. DOI: 10.1097/TA.0b013e318182afd0.
11. Rhorer AS. Percutaneous/minimally invasive techniques in treatment of femoral shaft fractures with an intramedullary nail. *J Orthop Trauma* 2009; 23: S2–S5. DOI: 10.1097/BOT.0b013e31819f2569.
12. Madhu T and Dunsmuir R. Sensory neuropathia of the foot after leg traction on fracture table. *Injury Extra* 2005; 36: 306–307.
13. Topliss CJ and Webb JM. Interface pressure produced by the traction post on a standard orthopaedic table. *Injury* 2001; 32: 689–691.
14. Gibson RJ. Erectile dysfunction induced by orthopedic trauma managed with a fracture table. *J Trauma* 2000; 48: 576.
15. Carlson DA, Dobozi WR and Rabin S. Peroneal nerve palsy and compartment syndrome in bilateral femoral fractures. *Clin Orthop Relat Res* 1995; (320): 115–118.
16. Soulie M, Vazzoler N, Seguin P, et al. [Urological consequences of pudendal nerve trauma during orthopedic surgery: review and practical advice]. *Prog Urol* 2002; 12: 504–509.
17. Lyon T, Koval KJ, Kummer F, et al. Pudendal nerve palsy induced by fracture table. *Orthop Rev* 1993; 22: 521–525.
18. Wu CS, Chen PY, Shih KS, et al. Modified patient position on a fracture table for hip fixation. *Orthopedics* 2007; 30: 518–520.
19. Reynders PA and Broos PL. Healing of closed femoral shaft fractures treated with the AO unreamed femoral nail. A comparative study with the AO reamed femoral nail. *Injury* 2000; 31: 367–371.
20. Duan X, Li T, Mohammed AQ, et al. Reamed intramedullary nailing versus unreamed intramedullary nailing for shaft fracture of femur: a systematic literature review. *Arch Orthop Trauma Surg* 2011; 131: 1445–1452. DOI: 10.1007/s00402-011-1311-8.
21. Lin SH, Lo CW, Cheng SC, et al. Use of reconstruction nails to manage ipsilateral displaced femoral neck-shaft fractures: assessment of a new approach. *J Orthop Surg (Hong Kong)* 2002; 10: 185–193. DOI: 10.1177/230949900201000214.