

Available online at www.sciencedirect.com

ScienceDirect

journal homepage: www.elsevier.com/locate/radcr

Case Report

Endovascular treatment for iatrogenic rupture of an iliac artery with severe tortuosity[☆]

Masahiro Koide, M.D.^{*}, Kento Fukui, M.D., Koji Sogabe, M.D., Tatsuya Kitada, M.D., Masaya Kogure, M.D., Yukinori Kato, M.D., Hiroki Kitajima, M.D., Satoshi Akabame, M.D.

Department of Cardiovascular Medicine, Kyoto Okamoto Memorial Hospital, 100, Nishinokuchi, Sayama, Kumiyama, Kyoto 613-0034, Japan

ARTICLE INFO

Article history:

Received 24 May 2020

Revised 1 June 2020

Accepted 2 June 2020

Keywords:

Retroperitoneal hemorrhage
Hemorrhage complication
Balloon-expandable stent graft
Self-expandable stent graft
Bowstring phenomenon
Accordion phenomenon

ABSTRACT

Retroperitoneal hemorrhage due to iatrogenic rupture of the iliac artery is a life-threatening complication associated with endovascular intervention. We present a case of iatrogenic iliac rupture after insertion of a sheath into a severely tortuous iliac artery during coil embolization of a cerebral aneurysm. Bleeding was controlled by resuscitative endovascular balloon occlusion of the aorta followed by placement of a balloon-expandable stent graft into the iliac artery. This resulted in complete repair of the ruptured iliac artery. The patient recovered without any neurological complications.

© 2020 The Authors. Published by Elsevier Inc. on behalf of University of Washington.

This is an open access article under the CC BY-NC-ND license.

(<http://creativecommons.org/licenses/by-nc-nd/4.0/>)

Introduction

Iatrogenic rupture of the iliac artery is a serious complication of endovascular intervention that can result in systemic shock due to retroperitoneal hemorrhage and is associated with a high rate of mortality (12%–19%) and longer hospital stays [1,2]. With the development of aortic endovascular intervention and transcatheter aortic valve implantation, there are an increasing number of procedures that involve passing a large-diameter sheath or device through the iliac artery; this

has resulted in an increased incidence of iliac rupture [3,4]. Although percutaneous coronary intervention with a small-diameter sheath results in retroperitoneal hematoma due to iliac artery injury in only 0.49%–0.74% of cases, most of these are hemorrhagic complications at the puncture site associated with high femoral artery puncture [5,6]. Iatrogenic iliac rupture caused by insertion of a small-diameter sheath in the middle portion of the iliac artery is extremely rare. We present a case of iatrogenic rupture of severely tortuous iliac artery during coil embolization of a cerebrovascular aneurysm.

[☆] Declaration of Competing of interests: Authors have no conflict of interest to disclose.

^{*} Corresponding author.

E-mail address: koide@koto.kpu-m.ac.jp (M. Koide).

<https://doi.org/10.1016/j.radcr.2020.06.011>

1930-0433/© 2020 The Authors. Published by Elsevier Inc. on behalf of University of Washington. This is an open access article under the CC BY-NC-ND license. (<http://creativecommons.org/licenses/by-nc-nd/4.0/>)

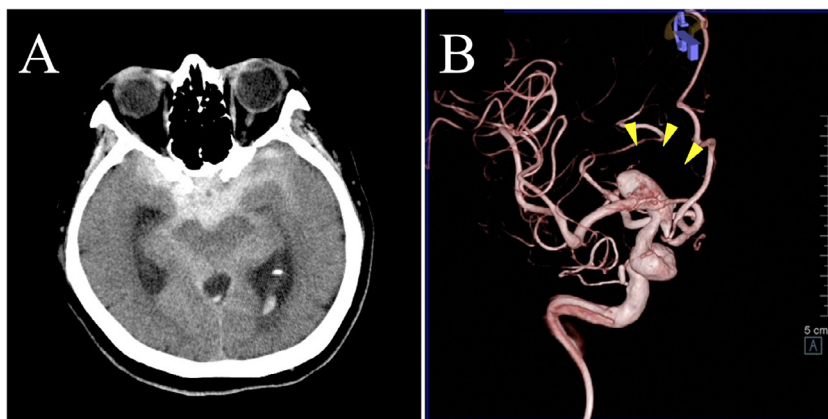


Fig. 1 – Head CT on admission revealed a subarachnoid hemorrhage (A) due to rupture of cerebral aneurysm (B).

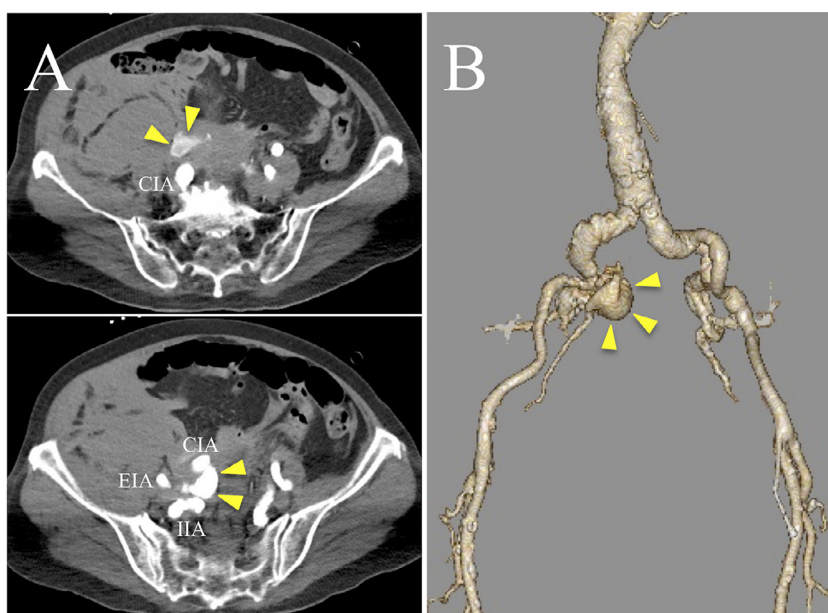


Fig. 2 – Emergency contrast CT performed to diagnose hemodynamic instability after coil embolization revealed a severe retroperitoneal hemorrhage due to extravasation from the right iliac artery (A). The 3-dimensional CT angiography revealed the high degree of tortuosity at the site of bleeding in the right iliac artery (B).

Case Report

An 80-year-old female presented to our hospital with a chief complaint of disturbance of consciousness. She underwent emergency head computed tomography (CT), which revealed a subarachnoid hemorrhage due to rupture of a cerebral aneurysm (Fig. 1A and B). The following day, coil embolization for the ruptured cerebral aneurysm was performed by a neurosurgeon. The operation proceeded uneventfully and included an 8-Fr long sheath introduced into the right femoral artery. After removal of the sheath, the patient's blood pressure dropped suddenly; hemodynamics remained unstable despite copious fluid replacement and intravenous administration of dopamine. Emergency abdominal CT revealed a severe retroperitoneal hemorrhage due to massive bleeding

from the right iliac artery (Fig. 2, Movie 1). The cardiology team was consulted for emergency associated with hemostasis and treatment. The patient arrived in the catheterization laboratory in severe shock despite being treated with a rapid transfusion of red blood cells and albumin. Laboratory values included a hemoglobin level at 3.5 mg/dl and a hematocrit of 10%. As a first step, a 7-Fr sheath was inserted into the contralateral left femoral artery to facilitate resuscitative endovascular balloon occlusion of the aorta (REBOA, Rescue Balloon; Tokai Medical Products, Kasugai, Japan); insertion of the catheter followed by dilation at the distal end of the abdominal aorta successfully blocked aortic blood flow (Fig. 3A) and resulted in hemodynamic stabilization. Subsequently, the right femoral artery was punctured under ultrasound guidance and a 7-Fr short sheath was inserted into the right iliac artery. Angiography revealed extravasation of contrast dye

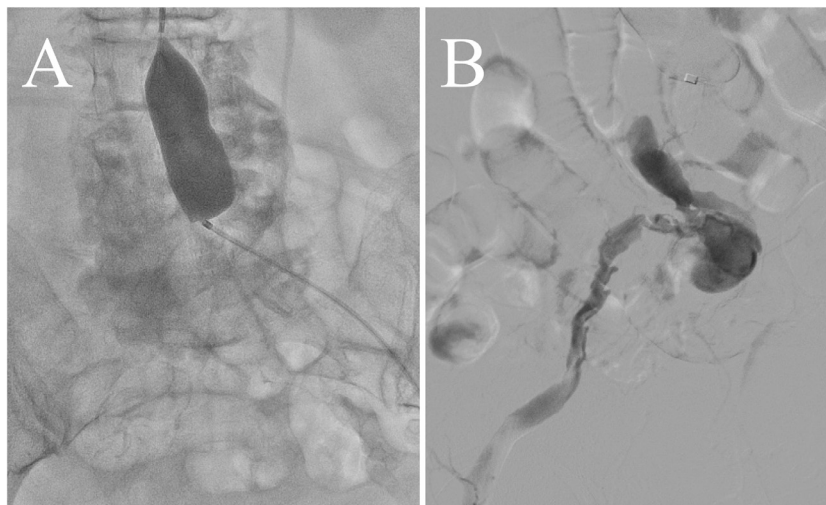


Fig. 3 – Blockade of aortic blood flow with REBOA catheter dilated at the distal end of the abdominal aorta (A). Angiography revealed extravasation from the right iliac artery (B).

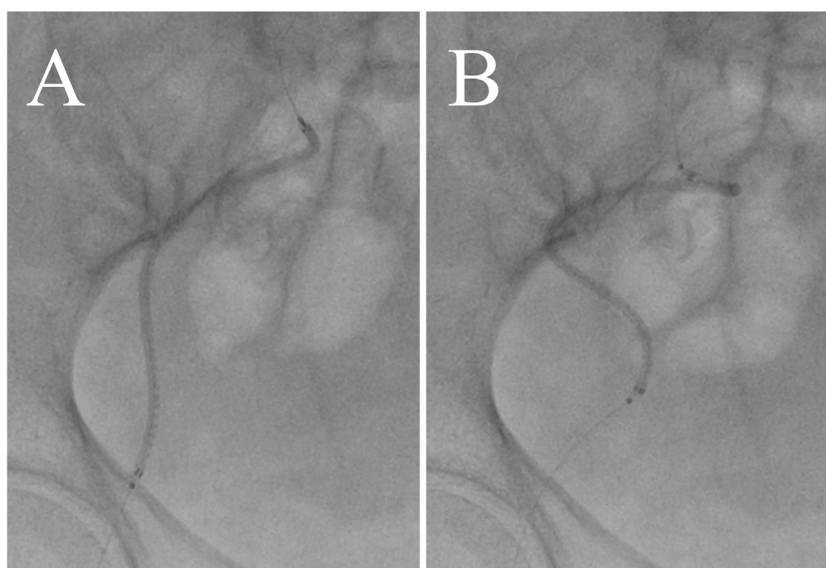


Fig. 4 – The bowstring phenomenon associated with deployment of the Viabahn stent graft. Viabahn stent graft prior to (A) and during deployment (B).

from the right iliac artery (Fig. 3B), most likely due to injury of the iliac artery during sheath insertion for the coil embolization procedure. After passing a nonstiff guidewire (Treasure Floppy; Asahi Intec, Nagoya, Japan), a Viabahn stent graft (WL Gore and Associates, Flagstaff, AZ) was delivered to the lesion; however, it was difficult to deploy the stent graft due to a severe bowstring phenomenon (Fig. 4, Movie 2). Therefore, we changed to a 0.035-inch stiff wire; a balloon-expandable stent graft (Viabahn VBX 8.0/59 mm; WL Gore and Associates, Flagstaff, AZ) was deployed to repair the ruptured iliac artery (Fig. 5A). Intravascular ultrasound showed stent malapposition at the proximal end of the Viabahn VBX, so dilation with a 12.0-mm balloon was added (Fig. 5B). Angiography confirmed the complete block of dye extravasation at the affected site

(Fig. 5C, Movie 3). The procedure resulted in hemodynamic stabilization; 9 days later, the patient was transferred to the rehabilitation ward. A CT scan performed 3 weeks later confirmed that ruptured iliac artery had been fully repaired (Fig. 6). After rehabilitation, she was discharged to her home with no neurological complications.

Discussion

Retroperitoneal hemorrhage due to iatrogenic rupture of the iliac artery is a life-threatening complication associated with endovascular intervention. Several anatomical predictors re-

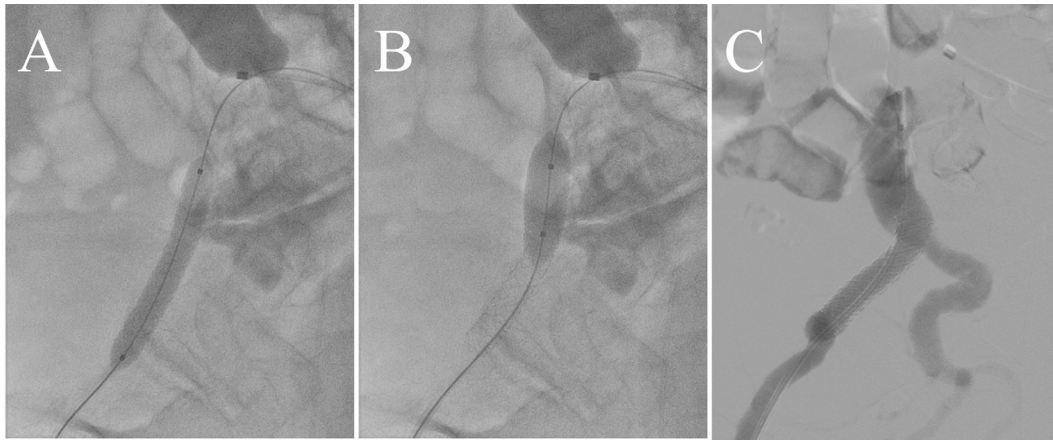


Fig. 5 – The balloon-expandable stent graft, Viabahn VBX of 8.0/59 mm, was deployed which covered the ruptured iliac artery (A) followed postdilatation with a 12.0-mm balloon (B). Final angiography confirmed the complete cessation of extravasation (C).

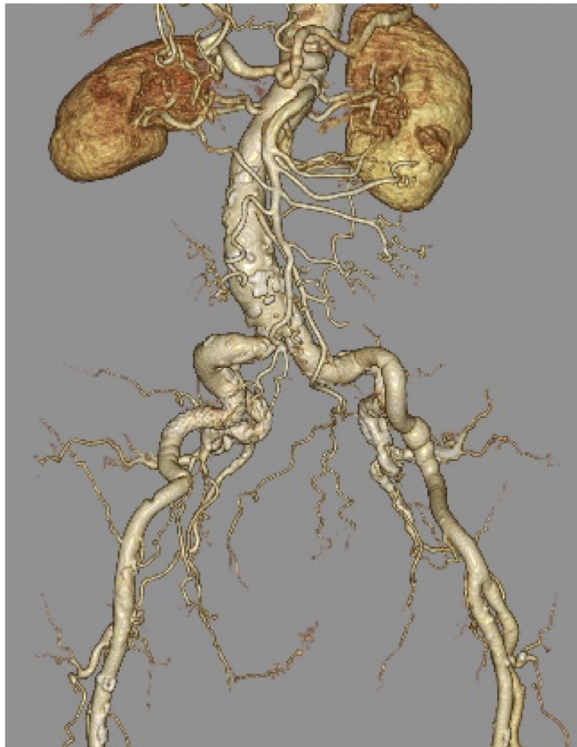


Fig. 6 – CT performed 3 weeks after admission revealed complete repair of ruptured iliac artery.

ported to be associated with a higher risk of iatrogenic rupture of the iliac artery include vessel tortuosity, calcification and insertion of disproportionately large-size sheath relative to vessel diameter. In this case, we identified a severe bend at an angle of 124 at rupture site (Fig. 7); this led to injury of the iliac artery despite the fact that we inserted a small-diameter sheath and the iliac artery had no prominent calcifications.

Although no hemodynamic instability suggestive of iliac artery rupture was detected during the coil embolization pro-

cedure, sudden hemodynamic deterioration was observed immediately after the sheath was removed. This sequence of events might relate to reversible vascular obstruction secondary to straightening of vessel tortuosity, otherwise known as the accordion phenomenon [7–9]. Even if the iliac artery was already seriously damaged when the sheath was inserted, it is possible that insertion of a long sheath into the tortuous iliac artery resulted in an accordion phenomenon which may have limited bleeding during the procedure. As such, removal of the sheath after the procedure released the accordion folds and opened up the iliac artery rupture, resulting in retroperitoneal hemorrhage.

Prompt hemostasis is the most important action to take in the case of an iliac artery rupture; there is a long history of open surgical repair performed for iatrogenic vascular injuries of this type [10,11]. However, patients requiring this type of emergency surgical repair typically have numerous comorbidities and unstable conditions; as such, open repair is likely to result in secondary complications, including poor wound healing and postoperative infection. In recent years, endovascular stent grafts have become important alternatives to surgical repair [12]. If rupture of the iliac artery is recognized prior to removal of the sheath, balloon tamponade followed by deployment of a stent graft at the rupture site could provide immediate hemostasis. However, in this case, the rupture was identified only after removal of the sheath and after hemodynamics had already undergone significant deterioration. Therefore, in this case, it was necessary to stabilize the patient via blockage of aortic blood flow with a REBOA catheter; this was followed by placement of a stent graft within the ruptured vessel.

We initially tried to place a self-expandable stent graft (Viabahn); however, this resulted in a severe bowstring phenomenon which precluded its deployment. This phenomenon was caused by the unique structure of Viabahn stent graft which is constrained around a delivery catheter and is released and deployed from the tip toward the hub by pulling a suture. If the stent graft is placed in severely tortuous portion of an artery, pulling the suture makes the delivery catheter to

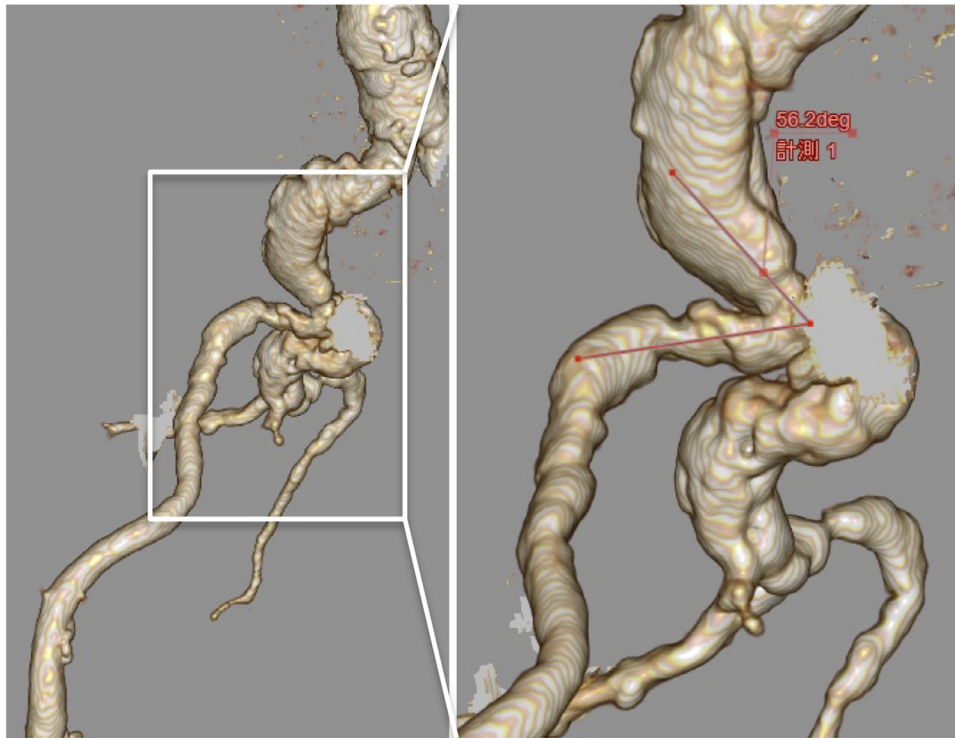


Fig. 7 – The 3-dimensional CT angiography showed a severe bend of 124 degrees at the rupture site.

bow towards the suture, known as the bowstring phenomenon [13,14]. In this case, the severe tortuosity of the right iliac artery and the use of a nonstiff guidewire facilitated the bowstring response. A few cases of severe bowstring phenomenon have been reported that were observed during the deployment of Viabahn stent graft within tortuous vessels; this has been observed even when stiff guidewires were used [13,14]. The sheath-covering technique, which alternates short deployment of the stent and short pullback of the sheath, was found to be effective in 1 case that described its use in a tortuous vessel [13]. However, deep insertion of the sheath into a tortuous vessel can result in further vessel damage. The balloon-expandable stent grafts might be effective for repairing vascular damage in such highly tortuous vessels, as shown here.

In conclusion, we present a rare case of iatrogenic rupture of severely tortuous iliac artery during coil embolization of a cerebrovascular aneurysm. Bleeding was controlled with a REBOA catheter followed by placement of a stent graft that resulted in fully successful and complete repair of the iliac artery lesion. Our case report demonstrates clearly that even in a situation where the sheath was removed after iliac artery rupture and hemodynamics was extremely unstable, it is still possible to intervene successfully by using REBOA catheter followed by a balloon-expandable stent graft.

Funding

None.

Informed consent

Informed consent was obtained from the patient prior to inclusion in this case report.

Supplementary materials

Supplementary material associated with this article can be found, in the online version, at doi:10.1016/j.radcr.2020.06.011.

REFERENCES

- [1] Shah SK, Parodi FE, Eagleton MJ, Bena JF, Clair DG. Iliac injury during abdominal and thoracic aortic endovascular intervention. *J Vasc Surg.* 2016;64(3):726–30.
- [2] Fernandez JD, Craig JM, Garrett HE Jr, Burgar SR, Bush AJ. Endovascular management of iliac rupture during endovascular aneurysm repair. *J Vasc Surg.* 2009;50(6):1293–300.
- [3] Hayashida K, Lefèvre T, Chevalier B, Hovasse T, Romano M, Garot P, et al. Transfemoral aortic valve implantation new criteria to predict vascular complications. *JACC Cardiovasc Interv.* 2011;4(8):851–8.
- [4] Feezor RJ, Huber TS, Martin TD, Beaver TM, Hess PJ, Klodell CT, et al. Perioperative differences between endovascular repair of thoracic and abdominal aortic diseases. *J Vasc Surg.* 2007;45(1):86–9.
- [5] Tiroch KA, Arora N, Matheny ME, Liu C, Lee TC, Resnic FS. Risk predictors of retroperitoneal hemorrhage following percutaneous coronary intervention. *Am J Cardiol.* 2008;102(11):1473–6.

- [6] Farouque HM, Tremmel JA, Raissi Shabari F, Aggarwal M, Fearon WF, Ng MK, et al. Risk factors for the development of retroperitoneal hematoma after percutaneous coronary intervention in the era of glycoprotein 2b/3a inhibitors and vascular closure devices. *J Am Coll Cardiol*. 2005;45(3):363–8.
- [7] Joseph D, Idris M. Catheter-induced “accordion effect” in tortuous right external iliac artery during peripheral angiography. *Cathet Cardiovasc Diagn*. 1995;34(4):318–20.
- [8] Trani C, Biondi-Zoccai GG, Burzotta F, Todaro D, Romagnoli E, Abbate A, et al. Catheter-induced straightening of external iliac tortuosity: a cause of pseudostenosis to be borne in mind. *Int J Cardiol*. 2005;101(2):333–4.
- [9] Dawson DL, Hellinger JC, Terramani TT, Najibi S, Martin LG, Lumsden AB. Iliac artery kinking with endovascular therapies: technical considerations. *J Vasc Interv Radiol*. 2002;13(7):729–33.
- [10] May J, White GH, Yu W, Waugh RC, Stephen MS, McGahan T, et al. Surgical management of complications following endoluminal grafting of abdominal aortic aneurysms. *Eur J Vasc Endovasc Surg*. 1995;10(1):51–9.
- [11] Franco CD, Goldsmith J, Veith FJ, Calligaro KD, Gupta SK, Wengerter KR. Management of arterial injuries produced by percutaneous femoral procedures. *Surgery* 1993;113(4):419–25.
- [12] Duran C, Naoum JJ, Smolock CJ, Bavare CS, Patel MS, Anaya-Ayala JE, et al. A longitudinal view of improved management strategies and outcomes after iatrogenic iliac artery rupture during endovascular aneurysm repair. *Ann Vasc Surg*. 2013;27(1):1–7.
- [13] Yoshida R, Takagi K, Morita Y, Komeyama S, Morishima I. Squat and jump: a rare case of stent-graft migration during deployment. *Clin Med Insights Case Rep*. 2019;12 1179547619873919.
- [14] Miller MJ, Stirling MJ, Chang YH, Smith TP. Acute compartment syndrome related to stent-graft exclusion of a popliteal arterial aneurysm. *Semin Intervent Radiol*. 2007;24(3):307–11.