

## A Male Infant with Abetalipoproteinemia: A Case Report from Iran

Parisa Rashtian<sup>1</sup>, Mehri Najafi Sani<sup>1</sup>, Rozita Jalilian<sup>1\*</sup>

1. Department of Pediatric Gastroenterology, Children's Medical Center, Tehran university of Medical Sciences, Tehran, Iran

### ABSTRACT

Abetalipoproteinemia (ABL) is a very rare autosomal recessive disorder caused by mutations in the microsomal triglyceride transfer protein gene (MTTP). ABL is characterized by lack of lipids and apolipoprotein B (apoB) in plasma, fat malabsorption and various clinical manifestations. We describe a 12-month-old infant boy, born from consanguineous parents and presented with diarrhea, steatorrhea, growth retardation, hypothyroidism, intraventricular brain cyst and kidney stones. The patient was diagnosed to have ABL and treated with dietary modification and oral fat-soluble vitamin replacement and followed until he reached 5 years of age.

### KEYWORDS

Abetalipoproteinemia; Microsomal triglyceride transfer protein; Failure to thrive

Please cite this paper as:

Rashtian P, Najafi Sani M, Jalilian R. A Male Infant with Abetalipoproteinemia: A Case Report from Iran. *Middle East J Dig Dis* 2015;7:181-4.

### INTRODUCTION

Abetalipoproteinemia (ABL; OMIM 200100) is a very rare hereditary autosomal recessive metabolic disorder of fat and fat-soluble vitamins absorption, which is caused by microsomal triglyceride transfer protein (MTTP; OMIM 157147) deficiency and characterized by absence of plasma apolipoprotein B and (apo B)-containing lipoproteins.<sup>1,2</sup> MTTP is a chaperone protein found in enterocytes and hepatocytes endoplasmic reticulum (ER) and includes three structural domains (N-terminal  $\beta$ -barrel,  $\alpha$ -helix and C-terminal) and three functional domains (transfer activity, membrane interaction and lipid binding).

The molecular basis of this disorder is the inheritance of two mutations in MTTP gene which is located on chromosome 4q23 and encodes the large subunit of MTTP (a 97-KDa protein containing 894 amino acids) that forms a heterodimer with the endoplasmic reticulum enzyme protein disulfide isomerase (PDI) and accelerates the transfer of lipids onto apolipoprotein B, resulting in assembly and secretion of apo B in the formation of VLDL and chylomicrons in the liver and intestine respectively.<sup>3,4</sup>

The syndrome was first described by Bassen and Kornzweig in 1950.<sup>5</sup> According to the signs and absence of lipoproteins, Salt and colleagues named the disorder as "Abetalipoproteinemia" afterwards.<sup>6</sup>

Patients with ABL may show various clinical manifestations. Children are usually asymptomatic at birth but develop digestive symptoms

### \* Corresponding Author:

Rozita jalilian MD,  
Children's Medical Center Hospital, 62  
Qarib St., Keshavarz Blvd., Tehran 14194,  
Iran  
Tel: + 98 21 66428998  
Fax: + 98 21 66923054  
Email: Rozita\_jalilian@yahoo.com  
Received: 18 May 2015  
Accepted: 22 Jun. 2015

including diarrhea, steatorrhea and failure to thrive in infancy. Subsequently retinopathy, ataxic neuropathy, acanthocytosis and fatty liver may appear in childhood due to fat-soluble vitamin deficiency, especially vitamin E and beta-carotene that are at extremely low levels in patients with ABL.<sup>2-4,7</sup>

Herein, we describe the history and clinical features of a patient with ABL who was referred to our hospital and followed until the age of five.

### CASE REPORT

A 12-months-old male infant was referred to our hospital because of failure to thrive. He was born from consanguineous parents and his birth weight was 3.4 kg and he failed to gain weight appropriately since two months of age. At the first visit his weight was 6 kg and his height and head circumference were 61 and 44cm, respectively. All growth parameters were below the fifth percentiles of growth chart. He also had developmental delay as he held his neck at 6 months and sat at 9 months of age. He had frequent defecations (8-9 times a day) that sometimes were steatotic. He had no family history of similar problems. On Physical examination only widening of fontanels was observed. Other exams were normal and no organomegaly was detected.

Laboratory tests showed: cholesterol=43 mg/dl, triglycerides=6 mg/dl, Alanine transaminase (ALT)=17 U/L, Aspartate transaminase (AST)=60 U/L, total protein=5 g/dl and albumin=3.8 g/dl. Stool examination showed Fat droplets (+) <40 drop/HPF. Thyroid function test showed TSH=6.5 mIU/L and T4=135 nmol/L that established diagnosis of subclinical hypothyroidism. Sweet chloride test was normal. Abdominal sonography demonstrated normal size of liver and spleen but there were multiple small stones in both kidneys. An intraventricular cyst was seen in brain MRI. Wrist X-ray showed osteopenic bones and bone age was 2 months. There was no abnormality in retinal funduscopy. Macroscopic findings in endoscopy included normal mucosa of esophagus and stomach but snow like appearance and pathologic findings were found in bulb of duodenum. Microscopic study showed tall villi and fine vacuolation of enterocytes. Crypts

were unremarkable and there was mild infiltration of lymphoplasmacells and some eosinophils (3-16/HPF) in lamina propria alongside edema (Figure 1).

The parents lipid profiles were completely normal. It would have been beneficial to perform molecular diagnosis but unfortunately the parents did not agree to do genetic study.

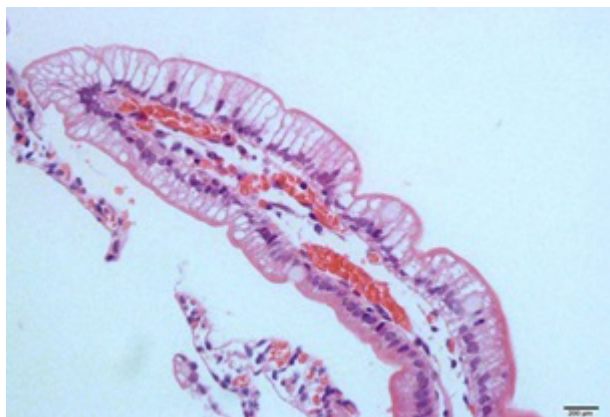
In the presence of symptoms, the most probable differential diagnosis included cystic fibrosis (CF) and pediatric celiac disease, but severe hypocholesterolemia and hypotriglyceridemia suggested other conditions including ABL, homozygous Familial hypobetalipoproteinemia (FHBL) with dominant transmission (mutations in APOB gene) and chylomicron retention disease (CMRD) with recessive transmission (mutation in SAR1B gene).

Normal levels of tissue transglutaminase antibodies and sweet chloride test along with microscopic studies ruled out celiac disease and CF. Family lipid profile was useful in delineating between other conditions. While obligate heterozygote parents of homozygous FHBL patients have decreased levels of plasma LDL-cholesterol and apo B, asymptomatic parents of our patient with normal plasma cholesterol levels suggested a recessive disorder and ruled out FHBL.

Undetectable amounts of plasma apo B and low density lipoproteins ruled out CMRD and confirmed the diagnosis of ABL.

Treatment included dietary modification and high dose oral fat-soluble vitamin supplementation. Our patient was treated with Caprilon formula, medium-chain triglycerides (MCT) oil 1cc/kg/day, vitamin A 10000 IU/day, vitamin E 2000 IU/day, vitamin D 400 IU/day, vitamin K 5 mg daily and levothyroxine 50-100 mcg/day.

He was followed every 6 months and showed appropriate weight gain. His weight was 16 kg at the age of 4 years. His mental development was also suitable. Kidney stones resolved with medical treatment and intraventricular brain cyst remained at the same size. Liver aminotransferases were elevated (AST 160 and ALT 250 U/L) but reinforcing of accurate fat-limited diet resulted in normal ranges of these enzymes levels during follow-ups. In last visit



**Fig. 1:** Intestinal biopsy showed tall villi and vacuolation of enterocytes. Crypts were unremarkable and there was mild infiltration of lymphoplasmacells and some eosinophils (3-16/HPF) in lamina propria alongside edema.

he was 5 years old and his weight was 18 kg and his height was 105 cm.

## DISCUSSION

ABL is a very rare recessive metabolic disorder characterized by the absence of apoB-containing lipoproteins in plasma. Malabsorption of fat and fat-soluble vitamins leads to a variable clinical phenotype that presents in early childhood with steatorrhea and failure to thrive and may include progressive multi-system abnormalities as the patient ages.<sup>7</sup> Most patients are diagnosed in the 2nd to 4th decades and few others in 1st and 6th decades. Earlier presentation of symptoms may be due to a more severe phenotype and may be more resistant to medical treatment resulting in poor outcomes. On the other hand, later presentation and longer period of untreated disease may be associated with poor outcomes due to consequences of fat-soluble vitamins deficiency.

Most reported patients with ABL had lipid malabsorption, remarkably low serum lipid levels and gastrointestinal manifestation including diarrhea, steatorrhea and oral fat intolerance. Retinitis pigmentosa, myopathy and spinocerebellar ataxia have also been reported in most patients due to fat-soluble vitamins deficiency. Liver involvement was seen in some patients.<sup>1,4,8-9</sup>

Our patient had signs and symptoms of early onset ABL including fat intolerance, diarrhea, steator-

rhea, growth retardation, developmental delay, low TG and cholesterol levels. Typical features in the intestinal biopsy were also noted. Gastrointestinal manifestations including fat intolerance, diarrhea and steatorrhea are consistent features in most reported patients.<sup>8</sup>

Brain CT scan showed intraventricular cyst which has not been previously reported despite numerous reported neurological involvement. In ABL, both central and peripheral nervous systems can be affected and may be the most serious clinical manifestation.<sup>1</sup> The primary pathology is progressive demyelination of the nervous system which is related to abnormal lipid peroxidation of the highly unsaturated phospholipid of myelin, probably due to prolonged vitamin E deficiency.<sup>10</sup> Several studies showed that early high dose vitamin E (100 IU/Kg) therapy prior to the age of 2 years can prevent progressive neurological dysfunction and diminish neurological sequelae.<sup>8,11</sup>

Ophthalmic manifestations of ABL include a wide range of symptoms. Retinitis pigmentosa is the most frequent abnormality associated with ABL. Pigmentary retinal degeneration is progressive and often causes slowly enlarging annular scotomas with macular sparing. Patients may have reduced night vision or color vision, early in the course of disease. Previous studies showed that high dose vitamin E therapy or combined vitamin E and vitamin A treatment before 2 years of age can prevent the development and progression of retinopathy.<sup>12-14</sup>

The absence of retinitis pigmentosa in our patient must be attributed to the fact that retinopathy may appear at any time during the first 2 decades of life.<sup>3</sup> Red cell acanthocytosis is the hematologic manifestation of ABL which is reported in several cases but was not seen in our case.<sup>8</sup>

Nephrolithiasis was present in our patient which was also been reported previously. In patients with ABL fat malabsorption causes combination of unabsorbed fatty acids with calcium ions in the intestinal lumen leading to excessive absorption of dietary oxalate and kidney stone formation.<sup>15</sup> Management included dietary fat restrictions, fat soluble vitamins supplements, specific formula and

polycitrate that resolved the problem in the patient.

Our patient had subclinical hypothyroidism, the association between ABL and subclinical hypothyroidism was previously reported in another case.<sup>16</sup>

Hepatic involvement including hepatosteatosi s and cirrhosis were also reported in some cases.<sup>8,9,17</sup> the hepatic manifestation of our patient was elevated levels of serum transaminases, probably due to hepatosteatosi s which resolved with accurate treatment.

In conclusion, patients with ABL may show particular symptoms in addition to typical features. Early diagnosis and accurate treatment are necessary to avoid the complications following fat-soluble vitamin deficiencies.

#### FINANCIAL DISCLOSURE

None declared

#### Funding/Support

None declared

#### Role of the sponsor

None declared

#### CONFLICT OF INTEREST

The authors declare no conflict of interest related to this work.

#### REFERENCES

- Sobrevilla LA, Goodman ML, Kane CA. Demyelinating central nervous system disease, macular atrophy and acanthocytosis (Bassen-Kornzweig syndrome). *Am J Med* 1964;**37**:821-8.
- Pons V, Rolland C, Nauze M, Danjoux M, Gaibelet G, Durandy A, et al. A severe form of Abetalipoproteinemia caused by new splicing mutations of microsomal triglyceride transfer protein (MTTP). *Human Mutation* 2011;**32**:751-9.
- Rahalkar AR, Hegele RA. Monogenic pediatric dyslipidemias: Classification, genetics and clinical spectrum. *Mol Genet and Metab* 2008;**93**:282-94.
- Uslu N, Gurakan F, Yuce A, Demir H, Tarugi P. Abetalipoproteinemia in an infant with severe clinical phenotype and a novel mutation. *Turk J Pediatr* 2010;**52**:73-7.
- Bassen FA, Kornzweig AL. Malformation of the erythrocytes in a case of atypical retinitis pigmentosa. *Blood* 1950;**5**:381-7.
- Salt HB, Wolff OH, Lloyd JK, Fosbrooke AS, Cameron AH, Hubble DV. On having no beta-lipoprotein: A syndrome comprising a-beta-lipoproteinaemia, acanthocytosis, and steatorrhea. *Lancet* 1960;**2**:325-9.
- Berriot-Varoqueaux N, Aggerbeck LP, Samson-Bouma ME, Wetterau JR. The role of the triglyceride transfer protein in abetalipoproteinemia. *Annu Rev Nutr* 2000;**20**:663-97.
- Zamel R, Khan R, Pollex RL, Hegele RA. Abetalipoproteinemia: two case reports and literature review. *Orphanet J Rare Dis* 2008;**3**:19.
- Di Filippo M, Créhalet H, Samson-Bouma ME, Bonnet V, Aggerbeck LP, Rabès JP, et al. Molecular and functional analysis of two new MTTP gene mutations in an atypical case of abetalipoproteinemia. *J Lipid Res* 2012;**53**:548-55.
- Segal S, Sharma S. Atypical retinitis pigmentosa and progressive ataxic neuropathy. *Can Fam Physician* 2005;**51**:1079-86.
- Chardon L, Sassolas A, Digeon B, Michel-Calemard L, Bovier-Lapierre M, Moulin P, et al. Identification of two novel mutations and long-term follow-up in abetalipoproteinemia: a report of four cases. *Eur J Pediatr* 2009;**168**:983-9.
- Runge P, Muller DP, McAllister J, Calver D, Lloyd JK, Taylor D. Oral vitamin E supplements can prevent the retinopathy of abetalipoproteinaemia. *Br J Ophthalmol* 1986;**70**:166-73.
- Chowers I, Banin E, Merin S, Cooper M, Granot E. Long-term assessment of combined vitamin A and E treatment for the prevention of retinal degeneration in abetalipoproteinaemia and hypobetalipoproteinaemia patients. *Eye* 2001;**15**:525-30.
- Bishara S, Merin S, Cooper M, Azizi E, Delpre G, Deckelbaum RJ. Combined vitamin A and E therapy prevents retinal electrophysiological deterioration in abetalipoproteinaemia. *Br J Ophthalmol* 1982;**66**:767-70.
- Grise P, Le Luyer B, Mitrofanoff P. Oxalate lithiasis associated with abetalipoproteinemia: Report of a case. *Chir Pediatr* 1983;**24**:411-2.
- Al-Mahdili HA, Hooper AJ, Sullivan DR, Stewart PM, Burnett JR. A mild case of abetalipoproteinaemia in association with subclinical hypothyroidism. *Ann Clin Biochem* 2006;**43**:516-9.
- Collins JC, Scheinberg IH, Giblin DR, Sternlieb I. Hepatic peroxisomal abnormalities in abetalipoproteinemia. *Gastroenterology* 1989;**97**:766-70.