



Comparative Study with and without the Use of 3D Prototyping of an Unconventional Technique in the Surgical Planning of Revision of Total Hip Arthroplasty*

Estudo comparativo com e sem o uso de prototipagem em 3D de uma técnica não convencional no planejamento cirúrgico de revisão de artroplastia total de quadril

Alonso Ranzzi^{1,2} Rafael de Luca de Lucena^{3,4} Carlos Roberto Schwartzmann^{3,5}
 Carlos Roberto Galia⁶ Marina Cornelli Giroto^{3,4} Leandro de Freitas Spinelli^{5,7}

¹Department of Orthopedics and Traumatology, Santa Casa de Misericórdia de Porto Alegre, Rio Grande do Sul, Brazil

²Department of Orthopedics and Traumatology, Universidade Federal de Ciências da Saúde de Porto Alegre, Rio Grande do Sul, Brazil

³Orthopedics and Traumatology Service, Santa Casa de Misericórdia de Porto Alegre, Rio Grande do Sul, Brazil

⁴Orthopedics and Traumatology Service, Universidade Federal de Ciências da Saúde de Porto Alegre, Rio Grande do Sul, Brazil

⁵Department of Clinical Surgery, Orthopedics and Traumatology, Universidade Federal de Ciências da Saúde de Porto Alegre, Rio Grande do Sul, Brazil

Address for correspondence Rafael de Luca de Lucena, MD, Serviço de Ortopedia e Traumatologia, Santa Casa de Misericórdia de Porto Alegre, rua Professor Annes Dias, 135, 2o andar – Centro Histórico, Porto Alegre, RS, 90460-150, Brazil (e-mail: rfdld@gmail.com).

⁶Department of Surgery, Orthopedics and Traumatology, Hospital de Clínicas de Porto Alegre, Universidade Federal do Rio Grande do Sul, Porto Alegre, Rio Grande do Sul, Brazil

⁷Graduate Program in Design and Manufacturing Processes, Bioengineering, Biomechanics and Biomaterials Laboratory, Universidade de Passo Fundo, Rio Grande do Sul, Brazil

Rev Bras Ortop 2022;57(5):884–890.

Abstract

This article presents a comparison between two cases in which there was a need for revision of total hip arthroplasty due to aseptic acetabular failure. We used 3D prototyping in one of the cases to perform an unconventional technique of molding synthesis material before the procedure to evaluate the time saved in the trans-operative period in complex cases.

Keywords

- ▶ arthroplasty, replacement, hip
- ▶ surgical planning
- ▶ 3D printing

* Study performed at the Orthopedics and Traumatology Service of Santa Casa de Misericórdia de Porto Alegre and at Universidade Federal de Ciências da Saúde de Porto Alegre, Rio Grande do Sul, Brazil.

received
October 11, 2020
accepted
February 11, 2021
published online
October 13, 2021

DOI <https://doi.org/10.1055/s-0041-1731659>
ISSN 0102-3616.

© 2021. Sociedade Brasileira de Ortopedia e Traumatologia. All rights reserved.

This is an open access article published by Thieme under the terms of the Creative Commons Attribution-NonDerivative-NonCommercial-License, permitting copying and reproduction so long as the original work is given appropriate credit. Contents may not be used for commercial purposes, or adapted, remixed, transformed or built upon. (<https://creativecommons.org/licenses/by-nc-nd/4.0/>)

Thieme Revinter Publicações Ltda., Rua do Matoso 170, Rio de Janeiro, RJ, CEP 20270-135, Brazil

Resumo**Palavras-chave**

- ▶ artroplastia de quadril
- ▶ planejamento cirúrgico
- ▶ impressão em 3D

Este artigo apresenta uma comparação entre dois casos em que havia a necessidade de revisão de artroplastia total de quadril por falha acetabular asséptica. Utilizamos prototipagem em 3D em um dos casos para realizar uma técnica não convencional de moldagem de material de síntese antes do procedimento com objetivo de avaliar o tempo economizado no transoperatório em casos complexos.

Introduction

Revision of total hip arthroplasty (THA) is currently an increasingly-performed procedure.¹ The complexity involved in surgeries of this magnitude often requires meticulous preoperative planning to minimize the risks of possible associated complications.

Although there has been a significant improvement in the materials used during arthroplasty, after a few years it is inevitable that a considerable part of the patients will progress to the need to replace the implants, especially due to aseptic loosening, often with significant acetabular and femoral failure.^{2,3}

This increased demand requires the creation and improvement of techniques for THA reviews. Preoperative imaging has progressed from two to three dimensions and, recently, to palpable modeling available in real size when using 3D printing.² This broadens the surgical team's understanding of the pathology in question and, therefore, expands the understanding of those involved in the procedure to be performed.³ Many orthopedic implants have a standard shape that is not compatible with every situation, so the preoperative molding of synthesis materials can be more adaptable according to the need, and it speeds up the surgical procedure, since it avoids this step during surgery without actually considerably increasing the final costs of the procedure.

In this sense, the present research presents a comparative study that demonstrates an unconventional technique in the surgical planning of THA review to evaluate the practical usefulness of 3D prototyping to abbreviate complex surgeries.

Materials and Methods

The present research was submitted and approved by the Ethics in Research Committee of our institution. The work consists of a comparison between two situations of an unconventional surgical technique for the review of THA in which there is a need for reconstruction of an acetabular failure, with and without the use of 3D printed models. Two cases (one with and the other without the use of 3D printed models) were selected in which there were radiological signs of aseptic loosening of the acetabular component and which fit type 3B in the Paprosky classification.

The cases operated herein reported present a new surgical technique for acetabular reconstruction. In one of the cases,

we used 3D prototyping (PT3D) of the hip that would be operated on. The technique consists in obtaining the 3D image of the region that will be reviewed and then processed in the computer-aided design (CAD) environment and later printed. For this, the patient was initially submitted to a traditional computed tomography (CT), which provides a computer file in the digital imaging and communications in medicine (DICOM) format that is then opened and processed in the InVesalius software (Centro de Tecnologia da Informação Renato Archer, Campinas, SP, Brazil) to be converted into the standard triangle language (STL) format. Then, the file was edited in the MeshMixer software (Autodesk, Inc., San Rafael, CA, US) to remove the artifacts, the loose implant, and improve the quality of the image to then print the acetabulum in real size with a Cliever 3D equipment (Cliever Tecnologia, Belo Horizonte, MG, Brazil), using polylactic acid (PLA) filament. The printing was performed with a layer thickness of 0.3 mm, filling of 70% and line thickness of 3 mm, and it took approximately 10 hours. The manufacturing took place in a controlled environment with a temperature of 25.8°C and air humidity of 47%. After the printing, a post-processing was performed to remove the excess material used in the part holder. The total cost of manufacturing the 3D biomodel was US\$ 16.00

We timed the steps of the preoperative and transoperative surgical planning to measure the comparison of the objective. We estimated the total time to mold the plate, the study of the acetabular component, the approximate size and direction of the screws, in addition to the amount of graft required to fill the acetabular failure.

Both revisions were performed in a single surgical time. The access route chosen for the second procedure was the same incision as that of the primary arthroplasty surgery, being posterolateral in both cases.

A reconstruction plate (small-fragment box) was molded in both cases, and for one of them we used as a base the biomodel printed in 3D to make the necessary adjustments before the procedure, and, for the second case, the modeling occurred during surgery. The precast plate based on the 3D biomodel was sterilized by the Materials Sector to be used permanently during surgery. In both acetabular reconstructions, we used autologous bone grafts of the iliac ipsilaterally to the main procedure. Both arthroplasties were replaced using a cemented acetabular component (conventional polyethylene) and a metallic femoral head.

Before the surgery, all patients were previously instructed regarding the technique to be performed, and they agreed with the process. The patients were operated on by the authors of the present article.

The patient data were kept confidential, serving only for the recording or illustration of the technique presented.

Description of Case 1

A 64-year-old female patient sought care for progressive chronic pain in the right hip. Ten years before, she had undergone a cemented THA on the right side due to fractured femoral neck. In the first care, anteroposterior (AP) radiographs of the hip and AP and profile (P) radiographs of the coxofemoral joint were performed (►Figure 1A, 1B, 1C). In addition, laboratory tests (blood count, c-reactive protein [C-RP] and erythrocyte sedimentation rate [ESR]) were requested, and they did not show abnormalities. We indicated revision of the arthroplasty due to aseptic loosening in a single stage surgery (type 3B acetabular failure in the Paprosky classification). The femoral stem did not present radiographic signs of loosening. The 3D prototype (3DPT) was printed for the preoperative planning (►Figure 2) based on a computed tomography of the coxofemoral joint.

Using the 3D biomodel of the pelvis, we molded the reconstruction plate before the procedure, and then sent it to the Sterilization Sector so that it was ready to be used at the time of the review (►Figure 3G). The access route chosen for the right hip was posterolateral, and another incision was performed for the removal of a homolateral iliac graft (►Figure 3A). During surgery, stability tests confirmed that the stem remained fixed, only the femoral metal head was replaced. The acetabular component was extracted, and a large local debridement was performed (►Figure 3B,C, D, E) and the molded plate was introduced (►Fig. 3F), observing the same cavity that was previously viewed when molding the plate with the aid of a 3D printed model (►Fig. 3G). The size of the acetabular prosthesis was also estimated during planning using cutters of varying sizes (►Figure 4A). We used a structured autologous graft of the ipsilateral iliac to prevent cement extravasation into the pelvis, as well as impacted spongy graft (►Figure 4B,C). The acetabular component was cemented on the reconstruction plate, and to the new bone layer the stability tests performed were adequate (►Figure 4D). The immediate postoperative outcome is shown in ►Figure 1B. Currently, the patient has been under follow-up for two years and three months.

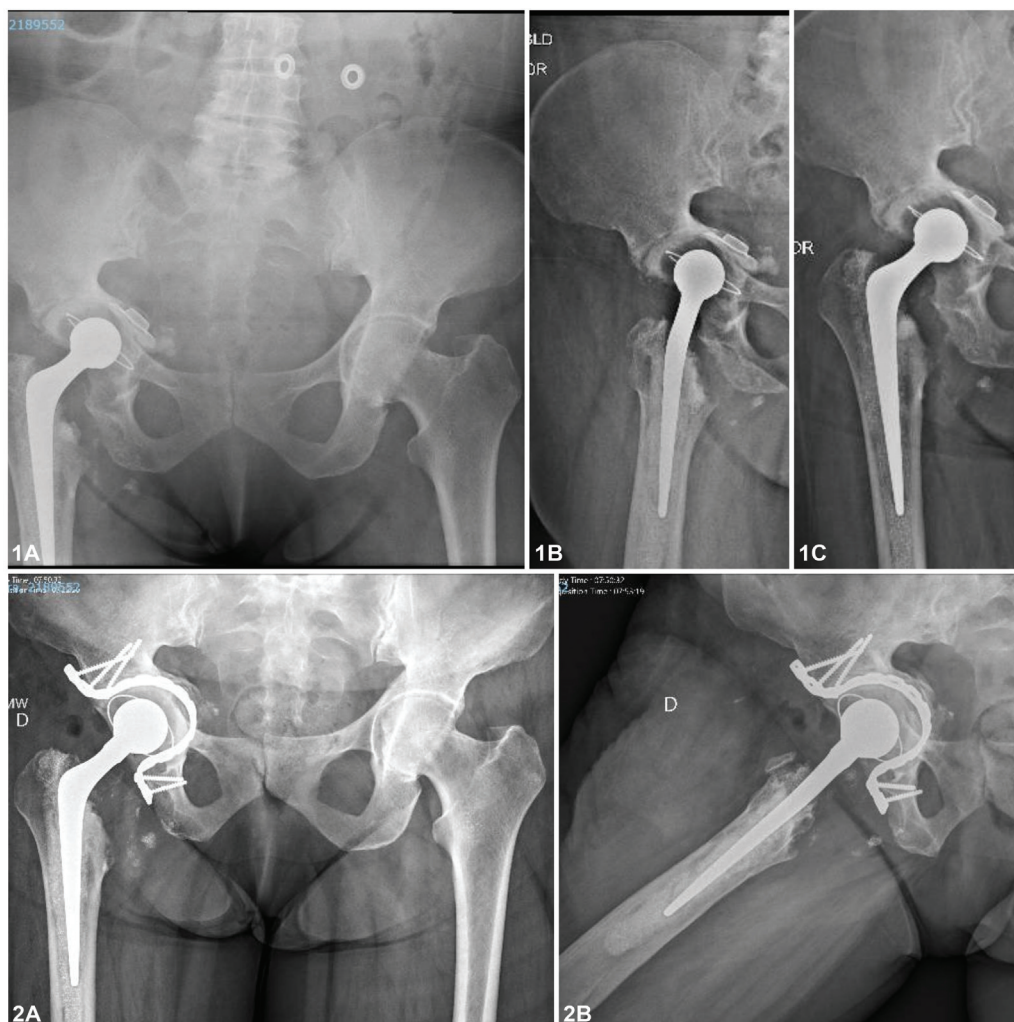


Fig. 1 (A) Preoperative radiographs (case 1). (B) Postoperative radiographs.

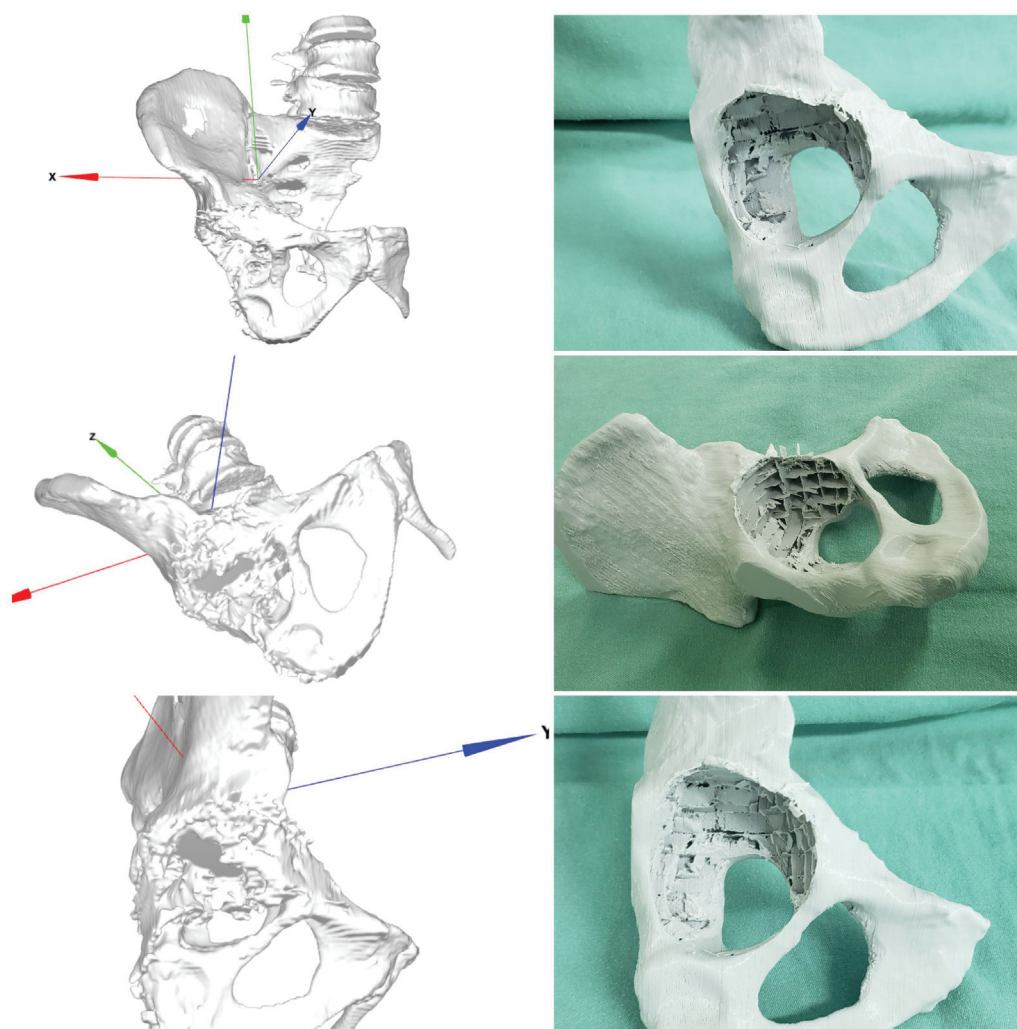


Fig. 2 3D prototype (case 1) printed after being processed based on a computed tomography scan.

Description of Case 2

A 58-year-old male patient sought care for chronic pain and functional limitation in the right hip. In the first care, AP radiographs of the pelvis and AP and P radiographs of the coxofemoral joint were performed (► **Figure 5A**). Total hip arthroplasty was indicated for osteoarthritis in the right hip (► **Figure 5B**). After 15 years, the patient returned for a consultation with significant failure of the acetabulum classified as Paprosky type 3B (► **Figure 5C**) and signs of osteolysis in the femoral stem in Gruen zones 1, 2, 6, and 7. Laboratory tests (blood count, C-RP and ESR) were requested, but they did not show abnormalities. We decided to perform a review of the THA in a single surgical time (► **Figure 5D**). The stem was stable during the transoperative tests, and we chose to maintain it. Currently, the patient has been under follow-up for two years (► **Figure 5E**).

Results

The cases herein reported demonstrate a new option of surgical technique to solve complex problems involving the review of THA in cases of Paprosky type-3B failures.

The patients were successfully operated on using a reconstruction plate on the acetabular fundus as support for the structural graft associated with impaction grafting for reconstruction of the acetabulum for further cementation of the acetabular component of the prosthesis.

The total time spent in the pre- and transoperative (with and without the use of a 3D printed mold, respectively) moldings of the reconstruction plate was 8 minutes and 27 minutes, until they were adequately adjusted.

The total time it took to choose the size of the cemented acetabular component pre- and transoperative (with and without the use of a 3D printed mold, respectively) was 2 and 6 minutes. The size and direction of the screws until the fixation of the reconstruction plate in the acetabulum were of 7 and 25 minutes respectively.

In order to obtain the necessary amount of graft, without counting the extraction time, it took 3 and 6 minutes respectively. The total time of the procedure in case 1 was of 123 minutes, and in case 2, 179 minutes, a difference of 56 minutes.

During the transoperative period, we did not need to perform additional moldings on the reconstruction plate,

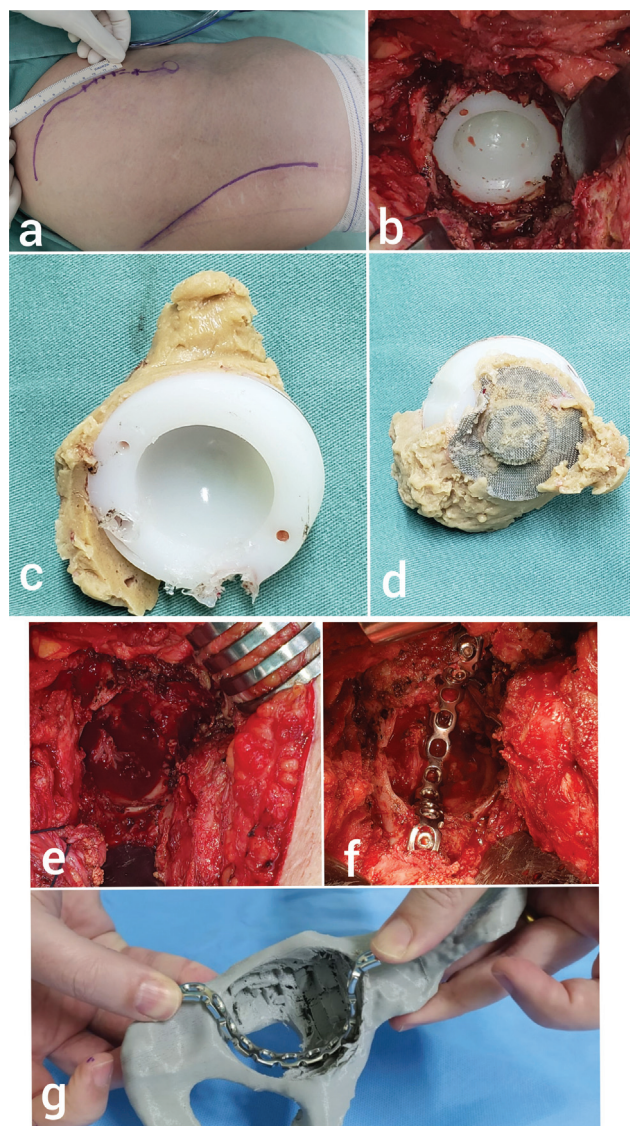


Fig. 3 (A) Ipsilateral iliac and posterolateral incisions (case 1). (B) Transoperative image of cemented acetabular component to be revised. (C-D) Acetabular component removed. (E) Acetabular failure after removal of the acetabular component. (F) Molded reconstruction plate embedded in the acetabulum. (G) Planning using the 3D biomodel with the precast plate.

previously made using the 3D printed model. The cemented acetabular component coincided exactly with what had been planned according to the tests during the prototyping, and the size of the screws was within a variation of ± 2 mm.

Discussion

The use of 3DPTs is a reality that has become familiar to orthopedic surgeons.³ Although not yet widely available, full-size printing facilitates the understanding and planning of the proposed procedure. The costs regarding the production of the part are easily supplanted by the shorter surgical time, not to mention all the known benefits that involve a faster procedure.³⁻⁵

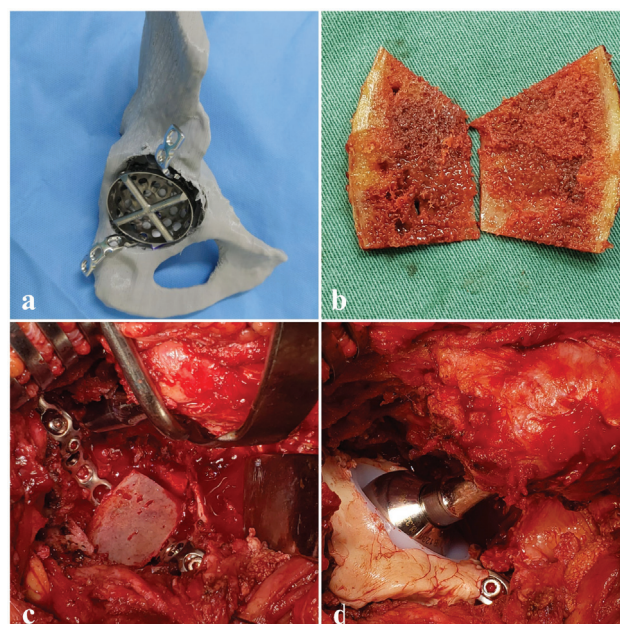


Fig. 4 (A) Reconstruction plate and acetabular cutter for preoperative planning. (B) Autologous bone graft of the iliac structured as a lid. (C) Graft cover used in the acetabular fundus to avoid cement extravasation into the pelvis. (D) Final result of the cemented acetabular component reviewed.

Another important point to be emphasized is that, during a THA review, we often find a difficult surgical exposure due to the non-anatomical presence of periprosthetic fibrotic tissues.^{5,6} With prototyping, there is the possibility of using anatomical landmarks previously defined in the biomodel as an intraoperative reference. We know that not all acetabular failures are the same; therefore, when we mold the material we can make the necessary adjustments.⁷ The individualization of the treatment to the demands of the patient is a medical trend, reinforcing the importance of a detailed preoperative planning, which provides more consistent results.²⁻⁵

The understanding of the patient is fundamental, especially regarding a complex THA review and the challenges faced by the surgeon, in order to demystify the concept that the exchange of components is often simple. In this sense, 3D printing can be a tactile tool that helps explain the procedure to be performed. While there are other positive points to note, we must recognize that the cost of 3D printers is still high.

We present here not only a description of two cases, but also an innovative technique that has been used in our service, given the limitation of materials we face in the Brazilian Unified Health System (Sistema Único de Saúde, SUS, in Portuguese) and the higher demand for revision surgeries due to the greater longevity of the population. Through the cases herein reported, we demonstrated a new option of surgical technique to solve complex problems involving the THA review in type-3B Paprosky failures. In these cases, we used a reconstruction plate on the acetabular fundus as a support for the structural graft

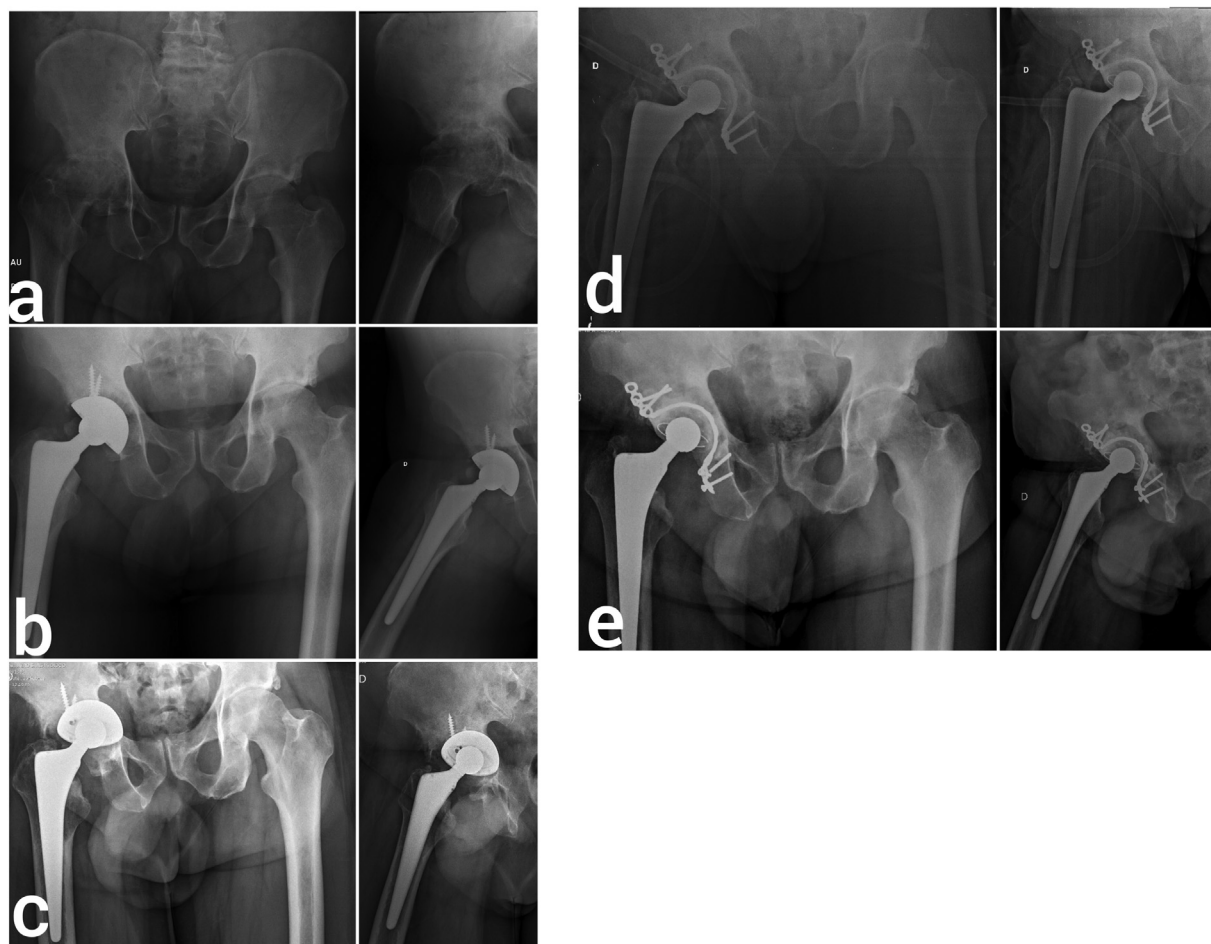

Fig. 5 (A) Preoperative radiograph evidencing important osteoarthritis in the right hip (case 2). (B) Immediate postoperative radiograph. (C) Postoperative radiograph 15 years later, with Paprosky type-3B failure. (D) Immediate postoperative radiograph of the revision surgery. (E) Postoperative radiograph with two years of evolution, evidencing osteointegration of the graft in the acetabular fundus.

associated with impaction grafting for acetabular reconstruction. This technique has shown excellent results to date. Furthermore, the procedure can be optimized with the use of 3D printing for a better understanding of the pathology by the surgical team, for the training of residents, the reduction of the surgical time, and, consequently, of the risks to the patients. We understand that the number of cases is still small, and that we cannot make generalizations regarding the two cases herein reported. However, the technique effectively solved the problems presented and undeniably led to a shorter surgical time. A greater follow-up and a greater number of cases treated with the proposed technique are still needed, and the use of 3D prototyping can offer a cost-effective alternative to solve specific cases.

Final Comments

The technique herein presented for the reconstruction of Paprosky type-3B defects demonstrated excellent results, especially when associated with some of the various benefits of using a 3DPT for the planning of surgical procedures. Preoperative molding of the synthesis material to be used may decrease the surgical time.

Financial Support

There was no financial support from public, commercial, or non-profit sources.

Conflict of Interests

The author has no conflict of interests to declare.

Acknowledgements

The authors would like to thank the Dr. Gisele Orlandi Introini, Dr. André Peres, Samuel Werner Wolf, Luis Fernando Marcelino Braga, and Andreia Gomes Aires of LIPECIN/UFCSA for their important contributions to the present research.

References

- 1 Best JT. Revision total hip and total knee arthroplasty. *Orthop Nurs* 2005;24(03):174–179, quiz 180–181
- 2 Xia RZ, Zhai ZJ, Chang YY, Li HW. Clinical Applications of 3-Dimensional Printing Technology in Hip Joint. *Orthop Surg* 2019; 11(04):533–544
- 3 Fang C, Cai H, Kuong E, et al. Surgical applications of three-dimensional printing in the pelvis and acetabulum: from models and tools to implants. *Unfallchirurg* 2019;122(04): 278–285

- 4 Wyatt MC. Custom 3D-printed acetabular implants in hip surgery—innovative breakthrough or expensive bespoke upgrade? *Hip Int* 2015;25(04):375–379
- 5 Woo SH, Sung MJ, Park KS, Yoon TR. Three-dimensional-printing Technology in Hip and Pelvic Surgery: Current Landscape. *Hip Pelvis* 2020;32(01):1–10
- 6 Gibon E, Kerboull L, Courpied JP, Hamadouche M. Acetabular reinforcement rings associated with allograft for severe acetabular defects. *Int Orthop* 2019;43(03):561–571
- 7 Abdel MP, Trousdale RT, Berry DJ. Pelvic Discontinuity Associated With Total Hip Arthroplasty: Evaluation and Management. *J Am Acad Orthop Surg* 2017;25(05):330–338