

Unusual combined cause of Takotsubo cardiomyopathy: Hyponatremia and seizure

 Ersin Cagri Simsek,¹  Sadik Volkan Emren,²  Oner Ozdogan¹

¹Department of Cardiology, Tepecik Training and Research Hospital, Izmir, Turkey

²Department of Cardiology, Katip Celebi University Ataturk Training and Research Hospital, Izmir, Turkey

ABSTRACT

Takotsubo cardiomyopathy (TTC) is characterized by transient systolic dysfunction of the left ventricle and changes of electrocardiographic or cardiac markers, resembling an acute coronary syndrome. Although the etiology of TTC is still unknown, a wide variability in the psychological and physical triggers for TTC is present. In this article, we describe the case of 69-year-old female with a history of epilepsy and who presented in the emergency room with a new-onset generalized tonic–clonic seizure activity. After finding out that her biochemistry results indicated severe hyponatremia, a diagnosis of TTC was established through echocardiography and angiography.

Keywords: Apical ballooning syndrome; Takotsubo cardiomyopathy; hyponatremia; seizure.

Cite this article as: Simsek EC, Emren SV, Ozdogan O. Unusual combined cause of Takotsubo cardiomyopathy: Hyponatremia and seizure. *North Clin Istanbul* 2019;6(3):304–307.

Takotsubo cardiomyopathy (TTC) is characterized by transient systolic dysfunction of the left ventricle and changes of electrocardiographic or cardiac markers, resembling an acute coronary syndrome. Mostly, TTC develops following emotional or physical stress in the absence of obstructive coronary disease or without angiographic evidence of acute plaque rupture [1–4]. The pathophysiology of TTC is unclear. An excessive release of catecholamines following emotional or physical stress seems to have a pivotal role in the development of TTC [5]. On the other hand, TTC can be triggered by some noncardiac clinical conditions such as hyponatremia and seizure [6–10]. In this article, we describe a case of TTC that developed following seizure and severe hyponatremia.

CASE REPORT

A 69-year-old female having a history of epilepsy was presented to the emergency room with a new-onset generalized tonic–clonic seizure activity. Upon admis-

sion, there was no chest pain or any cardiac symptom. Her medical history indicates she had hypertension and epilepsy, and these were treated with indapamide, carbamazepine, and levetiracetam. Her physical examination was unremarkable. Moreover, routine laboratory values revealed her serum sodium level was 112 mmol/L, initial troponin was 7.13 ng/mL (normal range 0.0–0.06 ng/mL), and serum carbamazepine concentration was 7.1 ng/mL (therapeutic range 4–12 ng/mL). The first electrocardiogram (ECG) showed sinus rhythm with diffuse upsloping 1 mm ST-segment elevation (Fig. 1). After transthoracic echocardiography (TTE), there was apical hypokinesia with an estimated ejection fraction (EF) of 36% (Fig. 2). Although TTC was suggested after initial clinical findings, the patient underwent coronary angiography to rule out coronary artery disease. After the procedure, it was found that coronary angiography revealed no stenosis in any coronary artery (Fig. 3) and that left ventriculography showed anteroapical, inferoapical, and apical akinesis (Fig. 4).



Received: November 12, 2017 Accepted: July 02, 2018 Online: August 08, 2018

Correspondence: Dr. Ersin Cagri SIMSEK. Tepecik Egitim ve Arastirma Hastanesi, Kardiyoloji Klinigi, 35110 Yenisehir, Izmir, Turkey.
Phone: +90 232 244 35 60 e-mail: ercagsim@hotmail.com

© Copyright 2019 by Istanbul Provincial Directorate of Health - Available online at www.northclinist.com

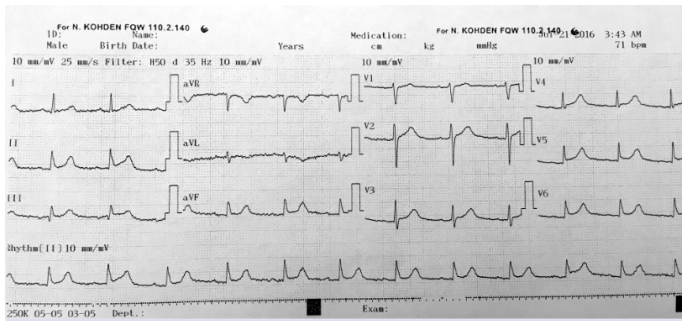


FIGURE 1. Electrocardiogram showing sinus rhythm with diffuse 1 mm upsloping ST-segment elevation.

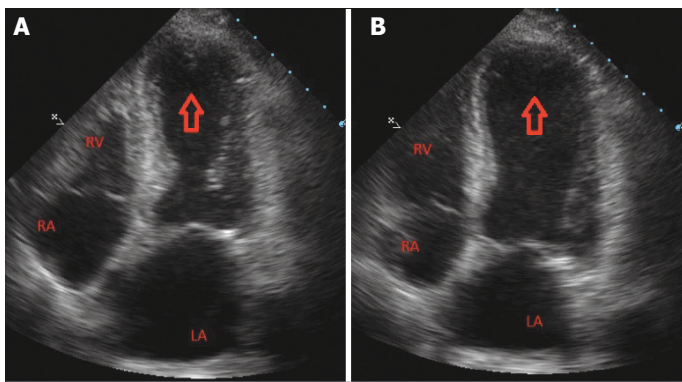


FIGURE 2. Transthoracic echocardiography demonstrating apical hypokinesia with an ejection fraction estimated at 36% in apical 4-chamber view. **(A)** Left ventricle systole. **(B)** Left ventricle diastole, red arrow; apical hypokinesia. (LA: left atrium; RA: Right atrium; RV: Right ventricle).

Hypothyroidism and adrenal insufficiency, both are causes of hyponatremia, were ruled out by determining thyroid-stimulating hormone levels [1.5 μ IU/mL (normal range 0.5–6.2 μ IU/mL)] and serum cortisol levels [20 μ g/dL (normal range 10–20 μ g/dL)]. After suffering from withdrawal to both indapamide and carbamazepine, the patient was subsequently treated with an intravenous infusion of 3% saline, and her sodium then increased to 135 mmol/L at the end of the first week. In this context, it was thought that TTC develops by hyponatremia due to indapamide and carbamazepine. There was then a discharge on aspirin (100 mg/d), metoprolol (50 mg twice daily), ramipril (5 mg/d), subcutaneous enoxaparin (0.8 mL twice daily), valproic acid (500 mg twice daily), and levetiracetam (500 mg twice daily) and a discontinuation of carbamazepine and indapamide treatment. Full recovery of EF (60%) was demonstrated through TTE at two weeks of discharge (Fig. 5). After two months, the patient

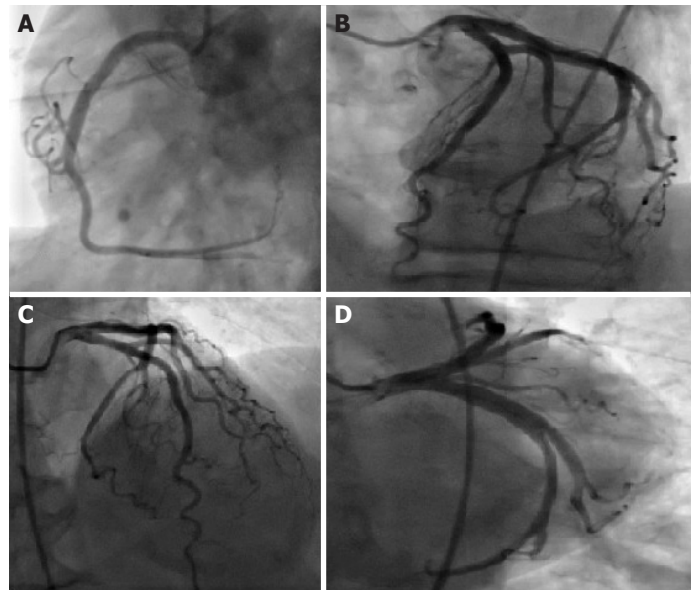


FIGURE 3. Coronary angiography showing normal coronary arteries.

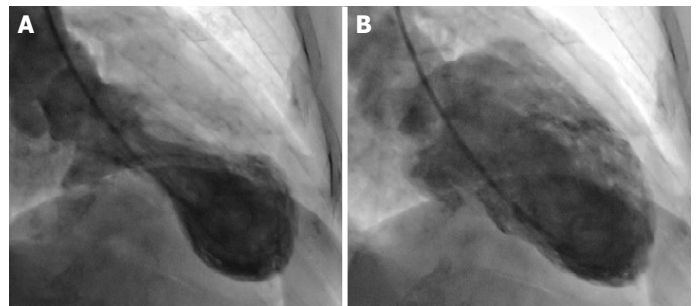


FIGURE 4. Left ventriculography demonstrating apical ballooning in the right anterior oblique view. **(A)** Left ventricle in systole. **(B)** Left ventricle in diastole.

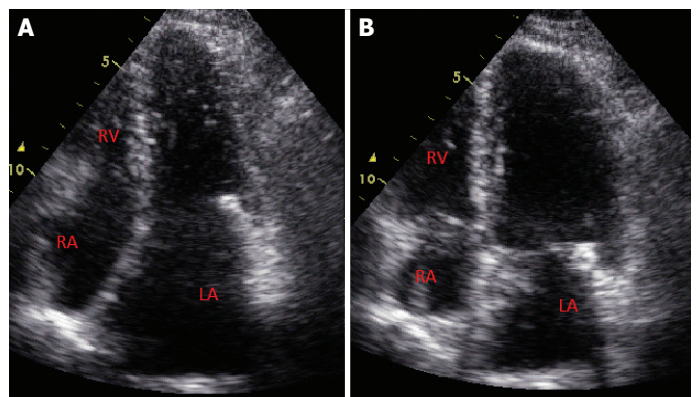


FIGURE 5. Control TTE showing full recovery in apical 4-chamber view after two weeks. **(A)** Left ventricle systole. **(B)** Left ventricle diastole.

was referred to the hospital after suffering from recurrent hyponatremia with a serum sodium level of 115 mmol/L. However, she presented with no cardiac symptoms and seizure. ECG and TTE also did not show any ST-segment changes or wall motion abnormality. Because of this, treatment with carbamazepine, after being stopped on the first hospital admission, had to be started and continued with a lower limit of therapeutic range [4.55 ng/mL (therapeutic range 4–12 ng/mL)] to prevent epileptic seizures.

DISCUSSION

Although its pathophysiology is unclear, TTC is defined as a reversible left ventricular hypokinesis. It was proposed that coronary artery vasospasm, transient obstruction of the left ventricular outflow tract, and microcirculatory dysfunction are the possible causes of this disease [11].

Hyponatremia is the most common electrolyte disorder in hospitalized patients, and its severity is determined according to serum sodium levels that are categorized into three: mild (serum sodium, 130–134 mmol/L), significant (125–129 mmol/L), and severe (<125 mmol/L) [12]. While asymptomatic patients do not require immediate correction, symptomatic hyponatremia is a medical emergency that needs prompt and prudent treatment. Moreover, acute severe hyponatremia is associated with neurologic symptoms, such as seizures and coma, and should be treated meticulously to prevent cerebral edema and encephalopathy. In present case, several clinical factors revealed that seizure is not associated with acute severe hyponatremia. First, the patient has been suffering from recurrent seizures due to epilepsy for a long time. Second, hyponatremia in this patient is chronic and recurrent. This patient is suffering from severe hyponatremia due to several contributing factors including drugs such as carbamazepine and indapamide. The association between hyponatremia and carbamazepine has been well described. However, the mechanisms on how carbamazepine causes hyponatremia are not fully understood. Carbamazepine may increase the secretion of antidiuretic hormone (ADH) from the posterior pituitary and sensitize the osmoreceptors to ADH in the distal convoluted tubules [13]. It can be noted that several case reports have established a causal relationship between indapamide and severe hyponatremia [14]. In this case, these two drugs (carbamazepine and indapamide) with different activity are thought to cause hyponatremia.

According to the a few previous case reports, TTC is associated with severe hyponatremia in several cases,

even with the absence of adrenal insufficiency and hypothyroidism [6, 9, 10]. In our case, we ruled out hypothyroidism and adrenal insufficiency. On the second admission, the patient had been taking carbamazepine without receiving indapamide for two months, and this eventually decreased serum sodium level similarly.

On the first admission, the serum sodium level was 112 mEq/L when TTC occurred, whereas it did not occur on the second admission when the serum sodium level was 115 mEq/L. In this context, we can assume that the recurrence of hyponatremia may not induce TTC. Singh et al. reported that there was a negative correlation between the use of renin angiotensin aldosterone system blockers and the recurrence of TTC [15]. However, we speculate that if the medication was started after the first TTC, it might have prevented the recurrence of TTC in spite of recurrent hyponatremia.

There is also an association between seizure and Takotsubo cardiomyopathy [16]. The mechanism of seizure-associated TTC can be explained by excessive catecholamine release during epileptic seizures. On the first admission, despite the reason of TTC occurrence was seizure instead of hyponatremia, the patient had a history of seizures. Because of this, we are unable to determine whether TTC occurred together with the previous seizures. In fact, both hyponatremia and seizure might separately cause TTC; however, we conclude that both hyponatremia and seizure were predisposing factors together in the present case.

Informed Consent: Written informed consent was obtained from the patient for the publication of the case report and the accompanying images.

Conflict of Interest: No conflict of interest was declared by the authors.

Financial Disclosure: The authors declared that this study has received no financial support.

Authorship Contributions: Concept – ECS; Design – ECS; Supervision – SVE; Materials – ECS; Data collection &/or processing – ECS, OO; Analysis and/or interpretation – SVE; Writing – ECS; Critical review – OO.

REFERENCES

1. Prasad A, Lerman A, Rihal CS. Apical ballooning syndrome (Tako-Tsubo or stress cardiomyopathy): a mimic of acute myocardial infarction. *Am Heart J* 2008;155:408–17.
2. Tsuchihashi K, Ueshima K, Uchida T, Oh-mura N, Kimura K, Owa M, et al. Transient left ventricular apical ballooning without coronary artery stenosis: a novel heart syndrome mimicking acute myocardial in-

- farction. Angina Pectoris-Myocardial Infarction Investigations in Japan. *J Am Coll Cardiol* 2001;38:11–8.
3. Parodi G, Bellandi B, Del Pace S, Barchielli A, Zampini L, Veluzzi S, et al. Natural history of tako-tsubo cardiomyopathy. *Chest* 2011;139:887–92.
 4. Kurowski V, Kaiser A, von Hof K, Killermann DP, Mayer B, Hartmann F, et al. Apical and midventricular transient left ventricular dysfunction syndrome (tako-tsubo cardiomyopathy): frequency, mechanisms, and prognosis. *Chest* 2007;132:809–16.
 5. Nef HM, Möllmann H, Akashi YJ, Hamm CW. Mechanisms of stress (Takotsubo) cardiomyopathy. *Nat Rev Cardiol* 2010;7:187–93.
 6. Worthley MI, Anderson TJ. Transient left ventricular apical ballooning syndrome following a hyponatraemic seizure. *Int J Cardiol* 2007;115:e102–4.
 7. Lemke DM, Hussain SI, Wolfe TJ, Torbey MA, Lynch JR, Carlin A, et al. Takotsubo cardiomyopathy associated with seizures. *Neurocrit Care* 2008;9:112–7.
 8. Kawano H, Matsumoto Y, Arakawa S, Hayano M, Fijisawa H. Takotsubo cardiomyopathy in a patient with severe hyponatremia associated with syndrome of inappropriate antidiuretic hormone. *Intern Med* 2011;50:727–32.
 9. AbouEzzeddine O, Prasad A. Apical ballooning syndrome precipitated by hyponatremia. *Int J Cardiol* 2010;145:e26–9.
 10. Sagiv O, Vukelic S, Czak S, Messineo F, Coplan NL. Apical ballooning syndrome associated with isolated severe hyponatremia: case report and suggested pathophysiology. *Rev Cardiovasc Med* 2012;13:e198–202.
 11. Komamura K, Fukui M, Iwasaku T, Hirofumi S, Masuyama T. Takotsubo cardiomyopathy: Pathophysiology, diagnosis and treatment. *World J Cardiol* 2014;6:602–9.
 12. Spasovski G, Vanholder R, Allolio B, Annane D, Ball S, Bichet D, et al. Clinical practice guideline on diagnosis and treatment of hyponatraemia. *Eur J Endocrinol* 2014;170:G1–47.
 13. Kuz GM, Manssourian A. Carbamazepine-induced hyponatremia: assessment of risk factors. *Ann Pharmacother* 2005;39:1943–6.
 14. Santos M, Dias V, Meireles A, Gomes C, Luz A, Mendes D, et al. Hyponatremia-an unusual trigger of Takotsubo cardiomyopathy. *Rev Port Cardiol* 2011;30:845–8.
 15. Singh K, Carson K, Usmani Z, Sawhney G, Shah R, Horowitz J. Systematic review and meta-analysis of incidence and correlates of recurrence of takotsubo cardiomyopathy. *Int J Cardiol* 2014;174:696–701.
 16. Sakuragi S, Tokunaga N, Okawa K, Kakishita M, Ohe T. A case of takotsubo cardiomyopathy associated with epileptic seizure: reversible leftventricular wall motion abnormality and ST-segment elevation. *Heart Vessels* 2007;22:59–63.