

CASE REPORT

Large tubular colonic duplication in an adult treated with a small midline incision

Yuen Geng Yong, Kyung Uk Jung¹, Yong Beom Cho¹, Seong Hyeon Yun¹, Hee Cheol Kim¹, Woo Yong Lee¹, Ho-Kyung Chun¹

Department of Surgery, Hospital Selayang, Lebuhraya Selayang-Kepong, Selangor, Malaysia, ¹Department of Surgery, Samsung Medical Center, Sungkyunkwan University School of Medicine, Seoul, Korea

Tubular colonic duplication presenting in adults is rare and difficult to diagnose preoperatively. Only a few cases have been reported in the literature. We report a case of a 29-year-old lady presenting with a long history of chronic constipation, abdominal mass and repeated episodes of abdominal pain. The abdominal-pelvic computed tomography scan showed segmental bowel wall thickening thought to be small bowel, and dilatation with stasis of intraluminal content. The provisional diagnosis was small bowel duplication. She was scheduled for single port laparoscopic resection. However, a T-shaped tubular colonic duplication at sigmoid colon was found intraoperatively. Resection of the large T-shaped tubular colonic duplication containing multiple impacted large fecaloma and primary anastomosis was performed. There was no perioperative complication. We report, herein, the case of a T-shaped tubular colonic duplication at sigmoid colon in an adult who was successfully treated through mini-laparotomy assisted by single port laparoscopic surgery.

Key Words: Colonic duplication, Congenital abnormalities, Adult, Laparoscopy

INTRODUCTION

Tubular colonic duplication in adults is rare and only a few cases have been reported in the literature. The standard treatment of colonic duplication is traditional laparotomy and surgical resection. When the colonic duplication is large and compounded by impacted large fecaloma, treatment with minimally invasive surgery may be difficult. We report a case of a large tubular colonic duplication with impacted large fecaloma in an adult successfully treated with a small midline abdominal incision.

CASE REPORT

A 29-year-old lady presented at the surgical outpatient clinic of Samsung Medical Center with symptoms of repeated episodes of abdominal pain, chronic constipation and abdominal mass for about 12 years. Physical examination revealed a non-tender mass at the right lower quadrant. Apart from an open appendectomy 20 years prior, she did not have any other illness. Initial abdominal-pelvic computed tomography (CT) scan showed segmental bowel thickening thought to be small bowel, and

Received July 19, 2011, Revised September 27, 2011, Accepted October 13, 2011

Correspondence to: Ho-Kyung Chun

Department of Surgery, Samsung Medical Center, Sungkyunkwan University School of Medicine, 81 Irwon-ro, Gangnam-gu, Seoul 135-710, Korea

Tel: +82-2-3410-3465, Fax: +82-2-3410-0040, E-mail: hkchun@skku.edu

© Journal of the Korean Surgical Society is an Open Access Journal. All articles are distributed under the terms of the Creative Commons Attribution Non-Commercial License (<http://creativecommons.org/licenses/by-nc/3.0/>) which permits unrestricted non-commercial use, distribution, and reproduction in any medium, provided the original work is properly cited.

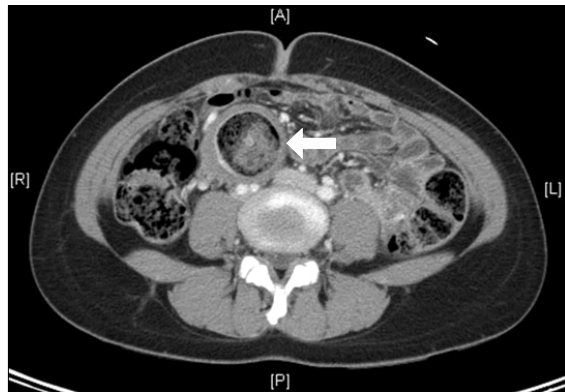


Fig. 1. Axial view abdominal computed tomography scan showing thickened bowel wall (white arrow) and segmental dilatation with stasis of intraluminal content.

dilatation with stasis of intraluminal content. Hence, a provisional diagnosis of small bowel duplication was made. She was then advised for operation but chose to observe the disease and refused to undergo the operation as her symptoms of abdominal pain and constipation improved with enemas. During her subsequent visits to our clinic, repeat CT scans showed slow interval progression of the bowel dilatation with thickening of the bowel wall and stasis of intraluminal content (Figs. 1, 2).

Three years following her first visit to our clinic, when she revealed to us of her intention to get married soon, we informed her that the surgical condition might threaten her pregnancy and complicate childbirth should a complication arise from the intestinal duplication. She then agreed to undergo the operation but, of note, wound cosmesis following the operation was one of her greatest concerns. She was scheduled for single port laparoscopic surgery, resection of the small bowel duplication and primary anastomosis for the preoperative diagnosis of small bowel duplication. Preoperative physical examination showed similar findings as when she was first seen in the outpatient clinic. Routine laboratory investigation results were unremarkable.

Under general anesthesia, a 3 cm midline incision skirt-ing the umbilicus was made. Wound retractor (ALEXIS wound retractor, Applied Medical Resources Co., Rancho Santa Margarita, CA, USA) was placed through the incision. Initial digital palpation through the incision revealed a huge bowel-related mass situated just under the

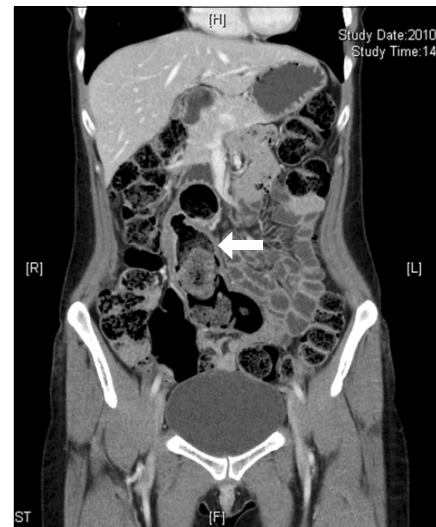

Fig. 2. Coronal view abdominal computed tomography scan showing longitudinal section of colonic duplication (white arrow).

abdominal incision site, containing multiple intraluminal, large, indentable masses that we thought was fecaloma. A colotomy was made and we removed some of the impacted fecaloma so as to facilitate the retrieval of the colon later (Fig. 3). The colotomy was then closed with sutures. The abdominal wound was extended further by 2 cm for better hand access. The entire small and large bowels were examined by hand palpation where upon we found that the bowel-related mass was communicating with the mid-sigmoid colon. A diagnosis of colonic duplication arising from the sigmoid colon was made. The sigmoid colon was mobilized under direct vision and retrieved through the wound retractor along with the colonic duplication (Fig. 4). The colonic duplication was supplied by the sigmoidal branches and wrapped by sigmoid mesocolon. The segment of sigmoid colon to which the colonic duplication connected was resected with GIA 80 (Tyco Healthcare, Norwalk, CT, USA). The colonic duplication was then dissected free from the sigmoid mesocolon. The blood vessels to the colonic duplication were ligated flush to the wall of the colonic duplication to avoid injury to the sigmoidal branches to the native colon. We then divided the final attachment of the blind end of the colonic duplication to the peritoneum overlying the bifurcation of the aorta (Fig. 5). Side-to-side, functionally end-to-end anastomosis using GIA 80 and TA 60 (Tyco Healthcare) was

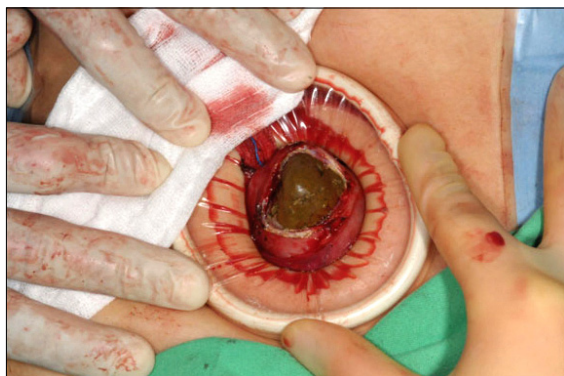

Fig. 3. Fecaloma removed through incision on colonic duplication.

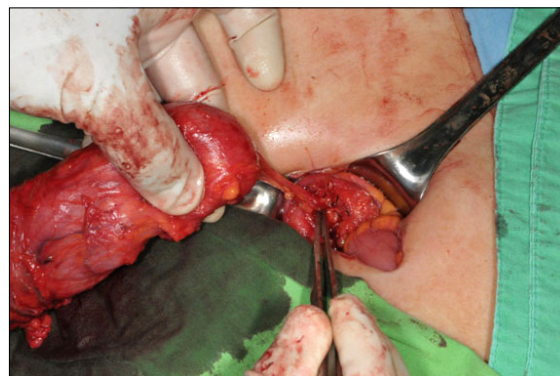

Fig. 5. Final attachment of blind end of colonic duplication to peritoneum overlying aortic bifurcation.

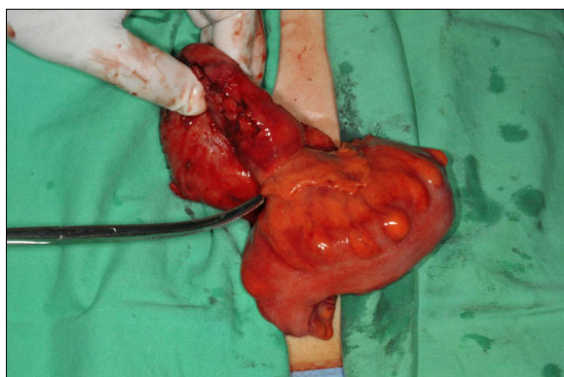


Fig. 4. Sigmoid and colonic duplication extracted through wound retractor. Note that duplication arises from mesenteric border of native colon and closely wrapped around by mesocolon.

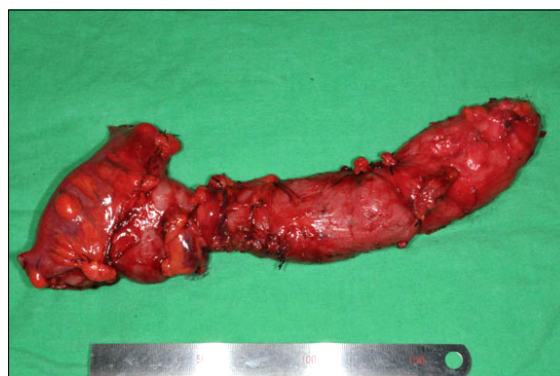

Fig. 6. Resected specimen showing large T-shaped tubular colonic duplication measuring 23 cm in length. Note that feeding vessels were ligated flush to wall of colonic duplication to avoid injury of vessels to native colon.

performed. We used the self-made ‘glove technique’ single port laparoscopic technique to perform a complete examination to look for any concomitant intra-abdominal pathology, peritoneal washout, and to ensure hemostasis. After closure, the length of the wound was 5 cm.

Gross examination of the specimen showed that a colonic duplication measuring 23 cm in length was connected to the native sigmoid colon perpendicularly. This is the T-shaped tubular colonic duplication (Fig. 6). The mucosa of the colonic duplication was normal and devoid of any mucosal lesions. The patient started enteral feeding on the third postoperative day and was discharged on the sixth postoperative day. There were no perioperative complications. The final pathology report was colonic duplication with hypertrophied muscular propria and chronic inflammation.

DISCUSSION

Gastrointestinal duplications are rare anomalies that can occur anywhere along the alimentary tract from tongue to anus [1]. Although theories such as embryonic gut abnormalities resulting in the formation of a diverticulum, a cyst, or twinning of a bowel segment, and environmental insults such as trauma and hypoxia during early fetal life have been suggested, none of which can solely account for all the locations where gastrointestinal duplication develops or for the associated anomalies [1].

More than 80% of gastrointestinal duplications present as acute abdomen before 2 years of age [1,2]. Colonic duplications only account for 13% of all duplications [1]. Two types of colonic duplications have been described in the

literature: tubular (which can be Y- or T-shaped) and cystic. They arise from the mesenteric side of the native bowel [1].

Tubular colonic duplication presenting in adults is rare. In a review of literature between 1876 and 1981 and the case reports by Yousefzadeh et al. [3], there were only 8 patients of tubular colonic duplication aged between 17 to 62 years old. From our literature search, we found only 8 cases of tubular colonic duplication in adult since 1983.

The clinical features of colonic duplication include abdominal mass, vague abdominal pain, chronic constipation possibly due to the direct effects of distension of the duplication or caused by compression of adjacent organs [2,4]. Intestinal duplications can also present with symptoms of its complications such as colovesical fistula, obstruction, intussusceptions and perforation [1,5,6]. Lower gastrointestinal hemorrhage secondary to the ectopic gastric mucosa [1], angiodysplasia [2] and ulcerations [2] within the intestinal duplication have been described. Malignancies have also developed in colonic duplication [7]. Therefore, many literatures recommend resection when intestinal duplication is detected so as to avoid its possible complications.

Plain abdominal film is usually unremarkable although it may show a cystic gas filled structure or a mass displacing the adjacent bowel [7]. Ultrasound is helpful in delineating the mass and the adjacent structures. Colonoscopy or contrast enema may not always be diagnostic. Contrast enema may reveal the luminal communication of the duplication with the colon but smaller duplication may appear similar to diverticulum [8]. Colonoscopic diagnosis can be made if the orifice of the duplication is large and an obvious communication between the duplication and the colon is present but small colonic duplication can be missed [8]. If colonoscopy is performed in this case, the presence of huge impacted fecaloma might obscure visualization of the orifice. CT scan is helpful in the diagnosis of colonic duplication but some literature have reported that duplication cyst in adults mimics other conditions such as pancreatic tumor [9], mesenteric inflammatory mass, or Meckel's diverticulum [10]. Various authors have agreed that the diagnosis of colonic duplication is difficult and is not usually made preoperatively [9]. In the present

case, CT scan was suggestive of small bowel duplication and the correct final diagnosis was only made intra-operatively.

The standard treatment of colonic duplication is traditional laparotomy and surgical resection. It is important that the mesenteric blood vessels are not injured during the dissection of the duplication because the duplication is situated at the mesenteric side of the bowel, and both the duplication and the native colon share the same blood supply [1]. The blood vessels to the colonic duplication should be ligated near to the wall of the duplication. Conventional laparoscopic resection of colonic duplication has been successful in a few cases in recent years [4]. However, resection of a large colonic duplication with impacted multiple large fecaloma and primary anastomosis can be successfully performed by a small single midline incision, insertion of a wound retractor, dissection under direct vision and subsequently self-made 'glove technique' single port laparoscopic surgery as described in this case report. With the same incision, we were still able to perform the dissection by single port laparoscopic technique should we not have been able to dissect the deeper, inaccessible area under direct vision. The additional advantage of tactile sensation, fast postoperative recovery, good wound cosmesis and the practicality of this procedure make this technique an attractive option.

In conclusion, although colonic duplication in adults is rare and the clinical diagnosis is challenging, it should be included in the differential diagnosis for adults presenting with abdominal mass, chronic abdominal pain and constipation. Small midline incision with the help of a wound retractor and self-made 'glove technique' single port laparoscopic surgery can be an attractive hybrid technique in the treatment of a huge benign bowel-related mass such as colonic duplication.

CONFLICTS OF INTEREST

No potential conflict of interest relevant to this article was reported.

REFERENCES

1. Macpherson RI. Gastrointestinal tract duplications: clinical, pathologic, etiologic, and radiologic considerations. *Radiographics* 1993;13:1063-80.
2. Fotiadis C, Genetzakis M, Papandreou I, Misiakos EP, Agapitos E, Zografos GC. Colonic duplication in adults: report of two cases presenting with rectal bleeding. *World J Gastroenterol* 2005;11:5072-4.
3. Yousefzadeh DK, Bickers GH, Jackson JH Jr, Benton C. Tubular colonic duplication - review of 1876-1981 literature. *Pediatr Radiol* 1983;13:65-71.
4. Park YA, Jung EJ, Han SJ. Laparoscopic resection of duplicated sigmoid colon under the guidance of intraoperative colonoscopy. *Surg Laparosc Endosc Percutan Tech* 2005;15:299-301.
5. Payne CE, Deshon GE Jr, Kroll JD, Sumfest J. Colonic duplication: an unusual cause of enterovesical fistula. *Urology* 1995;46:726-8.
6. Odofin O, Yianni L, Al-Talibi A, Gore DM. Perforation of an ileal duplication presenting as an acute abdomen. *Surgeon* 2010;8:117-8.
7. Lee J, Jeon YH, Lee S. Papillary adenocarcinoma arising in a duplication of the cecum. *Abdom Imaging* 2008;33:601-3.
8. Kume K, Sakata H, Otsuki M. Education and imaging. Gastrointestinal: tubular duplication of the descending colon. *J Gastroenterol Hepatol* 2007;22:1553.
9. Carneiro FP, de Nazareth Sobreira M, de Azevedo AE, Alves AP, Campos KM. Colonic duplication in an adult mimicking a tumor of pancreas. *World J Gastroenterol* 2008;14:966-8.
10. Lim GY, Im SA, Chung JH. Complicated duplication cysts on the ileum presenting with a mesenteric inflammatory mass. *Pediatr Radiol* 2008;38:467-70.