

Case Report

Guillain-Barré Syndrome and Posterior Reversible Encephalopathy Syndrome following Spinal Surgery

Yui Sanpei Akira Hanazono Sachiko Kamada Masashiro Sugawara

Department of Neurology, Akita University Graduate School of Medicine, Akita, Japan

Keywords

Guillain-Barré syndrome · Posterior reversible encephalopathy syndrome · Surgery · Intravenous immunoglobulin G

Abstract

Guillain-Barré syndrome (GBS) typically occurs after gastroenteritis and respiratory tract infection, but surgery has also been considered one of the triggers. Posterior reversible encephalopathy syndrome (PRES) is a rare complication of GBS. A normotensive female in her 70s presented ascending paralysis and frontal-parieto-occipital subcortical lesions with intermittent hypertension after spinal surgery. Nerve conduction studies revealed demyelinating polyneuropathy. The patient's brain lesions disappeared with amelioration of hypertension. She was diagnosed with the demyelinating form of GBS and PRES caused by intermittent hypertension. Intravenous immunoglobulin G (IVIG) improved her symptoms without exacerbation of the PRES. Surgery can be a trigger of GBS, and GBS can cause PRES by hypertension and present as central nervous lesions. It is important to treat hypertension before using IVIG when PRES is suspected as a complication of GBS, since the encephalopathy can be exacerbated by IVIG. There may be more undiagnosed cases of the coexistence of GBS and PRES after surgery because surgery itself can also cause PRES. Proper control of blood pressure and confirmation of negative central nervous lesions are required to treat GBS patients with IVIG safely.

© 2019 The Author(s)
Published by S. Karger AG, Basel

Introduction

Guillain-Barré syndrome (GBS) is the most common and most severe acute neuropathy, and about 100,000 people develop the disorder every year worldwide [1]. GBS typically occurs after gastroenteritis and respiratory tract infection, but surgery has also been considered one of the triggers [2–6]. Central nervous complications and brain lesions rarely occur in GBS alone [7]. Here, we report postoperative GBS, which presented as central nervous lesions caused by posterior reversible encephalopathy syndrome (PRES) in the initial phase of GBS. Amelioration of hypertension allowed us to treat the patient with intravenous immunoglobulin G (IVIg) safely.

Case Presentation

A normotensive female in her 70s with a 20-year history of rheumatoid arthritis treated with methotrexate and salazosulfapyridine developed numbness of the left thigh 1 year before. Spinal magnetic resonance imaging MRI revealed a canal stenosis at the L2/3 level. She received corrective surgery because of intermittent claudication. After surgery, numbness temporarily disappeared. However, on the fifth day after surgery, she presented with low back pain and numbness in her bilateral distal extremities. On the eighth day, the patient complained of distal weakness and difficulty in walking. On the twelfth day, impaired consciousness (GCS 13) and nausea appeared. Left mild hemiparesis was observed on neurological examination along with intermittent hypertension (180/130 mm Hg) that lasted about 1 week. A brain MRI showed bilateral subcortical altered signal intensities involving U-fibers of the frontal-parieto-occipital lobes. They were hyperintense on T2-weighted imaging (T2WI) and fluid-attenuated inversion recovery (FLAIR), hypointense on T1-weighted imaging (T1WI) with no diffusion restriction and no gadolinium enhancement (Fig. 1a–f). A spine MRI showed no new lesions. Routine laboratory studies revealed severe hyponatremia (117 mEq/L). She regained consciousness after sodium replacement, but the subcortical lesions had not disappeared. Over the next week, she acutely developed severe muscle weakness of the bilateral extremities, predominantly in the lower limbs. Cerebrospinal fluid (CSF) demonstrated cyto-protein dissociation (CSF protein of 1,216 mg/dL with 6 white cell counts). Since methotrexate-associated B-cell lymphoproliferative diseases, collagen diseases (including sarcoidosis and angitis), progressive multifocal leukoencephalopathy, and combined central and peripheral demyelination (CCPD) were suspected, she was transferred to our hospital. On admission, her blood pressure was 142/97 mm Hg, and her pulse was 55 bpm. Her Intermittent hypertension had already ameliorated without any treatment. On neurological examination, her extra-ocular movements were intact, but she had left central facial palsy and mild dysphasia. A severe muscle weakness of the bilateral extremities was observed, especially in the lower limbs (MMT 0). A hypesthesia of the distal extremities and areflexia of the lower limbs were also observed. The patient had constipation but did not manifest respiratory disturbance. Her nerve conduction studies revealed demyelinating polyneuropathy according to the Ho et al. criteria [8]. The motor nerves showed prolonged distal latency, decreased motor nerve conduction velocity in the cubital channel, increased F-wave latency, and conduction blocks. The left tibial nerve showed temporal dispersion. No sensory nerve action potentials were observed. Anti-viral, anti-nuclear, anti-neutrophil cytoplasmic antibodies, ACE, sIL-2R, M-protein in serum, and JC virus in CSF were absent except rheumatoid factor and the anti-CCP

antibody. A whole-CT scan revealed no tumor or lymph node swelling. Antiganglioside antibodies were not detected.

She was clinically and electrophysiologically diagnosed with the demyelinating form of GBS and treated with IVIG (400 mg/kg/day over 5 days). Considering the possibility of CCPD, we later started steroid pulse therapy (methylprednisolone 1,000 mg/day over 5 days), but all white matter lesions disappeared before the steroid was administered (Fig. 1g–i). She was diagnosed with GBS and PRES. We did not examine antibodies associated with CCPD, but the disorder is rare among the elderly in Japan [9], and this clinical course of brain lesions was not typical. Hyponatremia was caused by the syndrome of inappropriate secretion of antidiuretic hormone (SIADH) related to GBS and was improved by water restrictions. After treatment, she was quickly able to move her facial muscles and, gradually, her limbs.

Discussion

This is the first case where GBS and PRES occurred together in relation to surgery. This patient's course provided two important clinical suggestions.

First, surgery can be a trigger of GBS, and GBS can cause PRES by hypertension and present as central nervous lesions. A few published retrospective case series reported that between 5.8 and 19.4% of the patients with GBS had experienced a surgical procedure during the preceding 6 weeks [3, 4]. A 6-fold to 13-fold relative risk of GBS after a surgical operation has been shown in previous studies [2, 3]. Recent French nationwide data revealed a slightly weaker association between surgery and GBS but showed that surgical procedures on bones (vertebrae and limbs) and digestive organs were significantly associated with GBS [6]. Several mechanisms have been proposed to explain the onset of GBS after surgery. It has been postulated that surgery may alter the balance of the immune system and lead to transient immunosuppression by an activation of the endocrine stress systems [5]. This immunosuppression has also been hypothesized to promote clinical and subclinical infections that could induce GBS by the theory of crossreactive antibodies [2]. The intraoperative release of antigens and autoimmunization to these antigens has also been considered as a possible mechanism [5].

PRES is commonly associated with acute hypertension, eclampsia, vasculitis, metabolic disturbances, thrombotic thrombocytopenic purpura, hemolytic uremic syndrome, chemotherapeutic drugs, and immunomodulatory therapy. The typical MRI finding of PRES is reversible, symmetrical, and posterior subcortical vasogenic edema that appears hypointense on T1WI and hyperintense on T2WI and FLAIR [10]. It typically involves the parieto-occipital white matter in vascular watershed areas [10] as was seen in our case. These lesions completely resolve over days to weeks with treatment of the underlying cause.

PRES is a rare complication of GBS, and only a few cases have been reported. Central complications such as altered sensorium and seizures rarely occur in GBS alone [7]. It is especially rare that PRES develops prior to IVIG therapy in GBS [11]. The exact mechanism of PRES itself remains unclear. The proposed mechanisms include endothelial dysfunction, failure of cerebral blood flow (CBF) autoregulation, and subsequent ischemia by vasospasm [12]. Impaired CBF autoregulation is seen in the setting of acute hypertension in cases of autonomic dysfunction and eclampsia. Hypertension raised capillary filtration pressure, resulting in secondary endothelial cell damage and vasogenic edema. These are also the possible mechanisms of PRES caused by autonomic dysfunction in GBS patients. A review of PRES in GBS reported that 92% of the cases were female, and 92% were over 55 years old [11]. They postulated the

possibility of increased sensitivity to dysautonomia in this patient group. Our case also belongs to this group, and autonomic dysfunction caused by GBS might induce PRES.

Second, it is important to treat hypertension before using IVIG when PRES is suspected as a complication of GBS, since the encephalopathy can be exacerbated by IVIG. It is postulated that IVIG can lead to hyperviscosity, hypercoagulopathy, and platelet hyperactivity [7], resulting in endothelial dysfunction and failure of CBF autoregulation. In our case, hypertension was already ameliorated without any treatment in the week after the onset of limb weakness, and IVIG treatment was finished without exacerbation of PRES.

In addition, surgery can cause PRES through the inflammatory process and by fluctuating blood pressure. The coexistence of GBS and PRES has been thought to be rare, but there might be more cases after surgery because we do not routinely perform brain MRIs in GBS patients. Two reported GBS patients had incidental findings of radiographic evidence of PRES without clinical symptom suggesting this encephalopathy [13, 14]. Therefore, subclinical impaired CBF autoregulation may be more common in GBS than has been documented [11]. In the present case, disturbance of consciousness caused by SIADH led us to identify the lesions of PRES. The lesions would have been overlooked if a brain MRI had not been performed.

In conclusion, we should be aware that surgery can cause GBS, and be aware that surgery and the autonomic dysfunction of GBS can cause PRES, before we treat GBS patients with IVIG. It is important to consider the coexistence of GBS and PRES and perform brain MRIs when hypertension or central nervous symptoms such as altered consciousness appear, especially in females over the age of 55 years after surgery on bones. Early identification of PRES is important to avoid adverse effects when administering IVIG. Proper control of blood pressure and confirmation of negative central nervous lesions are required to treat GBS patients with IVIG safely.

Acknowledgement

The authors thank Dr. Kusunoki (Department of Neurology, Faculty of Medicine, Kindai University) for the measurement of antiganglioside antibodies.

Statement of Ethics

Informed consent was obtained from the patient for publication of this case report and any accompanying images and data.

Disclosure Statement

The authors have no conflicts of interest to declare.

References

- 1 Willison HJ, Jacobs BC, van Doorn PA. Guillain-Barré syndrome. *Lancet*. 2016 Aug;388(10045):717–27.
- 2 Gensicke H, Datta AN, Dill P, Schindler C, Fischer D. Increased incidence of Guillain-Barré syndrome after surgery. *Eur J Neurol*. 2012 Sep;19(9):1239–44.
- 3 Sipilä JO, Soilu-Hänninen M. The incidence and triggers of adult-onset Guillain-Barré syndrome in southwestern Finland 2004–2013. *Eur J Neurol*. 2015 Feb;22(2):292–8.

- 4 Yang B, Lian Y, Liu Y, Wu BY, Duan RS. A retrospective analysis of possible triggers of Guillain-Barre syndrome. *J Neuroimmunol*. 2016 Apr;293:17–21.
- 5 Rashid A, Kurra S, Lavelle W. Guillain-Barré syndrome after revision lumbar surgery: a case report. *Cureus*. 2017 Jun;9(6):e1393.
- 6 Rudant J, Dupont A, Mikaeloff Y, Bolgert F, Coste J, Weill A. Surgery and risk of Guillain-Barré syndrome: A French nationwide epidemiologic study. *Neurology*. 2018 Sep;91(13):e1220–7.
- 7 Nabi S, Rajput HM, Badshah M, Ahmed S. Posterior reversible encephalopathy syndrome (PRES) as a complication of Guillain-Barre' syndrome (GBS). *BMJ Case Rep*. 2016 Aug;2016:bcr2016216757.
- 8 Ho TW, Mishu B, Li CY, Gao CY, Cornblath DR, Griffin JW, et al. Guillain-Barré syndrome in northern China. Relationship to *Campylobacter jejuni* infection and anti-glycolipid antibodies. *Brain*. 1995 Jun;118(Pt 3):597-605.
- 9 Ogata H, Matsuse D, Yamasaki R, Kawamura N, Matsushita T, Yonekawa T, et al. A nationwide survey of combined central and peripheral demyelination in Japan. *J Neurol Neurosurg Psychiatry*. 2016 Jan;87(1):29–36.
- 10 Hobson EV, Craven I, Blank SC. Posterior reversible encephalopathy syndrome: a truly treatable neurologic illness. *Perit Dial Int*. 2012 Nov-Dec;32(6):590–4.
- 11 Chen A, Kim J, Henderson G, Berkowitz A. Posterior reversible encephalopathy syndrome in Guillain-Barré syndrome. *J Clin Neurosci*. 2015 May;22(5):914–6.
- 12 Fugate JE, Claassen DO, Cloft HJ, Kallmes DF, Kozak OS, Rabinstein AA. Posterior reversible encephalopathy syndrome: associated clinical and radiologic findings. *Mayo Clin Proc*. 2010 May;85(5):427–32.
- 13 Parmentier C, Vandermeeren Y, Laloux P, Mormont E. Asymptomatic posterior reversible encephalopathy revealed by brain MRI in a case of axonal Guillain-Barré syndrome. *Clin Neurol Neurosurg*. 2012 Sep;114(7):1006–9.
- 14 Barbay M, Arnoux A, Lebreton C, Leclercq C, Bugnicourt JM. Clinically silent posterior reversible encephalopathy in Guillain-Barre syndrome. *Can J Neurol Sci*. 2013 Mar;40(2):267.

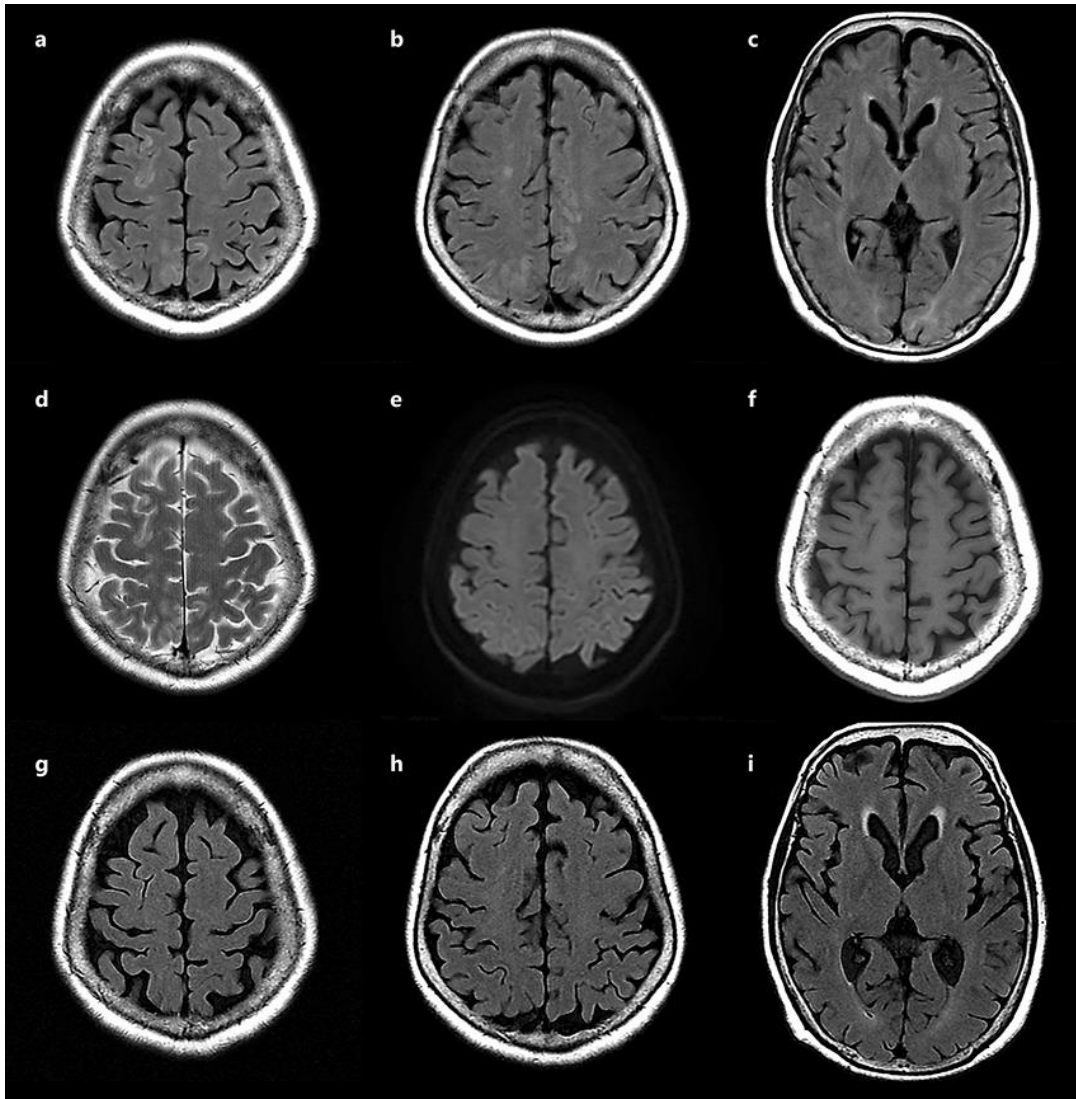


Fig. 1. Brain MRI of the patient. **a–c, g–i** FLAIR. **d** T2WI. **e** DWI. **f** T1WI. **a–f** At the onset. Bilateral subcortical altered signal intensities involving U-fibers of the frontal-parieto-occipital lobes are shown. **g–i** Follow-up MRI performed before steroid administration. All lesions had disappeared.