

Correspondence

Korean J Ophthalmol 2021;35(6):484-485
<https://doi.org/10.3341/kjo.2021.0008>

Branch Retinal Artery Occlusion in Patient with COVID-19: Case Report

Dear Editor,

There are many reports of coronavirus disease 2019 (COVID-19) patients presenting with arterial (stroke, myocardial infarction) and venous thrombosis (deep vein thrombosis, pulmonary thromboembolism, venous sinus thrombosis) [1]. However, few of the studies documenting thromboembolic complications in COVID-19 patients have presented data on ocular circulation. Many mechanisms can cause retinal artery occlusion, including exogenous or endogenous embolization, thrombosis, vasculitis, and vasospasm, all of which can occur alone or in combination. Retinal artery occlusions in young adults occur secondary to various pathological conditions. In retinal artery occlusion in young patients, unlike the elderly, the most common occlusion mechanism is embolism from the carotid artery, cardiac embolisms, and various hypercoagulable states that lead to thrombosis and are more common in younger patients. COVID-19 infection can lead to severe complications such as arterial and venous obstruction, microinfarctions, and multi-organ failure [2]. We report a young patient with COVID-19 pneumonia who developed branch retinal artery occlusion (BRAO).

A 34-year-old female patient with bilateral diffuse thickening of the interstitial structures and multiple ground-glass opacities on chest X-ray was diagnosed with mild COVID-19-related pneumonia. She had a positive severe acute respiratory syndrome coronavirus 2 (SARS-CoV-2) polymerase chain reaction test on July 31, 2020. She was

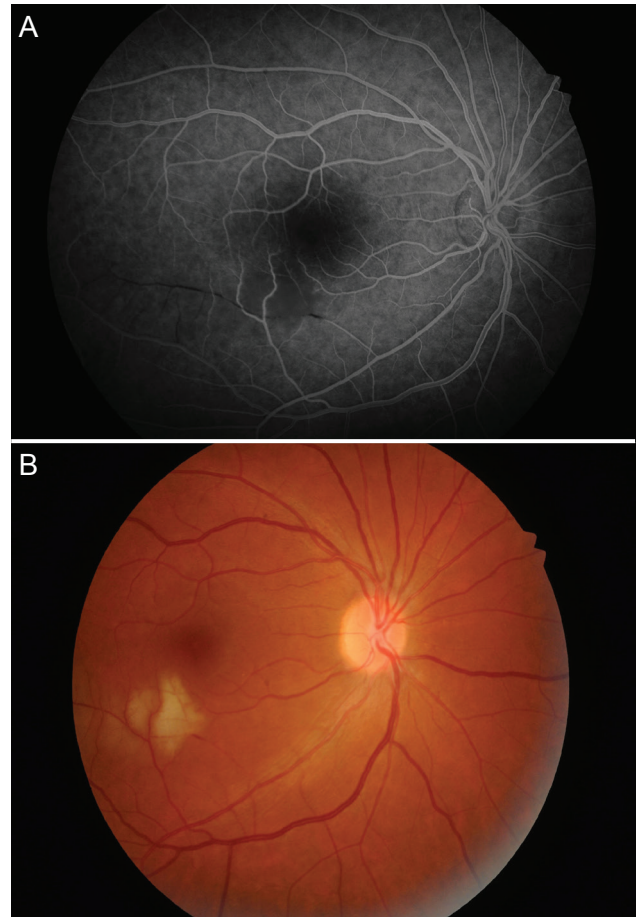


Fig. 1. Fluorescein angiography. (A) Right eye showing a hyper-reflectivity area delineates the embolus. (B) Color photograph of the right eye showing retinal whitening with emboli blocking. Written consent of the patient was obtained for the publication of this study.

hospitalized for 17 days and was in intensive care for 2 days. She was treated with acetylcysteine, vitamin C, levofloxacin, dexamethasone, stem cells, and plasma. Her clinical condition improved, and she was discharged from the hospital with enoxaparin sodium, hydroxychloroquine, and favipiravir. On November 13, 2020, the patient presented to the emergency department complaining of acute infe-

Received: January 11, 2021 Final revision: July 30, 2021
 Accepted: August 2, 2021

© 2021 The Korean Ophthalmological Society

This is an Open Access article distributed under the terms of the Creative Commons Attribution Non-Commercial License (<http://creativecommons.org/licenses/by-nc/3.0/>) which permits unrestricted non-commercial use, distribution, and reproduction in any medium, provided the original work is properly cited.

rior field visual loss in the right eye 8 days after completing her medical treatment. The patient was referred to Ataturk University Hospital, Erzurum, Turkey with a prediagnosis of BRAO on November 17, 2020.

No remarkable findings were observed on magnetic resonance imaging or magnetic resonance angiography of the brain and neck on our physical examination. Coagulation and hematological tests revealed within the normal range for protein C, protein S, prothrombin time, partial thromboplastin time, international normalized ratio, and antithrombin III levels. C-reactive protein, lupus anticoagulant, fibrinogen, D-dimer, and ferritin levels were slightly abnormal. Systemic physical examination and chest X-ray were normal. The medical and family history of the patient was unremarkable about malignancy, thromboembolic disease, and smoking except for morbid obesity. On ophthalmologic examination, visual acuity was 10 / 10 in both eyes. Color retinal photography and fundus fluorescein angiography showed inferotemporal BRAO (Fig. 1A, 1B). Confrontation visual field testing revealed a visual field defect in the right eye and a normal visual field in the left eye. The patient received hyperbaric oxygen therapy for 10 days and was discharged from the hospital. At follow-up 2 weeks later, she had normal visual acuity, visual field, and fundus examination results.

Combating COVID-19 is challenging due to the complex pathogenesis of SARS-CoV-2 infection. Although SARS-CoV-2 mainly affects the upper and lower respiratory tract, it can also affect other organ systems. Early data from the disease suggested that host response to this novel coronavirus leads to overproduction of proinflammatory cytokines, severe endothelial damage, and generalized vascular manifestations. Clinical reports have shown that the association between severe COVID-19 and viral coagulopathy can result in pulmonary embolism caused by arterial, venous, and microvascular thrombosis [3]. A case of presumed vasculitic retinal vein occlusion secondary to COVID-19 was reported in a 52-year-old male patient who presented with decreased vision in the left eye 10 days after a positive SARS-CoV-2 test. As the patient had no comorbidities such as diabetes, hypertension, or tuberculosis, the authors cited vasculitis as the most likely pathogenic mechanism. They also noted that systemic vasculitis has been reported extensively in association with COVID-19 and attributed it to type 3 hypersensitivity (a complex immune disease) and the resultant “cytokine storm.” They recommended SARS-CoV-2 testing for patients who present with retinal vasculi-

tis and no known risk factors [4].

Montesel et al. [5] reported that COVID-19 causes inflammation-induced homeostatic changes in arterial circulation that predispose to thrombotic disease. In addition, they concluded from post-mortem analysis that the viral infection caused endothelial dysfunction and a procoagulant state in the vascular tissues of all organs. They showed that retinal artery occlusion could occur as a complication of COVID-19, possibly through hypercoagulation and inflammatory pathways [5].

Although the retinal vascular tissue damage mechanism is not clear, this case supports the thrombo-inflammatory state as a potential cause of retinal artery occlusion in COVID-19 patients.

Orhan Ateş, Mustafa Yıldırım

Department of Ophthalmology, Medical School of Ataturk University, Erzurum, Turkey
E-mail (Orhan Ateş): orhan.ates@atauni.edu.tr

Kenan Yıldırım

Iğdir Public Hospital, Iğdir, Turkey

Conflict of Interest

No potential conflict of interest relevant to this article was reported.

References

1. Anthi A, Konstantonis D, Theodorakopoulou M, et al. A severe COVID-19 case complicated by right atrium thrombus. *Am J Case Rep* 2020;21:e926915.
2. Blaise P, Duchateau E, Duchesne B, et al. Retinal vascular occlusions: diagnosis and management. *Rev Med Interne* 2004;25:881-90.
3. Pons S, Fodil S, Azoulay E, Zafrani L. The vascular endothelium: the cornerstone of organ dysfunction in severe SARS-CoV-2 infection. *Crit Care* 2020;24:353.
4. Sheth JU, Narayanan R, Goyal J, Goyal V. Retinal vein occlusion in COVID-19: a novel entity. *Indian J Ophthalmol* 2020;68:2291-3.
5. Montesel A, Bucolo C, Mouvet V, et al. Case report: central retinal artery occlusion in a COVID-19 patient. *Front Pharmacol* 2020;11:588384.