

Review Article

Macular Hole in Myopic Eyes: A Narrative Review of the Current Surgical Techniques

Chiara De Giacinto , Marco R. Pastore, Gabriella Cirigliano, and Daniele Tognetto

Eye Clinic, Department of Medicine, Surgery and Health Sciences, University of Trieste, Trieste, Italy

Correspondence should be addressed to Chiara De Giacinto; chiaradegiacinto@gmail.com

Received 22 November 2018; Accepted 21 February 2019; Published 11 March 2019

Guest Editor: Claudio Azzolini

Copyright © 2019 Chiara De Giacinto et al. This is an open access article distributed under the Creative Commons Attribution License, which permits unrestricted use, distribution, and reproduction in any medium, provided the original work is properly cited.

Macular hole (MH) in myopic eyes is a disease arising from complex tractional forces exerted by vitreomacular interface, epiretinal tissue, and progressive scleral ectasia of the posterior ocular globe wall. This retinal disease requires vitreoretinal treatment for its repair, and the surgical intervention remains a challenge also for experienced surgeons. The aim of this review is to describe the current knowledge regarding the pathogenesis of MH in myopic eyes and to detail novel surgical techniques and technological advancements in its surgical management.

1. Introduction

Idiopathic macular hole (MH) is an important cause of central visual loss [1] characterized by a round full-thickness defect in the center of the macular area involving the anatomical fovea [2, 3]. The estimated prevalence in the general population is approximately 3.3 per 1000 people [4, 5], with a cumulative incidence of MH formation of 41.1 cases per 100 000 person-years [6]. This incidence increases with age, and the disease usually affects individuals in their sixth or seventh decade of life [7]. Females have a 64% increased risk of being diagnosed with MH when compared with males [6]. MH is a common complication in pathological myopic eyes with an axial length greater than 26.5 mm and/or a refraction greater than -6.00 diopters [8, 9], and a prevalence of 8.4% has been reported [10]. The incidence of myopic MH is greater in Asian ethnicity compared to Caucasian or black individuals due to the high prevalence of myopic refractive defect in Asian population [6].

For many years, MH was considered an untreatable disease resulting in irreversible vision loss. In the early 90s, new surgical strategies to treat this anatomical macular defect in order to improve the visual acuity were described. The surgical procedure consisted of three-port pars plana vitrectomy (PPV) with posterior hyaloid removal in combination with intraocular gas tamponade to allow the

flattening and the repositioning of MH edges [11, 12]. A remarkable success rate and a clear benefit from this type of surgical management were reported [13–16].

Although pars plana vitrectomy with posterior hyaloid removal, internal limiting membrane (ILM) peeling, long-acting gas tamponade, and face-down positioning is still the gold standard for a successful closure of idiopathic MH, the treatment of large, persistent, or myopic MH remains a challenge [17–19]. Nowadays, several methods have been proposed to allow high rate of success, particularly for the abovementioned MH such as the inverted ILM flap [20], inverted ILM flap insertion [21] with or without blood coverage of the hole [22], temporal or superior single-layer inverted ILM flap [23, 24], free ILM insertion [25], and double [26] or multiple free ILM flap insertion [16] into the MH.

The purpose of this review is to describe the current knowledge regarding the pathogenesis of MH in myopic eyes and to detail novel surgical techniques and technological advancements in the surgical management of this retinal disease.

2. Pathogenesis

The biomicroscopic identification of MH in highly myopic eyes may be difficult due to several factors such as the typical

low contrast between the anatomical foveal defect and the retinal pigmented epithelium (RPE), the chorioretinal atrophy, or the presence of a deep posterior staphyloma [27].

The introduction of optical coherence tomography (OCT), which provides an *in vivo* analysis of the relationship between the macula and the vitreous, has allowed identifying the perifoveal vitreous changes that may lead to MH formation. In particular, OCT is able to detect the localized adhesion between vitreous cortex and fovea, the incomplete posterior vitreous detachment associated with a full-thickness MH [28–30] and the ILM contraction that creates a tangential traction responsible of MH enlargement [19].

The anteroposterior traction caused by vitreous cortex on the fovea leads to MH formation [28–30]. It is widely accepted that the genesis of this dynamic force is localized in the precortical liquified vitreous pocket, immediately in front of the macula area, resulting in a passive contraction of the posterior hyaloid undetached from the fovea [31, 32]. Subsequently, the tangential traction due to the ILM stiffening promotes the progressive MH enlargement.

In contrast, in high myopic eyes, MH formation is related to more complex pathogenetic mechanisms [33–38]. In addition to the anteroposterior traction caused by the strong adhesion of vitreous cortex and to the tangential traction from the tightening of the ILM, an important role is reserved to the abnormal growth of myopic eyes that may result in the development of posterior staphyloma (PS) defined as a progressive scleral ectasia of the posterior ocular globe wall (Figure 1(a)) [39].

The PS introduces new pathogenetic forces in myopic MH formation and increases the spectrum of tractional forces in relation to different depths and location of the scleral ectasia with respect to the macular area. The centripetal vector forces are more relevant in case of deeper PS compared to the flatter staphyloma [40]. Due to the relative inelasticity of the inner retinal layers and retinal vessels, deep PS promotes a progressive retinal split which initially results in the development of a myopic foveoschisis (FS) (Figure 1(b)) and finally may lead to a retinal detachment involving the posterior pole.

In the case of flat PS, vitreoretinal tractions are not sufficient to produce the concomitant FS or retinal detachment [41, 42], and the pathogenetic mechanism of MH formation seems to be similar to those of emmetropic eyes [43].

Recently, several mechanisms regarding the development of MH in highly myopic patients were analyzed, and different pathways of MH formation were reported [44]. In detail, a normal foveal depression with abnormal vitreoretinal relationship characterized the first pathway. According to the main tractional forces recognized, two different processes can be distinguished. Similar to MH in emmetropic eyes, in high myopic eyes, the anteroposterior vitreomacular traction (VMT) induces a vitreomacular separation with the disruption of the inner laminar layers and the formation of inner foveal cysts with or without small foveal detachment (Figure 1(c)). The rupture of intraretinal cysts results in a disruption of outer laminar layers followed

by the progression in a full-thickness MH. Alternatively, the posterior hyaloid may separate from the fovea, and the development of a tangential traction exerted from the surrounding preretinal membrane leads to a lamellar MH formation. The progressive foveal disruption results in a full-thickness MH [44].

A second pathway is characterized by the presence of FS that may occur with or without macular detachment. FS is not an uncommon finding in highly myopic eyes (9–34%) [43] and is believed to be one of the main causes of MH formation in these patients [45–47]. A macular schisis promotes a tangential or multidirectional traction with the development of lamellar MH. The continuous traction caused by the preretinal membrane induces the evolution in a full-thickness MH [44]. When macular schisis occurs with foveal detachment, an outer laminal dehiscence can be observed (Figure 1(d)). If preretinal traction induces inner laminar dehiscence, a full-thickness MH may develop with a macular retinal detachment (Figure 1(e)) [44, 48].

Finally, the third pathway includes MH with concomitant chorioretinal atrophy or underlying macular scar. Both progressive retinal thinning over the lesion and tangential traction promote the MH formation that may occur adjacent to the margins or within the lesion area [44].

In a recent report, Lai et al. [49] analyzed the lamellar hole-associated epiretinal proliferation (LHEP) in lamellar MH and full-thickness MH in high myopic eyes. This epiretinal proliferation is a noncontractile membrane localized at the edge of a deep and wide retinal defect. Several OCT studies have demonstrated the tight connection between the inner retinal tissue and LHEP [50] characterized by a homogeneous mound at OCT examination [51]. Two morphological LHEP findings, typical of highly myopic eyes, were described: the broad LHEP extension and LHEP-posterior hyaloid (PH) adhesion. In eyes with high myopia, a broader extension of LHEP ($>1.500\ \mu\text{m}$ from the foveal center) was observed when compared with nonhighly myopic patients. Moreover, a greater prevalence of LHEP-PH adhesion in eyes with high myopia was detected. The LHEP-PH adhesion was described as the growth of the LHEP along the PH surface when the PH remains attached to the margins of the MH and to the space between the hole edge and the hyaloid.

Although several mechanisms of MH formation are clearly described in the literature, the exact evolution of this retinal disease in myopic eyes is not always predictable and rapid changes from a typical configuration to another pattern may be observed [44].

Figure 1 shows different myopic macular hole patterns.

3. Surgical Techniques

Since the introduction of three-port PPV with gas tamponade in the 90s [11, 12], several surgical strategies have been developed for the MH repair in high myopic eyes, including silicone oil tamponade, episcleral posterior buckling, suprachoroidal buckling, and scleral shortening technique [52–55].

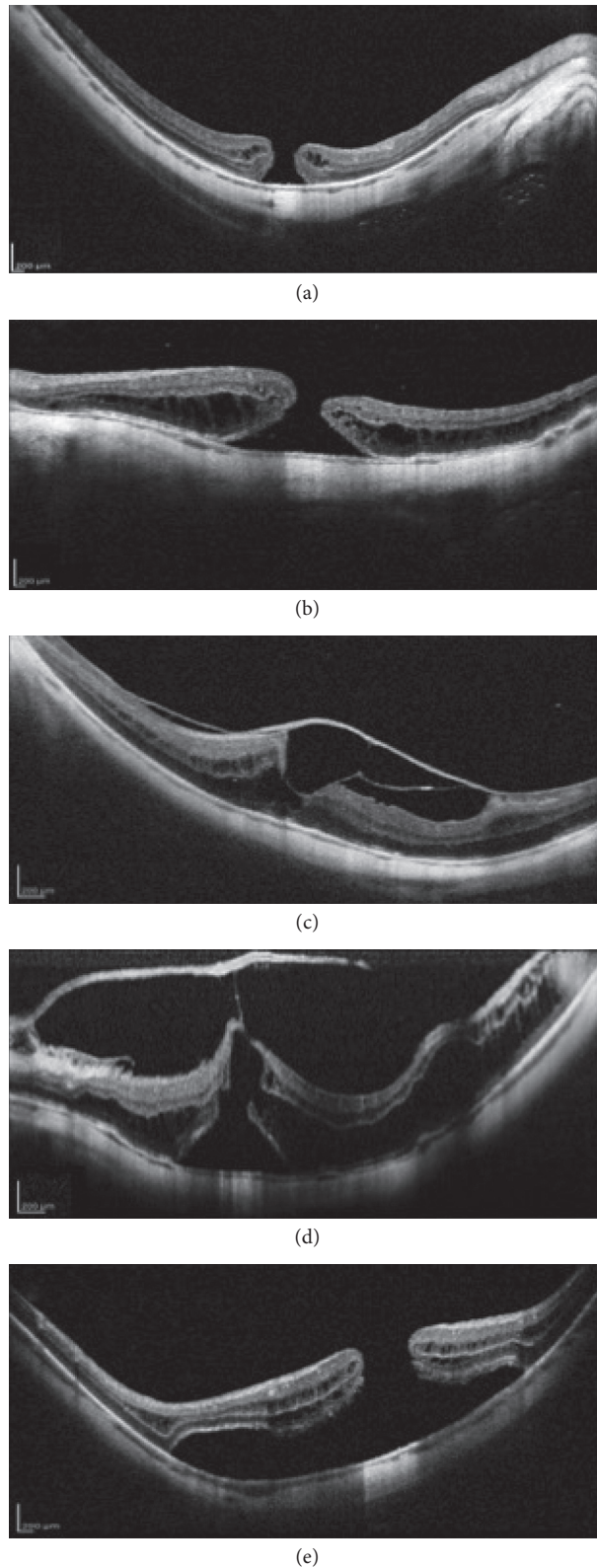


FIGURE 1: Different myopic macular hole (MH) patterns. (a) Full-thickness MH with intraretinal cysts in deep posterior staphyloma. (b) Full-thickness MH with perilesional foveoschisis. (c) Vitreomacular separation with vitreofoveal adhesion which causes the dehiscence of the inner retinal layers and the formation of inner foveal cysts. (d) Vitreomacular traction with impending macular hole associated with diffuse macular schisis and foveal detachment which results in outer retinal layers disruption. Note: the important traction exerted by the thickened posterior hyaloid undetached from the fovea and the consequential retinal split due to the deep posterior staphyloma. (e) Complete disruption of the inner and outer retinal layers resulting in macular retinal detachment.

Although PPV with ILM peeling and intraocular gas tamponade leads to an anatomical closure rate more than 90% for idiopathic MH [56], in highly myopic eye the successful closure of MH varies considerably from 60% to 100% and some patients require multiple treatments in order to achieve the closure of the hole [20, 57]. The aim of vitrectomy is to release all vitreoretinal tractions from the vitreous and the epiretinal tissue and to reduce macular stretching caused by the ILM in order to promote retinal elongation and adaptation to the posterior staphyloma, if present.

In highly myopic eyes, the ILM appears thin, sticky, and strongly adhered to the retinal surface; moreover, preretinal membranes showed a multilayered and heterogeneous aspect composed of vitreous cortex residuals, ERM, and ILM [58]. Because of these features, ILM tends to break into several little sections rather than peel off in a sheet during its surgical removal [59]. This aspect may lead to difficult and dangerous ILM peeling because the subsequent ILM regrasping is associated with a higher risk of iatrogenic retinal breaks [60].

To avoid these difficulties, several tools have been introduced in vitreoretinal surgery for the treatment of myopic MH helping the surgeons to perform a safe and effective procedure. The chromovitrectomy helps to better identify the vitreous and the epiretinal membranes in myopic eyes. The use of triamcinolone acetonide increases the visualization of the vitreous body and vitreous cortex that remains tightly adhered to the retina plane in high myopic patients. Furthermore, the introduction of vital dyes allows to stain the posterior pole and correctly recognized the ERM (trypan blue) and the ILM (brilliant blue, lutein/zeaxanthin + brilliant blue). Moreover, the use of specific light filters can provide a better visualization of stained ILM in myopic eyes [61], reducing the retina light toxicity [62].

In order to avoid the inadvertent migration of vital dyes into the subretinal space, several substances have been used during the dye-assisted ILM peeling in MH surgery [63–65]. To promote the gentle injections of vital dyes and heavy liquids into the vitreous cavity and to avoid fluid turbulence, several devices with a steady and slow jet have been introduced [66]. Specific dual-bore cannula with a side port for fluid injection prevents the risk of retinal injury caused by a fluid jet stream and promotes a faster pressure relief during injection by multiple fluid egress vents [67].

The microscope-integrated intraoperative OCT in MH surgery allows a real-time visualization of the vitreoretinal interface [68]. This device provides an imaging of foveal architecture during the tissue-instruments interaction helping the surgeon to release in a safe manner the VMT and to identify and remove residual ERM or ILM if present [69].

In high myopic MH, several factors may influence the anatomical and functional outcomes after surgery [44] including the increased axial length, the retinal shortening over an elongated sclera [57], the presence of posterior staphyloma [70], the presence of severe traction maculopathy [63], the presence of foveoschisis [41], and the intraoperative peeling of rigid and stiff ILM [71].

The extension of ILM peeling is a matter of controversy. For a successful MH closure, no clear guidelines regarding the minimum area of ILM peeling are available [72]. Due to the adhesion between the ILM and the retinal nerve fiber layer—ganglion cell layer complex, the peeling maneuver might damage these inner retinal layers with consequently poor postoperative visual acuity [73]. Thus, a smaller ILM peeling might be more respectful of the retinal nerve fiber layer—ganglion cell layer complex [74]. On the other hand, a wider peeling extended up to the vascular arcades might be useful in order to reduce the complex tractional forces in the myopic retina [75].

However, ILM peeling in myopic FS is currently under debate. Due to thin central foveal tissue, an iatrogenic full-thickness MH could develop during ILM removal. The risk of this complication ranges from 16.7 to 20.8% [76] and significantly increases in case of outer lamellar macular hole [77]. To reduce the risk of this complication and to preserve the epifoveal ILM, foveal-sparing ILM peeling procedures were introduced [76–79]. Although these techniques have showed a better success rate and visual outcome when compared to the classic ILM peeling, no consensus regarding the ILM area to be preserve was developed. A range from 300 to 1000 μm diameter was reported in different studies [77]. Anatomical results showed the primary success rate limited to 50–73.3% with vitrectomy, ILM peeling, and gas tamponade in high myopic eyes [80].

Recently, for persistent myopic MH, the inverted ILM flap technique was introduced [81]. In this procedure, the remnant of an incomplete ILM peeling is left and then inverted inside the macular hole to provide a scaffold for MH closure [81]. At the beginning, many surgeons believed necessary to insert the flap into the hole like a plug. Now it is thought sufficient to cover the hole with the peeled ILM flap in order to obtain a division between the vitreous cavity and the intraretinal spaces and to promote the MH repair mechanism [82]. The original procedure consisted of circumferentially 2-disc-diameter ILM peeling around the MH to preserve the adhesion between the inner ILM outline and the MH edges. Afterwards, the ILM flap was folded and gently positioned inside the MH [81]. For ILM flap manipulation and positioning, different techniques have been described to prevent the flap dislocation during the fluid-air exchange or in the postoperative period. These strategies include the use of viscoelastic [83] or perfluorocarbon [84] before balanced saline solution-air exchange, fluid-air exchange with low intraocular pressure and passive aspiration [75], and the addition of autologous serum [14, 22] or platelet-rich plasma [85]. Platelet-rich plasma seems to achieve better anatomical results compared to the autologous serum due to its greater adhesiveness to the edges of the hole [82].

In order to increase the ILM flap maneuverability and to reduce its displacement, several studies suggested the use of a bigger ILM flap which is resized and trimmed using the vitrectomy probe and subsequently plugged into the hole [20, 75, 86]. If ERM is present, it may be inverted with the ILM into the hole [20]. To avoid macular hole packing with a folded multilayered ILM, the creation of a single-layer

inverted flap was suggested [84]. This large monolayer ILM flap seemed to promote regular glial cells proliferation and to create a physiological scaffold for the photoreceptors [84, 87]. To preserve the nasal maculopapillary nerve fiber layer, a 270-degree C-shaped temporal ILM flap has been suggested [23]. ILM flap is peeled towards the hole but stopped approximately 0.5 disc diameter from the center of the fovea, and a single smooth layer is used to cover the MH. This technique provides a reduction in dissociated optic nerve fiber layer [88] and is able to release more than 180° traction from the temporal side. A surgical variant of 180° superior ILM flap which does not require postoperatively prone positioning was also proposed [89].

The inverted ILM flap approach remains technically challenging even for an experienced surgeon [90]. To further steady the flap in an adequate position, the vitreous cavity can be filled with gas or silicone oil [20, 26, 75]. Compared to gas, silicone oil is characterized by long-lasting but weaker tamponade action, especially for myopic eyes with deep posterior staphyloma because of its difficulty to fit into this area. Nevertheless, silicone oil has been tested as a tamponade in highly myopic eyes, and it surprisingly demonstrated to be an effective tamponade for the treatment of MH [53]. It has been demonstrated that silicone oil creates a bursa inside the MH with a compartmentalization of chemotactic and nutrient substances. These substances might promote reparative mechanism which supports the closure of the hole [82].

Although the anatomic success of inverted ILM flap technique without retinal detachment range from 94% to 100% [75, 81], a previous PPV with complete ILM peeling precludes the feasibility of this surgical approach in case of MH reopening. In these cases, several alternatives have been described including the use of anterior and posterior lens capsular flap transplantation [91] or the autologous transplantation of the ILM [25]. Recently, autologous neurosensory retinal free flap transplantation (ANRFF) technique with gas or silicone oil tamponade was introduced [92, 93]. Chen et al. [91] described the use of anterior and posterior capsule lens to close refractory MH, due to its similar nature to ILM, reporting a significantly better closure rate with the anterior capsule flap but not a significantly VA improvement than eyes treated with the posterior one. Once obtained a circular anterior or posterior capsular flap, it is stained with 0.125% ICG and transplanted into the hole [91]. The advantages of a lens capsular flap are its higher density compared with ILM making it easier to settle down on the retinal surface and its easy feasibility.

Autologous transplantation of the ILM was first described by Morizane et al. [25]. This surgical approach consists of visualization of residual ILM using 0.25 mg/mL brilliant blue G solution and creation and transplantation of a free flap of ILM inside the macular hole. Grewal and Mahmoud [92] described the use of ANRFF transplantation for refractory myopic MH complicated by retinal detachment. This technique involves harvesting an autologous neurosensory retinal free flap and gently positioning it over the refractory MH using bimanual approach [92].

In highly myopic eyes, a macular hole with retinal detachment (MHRD) can occur. Vitrectomy with removal of cortical vitreous and ILM and gas or silicone oil tamponade has become the standard of care for MHRD treatment [94]. Although anatomic reattachment can be achieved, the success rate of MH closure ranges from 50% to 70% and poor postoperatively visual acuity was reported [23, 95, 96]. The inverted ILM flap technique has been demonstrated to be a useful strategy to increase the closure rate of the hole in MHRD [20, 22, 23]. Macular buckling has also been introduced as a treatment option for both primary MHRD and MHRD refractory to vitrectomy with an anatomical success rate ranging from 70% to 100% [97–101]. This technique aims to reduce the complex anteroposterior and tangential tractions resulting from PS in highly myopic eyes through the modification of macular shape from concave to convex profile. According to the intraoperative difficulty to check the correct position of the buckle and to place sutures posteriorly, several buckles with different designs and material have been described [102–104].

Considering that eyes with extremely high myopia can frequently exceed 30 mm in the axial length, surgical instrumentation, such as vitreous forceps, must be evaluated accurately during PPV. To overcome the inability to reach the retinal surface, surgeons can verticalize the instruments and carefully apply a pressure on the sclera wall in order to temporarily reduce the axial length of the globe [105]. However, these maneuvers are not free from complications, such as limited visibility due to erroneous contact and dislocation of the viewing system, corneal folds and impaired surgeon maneuverability which result in a longer operation time and challenging surgical procedures [106]. To prevent complications resulting from iatrogenic trauma, long-shaft forceps for ILM peeling specific for highly myopic eyes were developed [107]. Curved elongated instruments were also proposed [105].

Microincision vitrectomy surgery (MIVS) has potential advantages compared to conventional vitrectomy in highly myopic eyes. Despite the lowest incidence of complications with the small-gauge system compared to conventional vitrectomy, no statistically significant difference in visual outcomes has been reported [59]. With MIVS a small-diameter sutureless sclerotomies may be performed. This surgery is characterized by a faster postoperative recovery, less postoperative inflammation and patient discomfort, and reduction of iatrogenic peripheral breaks incidence [108, 109]. However, in some cases, the self-healing sclerotomies can remain open with spontaneous leakage and early postoperative hypotony. This condition mainly occurs in myopic patients due to the anatomical characteristic of these eyes with a thinner sclera and a deranged fibrillar architecture [110].

The intrascleral tunnel morphology plays a key role in avoiding the sclerotomy leakage. Both biplanar oblique-perpendicular-bevel-down trocar insertion and longer tunnel have a lower incidence of early hypotony when compared to straight bevel-up and shorter sclerotomies [111–114]. To promote the wound sealing, several options have been introduced, including the prolonged sclerotomy

massage [115, 116], transconjunctival and trans-scleral absorbable suture [117], releasable sutures [118], use of fibrin glue or polyethylene glycol hydrogel polymer [119, 120], and conjunctival cauterization [117]. The introduction of 27-gauge vitrectomy with scleral incision diameter of 0.4 mm does not require biplanar trocar insertion, thus reducing the risk of postoperative hypotony in myopic eyes [121, 122].

4. Conclusions

Several and complex tractional mechanisms are implicated in the development of MH in myopic eyes including the anteroposterior forces due to the strong adhesion of vitreous cortex, the tangential traction on the macula caused by the ILM, as well as the centripetal vector forces exerted by the PS. Related to these anatomical conditions, myopic eyes still remain a challenge for vitreoretinal surgeons. In the last decades, the introduction of significant innovations for the treatment of myopic MH has allowed vitreoretinal surgeons to perform a safe and effective surgery in these complicated eyes.

Conflicts of Interest

The authors declare that there are no conflicts of interest regarding the publication of this paper.

References

- [1] J. Bainbridge, E. Herbert, and Z. Gregor, "Macular holes: vitreoretinal relationships and surgical approaches," *Eye*, vol. 22, no. 10, pp. 1301–1309, 2008.
- [2] D. H. W. Steel and A. J. Lotery, "Idiopathic vitreomacular traction and macular hole: a comprehensive review of pathophysiology, diagnosis and treatment," *Eye*, vol. 27, no. S1, pp. S1–S21, 2013.
- [3] T. Brockmann, C. Steger, M. Weger, A. Wedrich, and A. Haas, "Risk assessment of idiopathic macular holes undergoing vitrectomy with dye-assisted internal limiting membrane peeling," *Retina*, vol. 33, no. 6, pp. 1132–1136, 2013.
- [4] L. A. Casuso, I. U. Scott, H. W. Flynn et al., "Long-term follow-up of unoperated macular holes," *Ophthalmology*, vol. 108, no. 6, pp. 1150–1155, 2001.
- [5] E. Ezra, "Idiopathic full thickness macular hole: natural history and pathogenesis," *British Journal of Ophthalmology*, vol. 85, no. 1, pp. 102–109, 2001.
- [6] F. S. Ali, J. D. Stein, T. S. Blachley, S. Ackley, and J. M. Stewart, "Incidence of and risk factors for developing idiopathic macular hole among a diverse group of patients throughout the United States," *JAMA Ophthalmology*, vol. 135, no. 4, pp. 299–305, 2017.
- [7] H. A. Madi, I. Masri, and D. H. Steel, "Optimal management of idiopathic macular holes," *Clinical Ophthalmology*, vol. 10, pp. 97–116, 2016.
- [8] H. Kobayashi, K. Kobayashi, and S. Okinami, "Macular hole and myopic refraction," *British Journal of Ophthalmology*, vol. 86, no. 11, pp. 1269–1273, 2002.
- [9] A. J. Singh, M. M. K. Muqit, and W. H. Woon, "Is axial length a risk factor for idiopathic macular hole formation?," *International Ophthalmology*, vol. 32, no. 4, pp. 393–396, 2012.
- [10] G. Ripandelli, T. Rossi, F. Scarinci et al., "Macular vitreoretinal interface abnormalities in highly myopic eyes with posterior staphyloma," *Retina*, vol. 32, no. 8, pp. 1531–1538, 2012.
- [11] N. E. Kelly and R. T. Wendel, "Vitreous surgery for idiopathic macular holes," *Archives of Ophthalmology*, vol. 109, no. 5, pp. 654–659, 1991.
- [12] R. T. Wendel, A. C. Patel, N. E. Kelly, T. C. Salzano, J. W. Wells, and G. D. Novack, "Vitreous surgery for macular holes," *Ophthalmology*, vol. 100, no. 11, pp. 1671–1676, 1993.
- [13] J. W. Kim, W. R. Freeman, S. P. Stanley et al., "Prospective randomized trial of vitrectomy or observation for stage 2 macular holes," *American Journal of Ophthalmology*, vol. 121, no. 6, pp. 605–614, 1996.
- [14] E. Ezra and Z. J. Gregor, "Surgery for idiopathic full-thickness macular hole," *Archives of Ophthalmology*, vol. 122, no. 2, pp. 224–236, 2004.
- [15] W. R. Freeman, S. P. Azen, J. W. Kim et al., "Vitrectomy for the treatment of full-thickness stage 3 or 4 macular holes," *Archives of Ophthalmology*, vol. 115, no. 1, pp. 11–21, 1997.
- [16] S.-N. Chen, Y.-T. Hsieh, and C.-M. Yang, "Multiple free internal limiting membrane flap insertion in the treatment of macular hole-associated retinal detachment in high myopia," *Ophthalmologica*, vol. 240, no. 3, pp. 143–149, 2018.
- [17] N. Lois, J. Burr, J. Norrie et al., "Internal limiting membrane peeling versus No peeling for idiopathic full-thickness macular hole: a pragmatic randomized controlled trial," *Investigative Ophthalmology & Visual Science*, vol. 52, no. 3, pp. 1586–1592, 2011.
- [18] L. Ternent, L. Vale, C. Boachie et al., "Cost-effectiveness of internal limiting membrane peeling versus no peeling for patients with an idiopathic full-thickness macular hole: results from a randomised controlled trial," *British Journal of Ophthalmology*, vol. 96, no. 3, pp. 438–443, 2012.
- [19] F. Morescalchi, C. Costagliola, E. Gambicorti, S. Duse, M. R. Romano, and F. Semeraro, "Controversies over the role of internal limiting membrane peeling during vitrectomy in macular hole surgery," *Survey of Ophthalmology*, vol. 62, no. 1, pp. 58–69, 2017.
- [20] S. Kuriyama, H. Hayashi, Y. Jingami, N. Kuramoto, J. Akita, and M. Matsumoto, "Efficacy of inverted internal limiting membrane flap technique for the treatment of macular hole in high myopia," *American Journal of Ophthalmology*, vol. 156, no. 1, pp. 125–131, 2013.
- [21] S.-N. Chen and C.-M. Yang, "Inverted internal limiting membrane insertion for macular hole-associated retinal detachment in high myopia," *American Journal of Ophthalmology*, vol. 162, pp. 99–106, 2016.
- [22] C.-C. Lai, Y.-P. Chen, N.-K. Wang et al., "Vitrectomy with internal limiting membrane repositioning and autologous blood for macular hole retinal detachment in highly myopic eyes," *Ophthalmology*, vol. 122, no. 9, pp. 1889–1898, 2015.
- [23] T. C. Ho, A. Ho, and M. S. Chen, "Vitrectomy with a modified temporal inverted limiting membrane flap to reconstruct the foveolar architecture for macular hole retinal detachment in highly myopic eyes," *Acta Ophthalmologica*, vol. 96, no. 1, pp. 46–53, 2018.
- [24] S.-N. Chen, "Large semicircular inverted internal limiting membrane flap in the treatment of macular hole in high myopia," *Graefe's Archive for Clinical and Experimental Ophthalmology*, vol. 255, no. 12, pp. 2337–2345, 2017.
- [25] Y. Morizane, F. Shiraga, S. Kimura et al., "Autologous transplantation of the internal limiting membrane for refractory macular holes," *American Journal of Ophthalmology*, vol. 157, no. 4, pp. 861–869, 2014.

- [26] S. N. Chen and C. M. Yang, "Double internal limiting membrane insertion for macular hole-associated retinal detachment," *J Ophthalmol*, vol. 2017, Article ID 3236516, 5 pages, 2017.
- [27] A. M. Coppé, G. Ripandelli, V. Parisi, M. Varano, and M. Stirpe, "Prevalence of asymptomatic macular holes in highly myopic eyes," *Ophthalmology*, vol. 112, no. 12, pp. 2103–2105, 2005.
- [28] A. Gaudric, B. Haouchine, P. Massin, M. Paques, P. Blain, and A. Erginay, "Macular hole formation," *Archives of Ophthalmology*, vol. 117, no. 6, pp. 744–751, 1999.
- [29] M. R. Hee, C. A. Puliafito, C. Wong et al., "Optical coherence tomography of macular holes," *Ophthalmology*, vol. 102, no. 5, pp. 748–756, 1995.
- [30] R. F. Spaide, "Macular hole hypotheses," *American Journal of Ophthalmology*, vol. 139, no. 1, pp. 149–151, 2005.
- [31] V. Tanner, D. S. Chauhan, T. L. Jackson, and T. H. Williamson, "Optical coherence tomography of the vitreoretinal interface in macular hole formation," *British Journal of Ophthalmology*, vol. 85, no. 9, pp. 1092–1097, 2001.
- [32] A. Targino, R. A. Costa, D. Calucci, J. A. Cardillo, R. Jorge, and I. U. Scott, "OCT findings in macular hole formation in eyes with complete vitreofoveal separation," *Ophthalmic Surgery, Lasers, and Imaging*, vol. 39, no. 1, pp. 65–68, 2008.
- [33] M. Stripe and R. G. Michels, "Retinal detachment in highly myopic eyes duo to macular holes and epiretinal traction," *Retina*, vol. 10, no. 2, pp. 113–114, 1990.
- [34] Y. Oshima, Y. Ikuno, M. Motokura, K. Nakae, and Y. Tano, "Complete epiretinal membrane separation in highly myopic eyes with retinal detachment resulting from a macular hole11A product based on the results of this study is commercially available as a diamond-dusted membrane scraper (DDMS, Synergetics, Inc, Chesterfield, Missouri, and the Inami Company, Tokyo, Japan). The authors have no financial or proprietary interest in any materials discussed in this report," *American Journal of Ophthalmology*, vol. 126, no. 5, pp. 669–676, 1998.
- [35] C. Seike, S. Kusaka, K. Sakagami, and Y. Ohashi, "Reopening of macular holes in highly myopic eyes with retinal detachments," *Retina*, vol. 17, no. 1, pp. 2–6, 1997.
- [36] K. Sayanagi, Y. Oshima, Y. Ikuno, and Y. Tano, "Presumed vascular traction-associated recurrence of retinal detachment in patients with myopic macular hole," *Ophthalmic Surgery, Lasers, and Imaging*, vol. 40, no. 1, pp. 60–64, 2009.
- [37] H. Morita, H. Ideta, K. Ito, J. Yonemoto, K. Sasaki, and S. Tanaka, "Causative factors of retinal detachment in macular holes," *Retina*, vol. 11, no. 3, pp. 281–284, 1991.
- [38] W. E. Smiddy, S. S. Kim, B. J. Lujan, and G. Gregori, "Myopic traction maculopathy: spectral domain optical coherence tomographic imaging and a hypothesized mechanism," *Ophthalmic Surgery, Lasers, and Imaging*, vol. 40, no. 2, pp. 169–173, 2009.
- [39] R. Frisina, A. Baldi, B. M. Cesana, F. Semeraro, and B. Parolini, "Morphological and clinical characteristics of myopic posterior staphyloma in Caucasians," *Graefes Archive for Clinical and Experimental Ophthalmology*, vol. 254, no. 11, pp. 2119–2129, 2016.
- [40] Y. Oie, Y. Ikuno, T. Fujikado, and Y. Tano, "Relation of posterior staphyloma in highly myopic eyes with macular hole and retinal detachment," *Japanese Journal of Ophthalmology*, vol. 49, no. 6, pp. 530–532, 2005.
- [41] M. Alkabes, L. Padilla, C. Salinas et al., "Assessment of OCT measurements as prognostic factors in myopic macular hole surgery without foveoschisis," *Graefes Archive for Clinical and Experimental Ophthalmology*, vol. 251, no. 11, pp. 2521–2527, 2013.
- [42] Y. Jo, Y. Ikuno, and K. Nishida, "Retinoschisis: a predictive factor in vitrectomy for macular holes without retinal detachment in highly myopic eyes," *British Journal of Ophthalmology*, vol. 96, no. 2, pp. 197–200, 2012.
- [43] M. Alkabes, F. Pichi, P. Nucci et al., "Anatomical and visual outcomes in high myopic macular hole (HM-MH) without retinal detachment: a review," *Graefes Archive for Clinical and Experimental Ophthalmology*, vol. 252, no. 2, pp. 191–199, 2014.
- [44] C.-W. Lin, T.-C. Ho, and C.-M. Yang, "The development and evolution of full thickness macular hole in highly myopic eyes," *Eye*, vol. 29, no. 3, pp. 388–396, 2015.
- [45] D. Gaucher, B. Haouchine, R. Tadayoni et al., "Long-term follow-up of high myopic foveoschisis: natural course and surgical outcome," *American Journal of Ophthalmology*, vol. 143, no. 3, pp. 455–462, 2007.
- [46] N. Gaudric, K. Ohno-Matsui, T. Baba, S. Futagami, T. Tokoro, and M. Mochizuki, "Natural course of macular retinoschisis in highly myopic eyes without macular hole or retinal detachment," *American Journal of Ophthalmology*, vol. 142, no. 3, pp. 497–500, 2006.
- [47] N. Benhamou, P. Massin, B. Haouchine, A. Erginay, and A. Gaudric, "Macular retinoschisis in highly myopic eyes," *American Journal of Ophthalmology*, vol. 133, no. 6, pp. 794–800, 2002.
- [48] C. B. Sun, Z. Liu, A. Q. Xue, and K. Yao, "Natural evolution from macular retinoschisis to full-thickness macular hole in highly myopic eyes," *Eye*, vol. 24, no. 12, pp. 1787–1791, 2010.
- [49] T.-T. Lai, S.-N. Chen, and C.-M. Yang, "Epiretinal proliferation in lamellar macular holes and full-thickness macular holes: clinical and surgical findings," *Graefes Archive for Clinical and Experimental Ophthalmology*, vol. 254, no. 4, pp. 629–638, 2016.
- [50] C. E. Pang, R. F. Spaide, and K. B. Freund, "Comparing functional and morphologic characteristics of lamellar macular holes with and without lamellar hole-associated epiretinal proliferation," *Retina*, vol. 35, no. 4, pp. 720–726, 2015.
- [51] C. E. Pang, D. A. Maberley, K. B. Freund et al., "Lamellar hole-associated epiretinal proliferation," *Retina*, vol. 36, no. 7, pp. 1408–1412, 2016.
- [52] T. Kono, Y. Takesue, and S. Shiga, "Scleral resection technique combined with vitrectomy for a macular hole retinal detachment in highly myopic eyes," *Ophthalmologica*, vol. 220, no. 3, pp. 159–163, 2006.
- [53] J. Qian and Y.-R. Jiang, "Anatomic evaluation of macular holes with silicone oil tamponades in highly myopic eyes using optical coherence tomography," *European Journal of Ophthalmology*, vol. 20, no. 5, pp. 938–944, 2010.
- [54] T. Tanaka, F. Ando, and M. Usui, "Episcleral macular buckling by semirigid shaped-rod exoplant for recurrent retinal detachment with macular hole in highly myopic eyes," *Retina*, vol. 25, no. 2, pp. 147–151, 2005.
- [55] E. N. El Rayes and Y. Oshima, "Supra choroidal buckling in managing myopic vitreoretinal interface disorders," *Retina*, vol. 34, no. 1, pp. 129–135, 2014.
- [56] E. Abdelkader and N. Lois, "Internal limiting membrane peeling in vitreo-retinal surgery," *Survey of Ophthalmology*, vol. 53, no. 4, pp. 368–396, 2008.
- [57] T.-T. Wu, Y.-H. Kung, C.-Y. Chang, and S.-P. Chang, "Surgical outcomes in eyes with extremely high myopia for macular hole without retinal detachment," *Retina*, vol. 38, no. 10, pp. 2051–2055, 2018.

- [58] H. Sakaguchi, Y. Ikuno, J. S. Choi, M. Ohji, and T. Tano, "Multiple components of epiretinal tissues detected by triamcinolone and indocyanine green in macular hole and retinal detachment as a result of high myopia," *Am J Ophthalmol*, vol. 138, no. 6, pp. 1079–1081, 2004.
- [59] M. Gómez-Resca, A. Burés-Jelstrup, and C. Mateo, "Myopic traction maculopathy," *Microincision Vitrectomy Surgery*, vol. 54, pp. 204–212, 2014.
- [60] A. K. H. Kwok and T. Y. Lai, "Internal limiting membrane removal in macular hole surgery for severely myopic eyes: a case-control study," *British Journal of Ophthalmology*, vol. 87, no. 7, pp. 885–889, 2003.
- [61] D. R. Chow, "The evolution of endoillumination," *Microincision Vitrectomy Surgery*, vol. 54, pp. 77–86, 2014.
- [62] P. B. Henrich, C. Valmaggia, C. Lang, and P. C. Cattin, "The price for reduced light toxicity: do endoilluminator spectral filters decrease color contrast during brilliant blue G-assisted chromovitrectomy?," *Graefe's Archive for Clinical and Experimental Ophthalmology*, vol. 252, no. 3, pp. 367–374, 2014.
- [63] M. Cacciatori, M. Azzolini, M. Sborgia, M. Coppola, and V. De Molletta, "Sodium hyaluronate 2.3% prevents contact between indocyanine green and retinal pigment epithelium during vitrectomy for highly myopic macular hole retinal detachment," *Retina*, vol. 24, no. 1, pp. 160–161, 2004.
- [64] M. Facino, B. Mochi, S. Lai, and R. Terrile, "A simple way to prevent indocyanine green from entering the subretinal space during vitrectomy for retinal detachment due to myopic macular hole," *European Journal of Ophthalmology*, vol. 14, no. 3, pp. 269–271, 2004.
- [65] S. Rizzo, C. Belting, F. Genovesi-Ebert, A. Vento, and F. Cresti, "Modified technique for safer indocyanine-green-assisted peeling of the internal limiting membrane during vitrectomy for macular hole repair," *Graefe's Archive for Clinical and Experimental Ophthalmology*, vol. 244, no. 12, pp. 1615–1619, 2006.
- [66] M. Coppola, A. Rabiolo, M. V. Cicinelli, G. Querques, and F. Bandello, "Vitrectomy in high myopia: a narrative review," *International Journal of Retina and Vitreous*, vol. 3, no. 1, p. 37, 2017.
- [67] O. Toygar, M. H. Berrocal, M. Charles, and C. D. Riemann, "Next-generation dual-bore cannula for injection of vital dyes and heavy liquids during pars plana vitrectomy," *Retina*, vol. 36, no. 3, pp. 582–587, 2016.
- [68] J. P. Ehlers, W. J. Dupps, P. K. Kaiser et al., "The prospective intraoperative and perioperative ophthalmic ImagiNg with optical CoherEncE TomogRaphy (PIONEER) study: 2-year results," *American Journal of Ophthalmology*, vol. 158, no. 5, pp. 999–1007, 2014.
- [69] M. Mura, D. Iannetta, F. Nasini et al., "Use of a new intraocular spectral domain optical coherence tomography in vitreoretinal surgery," *Acta Ophthalmologica*, vol. 94, no. 3, pp. 246–252, 2016.
- [70] K. Suda, M. Hangai, and N. Yoshimura, "Axial length and outcomes of macular hole surgery assessed by spectral-domain optical coherence tomography," *American Journal of Ophthalmology*, vol. 151, no. 1, pp. 118–127, 2011.
- [71] Z. Zhang, Y. Wei, X. Jiang, and S. Zhang, "Pars plana vitrectomy and wide internal limiting membrane peeling with perfluoropropane tamponade for highly myopic foveoschisis-associated macular hole," *Retina*, vol. 37, no. 2, pp. 274–282, 2017.
- [72] N. Balducci, M. Morara, C. Veronese et al., "Retinal nerve fiber layer thickness modification after internal limiting membrane peeling," *Retina*, vol. 34, no. 4, pp. 655–663, 2014.
- [73] M. S. Sevim and H. Sanisoglu, "Analysis of retinal ganglion cell complex thickness after brilliant blue-assisted vitrectomy for idiopathic macular holes," *Current Eye Research*, vol. 38, no. 1, pp. 180–184, 2013.
- [74] D. H. W. Steel, Y. Chen, J. Latimer, K. White, and P. J. Avery, "Does internal limiting membrane peeling size matter?," *Journal of VitreoRetinal Diseases*, vol. 1, no. 1, pp. 27–33, 2017.
- [75] M. Mete, A. Alfano, M. Guerriero et al., "Inverted internal limiting membrane flap technique versus complete internal limiting membrane removal in myopic macular hole surgery," *Retina*, vol. 37, no. 10, pp. 1923–1930, 2017.
- [76] N. Shimada, Y. Sugamoto, M. Ogawa, H. Takase, and K. Ohno-Matsui, "Fovea-sparing internal limiting membrane peeling for myopic traction maculopathy," *American Journal of Ophthalmology*, vol. 154, no. 4, pp. 693–701, 2012.
- [77] T. Tian, H. Jin, Q. Zhang, X. Zhang, H. Zhang, and P. Zhao, "Long-term surgical outcomes of multiple parfoveolar curvilinear internal limiting membrane peeling for myopic foveoschisis," *Eye*, vol. 32, no. 11, pp. 1783–1789, 2018.
- [78] T. C. Ho, M. S. Chen, J. S. Huang, Y. F. Shih, H. Ho, and Y. H. Huang, "Foveola nonpeeling technique in internal limiting membrane peeling of myopic foveoschisis surgery," *Retina*, vol. 32, pp. 631–634, 2012.
- [79] H. Jin, Q. Zhang, and P. Zhao, "Fovea sparing internal limiting membrane peeling using multiple parfoveal curvilinear peels for myopic foveoschisis: technique and outcome," *BMC Ophthalmol*, vol. 16, no. 1, p. 180, 2016.
- [80] Y. Ikuno, K. Sayanagi, T. Oshima et al., "Optical coherence tomographic findings of macular holes and retinal detachment after vitrectomy in highly myopic eyes," *American Journal of Ophthalmology*, vol. 136, no. 3, pp. 477–481, 2003.
- [81] Z. Michalewska, J. Michalewski, K. Dulczewska-Cichecka, and J. Nawrocki, "Inverted internal limiting membrane flap technique for surgical repair of myopic macular holes," *Retina*, vol. 34, no. 4, pp. 664–669, 2014.
- [82] G. Pertile, M. Mete, and A. Alfano, "Features involved in the healing process of macular holes," *JAMA Ophthalmology*, vol. 135, no. 8, pp. 833–834, 2017.
- [83] N. Andrew, W. O. Chan, M. Tan, A. Ebnetter, and J. S. Gilhott, "Modification of the inverted internal limiting membrane flap technique for the treatment of chronic and large macular holes," *Retina*, vol. 36, no. 4, pp. 834–837, 2016.
- [84] M. K. Gilhotra, K. H. Park, S. W. Park, I. S., J. E. Byon, and ., "Perfluoro-n-octane-assisted single-layered inverted internal limiting membrane flap technique for macular hole surgery," *Retina*, vol. 34, no. 9, pp. 1905–1910, 2014.
- [85] M. S. Figueroa, A. Govetto, and P. D. Arriba-Palomero, "Short-term results of platelet-rich plasma as adjuvant to 23-G vitrectomy in the treatment of high myopic macular holes," *European Journal of Ophthalmology*, vol. 26, no. 5, pp. 491–496, 2016.
- [86] S. Rizzo, R. Tartaro, F. Barca, T. Caporossi, D. Bacherini, and F. Giansanti, "Internal limiting membrane peeling versus inverted flap technique for treatment of full-thickness macular holes," *Retina*, vol. 38, pp. S73–S78, 2018.
- [87] Z. Song, M. Li, J. Liu, X. Hu, Z. Hu, and D. Chen, "Viscoat assisted inverted internal limiting membrane flap technique for large macular holes associated with high myopia," *Journal of Ophthalmology*, vol. 2016, Article ID 8283062, 7 pages, 2016.
- [88] Z. Michalewska, J. Michalewski, K. Dulczewska-Cichecka, R. A. Adelman, and J. Nawrocki, "Temporal inverted internal

- limiting membrane flap technique versus classic inverted internal limiting membrane flap technique," *Retina*, vol. 35, no. 9, pp. 1844–1847, 2015.
- [89] S. R. Choi, J. W. Kang, J. H. Jeon et al., "The efficacy of superior inverted internal limiting membrane flap technique for the treatment of full-thickness macular hole," *Retina*, vol. 38, pp. 192–197, 2017.
- [90] M. S. Figueroa, J. M. Ruiz-Moreno, F. Gonzalez del Valle et al., "Long-term outcomes of 23-gauge pars plana vitrectomy with internal limiting membrane peeling and gas tamponade for myopic traction maculopathy," *Retina*, vol. 35, no. 9, pp. 1836–1843, 2015.
- [91] S.-N. Chen and C.-M. Yang, "Lens capsular flap transplantation in the management of refractory macular hole from multiple etiologies," *Retina*, vol. 36, no. 1, pp. 163–170, 2016.
- [92] D. S. Grewal and T. H. Mahmoud, "Autologous neurosensory retinal free flap for closure of refractory myopic macular holes," *JAMA Ophthalmology*, vol. 134, no. 2, pp. 229–230, 2016.
- [93] C. De Giacinto, R. D'Aloisio, G. Cirigliano, M. R. Pastore, and D. Tognetto, "Autologous neurosensory retinal free patch transplantation for persistent full-thickness macular hole," *International Ophthalmology*, 2018, In press.
- [94] T. Tognetto, Y. Ikuno, N. Shiraki, N. Matsumura, H. Sakaguchi, and K. Nishida, "Inverted internal limiting membrane insertion versus standard internal limiting membrane peeling for macular hole retinal detachment in high myopia: one-year study," *Graefes Archive for Clinical and Experimental Ophthalmology*, vol. 256, no. 8, pp. 1387–1393, 2018.
- [95] L. S. Lim, A. Tsai, D. Wong et al., "Prognostic factor Analysis of vitrectomy for retinal detachment associated with myopic macular holes," *Ophthalmology*, vol. 121, no. 1, pp. 305–310, 2014.
- [96] S. Dimopoulos, A. William, B. Voykov, F. Ziemssen, K. U. Bartz-Schmidt, and M. S. Spitzer, "Anatomical and visual outcomes of autologous thrombocyte serum concentrate in the treatment of persistent full-thickness idiopathic macular hole after ILM peeling with brilliant blue G and membrane blue dual," *Acta Ophthalmologica*, vol. 95, pp. 429–430, 2017.
- [97] Y.-P. Chen, T.-L. Chen, K.-R. Yang et al., "Treatment of retinal detachment resulting from posterior staphyloma-associated macular hole in highly myopic eyes," *Retina*, vol. 26, no. 1, pp. 25–31, 2006.
- [98] G. Ripandelli, A. M. Coppe, R. Fedeli, V. Parisi, D. J. D'Amico, and M. Stirpe, "Evaluation of primary surgical procedures for retinal detachment with macular hole in highly myopic eyes A randomized comparison of vitrectomy versus posterior episcleral buckling surgery," *Ophthalmology*, vol. 108, no. 12, pp. 2258–2264, 2001.
- [99] G. P. Theodossiadis and P. G. Theodossiadis, "The macular buckling procedure in the treatment of retinal detachment in highly myopic eyes with macular hole and posterior staphyloma," *Retina*, vol. 25, no. 3, pp. 285–289, 2005.
- [100] A. L. H. Siam, T. A. El Maamoun, and M. H. Ali, "Macular buckling for myopic macular hole retinal detachment," *Retina*, vol. 32, no. 4, pp. 748–753, 2012.
- [101] M. Alkabes, A. Burés-Jelstrup, C. Salinas et al., "Macular buckling for previously untreated and recurrent retinal detachment due to high myopic macular hole: a 12-month comparative study," *Graefes Archive for Clinical and Experimental Ophthalmology*, vol. 252, no. 4, pp. 571–581, 2014.
- [102] B. Parolini, R. Frisina, S. Pinackatt et al., "Indications and results of a new L-shaped macular buckle to support a posterior staphyloma in high myopia," *Retina*, vol. 35, no. 12, pp. 2469–2482, 2015.
- [103] M. Stirpe, G. Ripandelli, T. Rossi, A. Cacciamani, and M. Orciuolo, "A new adjustable macular buckle designed for highly myopic eyes," *Retina*, vol. 32, no. 7, pp. 1424–1427, 2012.
- [104] P.-C. Wu, J.-J. Sheu, Y.-H. Chen et al., "Gore-tex vascular graft for macular buckling in high myopia eyes," *Retina*, vol. 37, no. 7, pp. 1263–1269, 2017.
- [105] L. M. Lytvynchuk, A. Sergiienko, and G. Richard, "Modified curved aspiration cannulas and end-gripping forceps for 25-gauge vitrectomy on highly myopic eyes," *Retina*, vol. 35, no. 12, pp. 2660–2663, 2015.
- [106] J. G. Arumi, A. Boixadera, V. Martinez-Castillo et al., "for myopic macular hole without retinal detachment," *European Ophthalmic Review*, vol. 06, no. 4, pp. 204–207, 2012.
- [107] X. Gao, Y. Ikuno, and K. Nishida, "Long-shaft forceps for membrane peeling in highly myopic eyes," *Retina*, vol. 33, no. 7, pp. 1475–1476, 2013.
- [108] E. Chen, "25-Gauge transconjunctival sutureless vitrectomy," *Current Opinion in Ophthalmology*, vol. 18, no. 3, pp. 188–193, 2007.
- [109] D. M. Cha, S. J. Woo, K. H. Park, and H. Chung, "Intraoperative iatrogenic peripheral retinal break in 23-gauge transconjunctival sutureless vitrectomy versus 20-gauge conventional vitrectomy," *Graefes Archive for Clinical and Experimental Ophthalmology*, vol. 251, no. 6, pp. 1469–1474, 2013.
- [110] S. J. Woo, K. H. Park, J.-M. Hwang, J. H. Kim, Y. S. Yu, and H. Chung, "Risk factors associated with sclerotomy leakage and postoperative hypotony after 23-gauge transconjunctival sutureless vitrectomy," *Retina*, vol. 29, no. 4, pp. 456–463, 2009.
- [111] M. Gutfleisch, M. Dietzel, B. Heimes, G. Spital, D. Pauleikhoff, and A. Lommatzsch, "Ultrasound biomicroscopic findings of conventional and sutureless sclerotomy sites after 20-, 23- and 25-G pars plana vitrectomy," *Eye*, vol. 24, no. 7, pp. 1268–1272, 2010.
- [112] L. López-Guajardo, E. Vleming-Pinilla, J. Pareja-Esteban, and M. A. Teus-Guezala, "Ultrasound biomicroscopy study of direct and oblique 25-gauge vitrectomy sclerotomies," *American Journal of Ophthalmology*, vol. 143, no. 5, pp. 881–883, 2007.
- [113] D. Chen, Y. Lian, L. Cui, F. Lu, Z. Ke, and Z. Song, "Sutureless vitrectomy incision architecture in the immediate postoperative period evaluated in vivo using optical coherence tomography," *Ophthalmology*, vol. 117, no. 10, pp. 2003–2009, 2010.
- [114] K. S. Choi, H. D. Kim, and S. J. Lee, "Sclerotomy site leakage according to wound shape in 23-gauge microincisional vitrectomy surgery," *Current Eye Research*, vol. 35, no. 6, pp. 499–504, 2010.
- [115] B. Parolini, G. Prigione, F. Romanelli, M. G. Cereda, M. Sartore, and G. Pertile, "Postoperative complications and intraocular pressure in 943 consecutive cases of 23-gauge transconjunctival pars plana vitrectomy with 1-year follow-up," *Retina*, vol. 30, no. 1, pp. 107–111, 2010.
- [116] H. Takashina, A. Watanabe, K. Mitooka, and H. Tsuneoka, "Factors influencing self-sealing of sclerotomy performed under gas tamponade in 23-gauge transconjunctival sutureless vitrectomy," *Clinical Ophthalmology*, vol. 8, pp. 2085–2089, 2014.

- [117] M. Reibaldi, A. Longo, A. Reibaldi et al., “Diathermy of leaking sclerotomies after 23-gauge transconjunctival pars plana vitrectomy,” *Retina*, vol. 33, no. 5, pp. 939–945, 2013.
- [118] Y. Song, Y. W. Shin, and B. R. Lee, “Adjunctive use of a novel releasable suture technique in transconjunctival vitrectomy,” *Retina*, vol. 31, no. 2, pp. 243–249, 2011.
- [119] A. Panda, S. Kumar, A. Kumar, R. Bansal, and S. Bhartiya, “Fibrin glue in ophthalmology,” *Indian Journal of Ophthalmology*, vol. 57, no. 5, pp. 371–379, 2009.
- [120] A. Singh, M. Hosseini, and S. M. Hariprasad, “Polyethylene glycol hydrogel polymer sealant for closure of sutureless sclerotomies: a histologic study,” *American Journal of Ophthalmology*, vol. 150, no. 3, pp. 346–351, 2010.
- [121] Y. Oshima, T. Wakabayashi, T. Sato, M. Ohji, and Y. Tano, “A 27-gauge instrument system for transconjunctival sutureless microincision vitrectomy surgery,” *Ophthalmology*, vol. 117, no. 1, pp. 93–102, 2010.
- [122] U. Spandau and M. Pavlidis, “Vitrectomy of myopic eyes,” in *27-Gauge Vitrectomy: Minimal Sclerotomies for Maximal Results*, U. Spandau and M. Pavlidis, Eds., pp. 269–270, Springer, Zurich, Switzerland, 2015.