



Original Research

Reconstruction of Complex Scalp Defects in Different Locations: Suggestions for Puzzle

Soysal Bas,¹ Cagatay Oner,² Hikmet Ihsan Eren,¹ Semra Hacikerim Karsidag,¹ Adem Yilmaz³

¹Department of Plastic, Reconstructive and Aesthetic Surgery, University of Health Sciences Turkey, Sisli Hamidiye Etfal Training and Research Hospital, Istanbul, Turkey

²Department of Plastic, Reconstructive and Aesthetic Surgery, Sirnak State Hospital, Sirnak, Turkey

³Department of Neurosurgery, University of Health Sciences Turkey, Sisli Hamidiye Etfal Training and Research Hospital, Istanbul, Turkey

Abstract

Objective: Scalp defects may occur following trauma, radiotherapy, oncologic resection, and recurrent surgeries. The hair-bearing scalp has a dual role, which consists of protecting the calvarium and contributing to aesthetic appearance. While the “reconstructive ladder” approach may be used to close small and medium-sized scalp defects, it is not the case for larger ones involving the calvarium or with a radiation therapy history. The aim of this study is to present cases operated due to complex scalp defects, analyze complications, and discuss the choice of reconstruction.

Material and Methods: The study consists of 14 patients who were operated between December 2017 and August 2019 due to a complex scalp defect. Patient were evaluated according to age, gender, etiology, radiation therapy history, defect size and location, reconstruction steps, cranioplasty and duraplasty options, type of free flap, recipient artery, vein graft requirement, and complications.

Results: The mean age of patients, which consists of 11 men and three women, was 56.7 years. The etiology for scalp defects included basosquamous carcinoma, squamous cell carcinoma, giant basal cell carcinoma, atypical meningioma, glioblastoma multiforme, angiosarcoma, and anaplastic oligodendroglioma. The defect involved the full thickness of calvarium in nine cases and pericranium in five cases. Cranioplasties were made with rib graft ($n=1$), bone graft ($n=1$), and titanium mesh ($n=7$). Free flaps used for reconstruction were musculocutaneous latissimus dorsi (LD) ($n=4$), LD muscle ($n=3$), anterolateral thigh (ALT) ($n=4$), musculocutaneous ALT ($n=1$), vastus lateralis muscle (1), and rectus abdominis muscle ($n=1$). Flap loss was not observed. Complications occurred in four of the patients; include a partial graft loss, a wound dehiscence, seroma, and an unsatisfactory esthetic result.

Conclusion: Free tissue transfers rather than local flaps should be opted to reconstruct complex scalp defects, as failure of the latter, could create much greater defects, and worse consequences. There are many options for proper reconstruction, and it is essential to select the appropriate one, taking into account the comorbid conditions of each case.

Keywords: Free flaps; microsurgery, reconstruction, scalp.

Please cite this article as: Bas V, Oner C, Eren HI, Karsidag SH, Yilmaz A. Reconstruction of Complex Scalp Defects in Different Locations: Suggestions for Puzzle. Med Bull Sisli Etfal Hosp 2021;55(3):349–358.

Address for correspondence: Soysal Bas, MD. Sisli Hamidiye Etfal Egitim ve Arastirma Hastanesi, Halaskargazi Cad. Etfal Sk.

34371 Sisli, Istanbul, Turkey

Phone: +90 373 50 00 **E-mail:** soysalbas@gmail.com

Submitted Date: October 06, 2020 **Accepted Date:** November 05, 2020 **Available Online Date:** September 24, 2021

©Copyright 2021 by The Medical Bulletin of Sisli Etfal Hospital - Available online at www.sislietfaltip.org

OPEN ACCESS This is an open access article under the CC BY-NC license (<http://creativecommons.org/licenses/by-nc/4.0/>).



Introduction

Scalp defects may occur following trauma, radiotherapy, oncologic resection, and recurrent surgeries. The hair-bearing scalp has a dual role, which consists of protecting the calvarium and contributing to esthetic appearance.^[1] While the “reconstructive ladder” approach may be used to close small and medium-sized scalp defects, it is not the case for larger ones involving the calvarium or with a radiation therapy history.^[2]

Primary closure may be sufficient to close a small defect. A larger one with a suitable wound bed may be closed with a skin graft but will result in alopecia and a depressed appearance. As they permit replacing like with like, local flaps are usually a more suitable option to reconstruct medium-sized and even large defects since the orthochea flap has been described.^[3] Tissue expanders are another option to reconstruct scalp up to 50% with similar tissue.^[4] Meanwhile, the need for an intact calvarium and the two-staged approach limit tissue expanders’ application in malignancy cases. It is also well known that increased complication rates are associated with expansion of irradiated tissue.^[5]

Oncological resections combining scalp and calvarium necessitate a cranioplasty procedure in addition to a good soft tissue coverage. Similarly, recurrent intracranial tumor surgeries may occasionally result in skin flap necrosis and bone flap loss, therefore, require a cranioplasty.^[6] Cranioplasty is the reconstruction procedure of a defective calvarium with autogenous or alloplastic implant material. It allows to restore cosmesis, to prevent brain injuries and to avoid postcraniectomy symptoms described in the literature as “syndrome of the trephined.”^[7] The aforementioned complex scalp defects usually require reconstruction with free vascularized tissue. The omental flap was the first described free flap reconstruction technique for the scalp.^[8] Since that, numerous flaps have been described for scalp reconstruction. Latissimus dorsi (LD) and anterolateral thigh (ALT) flaps represent now the workhorse flaps for free scalp reconstruction.^[9]

The aim of this study is to present cases operated due to complex scalp defects, analyze complications, and discuss the choice of reconstruction.

Materials and Methods

This study was approved by the ethics committee of our institution (University of Health Science, Sisli Hamidiye Etfal Training and Research Hospital Local Ethics Committee, 25.08.2020; approval number: 2954). The study consists of 14 patients who were operated between December 2017 and August 2019 due to a complex scalp defect (presence

of calvarium defect and/or radiotherapy history). Patients were evaluated according to age, gender, etiology, radiation therapy history, defect size and location, reconstruction steps, cranioplasty and duraplasty options, type of free flap, recipient artery, vein graft (VG) requirement, and complications (Tables 1 and 2). The etiology for scalp defects included basosquamous carcinoma (BSC), squamous cell carcinoma (SCC), giant basal cell carcinoma (BCC), atypical meningioma (AM), glioblastoma multiforme (GBM), angiosarcoma (AS), and anaplastic oligodendroglioma (AOD). All patients had a preoperative computed tomography to assess bone component of scalp defect or bone invasion in case of a skin malignancy. Intracranial tumors resection and cranioplasty were performed by the neurosurgery team, and skin cancers resections were performed by plastic surgeons. Reconstruction was performed once malignancy had been resected with adequate margins. Free flaps used for reconstruction included LD muscle, musculocutaneous LD, musculocutaneous ALT, ALT, vastus lateralis (VL) muscle, and rectus abdominis (RA) muscle. All muscle flaps were covered with a meshed split thickness skin graft taken from the lateral thigh region. In two-step reconstruction with muscle flaps, titanium mesh was inserted secondarily through the same incision and the muscle fascia was placed below.

Statistical Analysis

SPSS version 23.0 (SPSS Inc., Chicago, IL) was used for statistical analysis: Descriptive statistics; the number for genders, histopathological types, reconstructive and cranioplasty options, and anatomic locations. Mean and standard deviation for age, duration of operation and follow-up were given.

Results

The mean age of patients, which consisted of eleven men and three women, was 56.7 ± 14.14 years (range, 28–71 years). The etiology for scalp defects included BSC ($n=1$), SCC ($n=3$), giant BCC ($n=1$), AM ($n=4$), GBM ($n=3$), AS ($n=1$), and AOD ($n=1$). Thirteen patients out of 14 had previous history of radiation therapy. The defect locations were temporoparietal ($n=4$) (Fig. 1), temporal ($n=1$) (Fig. 2), parietal ($n=1$), frontoparietal ($n=5$), frontotemporoparietal ($n=1$) (Fig. 3), parietooccipital ($n=1$) (Fig. 4), and orbitofrontal ($n=1$). The smallest defect size was 8×5 cm and the biggest was 25×18 cm (mean, 15.4×11.7 cm). The defect involved the full thickness of calvarium in nine cases due to intracranial tumor and pericranium in five cases due to skin tumor. Among the nine cases involving the entire calvarium, five had a revision cranioplasty, and four had

Table 1. Demographic data of patients

Patient number	Age	Gender	Etiology	RT	Defect location	Defect size (cm)
1	65	M	AM	+	Temporoparietal	17×10
2	51	M	AM	+	Frontoparietal	15×10
3	62	M	SCC	+	Frontotemporoparietal	25×18
4	28	F	GBM	+	Frontoparietal	15×10
5	63	M	SCC	+	Temporoparietal	20×15
6	32	M	GBCC	+	Frontoparietal	22×15
7	38	M	AOD	+	Parietooccipital	20×15
8	71	M	AS	-	Parietal	17×14
9	57	M	GBM	+	Frontoparietal	8×5
10	60	F	AM	+	Temporoparietal	14×11
11	66	M	SCC	+	Temporal	10×11
12	68	M	BSC	+	Temporoparietal	10×7
13	69	F	AM	+	Orbitofrontal	8×6
14	65	M	GBM	+	Frontoparietal	15×8

RT: Radiation therapy history; AM: Atypical meningioma; BSC: Basosquamous carcinoma; GBM: Glioblastoma multiforme; SCC: Squamous cell carcinoma; GBCC: Giant basal cell carcinoma; AOD: Anaplastic oligodendroglioma; AS: Angiosarcoma.

Table 2. Reconstruction data of patients

Patient number	Step	Cranioplasty	Cranioplasty material	Flap	Recipient artery	Vein graft	Complications
1	2	Alloplastic	Titanium mesh	LD-MC	STA	No	Wound dehiscence
2	1	Alloplastic and autogenous	Rib and titanium mesh	LD-MC	FA	+	Nil
3	1	—	—	LD-M	FA	+	Nil
4	2	Alloplastic	Titanium mesh	LD-MC	FA	+	Unsatisfactory aesthetic result
5	1	—	—	ALT-MC	FA	No	Nil
6	2	—	—	ALT	STA	No	Nil
7	2	Alloplastic	Titanium mesh	LD-MC	OA	No	Partial graft loss
8	1	Autogenous	Bone	LD-M	STA	No	Nil
9	1	Alloplastic	Titanium mesh	ALT	FA	No	Nil
10	1	Alloplastic	Titanium mesh	ALT	STA	No	Nil
11	1	—	—	LD-M	FA	+	Donor site seroma
12	1	—	—	ALT	STA	No	Nil
13	1	—	—	RAM	FA	+	Nil
14	2	Alloplastic	Titanium mesh	VL	FA	No	Nil

LD-MC: Latissimus dorsi myocutaneous flap; LD-M: Latissimus dorsi muscle flap; ALT: Anterolateral thigh flap; ALT-MC: Myocutaneous anterolateral thigh flap; STA: Superficial temporal artery; FA: Facial artery, OA: Occipital artery.

a primary cranioplasty simultaneously with the free flap surgery. In the primary cranioplasty cases, duraplasty with fascia lata graft was performed. Cranioplasties were made with rib graft ($n=1$), bone graft ($n=1$), and titanium mesh ($n=7$). The cases of secondary cranioplasty were operated in two steps. In the first operation, unhealthy bone and

soft tissues were debrided and reconstructed with free muscle flaps. In the second operation (4.5–8 months, mean 5.3 months later), bone defect was repaired with titanium mesh and flap thinning was performed if necessary. Duraplasty was not required in secondary cranioplasty cases.

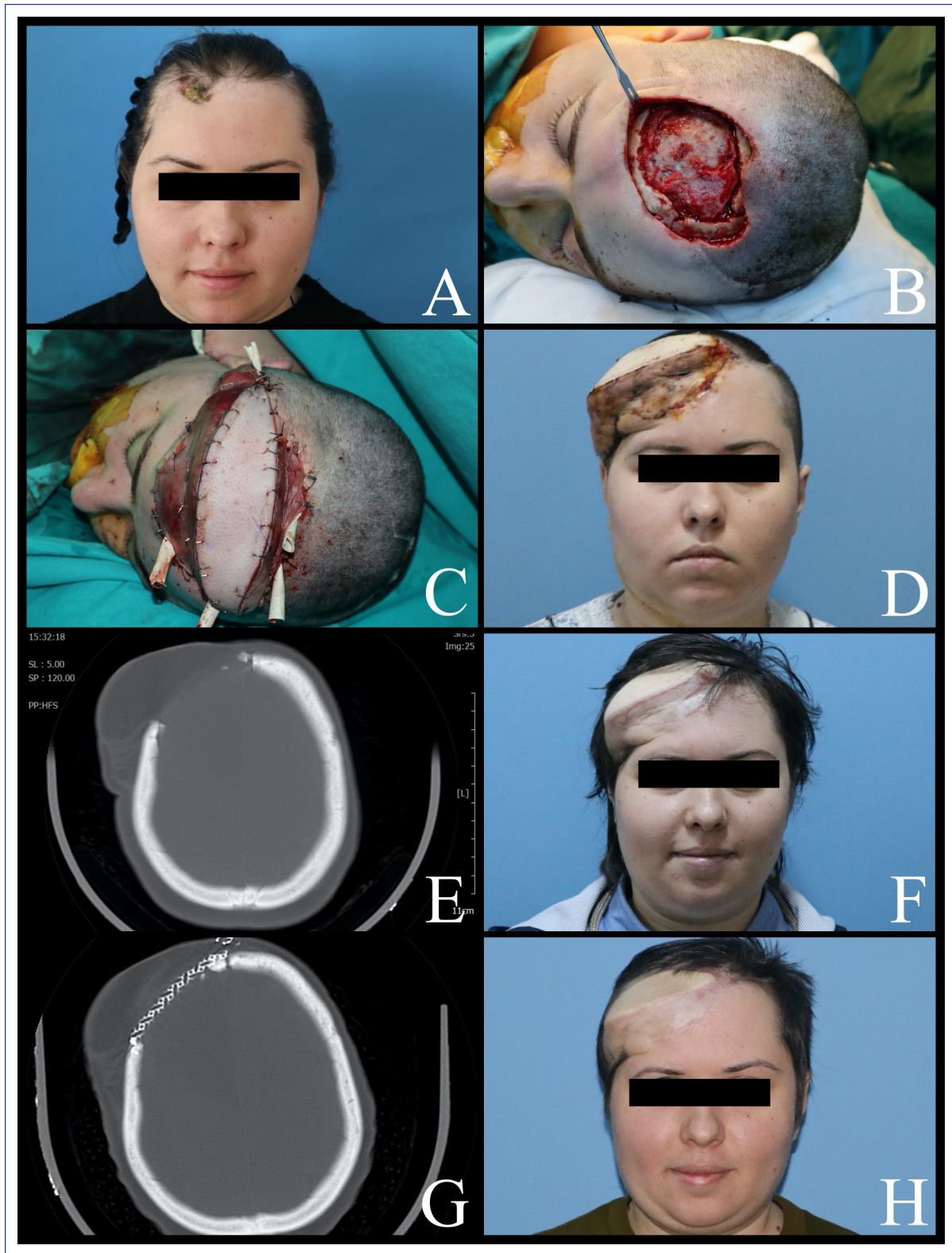


Figure 1. Case 4, two-stage reconstruction. A 28-year-old female patient operated for glioblastoma multiforme. (a) Full-thickness scalp defect in the right frontoparietal region. (b) Per-operative view of the defect area after debridement. (c) Reconstruction of the defect area with the musculocutaneous latissimus dorsi flap, immediate postoperative view. (d) Post-operative 1st week view of the patient. (e) Postoperative 6th month computed tomography image. (f) Post-operative 6th month view of the patient. (g) Computed tomography image after the second operation, bone reconstruction is seen with titanium mesh (h) 3rd month image after the second reconstructive surgery.

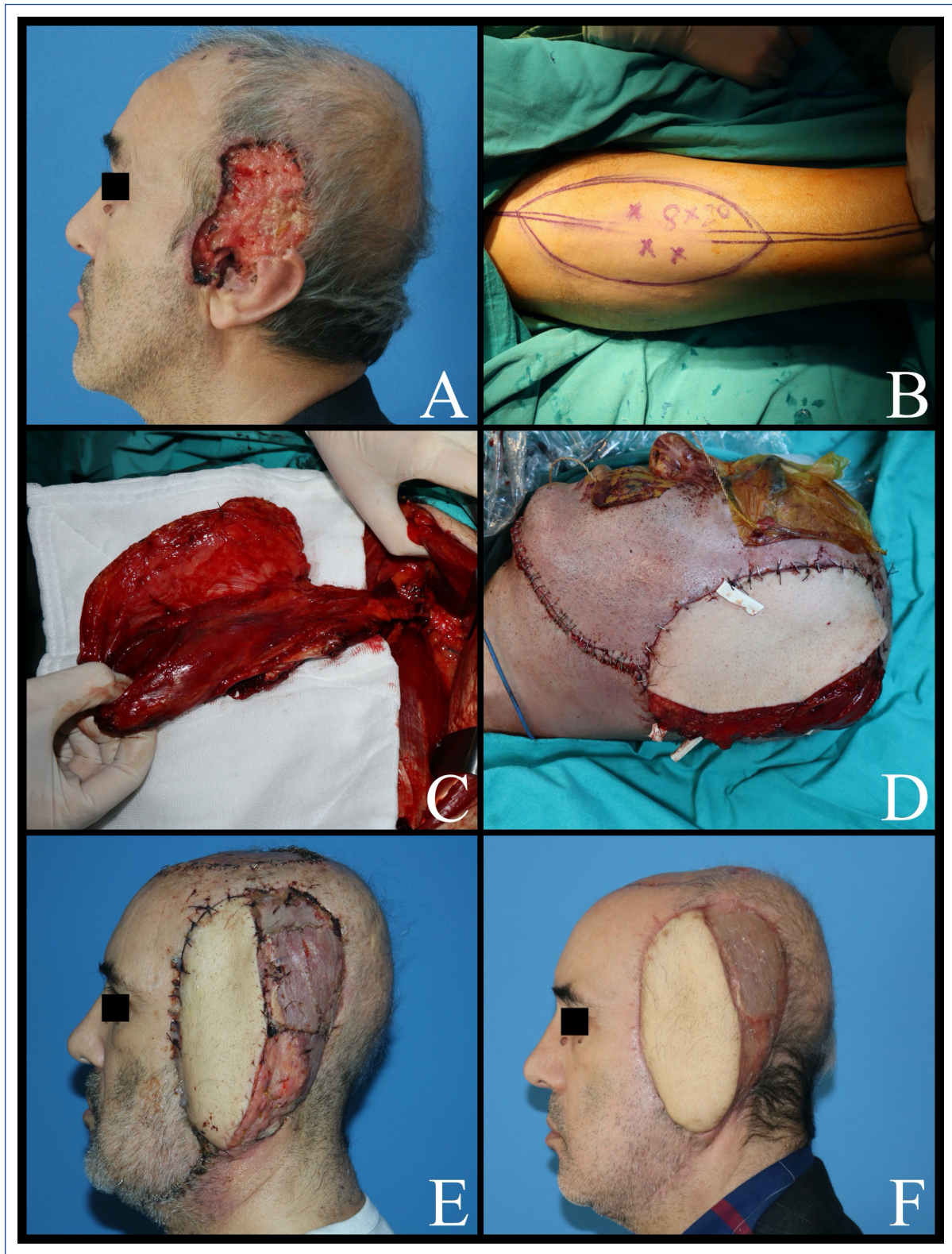


Figure 2. Case 5, one-stage reconstruction. A 63-year-old male patient was operated for the left temporal squamous cell carcinoma. (a) Lateral view of the preoperative tumoral mass. (b) per-operative anterolateral thigh flap planning. (c) Musculocutaneous anterolateral thigh flap view. (d) After neck dissection and flap adaptation early post-operative view. (e) Image of the 2nd post-operative week. (f) Image of the patient on the post-operative 6th week.

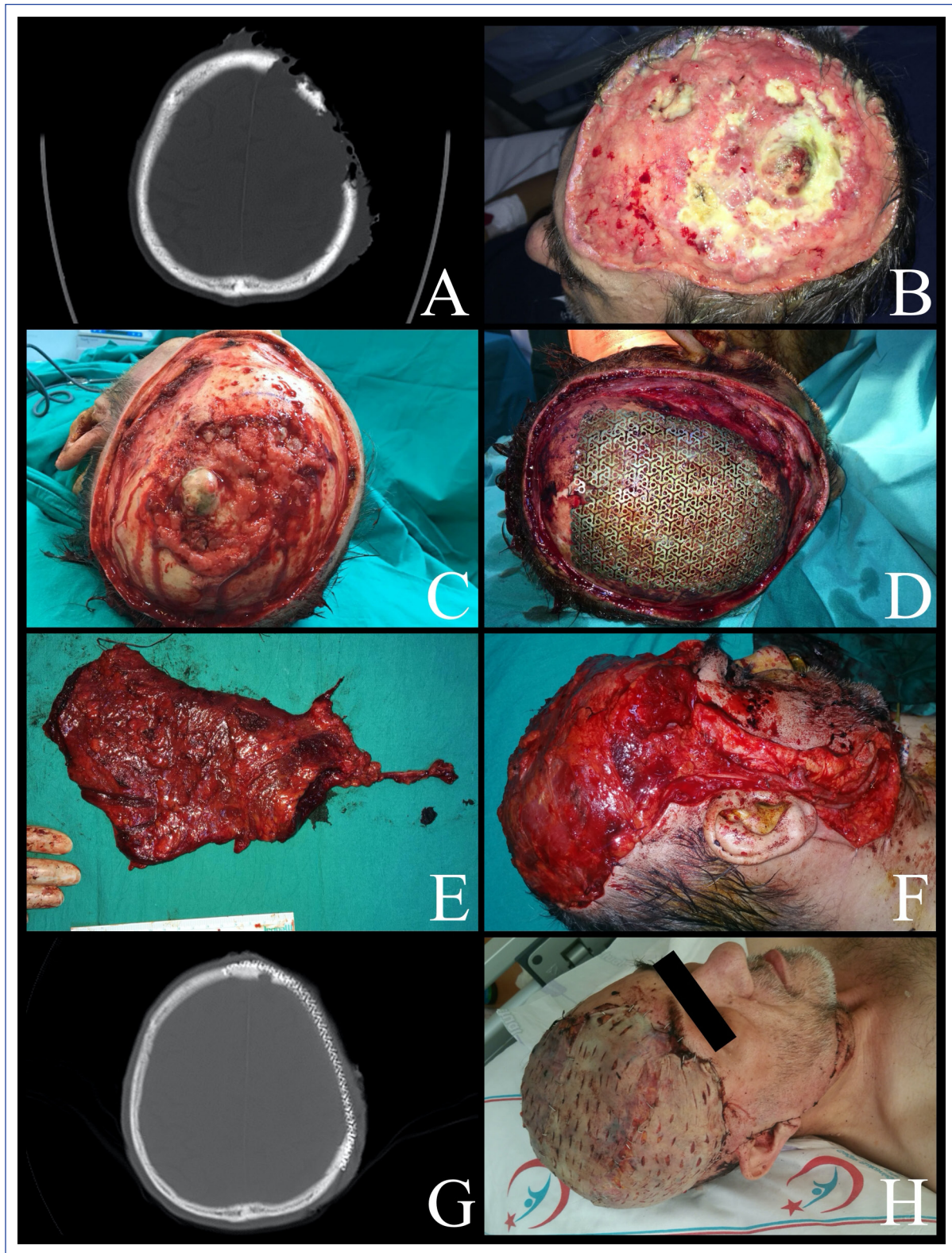


Figure 3. Case 3, one-stage reconstruction. A 62-year-old male patient operated on for squamous cell cancer in the frontotemporoparietal region. (a) Pre-operative computed tomography shows the intracranial extension of the mass. (b) Pre-operative view of the patient. (c) Per-operative tumor resection image. (d) Reconstruction of the bone defect with titanium mesh. (e) Image of the latissimus dorsi muscle flap. (f) Anastomosis of the flap vessels with vein graft to facial artery and vein. (g) Early post-operative computed tomography image. (h) Intact skin graft is seen in the early post-operative period.

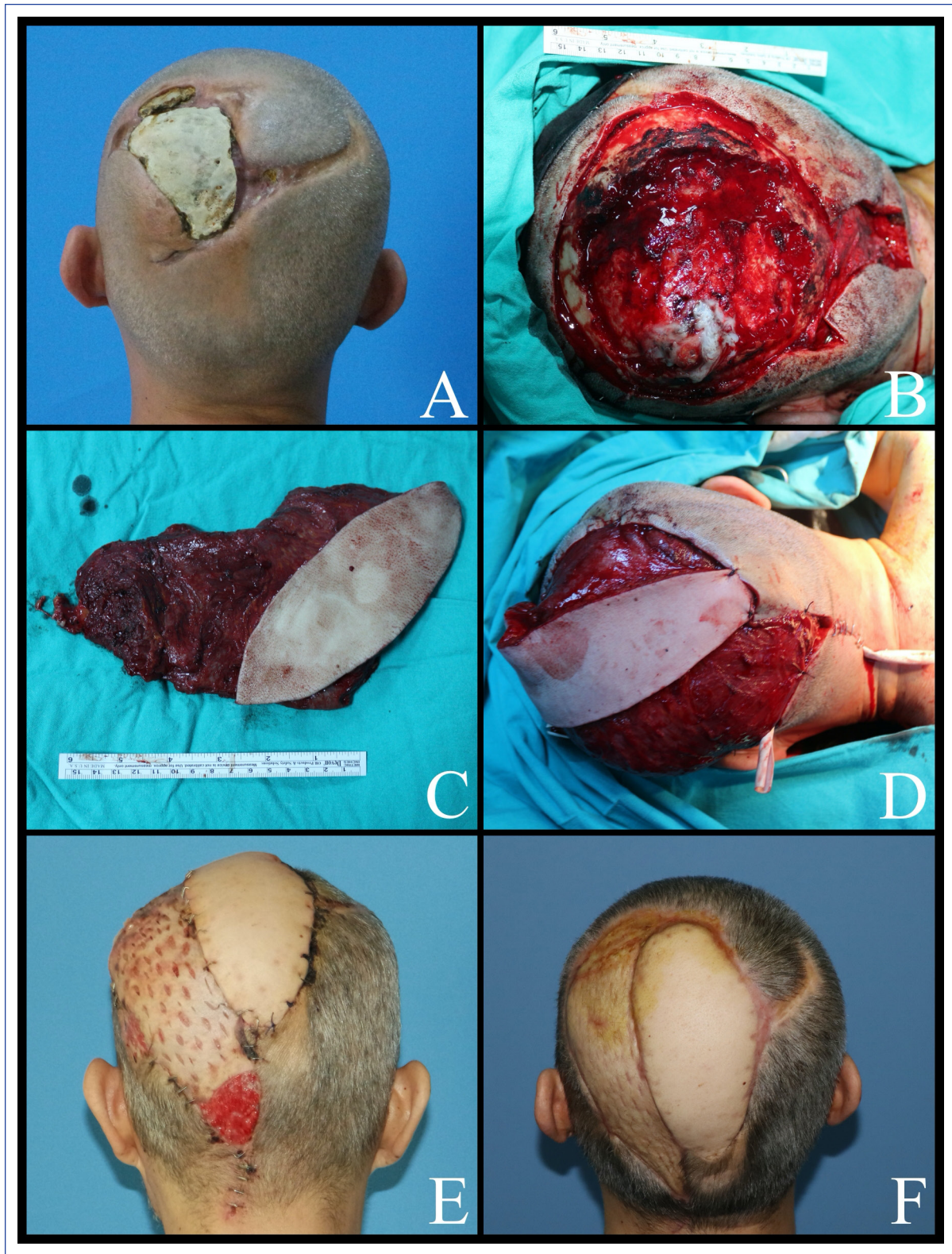


Figure 4. Case 7, two-stage reconstruction. First-stage reconstruction of a 38-year-old male patient operated for anaplastic oligodendroglioma. (a) Image of the pre-operative bone exposed defect area. (b) The view of unhealthy bone and soft tissues after debridement (c) Image of the musculocutaneous latissimus dorsi flap. (d) Early view of viable flap after anastomosis to the occipital artery and vein. (e) Post-operative 2nd week view of the patient. (f) Post-operative 3rd month view.

Free flaps used for reconstruction were musculocutaneous LD ($n=4$), LD muscle ($n=3$), ALT ($n=4$), musculocutaneous ALT ($n=1$), VL ($n=1$), and RAM ($n=1$). For the recipient artery, ipsilateral facial artery ($n=8$), ipsilateral superficial temporal artery ($n=5$), and contralateral occipital artery ($n=1$) were used. Vein anastomoses were made to veins of the same name as arteries. Anastomoses between facial artery and LD flap pedicle were mostly performed with interposition saphenous VGs ($n=5$) because of the long distance between the defect and recipient vessels. No flap loss was observed in any of the cases. A partial graft loss occurred in one case with musculocutaneous LD flap was treated with debridement followed by again grafting. A wound dehiscence occurred in one case with musculocutaneous LD was treated with debridement followed by primary repair. A seroma developed in an LD case's donor site, which was treated with serial aspirations. An unsatisfactory aesthetic result was detected in one patient and defatting was performed. The mean duration of the first and second operations was, respectively, 284 ± 59.2 and 90 ± 25.2 min. During the study period, one patient died 1 year after surgery due to urosepsis (case 3) and another patient died 2 years after surgery because of local recurrence of atypical meningioma (case 1). The mean follow-up duration was 14.3 ± 6.2 months (range 4–24 months).

Discussion

Complex scalp defect reconstructions are like a puzzle that needs to be solved due to the need for suitable recipient vessel, radiotherapy damage, osteomyelitis, implant exposure, the character of the defect, timing of reconstruction, the need for duraplasty, and cranioplasty.

Scalp defects can be challenging to cover even for experienced reconstructive surgeons because of the unpredictability and singularity of each case. The classical "reconstructive ladder" approach is useful to the plastic surgeon, as it helps thinking in an algorithmic way and guides the surgeon to close defects with the easiest possible surgical procedure. However, for complex, defects, it is important to evaluate the viability of tissue surrounding the wound, anticipate the future need of radiation therapy and make a durable reconstruction for the patient. Actually, failure to reconstruct a defect with local flaps would create a more challenging defect, because an implant removal or a more proximal recipient vessel dissection may be needed. For these reasons, it is very important to set aside the reconstructive ladder approach in complex scalp defects and to choose a "reconstructive elevator" with vascularized free tissue transfers.^[10]

LD is the most widely used myocutaneous flap for scalp reconstruction.^[11,12] Its reliable anatomy makes it a safe and easy flap to harvest. It has a long pedicle and can cover very large defects. Although LD looks bulky in the beginning, it atrophies with time and provides a good contour in scalp reconstruction. Some authors cite LD flap's denervation atrophy as unpredictable and sometimes causing palpation or exposition of implants.^[13] It was not seen in any patients during the follow-up period. Most of the cases in this study were reconstructed with LD flap. They were mostly post-craniectomy cases; all of them were reconstructed with titanium mesh. As no implant exposition occurred, LD was considered successful in these cases. The most common complication of the LD muscle flap is the donor area seroma. The frequency of seroma ranges from 1% to 80%.^[14] In this study, seroma was only encountered in one case, which resolved after serial aspirations. Since RA muscle flap results in bulky appearance in scalp defects, it has limited use. However, it is frequently preferred to fill dead spaces in maxillary and orbital reconstruction.^[15] In this study was used in one case for orbital defect reconstruction.

The ALT flap was introduced by Song *et al.* in 1984 and became the workhorse fasciocutaneous flap for free scalp reconstruction.^[16] ALT has a relatively constant anatomy, a long pedicle that can be further elongated up to 12 cm, permits a two-team approach because of its location and has a low donor site morbidity. ALT is a versatile flap that can be elevated as fasciocutaneous, adipocutaneous or as a chimeric flap with multiple skin islands and including a muscle. In a case with temporal SCC, ALT was raised as a myocutaneous flap including VL to fill the dead space formed after mastoidectomy. Another advantage is the possibility to add a vascularized fascia lata segment for duraplasty.^[13] The success of muscle flaps has been proven to prevent implant exposition and infection.^[17] In recent years, fasciocutaneous flaps have been reported to be as successful as muscle flaps in preventing infections.^[18,19] Two cases of cranioplasty made with titanium mesh were reconstructed with ALT flap and no implant exposure was encountered.

The choice of recipient vessels for anastomosis is an important subject matter. Superficial temporal artery is the most commonly used recipient artery, then comes the facial artery and other vessels including superior thyroid, posterior auricular, lingual, transverse cervical, external and common carotid, maxillary, and occipital artery.^[2,11-13,20] Even though the superficial temporal artery is the most preferred recipient artery, its small caliber and the intimal damage due to the previous surgeries or irradiation occasionally limit its usage. In these cases, facial artery is chosen

as a second option for recipient artery. However, facial artery is distant from scalp defects and requires frequently the use of interposition VG. The use of VG in free flap reconstruction is a matter of controversy. Some authors consider that the use of VG is associated with an increased flap failure rate whereas some studies show that their use is not associated with decreased flap survival.^[21,22]

In this study, anastomoses were mostly made to facial artery with VG in cases which superficial temporal arteries were of small caliber or previously damaged; no post-operative thrombosis or flap loss was observed. In cases reconstructed with ALT, the pedicle was elongated by dissecting the lateral descending branch up to the profunda femoris artery; no VG was used. Kim *et al.* reported a case of successful scalp reconstruction with omental flap, in which the anastomosis was made to the facial artery without the need for a VG.^[23] The omental flap may be a B plan in cases which VG are avoided, and ALT and superficial temporal arteries are not available. Omental flap requires laparotomy. Although it is laparoscopically harvested in recent years, there is always a risk of laparotomy and associated complications.^[24]

To the best of our knowledge, there is a one case in the literature that reported the use of occipital artery as a recipient artery in scalp reconstruction.^[20] In this study, a case with radiotherapy history, scalp defect was located in the parietooccipital area. After dissection, intimal damage in the ipsilateral occipital artery was found and anastomosis was performed to the contralateral occipital artery which was of good quality and caliber. We would like to emphasize the use of occipital artery as a recipient vessel especially in defects near the occipital area, because of its proximity and bilateral availability in that area. As a matter of fact, a similar scenario on the anterior side of the cranium would probably necessitate the use of VG.

The success in complex scalp defect reconstruction relies substantially on performing an extensive debridement of all nonviable and compromised tissues before final reconstruction. Complications such as wound infection, osteomyelitis, implant exposition can be seen after cranioplasty and are not uncommon.^[25] Complication rates up to 36% and secondary cranioplasty rates up to 76% were reported.^[26] In secondary cranioplasty cases, muscle flaps were preferred to prevent osteomyelitis and implant exposition. Moreover, it is especially recommended for radiotherapy wounds due to its high vascularity.^[27] Since the scalp is relatively poor in muscle tissue, free muscle flaps are the only option in muscle transfer.

In the second step of reconstruction, titanium mesh is used by entering from the suprafascial-submuscular plan. Choosing a dissection plan over the muscle fascia is

advantageous in several ways. First, it provides a bloodless plan and permitting a rapid dissection. Second, the muscle fascia that is left underneath provides a strong protection for the dura. Third, it allows to be covered with well vascularized muscle tissue over the implant material. Mukherjee *et al.* reported that period in which they observed the least complication rate was between 4 and 8 months in cases where they performed seconder cranioplasty with titanium mesh.^[25] In this study, the second step' of reconstruction was completed after an average of 5.3 months in four cases and no implant exposition was detected. These findings show that, in addition to flap preference, reconstruction timing is an important parameter in patients undergoing secondary cranioplasty with titanium mesh.

The main limitation of the study is, its retrospective design. In addition, the number of patients is limited. However, defects issuing from different etiologies, different reconstructive approaches were presented in all possible scalp locations.

Conclusion

Free tissue transfers rather than local flaps should be opted to reconstruct complex scalp defects, as failure of the latter, could create much greater defects and worse consequences. There are many options for proper reconstruction, and it is essential to select the appropriate reconstruction, taking into account the comorbid conditions of each case.

Disclosures

Ethics Committee Approval: The study was approved by the Local Ethics Committee (University of Health Sciences, Sisli Hamidiye Etfal Training and Research Hospital, 2954-25/08/2020).

Peer-review: Externally peer-reviewed.

Conflict of Interest: None declared.

Authorship Contributions: Concept – S.B., C.O.; Design – S.B., C.O.; Supervision – S.B., S.H.K.; Materials – S.B., C.O.; Data collection &/ or processing – S.B., C.O., H.I.E.; Analysis and/or interpretation – S.B., S.H.K, A.Y.; Literature search – S.B., C.O., H.I.E.; Writing – S.B., C.O.; Critical review – S.B., S.H.K., A.Y.

References

1. Bradford BD, Lee JW. Reconstruction of the forehead and scalp. *Facial Plast Surg Clin North Am* 2019;27:85–94. [\[CrossRef\]](#)
2. Browne JD, Burke AJ. Benefits of routine maxillectomy and orbital reconstruction with the rectus abdominis free flap. *Otolaryngol Head Neck Surg* 1999;121:203–9. [\[CrossRef\]](#)
3. Chao AH, Yu P, Skoracki RJ, Demonte F, Hanasono MM. Microsurgical reconstruction of composite scalp and calvarial

- defects in patients with cancer: a 10-year experience. *Head Neck* 2012;34:1759–64. [\[CrossRef\]](#)
4. Chou PY, Lin CH, Hsu CC, Yang WH, Kane AA, Lin CH. Salvage of postcranioplasty implant exposure using free tissue transfer. *Head Neck* 2017;39:1655–61. [\[CrossRef\]](#)
 5. Christy MR, Lipschitz A, Rodriguez E, Chopra K, Yuan N. Early postoperative outcomes associated with the anterolateral thigh flap in Gustilo IIB fractures of the lower extremity. *Ann Plast Surg* 2014;72:80–3. [\[CrossRef\]](#)
 6. Fodstad H, Love JA, Ekstedt J, Fridén H, Lilliequist B. Effect of cranioplasty on cerebrospinal fluid hydrodynamics in patients with the syndrome of the trephined. *Acta Neurochir (Wien)* 1984;70:21–30. [\[CrossRef\]](#)
 7. Furr MC, Cannady S, Wax MK. Interposition vein grafts in microvascular head and neck reconstruction. *Laryngoscope* 2011;121:707–11. [\[CrossRef\]](#)
 8. Gottlieb LJ, Krieger LM. From the reconstructive ladder to the reconstructive elevator. *Plast Reconstr Surg* 1994;93:1503–4. [\[CrossRef\]](#)
 9. Heron A, Michot A, Menez T, Jecko V, Penchet G, Casoli V. Secondary reconstruction of calvarial defects by using free flap: report of consecutive cases and analysis of strategy. *J Craniofac Surg* 2019;30:e151–5. [\[CrossRef\]](#)
 10. Hussussian CJ, Reece GP. Microsurgical scalp reconstruction in the patient with cancer. *Plast Reconstr Surg* 2002;109:1828–34. [\[CrossRef\]](#)
 11. Kim JW, Woo SH, Jang SY, Kim WS, Bae TH, Kim HK. Facial artery as a recipient vessel for extensive scalp reconstruction with free omental flap without vein graft. *J Craniofac Surg* 2018;29:e271–3. [\[CrossRef\]](#)
 12. Lamaris GA, Knackstedt R, Couto RA, Abedi N, Durand P, Gastman B. The anterolateral thigh flap as the flap of choice for scalp reconstruction. *J Craniofac Surg* 2017;28:472–6. [\[CrossRef\]](#)
 13. Mathes SJ, Alexander J. Radiation injury. *Surg Oncol Clin N Am* 1996;5:809–24. [\[CrossRef\]](#)
 14. Mathes SJ, Alpert BS, Chang N. Use of the muscle flap in chronic osteomyelitis: experimental and clinical correlation. *Plast Reconstr Surg* 1982;69:815–29. [\[CrossRef\]](#)
 15. McLean DH, Buncke HJ Jr. Autotransplant of omentum to a large scalp defect, with microsurgical revascularization. *Plast Reconstr Surg* 1972;49:268–74. [\[CrossRef\]](#)
 16. Mukherjee S, Thakur B, Haq I, Hettige S, Martin AJ. Complications of titanium cranioplasty—a retrospective analysis of 174 patients. *Acta Neurochir (Wien)* 2014;156:989–98. [\[CrossRef\]](#)
 17. Nelson JA, Fischer JP, Grover R, Kovach SJ, Low DW, Kanchwala SK, et al. Vein grafting your way out of trouble: Examining the utility and efficacy of vein grafts in microsurgery. *J Plast Reconstr Aesthet Surg* 2015;68:830–6. [\[CrossRef\]](#)
 18. Orticochea M. Four flap scalp reconstruction technique. *Br J Plast Surg* 1967;20:159–71. [\[CrossRef\]](#)
 19. Rios JL, Pollock T, Adams WP Jr. Progressive tension sutures to prevent seroma formation after latissimus dorsi harvest. *Plast Reconstr Surg* 2003;112:1779–83. [\[CrossRef\]](#)
 20. Scaglioni MF, Giunta G. Reconstruction of cranioplasty using the thoracodorsal artery perforator (TDAP) flap: A case series. *Microsurgery* 2019;39:207–14. [\[CrossRef\]](#)
 21. Sokoya M, Inman J, Ducic Y. Scalp and forehead reconstruction. *Semin Plast Surg* 2018;32:90–4. [\[CrossRef\]](#)
 22. Song YG, Chen GZ, Song YL. The free thigh flap: a new free flap concept based on the septocutaneous artery. *Br J Plast Surg* 1984;37:149–59. [\[CrossRef\]](#)
 23. Sosin M, De la Cruz C, Bojovic B, Christy MR, Rodriguez ED. Microsurgical reconstruction of complex scalp defects: an appraisal of flap selection and the timing of complications. *J Craniofac Surg* 2015;26:1186–91.
 24. Steiner D, Hubertus A, Arkudas A, Taeger CD, Ludolph I, Boos AM, et al. Scalp reconstruction: A 10-year retrospective study. *J Craniomaxillofac Surg* 2017;45:319–24. [\[CrossRef\]](#)
 25. Van Eeckhout GP, Garcia-Ceballos JI, Verdonck K, Plovier F, Wylock P. Microsurgical repair of scalp defects. *Eur J Plast Surg* 2006;29:115–22. [\[CrossRef\]](#)
 26. Yazar S, Lin CH, Lin YT, Ulusal AE, Wei FC. Outcome comparison between free muscle and free fasciocutaneous flaps for reconstruction of distal third and ankle traumatic open tibial fractures. *Plast Reconstr Surg* 2006;117:2468–75. [\[CrossRef\]](#)
 27. Zaha H, Inamine S. Laparoscopically harvested omental flap: results for 96 patients. *Surg Endosc* 2010;24:103–7. [\[CrossRef\]](#)