

# Neonatal Hypercalcemia Secondary to Subcutaneous Fat Necrosis Successfully Treated with Pamidronate: A Case Series and Literature Review

Veronica Mugarab Samedi<sup>1,2</sup> Kamran Yusuf<sup>2</sup> Wendy Yee<sup>2</sup> Hala Obaid<sup>3</sup> Essa Hamdan Al Awad, MD<sup>1,2</sup>

<sup>1</sup> Section of Neonatology, Peter Lougheed Centre, Calgary, Alberta, Canada

<sup>2</sup> Section of Neonatology, University of Calgary, Calgary, Alberta, Canada

<sup>3</sup> Department of Pediatrics, University of Calgary, Calgary, Alberta, Canada

Address for correspondence Essa Hamdan Al Awad MD, Section of Neonatology, Peter Lougheed Centre, 3500 – 26 Ave NE, Calgary AB, T1Y 6J4, Canada (e-mail: Veronica.Samedi@albertahealthservices.ca; essa.alawad@albertahealthservices.ca).

Am J Perinatol Rep 2014;4:e93–e96.

## Abstract

Subcutaneous fat necrosis (SCFN) is a noninfectious panniculitis that occurs in term infants who experience significant distress in the 1st weeks of life, including hypoxic ischemic encephalopathy (HIE). Since the introduction of therapeutic hypothermia for HIE, there have been a few published case reports of SCFN, following this modality of treatment. Although, most cases of SCFN resolve spontaneously, SCFN may be associated with hypercalcemia, which may sometimes reach dangerous levels. Approaches used for the management of this potentially life-threatening condition, include hyperhydration, calciuric diuretics, corticosteroids, and in more resistant cases pamidronate, a bisphosphonate. We report our experience on the use of pamidronate in two cases of severe hypercalcemia associated with SCFN following therapeutic hypothermia for HIE. We believe that with increasing use of therapeutic hypothermia for HIE, clinicians are likely to encounter this condition more frequently.

## Keywords

- ▶ hypercalcemia
- ▶ therapeutic hypothermia
- ▶ newborn
- ▶ pamidronate
- ▶ subcutaneous fat necrosis

Subcutaneous fat necrosis (SCFN) is a noninfectious panniculitis that occurs in term infants who experience significant distress in 1st weeks of life, including hypoxic ischemic encephalopathy (HIE).<sup>1–3</sup> Since the introduction of therapeutic hypothermia for HIE, there have been a few case reports SCFN published following this modality of treatment.<sup>4–6</sup> Although, most cases of SCFN resolve spontaneously, SCFN may be associated with hypercalcemia, which may sometimes reach dangerous levels.<sup>7–9</sup> Approaches used for the management of this potentially life-threatening condition, include hyperhydration, calciuric diuretics, corticosteroids and in more resistant cases pamidronate, a bisphosphonate.<sup>9–14</sup> We report our experience on the use of pamidronate in two cases of severe hypercalcemia associated with SCFN

following therapeutic hypothermia for HIE. We believe that with increasing use of therapeutic hypothermia for HIE, clinicians are likely to encounter this condition more frequently.

## Case Report

### Case 1

A full-term female infant, born by emergency caesarean section due to fetal distress to a 34-year-old primi gravida mother whose pregnancy was complicated with gestational diabetes controlled by diet. Resuscitation in case room included intubation at birth for thick meconium and blood clots; baby required intermittent positive pressure

received  
July 23, 2013  
accepted after revision  
October 1, 2014  
published online  
November 19, 2014

DOI <http://dx.doi.org/10.1055/s-0034-1395987>.  
ISSN 2157-6998.

Copyright © 2014 by Thieme Medical Publishers, Inc., 333 Seventh Avenue, New York, NY 10001, USA.  
Tel: +1(212) 584-4662.

License terms



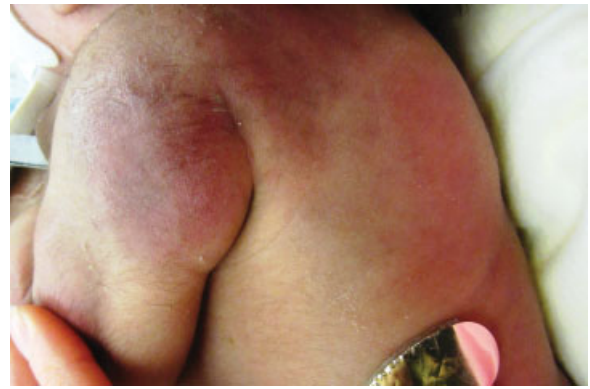ventilation on 100% oxygen and was transferred to the neonatal intensive care unit (NICU). Her Apgar scores were 1, 6, and 8 at 1, 5, and 10 minutes, respectively, and the cord pH was 6.85 and BE was  $-17$ . Based on clinical examination, cord pH and BE, the baby was diagnosed to have HIE and qualified for therapeutic cooling.

Baby underwent a complex course at the NICU which included persistent pulmonary hypertension secondary to meconium aspiration that was managed with surfactant therapy, high-frequency ventilation, inhaled nitric oxide and prostacyclin, multiorgan dysfunction that involved resistant hypotension with globally decreased biventricular function required inotropes (managed with multiple normal saline boluses, dopamine, dobutamine, and hydrocortisone infusions); acute renal failure and developed disseminated intravascular coagulopathy at 4 hours of life (required multiple transfusions of fresh frozen plasma, cryoprecipitate as well as red blood cells and platelets transfusions). Baby had partial sepsis work-up and completed 5 days course on antibiotics.

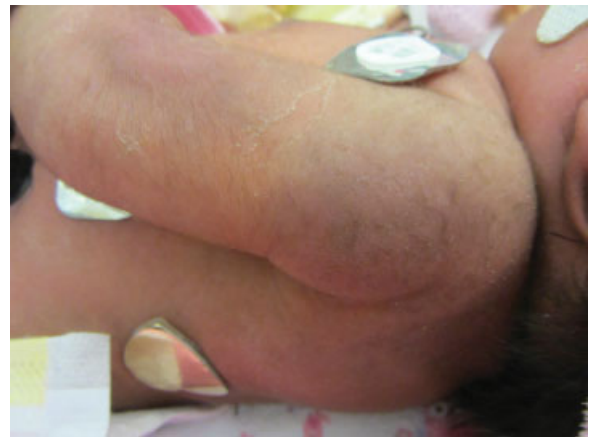P-therapeutic hypothermia was initiated within the 1st hour of life and continued for 72 hours. The core body temperature was maintained at  $34^{\circ}\text{C}$  during cooling and after 72 hours the baby was rewarmed at a rate of  $0.5^{\circ}\text{C}/\text{h}$  until a normal body temperature of  $36.5^{\circ}\text{C}$  was reached. There were no clinical seizures or abnormal neurological symptoms noted during her hospital stay. Magnetic resonance imaging (MRI) of the brain performed on the 5th day of life demonstrated small areas of questionable ischemic changes in the occipital cortex bilaterally. Electroencephalogram was done twice (on days 3 and 5) and showed nonspecific slowing with no epileptogenic potentials or subclinical seizures.

On the 10th day of life, she developed nodular, indurated, erythematous lesions in the right shoulder and interscapular space typical suggestive of SCFN ( $\rightarrow$  Figs. 1 and 2) with total affected area approximately  $17\text{cm}^2$  of skin surface. In view of potential risk of hypercalcemia serial calcium levels were done during the first 3 weeks of life and were unremarkable. However, on the 26th day of life her calcium level was  $4.15\text{ mmol/L}$  (normal range  $1.9\text{--}2.6\text{ mmol/L}$ ) with ionized calcium of  $1.86\text{ mmol/L}$  (normal levels). Other laboratory tests showed normal levels of phosphate ( $1.92\text{ mmol/L}$ ), alkaline phosphatase ( $172\text{ units/L}$ ), and 25-hydroxy vitamin D ( $100\text{ mmol/L}$ ). Parathyroid hormone level was significantly decreased (less than  $4\text{ mg/L}$ —normal range is  $13\text{--}54\text{ mg/L}$ ). Vitamin D supplements were stopped, and oral feeds were stopped. Intravenous fluids were given for hyperhydration and furosemide was started in a dose of  $1\text{ mg/kg}$  per dose every 12 hours.

Despite this aggressive treatment, calcium levels did not show significant improvement (calcium was  $3.56\text{ mmol/L}$ ), pamidronate was started on day 27 of life in a dose of  $0.25\text{ mg/kg}$ , and level of total calcium postinfusion was  $3.5\text{ mmol/L}$  with ionized calcium of  $1.5\text{ mmol/L}$ . Given the small decrease in calcium levels, a higher dose of  $0.5\text{ mg/kg}$  on three consecutive days starting on day 28 of life resulted in normalization of calcium levels. Total duration of hypercalcemia



**Fig. 1** Subcutaneous fat necrosis on baby N, on day 12 of life, with nodular, indurated, erythematous lesions in the right shoulder and interscapular space.



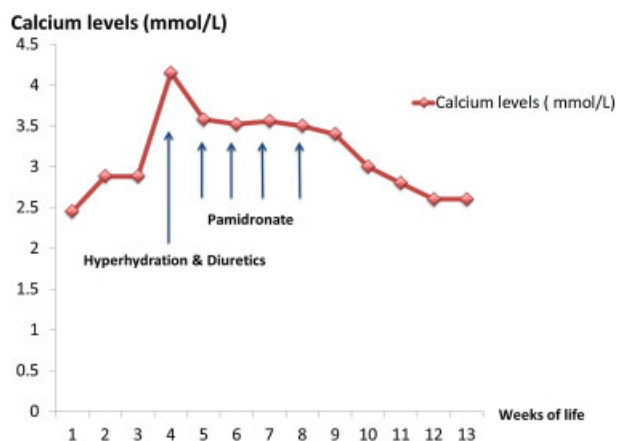
**Fig. 2** Same infant on day 20 of life, lesions are less erythematous, started to resolve.

(with treatment) was about 1 week. No side effects were observed during treatment.

Total calcium before discharge home on day 33 of life was  $2.94\text{ mmol/L}$  with ionized calcium  $1.6\text{ mmol/L}$ . To date, all calcium levels postpamidronate treatment have been normal last calcium level at the age of 2 months was  $2.65\text{ mmol/L}$  and phosphate  $1.79\text{ mmol/L}$ . Mild nephrocalcinosis was noted on renal ultrasound on 26th day of life. A repeat renal ultrasound on 45th day of life showed signs of resolution of the nephrocalcinosis ( $\rightarrow$  Fig. 3). Baby continues to gain weight on exclusive breastfeeding. The follow-up of serum calcium level will be continued till 6 months. Vitamin D is on hold at least for next 3 months.

## Case 2

A full-term female infant, born by spontaneous vaginal delivery to a 27-year-old primi gravida mother with an uneventful pregnancy. At the time of birth there was a knot in the umbilical cord and thick meconium was present. Her Apgar scores were 5, 7, and 7 at 1, 5, and 10 minutes, respectively; the cord pH was  $7.11$  (BE was not documented); baby cried and was vigorous at birth, resuscitation in case

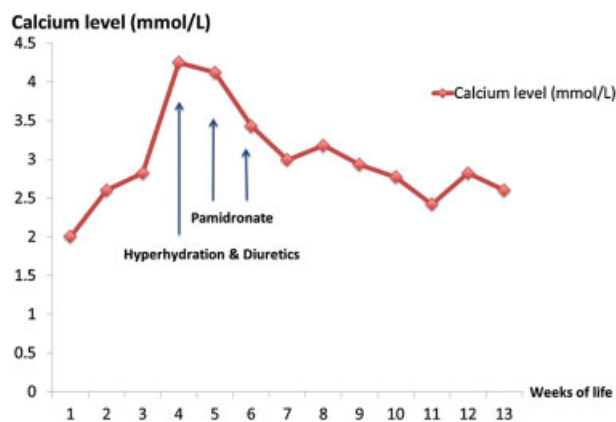


**Fig. 3** Calcium level for infant N: before, during, and after the treatment.

room included oral suction only. Baby initially did well but within 1st hour of life developed progressive respiratory distress that required intubation and surfactant administration. In view of worsening condition baby was transferred to the level-three intensive care.

Course at NICU was complicated and included persistent pulmonary hypertension secondary to meconium aspiration that was managed with surfactant therapy, mechanical ventilation, and inhaled nitric oxide. Systemic hypotension managed with normal saline boluses, dopamine, and dobutamine. Although blood cultures were negative, the baby received 7 days of antibiotics for presumed sepsis. The most serious part of clinical course was HIE that presented on the 1st day of life with central hypotonia, tonic-clonic seizures, and abnormal eye movements. Therapeutic hypothermia was initiated immediately and continued for 72 hours. Seizures were treated with phenobarbital. Follow-up MRI showed bilateral occipital subdural hematomas and follow-up electroencephalogram was normal. At the age of 14 days she developed firm erythematous subcutaneous lesions on the nape of her neck, between the scapula and over the shoulders which were diagnosed as SCFN. Approximate affected area was about 18 cm<sup>2</sup> of skin surface. Calcium level at the time was high normal (2.82 mmol/L).

At the age of 29 days she was readmitted through the emergency room for failure to thrive, hypotonia, and lethargy and found to have critical hypercalcemia with a total calcium level of 4.25 mmol/L and ionized calcium of 1.91 mmol/L. She was immediately transferred to pediatric intensive care unit with diagnosis of serious hypercalcemia secondary to SCFN. Initial management was hyperhydration, diuretics, and methylprednisolone 2 mg/kg/dose, and one dose of pamidronate 0.5 mg/kg. Initial normalization of calcium level was followed by rebound up to 3.19 mmol/L, and a repeat dose of pamidronate was given which normalized the calcium. No side effects were observed during treatment. Total calcium before discharge home on day 38 of life was 2.71 mmol/L with ionized calcium 1.4 mmol/L. Baby was subsequently kept on a low vitamin D and low calcium diet (Calcilo XD). She was followed by Pediatrician, endocrinology, and nephrology



**Fig. 4** Calcium level for infant F: before, during, and after the treatment.

clinics for failure to thrive, hypercalcemia and bilateral nephrocalcinosis. Subsequent calcium levels at follow-up till the age of 3 months were normal (→ Fig. 4).

## Discussion

SCFN is a noninfectious inflammatory disorder of adipocytes presenting within 1st weeks of life as erythematous, indurated, painful, subcutaneous nodules usually located over the cheeks, back, shoulders, and buttocks. Although the cause is unknown, typically, there is a history of intrauterine or perinatal distress in almost all cases. Predisposing conditions include but are not limited to ischemic injury, perinatal hypoxia, hypothermia, meconium aspiration, Rh incompatibility, obstetric trauma, sepsis, gestational diabetes, and preeclampsia.<sup>2,3,11</sup> The subcutaneous fat in infants has a high concentration of saturated fatty acids (stearic and palmitic acids) with a high melting point. In addition, enzyme systems involved in fatty acid metabolism are not fully developed.<sup>1,9,12</sup> Different stressors may exacerbate this enzyme defect and result in increased levels of saturated fatty acids in fat deposits. At the same time, high melting point of the saturated fatty acids may cause crystallization of fat, result in adipocyte necrosis triggering a granulomatous reaction.<sup>5,7,15</sup> SCFN is mostly a self-limited process that resolves within weeks or months. However, this condition known to be associated with frequent metabolic complications as hypoglycemia, hypertriglyceridemia, or with hematological complications as anemia and thrombocytopenia. Hypercalcemia is the most dangerous one. Local lesions gradually become in a fibrosed with fat atrophy. There are no commonly known cosmetic consequences of this condition.<sup>3,7,9</sup> The differential diagnoses include sclerema neonatorum, erythema nodosum, and bacterial cellulitis. Common comorbidities associated with SCFN include hypoglycemia, anemia, thrombocytopenia, hypertriglyceridemia, and potentially life-threatening hypercalcemia.<sup>2,10,14,16</sup> Hypercalcemia usually develops when skin lesions begin to resolve. However, skin lesions usually resolve over a period of weeks to several months, while hypercalcemia can persist longer and require

regular monitoring. In some cases hypercalcemia may present as late as up to 6 months after the fat necrosis resolved.<sup>8</sup>

The exact cause of hypercalcemia in SCFN is unknown. Possible explanations include high levels of 1, 25-dihydroxyvitamin D3 secreted by macrophages resulting in increased calcium absorption, increased prostaglandin activity leading to osteoclast activation, and direct calcium release from necrotic fat cells.<sup>7,17,18</sup>

The first line of treatment for hypercalcemia in infants with SCFN is hyperhydration, calcium wasting diuretics, and dietary vitamin D and calcium restriction. In case of dangerously high hypercalcemia alternative choices are corticosteroid therapy and pamidronate.<sup>9,14,16,19</sup>

Corticosteroids act slowly than pamidronate and in most cases help to achieve normalization in serum calcium level within a week. The mechanism of their action is interference with the metabolism of vitamin D and increase renal calcium excretion, raising the risk of common complications such as nephrocalcinosis.<sup>4,5,14</sup>

In situations when a rapid response is desired, pamidronate is another valid option. Pamidronate belongs to the bisphosphonates group of drugs and acts by inhibiting the activity of osteoclasts and blocking dissolution of bone calcium phosphate (hydroxyapatite) crystals. Bisphosphonates bind closely to hydroxyapatite bone mineral surfaces and are selectively internalized by osteoclasts, where they inhibit their activity.<sup>18</sup> Nitrogen-containing bisphosphonates inhibit the mevalonate pathway, the main target being farnesyl diphosphate synthase.<sup>17</sup>

Side effects of pamidronate include an acute “flu-phase” reaction with fever, myalgia, bone pain, vomiting, and hypocalcemia. Three to four doses of pamidronate 0.25–0.5 mg/kg have been found to be both effective and well tolerated in neonates.<sup>14,15,19</sup> Alos et al<sup>16</sup> reported four patients with severe hypercalcemia secondary to SCFN who received three to four doses of pamidronate (0.25–0.50 mg/kg/dose). The author suggested that pamidronate may be used as first-line treatment for severe hypercalcemia in infants with SCFN with the aim of reducing nephrocalcinosis. To date only 11 patients with hypercalcemia secondary to SCFN treated with intravenous pamidronate have been reported in the literature.<sup>16,20</sup> In the two presented cases we described the effective normalization of calcium levels after pamidronate treatment and not to corticosteroids. In the first case, pamidronate was started early, used in daily injections regimen, and did not cause any side effects.

## Conclusion

In conclusion, newborns with HIE treated with therapeutic hypothermia can develop SCFN which may lead to significant hypercalcemia. With the increasing use of therapeutic hypothermia for HIE, health caregivers looking after infants are likely to encounter this condition more frequently. In the two presented cases of critical hypercalcemia that did not respond to diuretics and hyperhydration, pamidronate was effective as a fast and safe treatment for hypercalcemia that could minimize or totally eliminate the need for

therapy with corticosteroids and decrease the length of hospital stay.

## References

- Akin MA, Akin L, Coban D, Akcakus M, Balkanli S, Kurtoglu S. Post-operative subcutaneous fat necrosis in a newborn: a case report. *Fetal Pediatr Pathol* 2011;30(6):363–369
- Hicks MJ, Levy ML, Alexander J, Flaitz CM. Subcutaneous fat necrosis of the newborn and hypercalcemia: case report and review of the literature. *Pediatr Dermatol* 1993;10(3):271–276
- Tran JT, Sheth AP. Complications of subcutaneous fat necrosis of the newborn: a case report and review of the literature. *Pediatr Dermatol* 2003;20(3):257–261
- Shankaran S, Laptook AR, Ehrenkranz RA, et al; National Institute of Child Health and Human Development Neonatal Research Network. Whole-body hypothermia for neonates with hypoxic-ischemic encephalopathy. *N Engl J Med* 2005;353(15):1574–1584
- Sivanandan S, Rabi Y, Kamaluddeen M, Akierman A, Lodha A. Subcutaneous fat necrosis as a complication of therapeutic hypothermia in a term neonate. *Indian J Pediatr* 2012;79(5):664–666
- Strohm B, Hobson A, Brocklehurst P, Edwards AD, Azzopardi D; UK TOBY Cooling Register. Subcutaneous fat necrosis after moderate therapeutic hypothermia in neonates. *Pediatrics* 2011;128(2):e450–e452
- Bonnemains L, Rouleau S, Sing G, Boudierlique C, Coutant R. Severe neonatal hypercalcemia caused by subcutaneous fat necrosis without any apparent cutaneous lesion. *Eur J Pediatr* 2008;167(12):1459–1461
- Borgia F, De Pasquale L, Cacace C, Meo P, Guarneri C, Cannavo SP. Subcutaneous fat necrosis of the newborn: be aware of hypercalcemia. *J Paediatr Child Health* 2006;42(5):316–318
- Katz DA, Huerter C, Bogard P, Braddock SW. Subcutaneous fat necrosis of the newborn. *Arch Dermatol* 1984;120(11):1517–1518
- Aucharaz KS, Baker EL, Millman GC, Ball RJ. Treatment of hypercalcemia in subcutaneous fat necrosis is controversial. *Horm Res* 2007;68(1):31
- Burden AD, Krafchik BR. Subcutaneous fat necrosis of the newborn: a review of 11 cases. *Pediatr Dermatol* 1999;16(5):384–387
- Cagle JJ, Reyes S. Subcutaneous fat necrosis of the newborn: a case presentation. *J Perinatol* 1996;16(2 Pt 1):140–141
- Hakan N, Aydin M, Zenciroglu A, et al. Alendronate for the treatment of hypercalcemia due to neonatal subcutaneous fat necrosis. *Eur J Pediatr* 2011;170(8):1085–1086, author reply 1087
- Lombardi G, Cabano R, Bollani L, Del Forno C, Stronati M. Effectiveness of pamidronate in severe neonatal hypercalcemia caused by subcutaneous fat necrosis: a case report. *Eur J Pediatr* 2009;168(5):625–627
- Sfaihi L, Kmiha S, Aloulou H, Kamoun T. Bisphosphonate therapy in subcutaneous fat necrosis with hypercalcemia and nephrocalcinosis in the newborn. *J Neonatal Nurs* 2013;19:76–79
- Alos N, Eugène D, Fillion M, Powell J, Kokta V, Chabot G. Pamidronate: Treatment for severe hypercalcemia in neonatal subcutaneous fat necrosis. *Horm Res* 2006;65(6):289–294
- Dunford JE, Thompson K, Coxon FP, et al. Structure-activity relationships for inhibition of bone resorption in vivo by nitrogen-containing bisphosphonates. *J Pharmacol Exp Ther* 2001;296(2):235–242
- Russell RG, Rogers MJ. Bisphosphonates: from the laboratory to the clinic and back again. *Bone* 1999;25(1):97–106
- Khan N, Licata A, Rogers D. Intravenous bisphosphonate for hypercalcemia accompanying subcutaneous fat necrosis: a novel treatment approach. *Clin Pediatr (Phila)* 2001;40(4):217–219
- Farooque A, Moss C, Zehnder D, Hewison M, Shaw NJ. Expression of 25-hydroxyvitamin D3-1alpha-hydroxylase in subcutaneous fat necrosis. *Br J Dermatol* 2009;160(2):423–425