

[CASE REPORT]

Hematemesis due to Drug Allergy to Oral Prednisolone in a Patient with Ulcerative Colitis

Takahiro Arisaka¹, Mimari Kanazawa¹, Keiichi Tominaga¹, Fumiaki Takahashi¹,
Kazuhiro Takenaka¹, Takeshi Sugaya¹, Osamu Arisaka²,
Atsushi Irisawa¹ and Hideyuki Hiraishi¹

Abstract:

The patient was diagnosed with ulcerative colitis and received remission induction therapy with prednisolone. While they developed muscle pain in the lower extremities after starting prednisolone, they ultimately achieved clinical remission. After discharge, hematemesis and gastric discomfort developed. Esophagogastroduodenoscopy showed mucosal edema, redness, and oozing bleeding in the gastric body. In addition, the patient had bloody stool and was considered to have a relapse of ulcerative colitis. They therefore received remission induction therapy with tacrolimus. The patient achieved clinical remission again; however, gastric discomfort and muscle pain remained. A drug lymphocyte stimulation test revealed positivity for prednisolone; therefore, the patient was diagnosed with an allergy to prednisolone.

Key words: ulcerative colitis, prednisolone, drug allergy, hematemesis, drug lymphocyte stimulation test

(Intern Med 58: 1093-1096, 2019)

(DOI: 10.2169/internalmedicine.1639-18)

Introduction

Corticosteroids seem to be rare causes of immediate hypersensitivity reactions (1). We herein report our experience with a patient with ulcerative colitis who developed hematemesis due to drug allergy to oral prednisolone.

Case Report

A 19-year-old man developed diarrhea and bloody stool; however, there were no abnormalities on close investigation 8 months before the first visit. Two months before the first visit, the patient had bloody stool (seven to eight times a day) again.

One month before the first visit to our hospital, the patient underwent upper gastrointestinal (GI) endoscopy at another facility, but no abnormalities were detected at that time. He was then referred to our hospital. The patient was diagnosed with ulcerative colitis (total colitis type) after colonoscopy and was admitted to our department. The clinical

course was considered relapsing-remitting type. The patient received remission induction therapy with mesalazine 3,600 mg/day and prednisolone 60 mg/day. Although he experienced muscle pain in the lower extremities after starting prednisolone, he ultimately achieved clinical remission and was discharged on day 35. Eleven days after discharge, the patient developed gastric discomfort, hematemesis, and bloody stool. He was suspected of having upper GI bleeding and ulcerative colitis relapse and was therefore re-admitted to the hospital.

The patient's drug history was summarized as follows: Mesalazine (Asacol[®]) 3,600 mg/day, prednisolone (Predonine[®]) 20 mg/day, rabeprazole (Pariet[®]) 10 mg/day, and sulfamethoxazole/trimethoprim (ST; Baktar[®] combination tablets) 1 tablet/day.

Physical findings on admission were as follows: body height 173 cm, body weight 82 kg, blood pressure 119/63 mmHg, pulse rate 95 beats/min, and body temperature 36.2°C. The heart and respiratory sounds were clear. His abdomen was flat and soft, with no abnormalities on percussion. Spontaneous pain and tenderness were observed in the

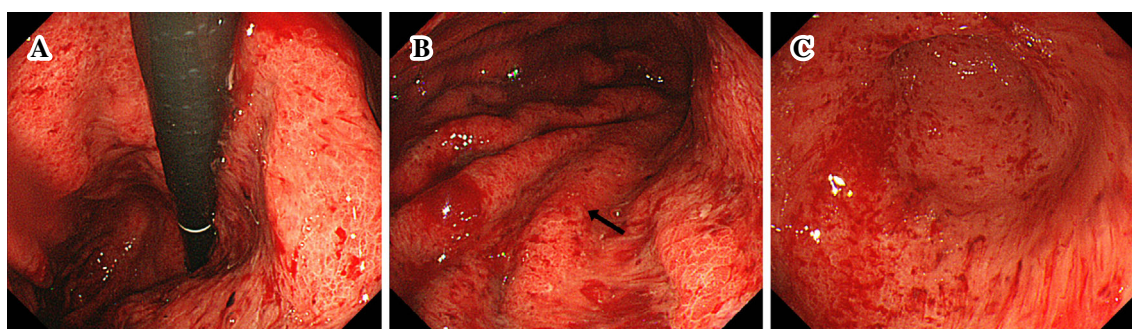
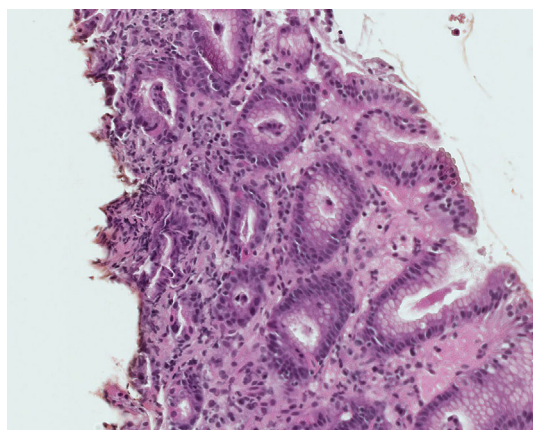
¹Department of Gastroenterology, Dokkyo Medical University, Japan and ²Department of Pediatrics, Nasu Red Cross Hospital, Japan

Received: June 4, 2018; Accepted: September 26, 2018; Advance Publication by J-STAGE: December 18, 2018

Correspondence to Dr. Mimari Kanazawa, mimari77@dokkyomed.ac.jp

Table. Drug Lymphocyte Sensitivity Test (Considered Positive If the Stimulation Index Is $\geq 180\%$).

Medicine (Product name)	Measured value (ppm)	Stimulation index (%)
Mesalazine (Asacol [®])	50	75
Prednisolone (Predonine [®])	760	1,151
Sulfamethoxazole, Trimethoprim (Bacter [®])	63	95
Rabeprazole (Pariet [®])	47	71
Brotizolam (Lendormin [®])	48	72
Methylprednisolone (Solu-Medrol [®])	319	168
Betamethasone (Rinderon [®])	273	144
Dexamethasone (Decadron [®])	320	169
Hydrocortisone (Saxison [®])	280	148
CONTROL	66	

**Figure 1.** Upper esophagogastrroduodenoscopy results on admission. Mucosal edema, easily bleeding mucosa with redness, and spontaneous bleeding were observed. A: Lesser curvature of the lower gastric body. B: Greater curvature of the middle gastric body. The biopsy site is indicated by an arrow. C: Antral greater curvature.**Figure 2.** Moderate inflammatory cell infiltration was observed.

epigastric region. Gastric lavage revealed bloody fluid. Fresh blood was observed on a rectal examination. His frequency of bowel movement was two or three times a day. Diarrhea and mucous and bloody stool were observed. Muscle pain in the lower extremities appeared immediately after starting prednisolone. The clinical activity index was 7 points (1). A clinical laboratory examination revealed a hemoglobin level of 12.6 g/dL with decreased total protein and albumin lev-

els. His white blood cell count was $16.0 \times 10^3/\mu\text{L}$, C-reactive protein was 2.56 mg/dL, and erythrocyte sedimentation rate was 1.4%. *Helicobacter pylori* IgG antibody, cytomegalovirus antigen, and *Clostridium difficile* were negative. Drug lymphocyte stimulation test (DLST) results [considered positive if the stimulation index (SI) is $\geq 180\%$] are shown in the Table.

On day 1, emergency esophagogastrroduodenoscopy (EGD) was performed for upper GI bleeding, which showed mucosal edema, redness, and oozing bleeding mainly in the gastric body (Fig. 1). A biopsy was not performed because there was mucosal bleeding. We performed an examination to determine if an infection was present, and all tests were negative. We also considered the possibility of a drug allergy to mesalazine or ST mixture and discontinued the drugs on admission. On day 3, EGD was performed again, which still showed mucosal edema, redness, and oozing bleeding. A biopsy was performed for further investigation. A histological examination showed moderate inflammatory cell infiltration but no clear eosinophil infiltration (Fig. 2). In addition, after the discontinuation of mesalazine, the frequency of bowel movement increased, and the bloody stool showed an exacerbating tendency, so colonoscopy was performed in order to assess the mucosa. Colonoscopy showed findings of inflammation throughout the large intestine, with

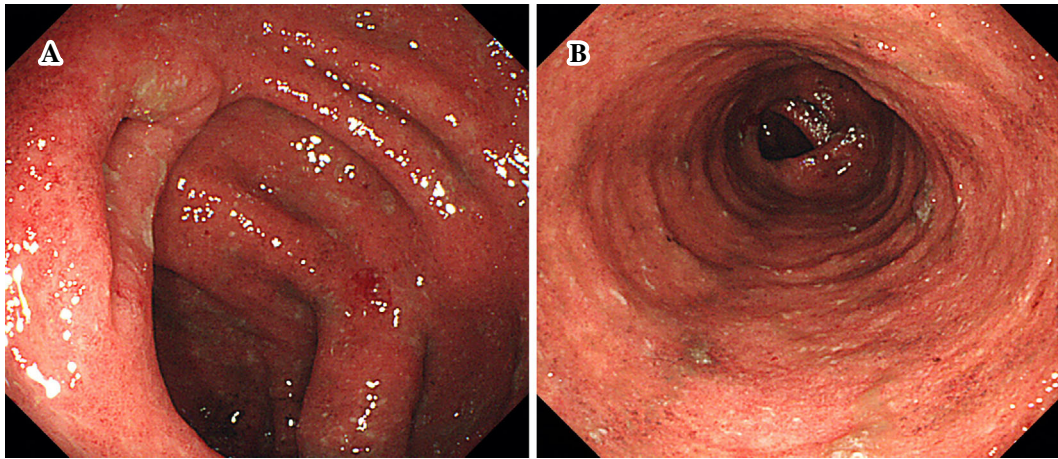


Figure 3. Colonoscopy results after admission. Findings of inflammation in the entire large intestine, with a Mayo endoscopic score of 2, were observed. A: Ileocecal area. B: Descending colon.

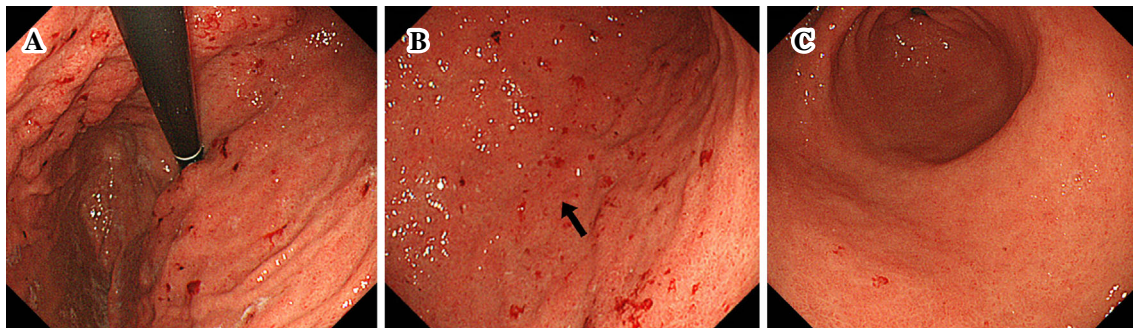


Figure 4. Upper esophagogastroduodenoscopy findings after the discontinuation of prednisolone. A reduction of the redness and improvement in mucosal edema were observed compared with the previous endoscopy results. A: Anterior wall side of the lesser curvature of the upper gastric body. B: Greater curvature of the middle gastric body. The biopsy site is indicated by an arrow. C: Antral greater curvature.

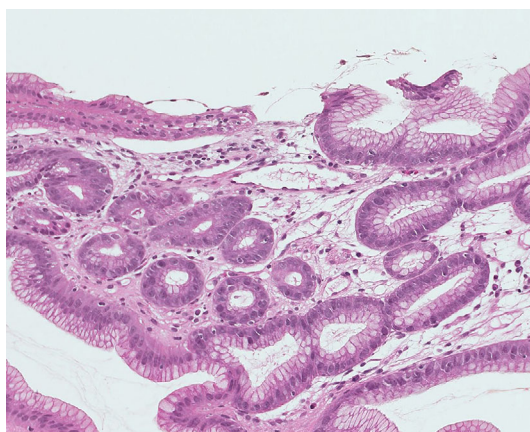


Figure 5. Mild inflammatory cell infiltration was observed.

a Mayo endoscopic score of 2 (Fig. 3). On day 8, remission induction therapy with tacrolimus was started. Thereafter, the bloody stool disappeared; however, gastric discomfort and muscle pain in the lower extremities persisted. The DLST was strongly positive for prednisolone; therefore, the

patient was diagnosed with an allergy to prednisolone, and prednisolone was tapered and discontinued.

After the discontinuation, the gastric discomfort and muscle pain in the lower extremities disappeared. On day 16, EGD was performed again, which confirmed the improvement of the mucosa (Fig. 4). A biopsy was performed for the histological assessment of inflammation. A histological examination showed improvement in the inflammatory cell infiltration (Fig. 5). The DLST was negative for mesalazine, indicating a low possibility of allergy to this drug, and mesalazine was restarted on day 22. The patient achieved clinical remission with combination therapy of tacrolimus and mesalazine and was discharged on day 32.

Discussion

There have been several reported cases of complications due to topical or systemic corticosteroids, including anaphylactic reaction, urticaria, and angioedema. Patel and Bahna reviewed 106 cases of hypersensitivity reactions to corticosteroids in patients with an age range of 2-90 years by

searching the literature published from January 1, 2004, to December 31, 2014, on PubMed and reported the importance of recognition of immediate hypersensitivity reaction to corticosteroids. In their report, allergic reactions to steroids were observed via intravenous, oral, and intra-articular administrations of the drugs, and the diagnosis was made based on a history of the illness and the result of a challenge test, with the rate of positive patch test reactions reported to be 74.1% (2). Allergic reactions to steroids include contact dermatitis associated with topical steroids, allergic contact stomatitis, and delayed hypersensitivity reaction of the nasal mucosa (3). In particular, the presence of skin or mucosal chronic inflammation is considered to increase contact allergen penetration, leading to the establishment of sensitization.

Cases of steroid allergy in patients with ulcerative colitis are rarely reported. However, there are reports on allergic reaction to topical preparations (steroid enema). Monk and Skipper concluded that allergy to steroids should be considered in patients with inflammatory bowel disease (IBD) who are using rectal steroid preparations (4). There are also reported cases of allergy to topical steroids in patients with IBD, as described above. However, to our knowledge, there have been no reports of allergy to systemic steroids (intravenous or oral administration).

Regarding the possibility of adverse reactions to steroids, there is one case report describing an infection (5), and several reports have indicated that glucocorticoids only rarely cause peptic ulcers and thus are not regarded as a risk factor. Furthermore, as our patient presented with diffuse hemorrhaging in the entire gastric body mucosa, his condition was considered to be clearly different from those associated with common drug-induced peptic ulcers. The episode of hematemesis in the present case requires a differential diagnosis from upper GI lesions associated with ulcerative colitis. Hori et al. raised the possibility that upper GI lesions associated with ulcerative colitis can occur while on a steroid-free regimen or under treatment with relatively low-dose prednisolone. The present case did not correspond with the condition suggested by Hori et al. because the upper GI bleeding occurred during treatment with prednisolone 20 mg/day. We therefore considered the findings in the present case to be suggestive of upper GI bleeding due to allergy rather than upper GI lesions associated with ulcerative colitis (6). In addition, in theory, there is a possibility that our patient had an allergic reaction to an additive substance in the prednisolone tablet, although there are no previous reports describing such allergic responses.

Regarding muscle pain, Levin et al. reported that 65% of patients treated with glucocorticoid for ≥ 1 year complained of weakness in the lower extremities and that amyotrophy was objectively observed in 20% of patients (7). In addition, Pereira et al. reported that steroid myopathy symptoms are

characterized by painless muscle weakness and amyotrophy that first occur in the proximal lower extremities and spread to the proximal upper extremities and the distal parts (8). In our patient, the time from treatment to the onset was short, and he complained of muscle pain, which was inconsistent with steroid myopathy characteristics (i.e. painless muscle weakness and amyotrophy). We therefore concluded that the symptoms were caused by allergic reactions to prednisolone. In general, the incidence of upper GI bleeding is not high in patients with ulcerative colitis; however, there are several reported cases of upper GI bleeding associated with lesions that arise due to the exacerbation of ulcerative colitis (9, 10). Although there are no reported cases of GI bleeding from gastric mucosal lesions caused by drug allergy, the upper GI bleeding in the present case, which occurred during clinical remission, was considered to be caused by an allergic reaction to steroid, based on the clinical course and test findings.

We encountered a case of upper GI bleeding due to drug allergy to prednisolone in a patient with ulcerative colitis.

The authors state that they have no Conflict of Interest (COI).

References

1. Rachmilewitz D. Coated mesalazine (5-aminosalicylic acid) versus sulphasalazine in the treatment of active ulcerative colitis: a randomised trial. *BMJ* **298**: 82-86, 1989.
2. Patel A, Bahna SL. Immediate hypersensitivity reactions to corticosteroids. *Ann Allergy Asthma Immunol* **115**: 178-182, 2015.
3. Bircher AJ, Pelloni F, Langauer Messmer S, Müller D. Delayed hypersensitivity to corticosteroids applied to mucous membranes. *Br J Dermatol* **135**: 310-313, 1996.
4. Monk BE, Skipper D. Allergy to topical corticosteroids in inflammatory bowel disease. *Gut* **52**: 597, 2003.
5. McCallum C, Johnson B. Mycobacterium chelonae bacteremia in a patient taking infliximab and prednisone. *CMAJ* **188**: 17-18, 2016.
6. Hori K, Ikeuchi H, Nakano H, et al. Gastroduodenitis associated with ulcerative colitis. *J Gastroenterol* **43**: 193-201, 2008.
7. Levin OS, Polunina AG, Demyanova MA, Isaev FV. Steroid myopathy in patients with chronic respiratory diseases. *J Neurol Sci* **338**: 96-101, 2014.
8. Pereira RM, Freire de Carvalho J. Glucocorticoid-induced myopathy. *Joint Bone Spine* **78**: 41-44, 2011.
9. Cordova J, Gokhale R, Kirschner B. Fever and upper GI hemorrhage in a 10-year-old girl with newly diagnosed ulcerative colitis. *Gastroenterology* **149**: 867-869, 2015.
10. Uchino M, Matsuoka H, Bando T, et al. Clinical features and treatment of ulcerative colitis-related severe gastroduodenitis and enteritis with massive bleeding after colectomy. *Int J Colorectal Dis* **29**: 239-245, 2014.

The Internal Medicine is an Open Access journal distributed under the Creative Commons Attribution-NonCommercial-NoDerivatives 4.0 International License. To view the details of this license, please visit (<https://creativecommons.org/licenses/by-nc-nd/4.0/>).